

# Non-neoplastic diseases of the cervix in Nigerians : A histopathological study

Olutoyin. G. Omoniyi-Esan,\* Steven. A. Osasan, Olusegun. S. Ojo

Department of Morbid Anatomy and Forensic Medicine, Faculty of Basic Medical Sciences, College of Health Sciences, Obafemi Awolowo University Ile-Ife, Nigeria

\* Department of Morbid Anatomy and Forensic Medicine, Obafemi Awolowo University Teaching Hospitals Complex Ile-Ife, Nigeria

## Abstract

**Background:** Diseases of the cervix are common in young sexually active women. Non-neoplastic diseases are predominantly inflammatory and are common but there are a few publications on the subject compared to neoplastic diseases of the cervix.

**Materials and Methods:** The surgical day books of the Histopathology department of the Obafemi Awolowo University Teaching Hospitals Complex Ile-Ife, Nigeria from the year 1990-1999(Ten years) were studied for all cervical biopsies.

**Results:** Four hundred (400) cervical surgical biopsies were received during this period. 150 (37.5%) of the cases were non-neoplastic lesions. Age range was 20-69 years with peak incidence at 40-49 years.

Histological distribution showed 123 cases (82%) were chronic non-specific cervicitis. Eighteen cases (12%) were chronic cervicitis with koilocytic change pathognomonic of Human Papilloma Virus (HPV) infection, two- third (12cases) of which occur within 40-49years. There were five cases (3.3%) of chronic granulomatous cervicitis, three cases (2.0%) of acute cervicitis and only one case (0.7%) of microglandular endocervical hyperplasia .

**Conclusion:** All the histological types were found within the peak age incidence of 40-49 years. Chronic non-specific cervicitis was the most common non-neoplastic cervical lesion and it occurs in all age groups of women studied. In 12% of patients it is associated with cytopathic effect of HPV. This has obvious implication for the occurrence of carcinoma of the cervix in our country. We recommend routine pap smear test in this group of patients especially, as a way of reducing the occurrence of carcinoma of the cervix.

**Key words:** Non-neoplastic, Cervix, Disease.

*African Health Sciences* 2006; 6(2): 76-80

## Introduction

Diseases of the cervix are common in young sexually active women.<sup>1</sup>

Non-neoplastic diseases of the cervix are predominantly inflammatory in nature.

Infections and inflammatory lesions of the cervix are common but there is a dearth of literature on the histological characteristics of these lesions.

Cervical inflammation may be acute, chronic or active (acute-on-chronic). Each of these may be from non-infective and infective causes. Non infective cervicitis is most often chemical in nature. Common causes include chemical irritations secondary to douching or local trauma produced by foreign bodies including tampons, diaphragms, pessaries and intrauterine contraceptive devices.<sup>1</sup>

The aetiology of infective cervicitis is variable and consists commonly of sexually-transmitted diseases, *Staphylococcus aureus*, endogenous vaginal aerobes and anaerobes among others. Although frequently encountered clinically, there are few reports on the histopathology of these lesions. This is not unconnected to the fact that most of these infections are amenable to antimicrobial agents and do not require cervical surgical biopsy for diagnosis.

Chronic Granulomatous inflammation also affects the cervix. Worldwide, the commonest cause is tuberculosis<sup>2, 3</sup> Other less frequent causes include schistosomiasis, amoebiasis<sup>4</sup>, enterobiasis, actinomycosis, lymphogranuloma venereum (LGV) and syphilis.

Tuberculous cervicitis usually arises secondary to disseminated tuberculosis and usually produces ulcerative lesion and sometimes hypertrophic lesions which may grossly simulate carcinoma of the cervix<sup>5</sup>. In a study by Chakraborty et al, hypertrophic lesions were found to be predominant and contain abundant acid fast bacilli than the ulcerative lesions<sup>6</sup>. The occurrence of concomitant tuberculous cervicitis and carcinoma has also been reported.<sup>7</sup>

Schistosomiasis is endemic in the tropics. In severe infections, calcified ova of *Schistosoma* may be seen in the genital tract. Cervical involvement may be

### Correspondence to:

Olutoyin. G. Omoniyi-Esan

Department of Morbid Anatomy and Forensic Medicine,

Faculty of Basic Medical Sciences

College of Health Sciences,

Obafemi Awolowo University Ile-Ife, Nigeria

e-mail [gomoniyi\\_esan@yahoo.com](mailto:gomoniyi_esan@yahoo.com), or [goesan@oauife.edu.ng](mailto:goesan@oauife.edu.ng)

Tel: 234-08033536852.

present as polypoid or nodular masses<sup>8</sup>. Viruses especially *Human papilloma virus* and *Herpes simplex virus* commonly infect the cervix and are strongly associated with carcinoma of the cervix<sup>9 10</sup>

Other lesions seen in the cervix include tunnel cluster, mesonephric hyperplasia, endometriosis and microglandular endocervical hyperplasia.<sup>11, 12</sup>. These lesions may be misinterpreted as malignant. Familiarity with their histopathological features is essential in their recognition and appropriate management.

The aim of this study is make information available on non-neoplastic diseases of the cervix from our routine histopathological practice.

## METHODS

The register of the histopathology department of the Obafemi Awolowo University Teaching Hospitals Complex, Ile-Ife from the year 1990-1999 (10 years) were studied for all cervical biopsies. The original requests cards were retrieved and information such as age and histopathological diagnosis were extracted.

All non-neoplastic cervical biopsies specimens were assessed for the study. In our histopathology laboratory at Ile-Ife, cervical surgical specimens as other specimens are routinely formalin fixed, paraffin-embedded, and cut at 2-3mm. All such sections are routinely stained with haematoxylin and eosin stains.

Vital statistical data like age and histopathological diagnosis were noted. All the slides of the patients with non-neoplastic cervical pathology were retrieved and examined. Where not available, fresh sections were cut and stained with routine haematoxylin and eosin stains.

The biopsies were classified into acute cervicitis, chronic non-specific cervicitis, chronic cervicitis with koilocytic change, granulomatous cervicitis, and miscellaneous lesions (e.g microglandular hyperplasia, endometriosis, turnell clusters).<sup>1</sup>

Data were processed using SPSS version 10.0. Descriptive methods such as tables and figures were used for presentation of the results.

## RESULTS

Between the period January 1990 and December 1999, a total of four hundred and twenty-two (422) cervical surgical biopsies were received in the Department of Morbid Anatomy and Forensic Medicine, Obafemi Awolowo University Teach-

ing Hospitals Complex, Ile-Ife. Four hundred cases met the criteria for the study. This constituted 4.4% of surgical pathology cases from females and 3% of total surgical pathology specimens during the study period. Out of these, one hundred and fifty (150 cases) 37.5% were non-neoplastic lesions.

The age distribution of the patients is depicted in tables 1. The age range was 20-69 years while the peak age incidence was 40-49 years with 52 cases (34.7%). This is also the peak age for all the histological types. This is followed by age group 30-39 years with 45 cases (30.0%), 50-59 years with 28 cases (18.7%). The least number of patients is seen in age group 20-29 years with only 11 cases (7.3%). It is noteworthy to note that majority of non-neoplastic lesions (83.4%) occurred in age group 30-59 years.

The histological types of non-neoplastic lesions are shown in table 2 and Fig 1 shows the histological types seen within each age group.

**Table 1: Age distribution of patients with non-neoplastic lesions of the cervix.**

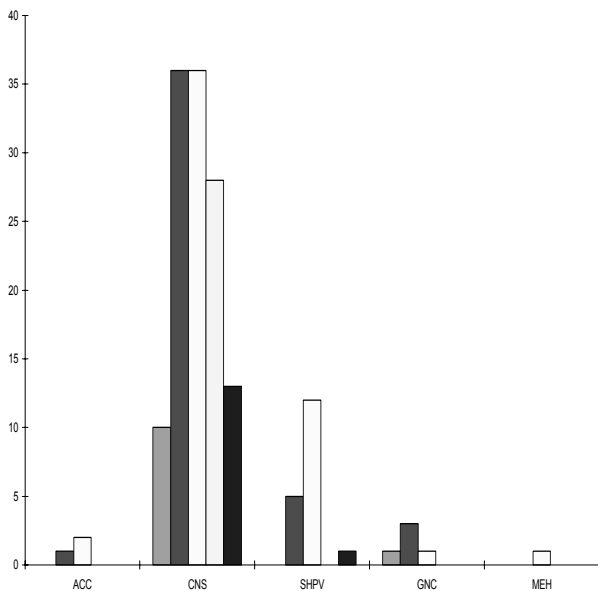
Age range	No of patients	Percentage
20-29	11	7.3
30-39	45	30.0
40-49	52	34.7
50-59	28	18.7
60-69	14	9.3
<b>Total</b>	<b>150</b>	<b>100.0</b>

**Table 2: Histological types of non-neoplastic lesions**

Histological types	No of cases	Percentage
Acute cervicitis	3	2.0
Chronic non-specific cervicitis	123	82.0
Chronic non-specific cervicitis with subclinical HPV infection (Koilocytosis)	18	12.0
Chronic granulomatous cervicitis	5	3.3
Microglandular endocervical hyperplasia	1	0.7
<b>Total</b>	<b>150</b>	<b>100.0</b>

Chronic non-specific cervicitis was the commonest non-neoplastic lesion and constituted 123 cases (82.0%). It was also seen in all age groups. Eighteen cases (12.0%) were chronic cervicitis with koilocytic change pathognomonic of HPV infection. Two third of these (12cases) occur within 40-49years. Five cases (3.3%) of chronic granulomatous cervicitis were seen, three of which were schistosomal cervicitis with numerous calcified ova. One of the cases was that of caseating granulomas suggestive of tuberculosis and the other has stellate abscess with numerous neutrophils suggestive of actinomycosis. There were only three cases with features of acute cervicitis. There was a case of microglandular endocervical hyperplasia. The complete spectrum of the non-neoplastic diseases occurs in the age group 40-49years. Majority of women within the age group 50-69years have chronic non-specific cervicitis.

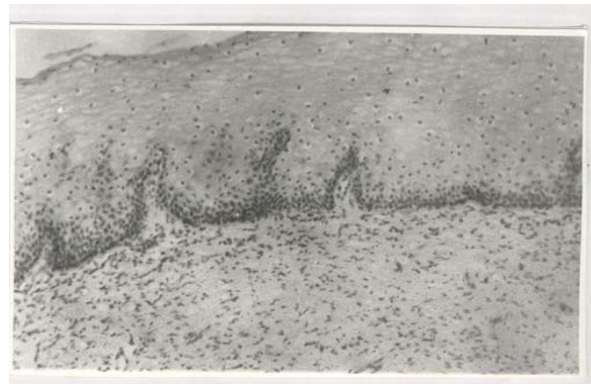**Figure 1. Histological types according to age – groups**



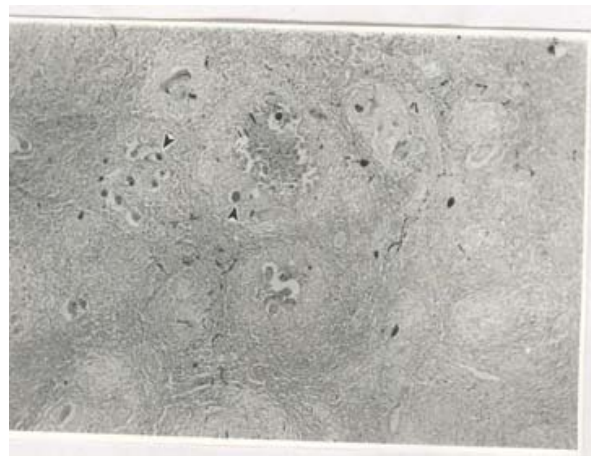**Keys:**

ACC – acute cervicitis, CNS – chronic non-specific cervicitis,  
 SHPV – chronic non-specific cervicitis with sub-clinical HPV infection.  
 GNC –granulomatous cervicitis, MEH–microglandular endocervical hyperplasia.

**Fig. 2: Photomicrograph of the cervix showing chronic cervicitis with koilocytosis. Note the koilocytic change in the upper two-third of the epithelium and numerous mononuclear inflammatory cells in the stroma. H&E X144.**



**Fig 3:Photomicrograph of the cervix showing granulomatous cervicitis. Note numerous granulomas with calcified schitosome ova (arrow heads ) at the centre.The epithelium (not shown )is completely ulcerated. H&EX 58.**



Chronic non-specific cervicitis was the commonest non-neoplastic lesion and constituted 123 cases (82.0%). It was also seen in all age groups. Eighteen cases (12.0%) were chronic cervicitis with koilocytic change pathognomonic of HPV infection. Two third of these (12cases) occur within 40-49years. Five cases (3.3%) of chronic granulomatous cervicitis were seen, three of which were schistosomal cervicitis with numerous calcified ova. One of the cases was that of caseating granulomas suggestive of tuberculosis and the other has stellate abscess with numerous neutrophils suggestive of

actinomycosis. There were only three cases with features of acute cervicitis. There was a case of microglandular endocervical hyperplasia. The complete spectrum of the non-neoplastic diseases occurs in the age group 40-49 years. Majority of women within the age group 50-69 years have chronic non-specific cervicitis.

## DISCUSSION

Chronic non-specific cervicitis constituted 82.0% of all non-neoplastic lesions. This is not surprising because it is a frequently encountered condition both clinically and in histopathological specimens<sup>2</sup>. True chronic cervicitis is diagnosed histologically by the presence of a heavy mixed chronic inflammatory cell infiltrates – lymphocytes, plasma cells and histiocytes. This study showed that chronic non-specific cervicitis occurs in all age groups in our women between 20-69 years. Though, it is said to be rare before menarche or after menopause<sup>2</sup>, it is the main non-neoplastic lesion seen in the menopausal women in this study. This may be due to the fact that most of these women are still sexually active though menopausal. Infection of the female genital tract of which the cervix is the “gate-way” not only predisposes women to tubal infertility but also to the risk of ectopic pregnancy<sup>13,14</sup>.

There are very few reports describing the histopathology of chronic cervicitis. Most of the studies available are on cytological and microbiological diagnosis<sup>1,2,3,4,5</sup>. *Chlamydia trachomatis* infection is the most prevalent sexually transmitted disease in developed countries and appears to be equally prevalent in developing countries. The prevalence in Gambia is 6.9%<sup>16</sup>, Ghana 7.7%<sup>17</sup> and Kenya 10.0%<sup>18</sup> in women attending antenatal clinics<sup>13,6</sup>. In Nigeria, a prevalence of 10.5% was reported among sexually active adolescent girls<sup>7</sup>. *Chlamydia cervicitis* is significantly associated with cervical ectropion<sup>8,9</sup>. The histopathological hallmarks of infection with *C. trachomatis* are sub-epithelial lymphoid follicles, fibrosis and scarring. Kiviati et al documented well-formed lymphoid follicles with germinal centres in 67% of culture-proven infection with *C. trachomatis*<sup>10</sup>.

None of the cases seen in this series has any of these features. Patients with chronic non-specific cervicitis usually have mixed infiltrates of plasma cells, histiocytes, lymphocytes and occasional neutrophils. These histological features are present in our patients.

Chronic granulomatous infections are very common in the tropics. In severe infection there may be involvement of the cervix. Schistosomiasis and tuberculosis are frequently encountered. Schistosomiasis of the cervix caused by *S. mansoni* is very common in Egypt, South America, Puerto Rico and several Asian countries<sup>1</sup>. Many cases of cervical schistosomiasis are associated with urinary schistosomiasis. It may also be associated with extensive pseudo-epitheliomatous hyperplasia of cervical squamous epithelium. Association with carcinoma of the cervix has also been reported<sup>1</sup>. The cases seen in this study had erosion of the ectocervix.

Genital tract tuberculosis in order of frequency affects more commonly the fallopian tubes, the corpus, ovary and occasionally the cervix. The incidence of cervical tuberculosis in the general population is 2-6%<sup>5</sup>.

Viral cervicitis is very important clinically. Over the years there has been increasing detection of subclinical HPV infection cytologically and histologically. The hallmark of infection with HPV is koilocytic change in the epithelial cells, which correlates well with HPV nucleic acid by in-situ hybridisation<sup>9</sup>. In this series 18 cases (12.0%) of the chronic cervicitis showed koilocytic atypia (sub-clinical HPV infection). A higher value of 37.0% of koilocytic atypia was reported in cytologically screened dysplastic smears in Ibadan<sup>15</sup>.

Two-third of the cases occur within 40-49 years. This is also the peak age incidence for carcinoma of the cervix in our environment<sup>24</sup>. High grade HPV (serotype 16 and 18) is strongly associated with cervical cancer<sup>25,26</sup>. Infection with HPV is thought to be the initiating event; other factors like co-existing microbial infection and cigarette smoking also contribute to cervical carcinogenesis.

Only 2.0% cases of acute cervicitis were seen. Patients with acute cervicitis usually present with acute discomfort, purulent cervical discharge and are treated medically. Most of the patients do not require cervical biopsy. Acute cervicitis may follow trauma due to parturition or abortion, inappropriate use of tampons or infection by pathogenic agents.<sup>2</sup> *T. vaginalis* infection of the cervix produces acute cervicitis. The histological features of which include spongiosis, ulceration and necrosis of diffuse punctuated erythema. Cytologically *T. vaginalis* infection can easily be recognized by the presence of ovoid trichomonad organism and/or prominent perinuclear halo.<sup>15</sup>

In conclusion, the peak age incidence of 40-49 years shows that women in this age group are prone to cervical lesions. All the histological types were also found within this age range. Chronic non-specific cervicitis is the most common non-neoplastic cervical lesion and occurs in all age groups of women studied. This shows that the burden of non-neoplastic cervical lesions in the women of reproductive age is infective in origin with its attending sequelae.

We recommend routine pap smear test in this group of patients especially, as a way of reducing the occurrence of carcinoma of the cervix.

## References

- 1 Kurman RJ. (ed). Blaustein's pathology of the female genital tract. 4<sup>th</sup> edition Springer –Verlag. NewYork 1994. 6 :203-225
- 2 Lowe D, Slavin G. Non- neoplastic conditions of the cervix : In Fox H (ed). Haines & Taylor: Obstetrical and Gynaecological pathology. 4<sup>th</sup> edition Churchill Livingstone New York 1995. 6:249-267
- 3 Koller AB: Granulomatous lesions of the cervix uteri in Black patients: **S Afr Med J**. 1975;49(30):1228-32.
- 4 Nopdonrattakoon L. Amoebiasis of the female genital tract: a case report. **J Obstet Gynaecol Res**. 1996;22(3):235-8.
- 5 Cook G: Manson's Tropical Diseases 12<sup>th</sup> edition. WB Saunders Philadelphia 1996. 57:989-999
- 6 Chakraborty P, Roy A, Bhattacharya S, Addhya S, Mukherjee S. Tuberculous cervicitis: a clinicopathological and bacteriological study. **J Indian Med Assoc**. 1995;93(5):167-8.
- 7 Yamabe T, Nakayama M, Suzuki K, Fukuda E Coincidence of carcinoma and tuberculosis of the uterine cervix. **Gan No Rinsho**. 1972;18(2):151-3.
- 8 Helling-Giese G, Sjaastad A, Poggensee G, Kjetland EF, Richter J, Chitsulo L, Kumwenda N, Racz P, Roald B, Gundersen SG, Krantz I, Feldmeier H.: Female genital schistosomiasis (FGS): relationship between gynecological and histopathological findings: **Acta Trop**. 1996;62(4):257-67.
- 9 Herrington C. S. Human papillomavirus and cervical neoplasia I: Classification, virology, pathology and epidemiology. **J. Clin. Pathol** 1994; 47:1006-1072.
- 10 Cooper K, Herrington CS, Es-llo et al. Integration of HPV type 16 and 18 in cervical adenocarcinoma. **J. Clin. Pathol** 1992: 45:382-384.
- 11 Nucci MR. Symposium part III: tumor-like glandular lesions of the uterine cervix. **Int J Gynecol Pathol**. 2002 Oct;21(4):347-59.
- 12 Da Forno PD, McGregor AH, Brown LJ. Microglandular hyperplasia: a pitfall in the diagnosis of microglandular type endometrioid adenocarcinoma. **Histopathology**. 2005;46(3):346-8
- 13 Collet M, Reniers J. Frost E et al: Infertility in Central Africa: Infection is the cause. **Int. J. Gynaecol Obstet** 1988; 26:423-428.
- 14 Sule-Odu OA, Fakoya TA, Odusoga OL. Asymptomatic endocervical infection in infertile women in Sagamu, Nigeria. **Nigerian Medical Practitioner** 1999: 37(1-2): 9-11.
- 15 Konje JC, Ogunniyi JO. Otolorin EO. Odusoga OL et al. Cervical cancer screening at Ibadan. **Eur. J. Gynaecol Oncol** 1991. 12; 1:55-61.
- 16 Mabey DEW, Lloyd-Evans N, Contehs et al. Sexually transmitted disease among randomly selected attendees at an antenatal clinic in the Gambia. **Br. J. Vener Dis** 1984: 60:331-336.
- 17 Bentsi C, Klufio CA., Perine PL. et al. Genital infections with *Chlamydia trachomatis* and *N.gonorrhoea* in Ghanaian Women. **Genitourin Med** 1985; 61:4-50.
- 18 Loyal M, Plummer F, Nganze H et al. Epidemiology of ophthalmia neonatorum in Kenya. **Lancet** 1986; 2: 11345-11348.
- 19 Brabin L, Kemp J, Obunge K. et al .Reproductive tract infections and abortion among adolescent girls in rural Nigeria. **Lancet** 1995; 345: 300-304.
- 20 Brunham RC., Paavonem S, Steven CE. et al Mucopurulent cervitis –The ignored counterpart in women of urethritis in men. **N. Engl. J. Med**. 1984; 311 (1): 1-6.
- 21 Critihlour CW, Wolner – Hanssen P, Eschenbau DA. et al. Determinants of cervical ectopia and of cervitis: Age, oral contraception, specific cervical infection. **Am. J. Obstet Gynecol** 1995: 173:534-43.
- 22 Kiviat NB, Paavonen JA. Wolner-Hanssen P. et al. Histopathology of endocervical infection caused by. *Chlamydia trachomatis* *Herpes simplex virus*, *Trichomonas vaginalis* and *Neisseria gonorrhoea*. **Hum Pathol**: 1990; 21(8): 831-837.
- 23 Moubayed P, Ziehe A, Peters J, Mwakyoma H, Schmidt D: Carcinoma of the uterine cervix associated with schistosomiasis and induced by human papillomaviruses. **Int J Gynaecol Obstet**. 1995;49(2):175-9
- 24 Omoniyi-Esan GO, Fasubaa OB, Adelusola KA, Ojo OS. Histopathological pattern of cervical malignancies in south-western Nigeria. **Trop J Obstet Gynaecol**: 2004;21:118-121
- 25 Walboomers JMM, Jacobs MV, Manos et al . Human papillomavirus is a necessary cause of invasive cancer worldwide. **J.Clin.Pathol**. 1999:189: 12-19.
- 26 Munoz N; HPV and Cervical Cancer: Review of cases – control and cohort studies. In Mujuo ZN, Bosch FX, Shah KV et al (ed). The epidemiology of human papillomavirus and cancer. **Lyon: IARC Scientific Publication**. 1992:119; 251-261.