

Use of stents for treating obstruction of urinary outflow in patients unfit for surgery

Departments of Surgery and Radiology, Royal Postgraduate Medical School, Hammersmith Hospital, London W12 0HS

G Williams, FRCS, consultant urologist

R Jager, MD, senior registrar

J McLoughlin, FRCS, registrar

L Machan, FRCP, senior registrar

K Gill, FRCSI, registrar

R Asopa, FRCS, registrar

A Adam, FRCR, radiologist

Medinvent SA, Lausanne, Switzerland

A El Din MD, consultant radiologist

Correspondence to: Mr Williams.

Br Med J 1989;298:1429

G Williams, R Jager, J McLoughlin, A El Din, L Machan, K Gill, R Asopa, A Adam

Transurethral resection is the most widely accepted treatment for obstruction of urinary outflow. The associated morbidity and mortality have led to a search for less invasive treatments. Expandable tubular stents of stainless steel mesh have been used successfully in patients with recurrent urethral strictures.¹ We assessed the safety and efficacy of these stents inserted into the prostatic urethra under topical anaesthesia in a group of patients considered to be unsuitable for surgery.

Patients, methods, and results

Nine patients aged between 70 and 84 with permanent indwelling catheters were treated. They had presented previously with obstruction of urinary outflow and were considered unsuitable for surgery. In

the radiology department retrograde urethrography was performed to locate the external sphincter. With 2% lignocaine gel as the surface anaesthetic the end of the delivery device of a 14 mm diameter system (Wallstent, Medinvent) was pushed 1-2 cm past the neck of the bladder and the outer sheath withdrawn, leaving the stent lying within the prostatic urethra close to the external sphincter. A 14 French gauge catheter was introduced into the bladder through the stent over the guidewire. The catheter was removed 24 hours later and the position of the stent checked.

All nine patients voided spontaneously after removal of the urethral catheter. Peak urinary flow rates ranged between 10 and 22 ml/s. No residual urine was detected in any patient on ultrasonography. One patient had mild stress incontinence for 12 days after the procedure but then became fully continent. After four months only two patients had developed a urinary infection, and both infections were asymptomatic.

Comment

We believe that we are the first to describe the use of prostatic stents to relieve obstruction of urinary outflow. These stents, which were originally designed for intravascular use,² have many features that make them ideal for use in the prostatic urethra: they are made from stainless steel mesh woven into a self expanding tube that can be restrained and inserted into a small bore delivery system and yet attain a calibre that allows good urinary flow (figure); they are elastic and strong enough to resist the closing pressure of the prostatic urethra; their pliability allows them to sit comfortably without appreciable distortion; the pores in the mesh allow the epithelium to cover the stent; and they do not prevent future endoscopy of the bladder.

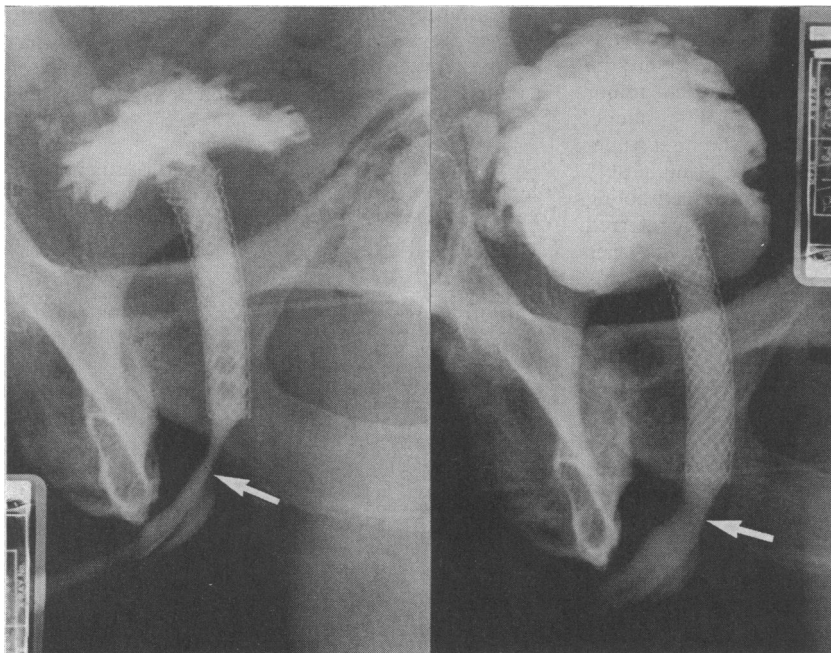
Figures quoted for mortality related to prostatic surgery range from 1.6 to 6.4% in selected high risk groups and highlight the need for alternative forms of treatment.³ Insertion of stents is carried out easily in the radiology department under topical anaesthesia and does not require admission to hospital, although long term follow up is essential. At present we cannot advocate using stents to treat men with symptoms of obstruction of urinary outflow, but we hope that they may offer elderly and infirm patients an alternative to prostatic surgery.

1 Milroy EJJ, Chapple CR, Cooper JE, et al. A new treatment for urethral strictures. *Lancet* 1988;i:1424-7.

2 Palmaz JC, Windler SA, Garcia F, Tio FO, Sibbit RR, Reuter SR. Atherosclerotic rabbit aortas: expandable intraluminal grafting. *Radiology* 1986;160:723-6.

3 Melchior J, Valk WL, Foret JD, Mebust WK. Transurethral prostatectomy in the azotemic patient. *J Urol* 1974;112:643-6.

(Accepted 16 March 1989)



Retrograde urethrograms showing stent within prostatic urethra (left) and during voiding (right). Arrows indicate external sphincter

Hearing loss leading to impaired ability to communicate in residents of homes for the elderly

J K Anand, Ivy Court

Peterborough Health Authority, Peterborough PE1 1LN

J K Anand, FFCM, district medical director

Ivy Court, CERTED (FAE), specialist teacher

Correspondence to: Dr Anand.

Br Med J 1989;298:1429-30

An impaired ability to communicate leads to loss of independence, social isolation, irritation, and unhappiness.¹ Sixty per cent of people aged over 70 have some degree of deafness.² We tried to identify and ameliorate hearing loss that leads to an impaired ability to communicate in residents of homes for the elderly.

Subjects, methods, and results

Altogether 304 of the 316 residents of eight homes in Peterborough were assessed informally by IC, who is a specialist teacher experienced in the rehabilitation of adults with acquired hearing loss; three residents refused to be assessed, one did not understand English, and eight were away from the home. For the assessment IC and the resident sat facing each other about a metre apart in a quiet, well lit room. When necessary a personal amplifier was used to see whether communication improved. Audiometry was not used. Hearing aids were tested by switching them on, turning the volume to maximum, and holding them in a cupped hand; under these conditions a functioning aid should whistle. Non-functioning aids were tested for a flat battery and for twisted or blocked tubing; blockages