

cause a considerable difference in electrophoretic mobility when compared with haemoglobin A (Figs. 6 and 7).

Summary

In two surveys, each of 100 non-anaemic patients in Shiraz, Iran, two examples of haemoglobin D Punjab were found. In a third survey of 400 anaemic patients in Teheran, thalassaemia, haemoglobin S, haemoglobin D, and haemoglobin C were found. In addition, a new haemoglobin, J Iran, $\alpha_2\beta_2$ 77 His→Asp, was discovered.

One of us (S.R.) is indebted to Drs. H. Mirdamadi, Mefidi, and Roberts for their advice and co-operation. We should like to thank Mr. D. Irvine, who prepared the fingerprints of the haemoglobin D samples found in the Shiraz Survey. We are also indebted to

Professor W. Dutz and his staff, of Pahlavi University, for help with the collection of samples in Shiraz.

REFERENCES

- Ager, J. A. M., and Lehmann, H. (1958). *Brit. med. J.*, **1**, 929.
 Baglioni, C. (1961). *Biochim. biophys. Acta (Amst.)*, **48**, 392.
 — and Weatherall, D. J. (1963). *Ibid.*, **78**, 637.
 Beale, D., and Lehmann, H. (1965). *Nature (Lond.)*, **207**, 259.
 Chernoff, A. I., and Pettit, N. M. (1964). *Blood*, **24**, 750.
 Clegg, J. B., Naughton, M. A., and Weatherall, D. J. (1965). *Nature (Lond.)*, **207**, 945.
 Huehns, E. R., and Shooter, E. M. (1965). *J. med. Genet.*, **2**, 48.
 — and Beaven, G. H. (1962). *J. molec. Biol.*, **4**, 323.
 Ingram, V. M. (1958). *Biochim. biophys. Acta (Amst.)*, **28**, 539.
 Itano, H. A., and Robinson, E. (1953). *Nature (Lond.)*, **184**, 1468.
 Nirenberg, M., Leder, P., Bernfield, M., Brimacombe, R., Trupin, J., Rottman, F., and O'Neal, C. (1965). *Proc. nat. Acad. Sci. (Wash.)*, **53**, 1161.
 Sanger, F., and Tuppy, H. (1951). *Biochem. J.*, **49**, 463.
 Spackman, D. H., Stein, W. H., and Moore, S. (1958). *Analyt. Chem.*, **30**, 1190.
 Watson-Williams, E. J., Beale, D., Irvine, D., and Lehmann, H. (1965). *Nature (Lond.)*, **205**, 1273.

Medical Memoranda

Massive Haematuria Associated with Sickle-cell Trait

Brit. med. J., 1967, **1**, 677-679

The incidence of sickle-cell disease in the Negro race in the United States has been estimated at between 7% (Killingsworth and Wallace, 1936) and 13% (Beck and Hertz, 1935). Among West Indian Negroes in Jamaica the incidence of this disease has been estimated at 11% by Went (1957). The incidence of the heterozygous sickle-cell trait (haemoglobinopathy A-S) is estimated as 40 times that of the homozygous sickle-cell anaemia (haemoglobinopathy S-S).

As a result of immigration, sickle-cell disease is now often encountered in Britain (Dixon, 1962; Beard and Signy, 1965). Massive haematuria has become a well-established though rare complication of sickle-cell trait in the United States and the West Indies, but it does not seem to have been reported previously in Britain. The following case is therefore presented to draw attention to this condition and to suggest that this diagnosis should be considered early in the investigation of massive haematuria in a susceptible patient.

CASE REPORT

A 25-year-old Jamaican Negro was referred to hospital in December 1960 with profuse painless haematuria. There was nothing of note in either his previous medical history or his family history. No abnormal features were found on a routine examination of blood smears. An excretory pyelogram was normal. Cystoscopy was undertaken on two occasions and no cause for the bleeding was found. Ascending pyelograms were performed; on the right side the appearances were normal, while there was a filling defect in the upper calix on the left side. A tumour was suspected, but an aortogram did not confirm this diagnosis.

Massive haematuria recurred on 10 April 1961 and persisted after admission to hospital. The left kidney was explored after cystourethroscopy on 26 April. The kidney appeared normal to palpation and it was possible to invaginate the pelvis into the suspicious upper calix without any abnormality being detected. In the post-operative period haematuria recurred.

A second urethroscopy was undertaken on 18 May in another hospital. Granulation tissue was found in the posterior urethra and diathermy was given. Several specimens of urine were found to be free of red cells at this time, and the possibility of a self-inflicted injury was considered.

He was next referred to the Urological Clinic at the General Hospital, Birmingham, on 7 July. At this time he had a heavy haematuria, a blood-pressure of 180/115 mm. Hg, haemoglobin 12.7 g./100 ml., and serum urea 26 mg./100 ml. A mid-stream specimen of urine contained a significant number of pus cells and yielded *Escherichia coli* and *Proteus mirabilis* on culture. An excretory pyelogram showed a central translucency in the upper group of calices on the left side, thought to be blood clot.

He was admitted to the Queen Elizabeth Hospital, Birmingham, on 3 November on account of further persistent haematuria associated with pain and discomfort in the left renal area. Haemoglobin was then 8.8 g./100 ml., and increased variation in the size and shape of the red cells was noted. Serum urea was 22 mg./100 ml. and the urine was sterile although profuse numbers of red cells were reported. Blood-pressure remained 180/115 mm. Hg.

At cystoscopy on 6 November blood was seen coming from the left ureteric orifice. A left ascending pyelogram was performed, and as this showed a constant filling defect the left kidney was explored later the same day. There were dense adhesions from the previous exploration and the kidney was mobilized only with difficulty. The ureter appeared normal apart from containing blood clot; the kidney also appeared normal but was difficult to examine. In view of the protracted bleeding from this kidney a nephrectomy was performed.

The kidney weighed 105 g. and seemed to be normal apart from a depressed area measuring 2 by 2 cm. at the upper pole, to which the capsule was adherent and the borders of which were haemorrhagic. On histological examination there was an area of dense fibrosis with loss of tubules and crowding together of glomeruli, which themselves showed loss of structure but no dense fibrosis. Around the periphery of the lesion was a chronic inflammatory reaction consisting mainly of lymphocytes. Occasional haemosiderin-laden macrophages and haematoidin crystals were present. A small artery was occluded by thrombus. While the nature of this lesion remained obscure, the appearances most closely resembled those of infarction, but were by no means typical. The remainder of the kidney showed no histological abnormality.

He made an uneventful recovery from the nephrectomy and was finally discharged on 3 January 1962, there having been no further haematuria.

He was next referred on 10 September 1965 with a 10-day history of massive haematuria associated with an aching pain in the right loin and dizziness. Haemoglobin was 11.4 g./100 ml. and blood films showed a slight variation in the size and shape of the red cells but were otherwise normal. Massive haematuria persisted and the haemoglobin fell to 8.8 g./100 ml. within six days. Blood-pressure was 165/100 mm. Hg, and serum urea 33 mg./100 ml.

The excretory pyelogram showed that the right kidney was 15 cm. in length and of normal shape. The calices, pelvis, and ureter appeared normal, while there was a filling defect in the bladder due to blood clot.

Cystoscopy was performed on 16 September and heavy haematuria noted. The bladder mucosa was normal, but blood was seen coming from the right ureteric orifice. It was thought that the likely diagnosis was focal pyelonephritis, but repeated specimens of urine were sterile. Creatinine clearance was 88 ml./min., with a serum creatinine of 1.6 g./100 ml.

It was then decided to investigate the clotting mechanism, and an elevation of prothrombin time to 19 seconds (control 13 seconds) was found despite normal liver-function tests. This defect was treated with intramuscular injections of vitamin K. Suitable preparations of wet films showed the presence of sickle cells, and on paper electrophoresis an abnormal haemoglobin with the mobility of haemoglobin-S was found in addition to haemoglobin-A.

Massive haematuria persisted and frequent transfusions were necessary to maintain the haemoglobin above 10 g./100 ml. It was thought that the bleeding might be continuing as a result of the activity of urokinase on the clot and that this fibrinolysis might be inhibited by epsilon-amino-caproic-acid therapy. This was given in the dose of 6 g. four times daily by mouth—the dose used in haemophilia—and after one week bleeding had ceased and has not recurred in the subsequent four months.

A further excretory pyelogram showed no evidence of persistence of clot within the renal pelvis.

DISCUSSION

Patients with sickle-cell anaemia are well known to show microscopic haematuria. Episodes of renal infarction and renal insufficiency are established complications but are usually incidental to the more dramatic symptoms of the disease (Bernstein and Whitten, 1960).

Abel and Brown (1948) reported the first case of massive haematuria in sickle-cell trait in a 23-year-old previously fit Negro soldier. The pyelographic appearance suggested a filling defect in the pelvis of the left kidney, and a nephrectomy was performed. No sickle cells had been seen in the peripheral blood before the operation, but they were recognized in sections of the kidney.

Harrison and Harrison (1952) reported nine cases of massive unilateral haematuria associated with the sickle-cell trait. Nephrectomy was performed on four patients either as a life-saving measure or to prevent chronic blood loss.

Twenty-seven previously reported cases were reviewed by Lund, Cordonnier, and Forbes (1954), who added seven cases of their own. One patient had had a left nephrectomy performed four years previously for massive haematuria and then presented with bleeding from the remaining right kidney. This is the first case reported to have bled from the remaining kidney, and it led the authors to recommend conservative management.

The largest series studied was reported by Mostofi, Bruegge, and Diggs (1957), who reviewed retrospectively the histological features of kidneys removed from 22 Negro soldiers on account of massive haematuria. The diagnosis was made on the finding of sickle cells in the kidney sections. A review of the clinical data showed that all the patients were previously healthy and presented with gross haematuria. Ten patients reported previous episodes of haematuria and seven complained of aching in the flank. In 19 patients blood was seen coming from the left ureteric orifice at cystoscopy. These authors discuss and

reject the possibility that the appearance of intravascular sickling might be an artifact produced by formalin fixation. Sections of the left kidney removed from our patient in 1961 have been reviewed by Dr. Douglas Brewer, who reports that he is unable to find positive evidence of sickling.

Twenty-one papers on this subject covering 97 patients were reviewed by Lucas and Bullock (1960). They found that 80% of the patients were male and that the bleeding came from the left kidney four times as often as from the right. In established cases of sickle-cell trait the age of presentation varied from 13 to 46 (mean 28.7). In 37 patients electrophoresis had been performed and 25 showed the heterozygous haemoglobinopathy A-S (sickle-cell trait). There were three cases of true sickle-cell anaemia, eight cases of sickle-cell haemoglobin-C disease, and one case of sickle-cell thalassaemia. Classification of all 97 patients on clinical grounds showed that 15 had sickle-cell anaemia and 82 had sickle-cell trait. Nephrectomy had been performed in 50% of the cases reported.

Seven instances of recurrent massive bleeding following earlier nephrectomy, such as occurred in our patient, were found in this review. However, most authors have not reported a long-term follow-up of their patients, and so the true incidence of recurrent bleeding from the remaining kidney may be higher.

The pyelographic appearances of the kidney in this condition are commonly misleading. In 15 patients (Mostofi *et al.*, 1957) the radiological appearances were suggestive of neoplasm, hydronephrosis, non-opaque stone, haemangioma, or blood clot. Our own case showed a deformity in the left renal pelvis suggestive of neoplasm on the initial excretory pyelogram, and an aortogram was performed prior to the exploration. A retrograde pyelogram performed before his left nephrectomy showed a constant filling defect, possibly a non-opaque stone, a papilloma of the renal pelvis, or blood clot.

In view of the pathological changes occurring in the renal papillae, Harrow, Sloane, and Liebman (1963) paid close attention to these areas in a radiological study of this condition. In five patients they found definite evidence of renal papillary necrosis on pyelography. Close reappraisal of the pyelograms performed on our patient, both prior to his left nephrectomy and during his subsequent episode of right-sided bleeding, has failed to reveal any similar evidence.

The tendency of the massive haematuria of sickle-cell trait to originate in the left kidney is remarkable. Harrow *et al.* (1963) suggest that the many tributaries of the left renal vein may lead to an elevated venous pressure on that side with resultant stagnation and sickling. Certainly there are marked differences in the pattern of venous drainage between the left and right kidneys, as emphasized by Erlik, Barzilai, and Shramek (1965), but the influence of these anatomical differences on the left renal venous pressure is undetermined.

The alteration in the haemoglobin molecule leading to sickle-cell formation may be provoked by a reduction in oxygen tension, a lowering of the pH, or an increase in osmolality. Many authors have attributed the massive haematuria in sickle-cell trait to a reduction in oxygen tension in the venous limb of the vasa recta with subsequent localized infarction.

However, Harrow *et al.* (1963) put forward the theory that the graded increase in osmolality from the base of the medulla to the tips of the pyramids resulting from the countercurrent mechanism of urinary concentration accounts for the distribution of the pathological changes at the papillae. It has been shown by Perillie and Epstein (1961) that the renal medulla is the only body structure in which osmolality is normally increased to four times the plasma level in both the interstitial and intravascular structures. Moreover, it has been shown that cells from the inner medulla of the kidney are able to gain their energy from anaerobic as well as aerobic processes. These cells are thus adapted to survival in a region where oxygen tension may become critical (Ullrich, Kramer, and Boylan, 1962).

Thus increased osmolality and low oxygen tension, both of which are factors favourable to sickle-cell formation, obtain in the renal medulla.

In view of the possibility of further bleeding from the opposite kidney, conservative measures should be adopted in the management of such patients. Immergut and Stevenson (1965) believe that bleeding from the necrotic areas in the papillae may be perpetuated by excessive fibrinolysis of the clot. They treated three patients with massive haematuria due to the sickle-cell trait with epsilon-amino-caproic-acid to inhibit this excessive fibrinolytic activity. In all three patients haematuria ceased within three to seven days of starting therapy, and in one patient in whom bleeding recurred one week later a second course of the drug was again effective. Certainly in our own case the correction of a "prothrombin" deficiency by the administration of vitamin K, the administration of epsilon-amino-caproic-acid, and blood transfusion were followed by a cessation of bleeding.

In a personal series of 27 cases presented by Lucas and Bullock (1960), 23 were managed conservatively. In 22 of these bleeding ceased with bed-rest alone. Nephrectomy was undertaken on four patients on account of recurrent and persistent haematuria. These authors consider that the indications for nephrectomy in this condition are continued severe haematuria, transfusion reactions, and strong suggestions of malignancy.

Dees (1965) favours renal pelvic tamponade as a means of controlling haematuria. Two of the patients whom he reports had sickle-cell disease, and their bleeding ceased when the ureter was completely obstructed for 24 to 48 hours by an indwelling tapered ureteral bougie. One of these patients had a recurrence of bleeding a week later. In view of the possible role of anoxia as a cause of this condition, he was placed in a hyperbaric oxygenation chamber at two-atmospheres pressure for one hour. Bleeding ceased within two hours.

It is felt that the diagnosis in our own case might have been made at an earlier stage had the haematologists and pathologists concerned known that the patient was an immigrant West Indian. In view of the large numbers of such patients present-

ing it is suggested that this fact should be recorded in the details sent by the clinician to the laboratory.

The severity of the haematuria in this condition makes it likely that such patients will be referred to surgeons. We therefore have no hesitation in advising that this diagnosis should be considered early in the investigation of massive haematuria in a susceptible patient.

We wish to thank Mr. G. H. Baines for permission to publish this report and Dr. J. D. Blainey for reading the manuscript.

Requests for reprints should be addressed to Mr. J. Meynell, Department of Clinical Pathology, General Hospital, Birmingham.

M. A. BENNETT, M.B., B.CH., B.A.O.,
Medical Registrar.

R. W. HESLOP, M.B., B.SC., F.R.C.S.,
Consultant Urological Surgeon, Hull and East Riding.

M. J. MEYNELL, M.D., B.SC., D.P.H., F.R.C.P., F.C.PATH.,
Consultant Clinical Pathologist.

Departments of Clinical Pathology and Urology,
The United Birmingham Hospitals.

REFERENCES

- Abel, M. S., and Brown, C. R. (1948). *J. Amer. med. Ass.*, **136**, 624.
Beard, M. J., and Signy, A. G. (1965). *Postgrad. med. J.*, **41**, 624.
Beck, J. S. P., and Hertz, C. S. (1935). *Amer. J. clin. Path.*, **5**, 325.
Bernstein, J., and Whitten, C. F. (1960). *Arch. Path.*, **70**, 407.
Dees, J. E. (1965). *J. Urol. (Baltimore)*, **93**, 136.
Dixon, G. (1962). *Proc. roy. Soc. Med.*, **55**, 763.
Erlik, D., Barzilai, A., and Shramek, A. (1965). *J. Urol. (Baltimore)*, **93**, 540.
Harrison, F. G., and Harrison, F. G. (1952). *Ibid.*, **68**, 943.
Harrow, B. R., Sloane, J. A., and Liebman, N. C. (1963). *New Engl. J. Med.*, **268**, 969.
Immergut, M. A., and Stevenson, T. (1965). *J. Urol. (Baltimore)*, **93**, 110.
Killingsworth, W. P., and Wallace, S. A. (1936). *Sth. med. J. (Bgham, Ala.)*, **29**, 941.
Lucas, W. M., and Bullock, W. H. (1960). *J. Urol. (Baltimore)*, **83**, 733.
Lund, H. G., Cordonnier, J. J., and Forbes, K. A. (1954). *Ibid.*, **71**, 151.
Mostofi, F. K., Bruegge, C. F. V., and Diggs, L. W. (1957). *Arch. Path.*, **63**, 336.
Perillie, P. E., and Epstein, F. H. (1961). *Clin. Res. Proc.*, **9**, 332.
Ulrich, K. J., Kramer, K., and Boylan, J. W. (1962). In *Renal Disease*, edited by D. A. K. Black, p. 49. Blackwell, Oxford.
Went, L. N. (1957). *Nature (Lond.)*, **180**, 1131.

Renal Potassium Wasting in Hypercalcaemia

Brit. med. J., 1967, **1**, 679-680

The adverse effects of hypercalcaemia on renal function are well known. Urea retention, accompanied by a failure to form concentrated urine, has been described in hypercalcaemia due to hyperparathyroidism (Cohen *et al.*, 1957), calciferol intoxication (Danowski *et al.*, 1945), sarcoidosis (Dent *et al.*, 1953), osteolytic bone metastases (Sanderson, 1959), and milk-alkali syndrome (Wenger *et al.*, 1957). Attention has also been drawn to an impaired renal excretion of acid and ammonia in hypercalcaemia (Fourman *et al.*, 1960; Ferris *et al.*, 1961). In addition, renal potassium wasting may occur, somewhat rarely, in such cases (Ferris *et al.*, 1961). This paper describes a case of hyperparathyroidism which was complicated by excessive renal potassium loss and severe hypokalaemia.

CASE REPORT

A man of 23 sustained a fracture of the left femoral shaft. He was admitted to hospital, and after reduction of the fracture an

intramedullary nail was inserted. The operation was followed by persistent vomiting. Nine days after admission he complained of pain at the fracture site and the leg was found to be shortened and externally rotated. X-ray examination showed disintegration of the bone at the fracture site and partial extrusion of the intramedullary nail. Metabolic bone disease was suspected and the serum calcium was found to be 14.9 mg./100 ml.

At this stage further questioning revealed the following additional symptoms: loss of weight (20 lb. (9 kg.) in nine months), increasing lassitude and fatigue for nine months, thirst and polyuria for six months, anorexia and occasional vomiting for six months, and vague

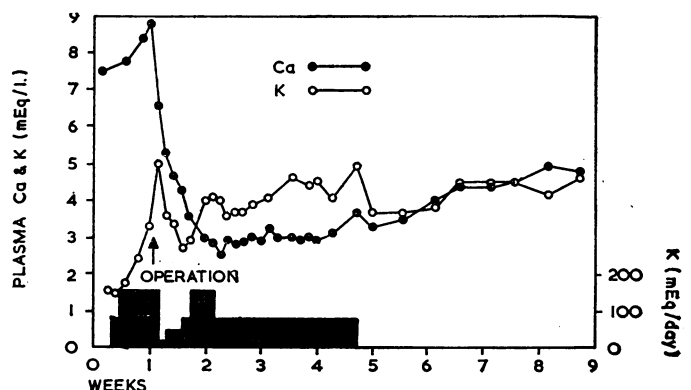


FIG. 1.—Plasma calcium and potassium levels. The shaded area indicates the amounts of potassium administered.