

Radiation-induced Peripheral Neuropathy*

BASIL A. STOLL,† F.F.R., D.M.R.D.&T., M.R.C.S.; JOHN T. ANDREWS,‡ M.R.A.C.P., M.C.R.A., D.OBST.R.C.O.G.

Brit. med. J., 1966, 1, 834-837

It has been thought that adult nervous tissues show a remarkable degree of resistance to injury by x rays. Clemedson and Nelson (1960), after a comprehensive review of the literature, state: "Nervous tissues, especially of adult animals, show a remarkable radio-resistance." In the past few years, however, experimental work on animals (Lander, 1959; Innes and Carsten, 1961) suggests that delayed degeneration of spinal nerves can follow doses of x rays which are near the clinical range. Clinically, also, peripheral nerves have in the past been regarded as relatively radio-resistant. Damage to nerves from the high dose in the vicinity of radium needles was, of course, a well-recognized complication of the Keynes technique for radium implantation of the axillary contents. However, with the use of kilovoltage x-ray therapy in the past, the skin tolerance was the limiting factor in dosage, and damage to peripheral nerves was rarely seen. More recently, however, with the development of megavoltage x-ray machines, peak dosage is below the skin and the risk of nerve damage is therefore increased. This report presents evidence of peripheral-nerve damage in a group of patients treated by megavoltage x-ray therapy after operation for carcinoma of the breast.

The incidence of neuropathy is expressed as a proportion of the total number of treated patients followed for a period of up to 30 months. However, it is realized that a proportion of patients who died within this period without developing symptoms might well have shown them had they survived.

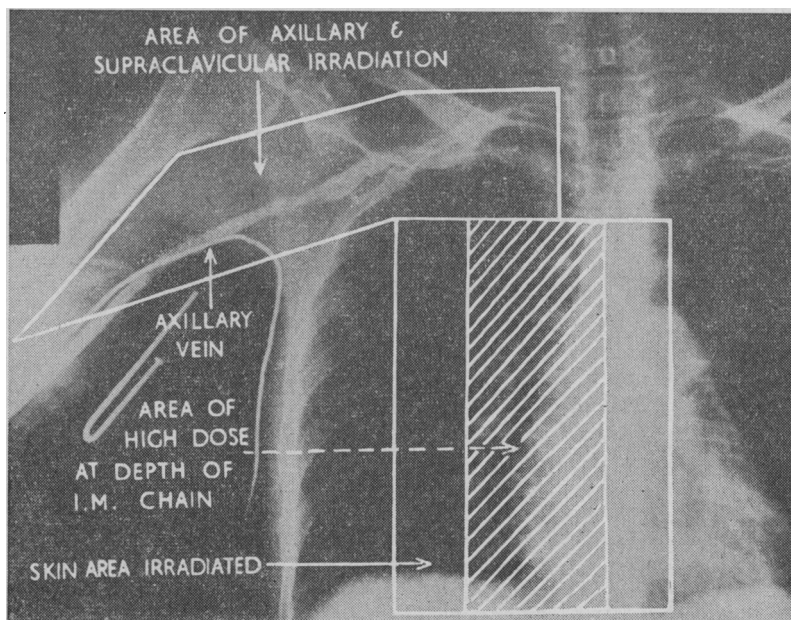


FIG. 1.—Venogram and superimposed planning of field for irradiation of supraclavicular-axillary chain of nodes. Also position of oblique fields for irradiation of internal mammary chain. (By courtesy of the publishers of *The Medical Journal of Australia*.)

Patient Material and Radiation Technique

The 117 female patients surveyed were a consecutive series treated during 1958-62 by an identical technique. Megavoltage x-ray therapy was given within a period of 3 to 10 weeks after radical mastectomy. Of the patients, 65% were aged 50 or less, and 70% had demonstrable metastases in the axillary nodes at operation.

They were treated by a 4 MeV linear accelerator to an irregularly shaped field (Fig. 1) measuring approximately 15 by 5 cm., to include the scalene, supraclavicular, and axillary node areas. The field of irradiation was based on the axillary-subclavian venogram, as described by Ackland, Holman, and Stoll (1960). The peak dose delivered to an anteriorly placed field was at two dose levels—6,300 rads in 12 increments in 25 to 26 days in 33 cases, and 5,775 rads in 11 or 12 increments in 25 to 28 days in 84 cases. Fig. 2 represents diagrammatically parts of the brachial plexus irradiated in our technique.

Assessment of Neurological Damage

Some of the patients subsequently complained of neurological symptoms in one hand or arm. Initial symptoms were not noted in our cases earlier than five months or later than 30 months after irradiation (Fig. 3).

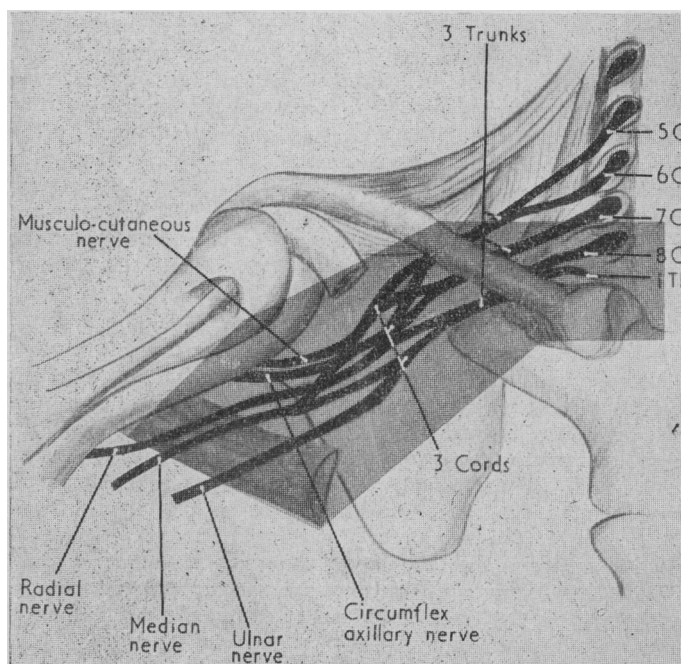


FIG. 2.—Diagrammatic representation of the parts of the brachial plexus irradiated in the technique shown in Fig. 1. Field area deliberately distorted to show relationship to brachial plexus.

* This paper was read by J. T. Andrews at the Annual General Meeting of the College of Radiologists of Australasia in Brisbane, Queensland, in October 1965.

† From the Peter MacCallum Clinic, Melbourne, Australia.

‡ From the Peter MacCallum Clinic, Melbourne, Australia. Now medical officer to the Radioisotope Unit, Royal Melbourne Hospital, Melbourne.

In the group receiving 6,300 rads neurological symptoms were complained of by 24 out of 33 patients (73%). In the group receiving 5,775 rads neurological symptoms were complained of by 13 out of 84 patients (15%). It is interesting to note (Fig. 3) that the higher-dose group tends to show initial symptoms somewhat earlier than the lower-dose group. All patients in these two groups with symptoms who survived after 1962 were questioned and examined neurologically, with special attention to the upper limbs and adjacent parts of the neck and thorax. Their symptoms, signs, and electromyographic findings were recorded separately, a special examination sheet being prepared by one of us (J. T. A.) for the purpose (Figs. 4 and 5). The overall nomenclature of grading was 1 for slight, 2 for moderate, and 3 for severe changes.

Of the patients receiving 6,300 rads 21 were available for neurological examination—17 had neurological symptoms and abnormal neurological signs, which were severe (grade 3) in six; two showed abnormal neurological signs only and did not complain of symptoms (grade 1); and two had neither symptoms nor signs. Of those receiving 5,775 rads 13 presented symptoms and abnormal neurological signs, which were severe in only one.

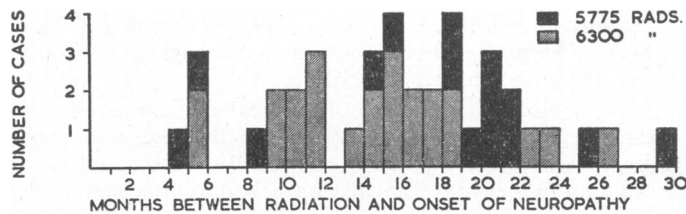


FIG. 3.—Latent time interval between irradiation and onset of neurological symptoms in 39 patients (follow-up minimum of 30 months). Two cases included in this figure are excluded from assessment in the text. They represent two cases of neuropathy developing among eight patients whose fractionation of treatment was incorrect.

The presenting symptom was paraesthesia in the fingers in most cases, but many also complained of hypoaesthesia, and a few of weakness of the hand or fingers in addition. On neurological examination, however, the signs were as often motor as

MOVEMENT	MUSCLES	NERVES AND SPINAL SEGMENT	EXAM.
Add. of arm	Pect. maj. and minor	Ant. thoracic	C ₅ -T ₂
Abd. of arm	Supraspinatus Deltoid	Suprascapular Axillary	C ₅ C ₅ -C ₆
Flexion of forearm	Biceps Coracobrachialis Brachialis Brachioradialis	Musculocutaneous " " Radial " "	C ₅ -C ₆ C ₇ C ₆ -C ₇ C ₅ -C ₆
Extension of forearm	Triceps	Radial	C ₇ -C ₈
Flexion of wrist	Flex. carpi radialis Palmaris longus Flex. carpi ulnaris	Median " " Ulnar	C ₆ -C ₇ -C ₈ C ₇ C ₇ -C ₈
Extension of wrist	External carpi radialis External carpi ulnaris	Radial " "	C ₆ -C ₇ C ₆ -C ₈
Abd. and Add. of fingers	Interossei	Ulnar	C ₈ -T ₁
Opp. of thumb	Opponens pollicis	Median	C ₈ T ₁
SPHYGMOMANOMETER TEST			

FIG. 5.—Standard table for examination of motor system.

sensory, and usually mixed sensory, motor, and reflex changes were elicited. The onset of symptoms or of motor weakness was quite sudden in a small proportion of cases.

No constant neurological pattern of damage emerged, but segments between C5 and D2 were involved in different cases, with some preference for the upper segments. The sensory loss was sometimes patchy with a dermatome. Nevertheless, contiguous dermatomes rather than dissociated ones tended to be involved.

In the more severe cases there were nearly always changes in sensation, muscular power, and reflex activity. Again there was no selective damage to either the upper or lower nerve-root segments, but damage that was patchy in distribution was often present. This was confirmed by the electromyographic recordings carried out in five of the cases.

In the milder cases complaining of paraesthesia the symptoms tended to improve spontaneously after six to nine months. Even in one of the most severe cases there was electromyographic evidence of partial recovery after a period of two years.

Pathology

Necropsies were performed on two of the patients with symptoms in this series. One of these had received irradiation within the higher-dose range and had developed severe symptoms and neurological signs. Death occurred 27 months after radiotherapy.

Macroscopically there was marked fibrosis surrounding the nerves of the brachial plexus. Microscopical examination after standard and myelin stains showed that, proximal to the fibrosis in the axilla, nerves sectioned retained normal myelinization. Within the area of fibrosis, however, nerves showed a varying degree of fibrous thickening of the

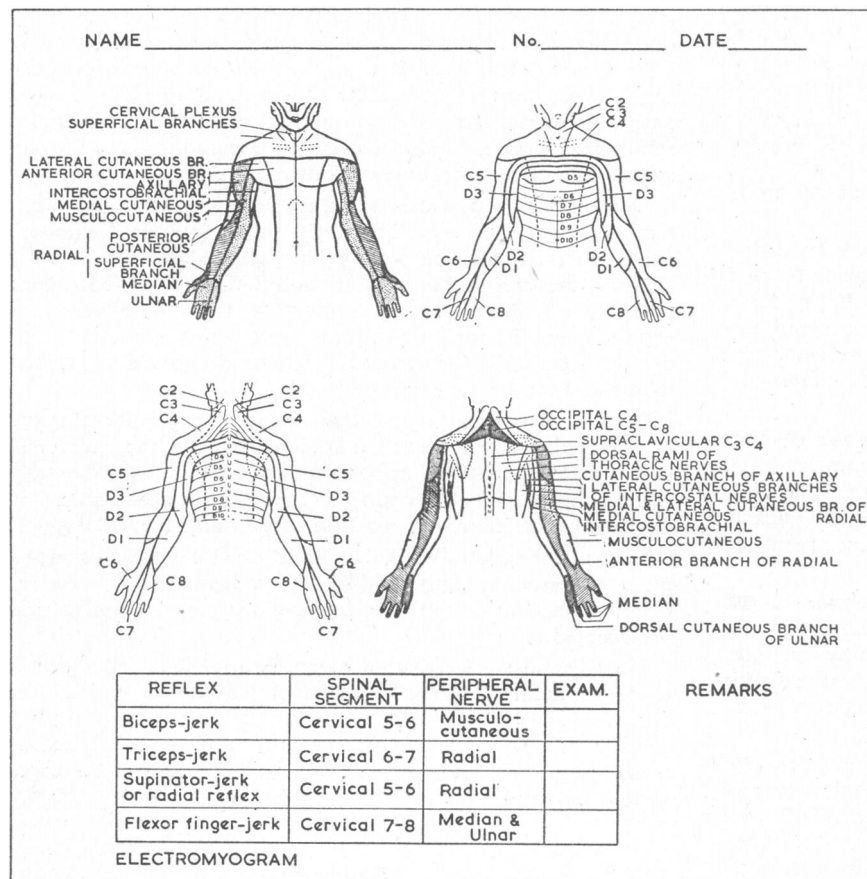


FIG. 4.—Standard diagram for examination of sensory system and reflexes. (Figs. 4 and 5 are modified from Victor Pauchet and S. Dupret's *Pocket Atlas of Anatomy* by courtesy of Oxford University Press.)

neurilemma sheath, demyelination, and fibrous replacement of some nerve fibrils. Distal to the fibrotic area the median nerve in the upper arm was sectioned, and this too showed extensive myelin loss, atrophy, and fibrous replacement of fibrils.

The other patient received irradiation in the lower-dose range and had minimal symptoms and signs. Death occurred 12 months after radiotherapy. In this case fibrosis was found at the anterior aspect of the brachial plexus, but the nerves were lying free. Sections taken from the cords of the plexus appeared normal histologically after standard and myelin staining, except for two small nerves immediately adjacent to the fibrosed anterior axillary wall. These showed some loss of myelin but minimal fibrosis.

For comparison, a necropsy was performed on a patient who had received irradiation in the lower-dose range and had no symptoms or signs. Death occurred 12 months after irradiation. In this case no fibrosis was visible either macroscopically or microscopically, and the nerves sectioned appeared to be normal.

Dose-time Considerations

In this series it should be noted that there were two different dose levels of radiation reported. If it be assumed that the affected portion of the brachial plexus lies at a depth of 2–4 cm. the higher dose of 6,300 rads peak delivers a minimum dose of 5,500 rads at the plexus. The lower dose of 5,775 rads peak delivers a minimum dose of 5,100 rads at the same depth. Both doses were given in 11 or 12 increments in 25 to 28 days. The incidence of neuropathy was 73% with the higher dose and 15% with the lower dose.

Information on the relationship between dose level and the incidence of neuropathy is available from two other series also. First, a group of 25 patients were treated by 4 MeV x rays to a large supraclavicular field (up to 22 by 13 cm.) to a peak dose of 4,650 to 5,550 rads in 18 to 20 days. With this dose level neuropathic symptoms were noted in 16% of patients. Assuming that the affected portion of the brachial plexus lies at a depth of 2–4 cm., then the minimum dose associated with neuropathy in this group was 4,100 in nine increments in 18 days.

Secondly, a group of 139 patients were treated by orthovoltage (200 kV, H.V.L. 1 mm. Cu) with small fields (4 by 6 cm.) to the apical axilla with a tumour dose of 4,300 to 5,300 rads in 25 to 28 days. In this series neuropathic symptoms were noted in 10% of cases. The minimum dose associated with neuropathy in this group was 4,350 rads in 10 increments in 25 days.

It is thus seen that an incidence of neuropathy on 10–20% of cases is noted for three dose levels—that is, minimum, 5,100 rads in four weeks with 4 MeV x rays; minimum, 4,100 rads in three weeks with 4 MeV x rays; minimum, 4,350 rads in four weeks with 200 kV x rays. In all groups increments of 400–500 rads were given three times weekly.

These dosage levels and increments lead to a substantial risk of delayed neuropathic symptoms even if minimal in the majority. It is also worthy of note that we have recorded similar symptoms occasionally even after quite modest radiation doses of the order of 3,500 to 3,700 rads in 20 increments in 25 to 27 days given by 200 kV x rays.

Limited data are available concerning the morphological changes which follow irradiation of the peripheral nerves of adult animals. For many years Janzen and Warren (1942) were quoted as reporting the absence of functional or structural changes in the sciatic nerve of the rat up to two months after doses of 4,000 to 10,000 r of 200 kV x rays. However, Linder (1959) irradiated the rat sciatic nerve to a dose of 3,000 r in five days and found focal nerve degeneration and scarring in

25% of cases when examined 3 to 11 months after irradiation. A later paper (Innes and Carsten, 1961) reports irradiation of the nerves of the cauda equina of rats with a dose of 3,500 rads (presumably as a single dose). After about seven months all the rats showed severe degenerative lesions of the spinal nerves. It is therefore suggested that the observations of Janzen and Warren were not sufficiently extended after irradiation to note a degenerative effect similar to that found by the later authors. When the latent period between radiation and first neurological symptoms is plotted in our cases (Fig. 3) it is interesting to note that the majority incidence is between 10 and 22 months.

Functional changes, however, appear in experimentally irradiated nerve at lower dose levels than do structural changes. Arnold *et al.* (1961) reports depressed conduction in the saphenous nerve of the cat soon after such moderate doses as 1,000 to 3,000 r of 250 kV x rays.

Relationship of Neuropathology to Other Causes

Moderate-to-severe oedema of the arm was noted in 40 out of the 117 patients (19 out of 33 patients receiving the higher dose; 21 out of 84 receiving the lower dose). This incidence is higher than that resulting from our previous technique, which delivers a tumour dose of 3,800 rads in 28 days by kilovoltage to the axilla and supraclavicular area.

The higher incidence of oedema undoubtedly reflects the greater degree of fibrosis resulting from the high-dose megavoltage technique. A common clinical finding was gross induration in the supraclavicular fossa, and in some cases forceful pressure on this area caused a painful sensation to radiate into the fingers.

Though the degree of clinical oedema was not often related to the degree of neuropathy, the possibility of relationship has been considered for several reasons. (1) According to Treves (1957), in an analysis of over 1,000 post-mastectomy cases the onset of oedema was at 11 to 23 months after mastectomy. This is remarkably similar to the peak incidence of post-irradiation neuritis in our series (10 to 22 months). (2) Several patients volunteered the information that their neurological symptoms improved when the oedema was reduced (by corticosteroid, diuretic, or pressure-cuff therapy).

Decompressive measures seem to have improved the symptoms in some cases. Three patients with predominantly median-nerve symptoms were greatly relieved after decompression of the carpal tunnel. In addition, two patients complaining of severe sensory symptoms were investigated by exposure of the brachial plexus above the clavicle. They derived some relief of symptoms from this procedure, though motor and sensory changes persisted.

These observations suggest that pressure on peripheral nerves by oedema may be an additional factor but not the basic cause of the neuropathy. The importance of oedema at the "entrapment points" along the course of the nerve in causing brachial neuropathy has been stressed (Thompson and Kopell, 1959).

It should be emphasized that in all these cases radiation was given to tissues recently subjected to radical surgery; the role of infections and sloughing in causing oedema and fibrosis must be accepted.

The diagnosis of radiation damage to the brachial plexus is made difficult by the differential diagnoses of cervical spondylosis (which is a common finding in this age group), pressure from metastatic supraclavicular nodes, and the carpal-tunnel syndrome. As noted previously, three cases had a carpal-tunnel decompression in this series.

Summary

Peripheral-nerve damage is reported in a series of patients treated post-operatively for breast carcinoma by a small-field,

high-dose megavoltage x-ray technique. The clinical nature of the damage has been assessed and an attempt made to establish the site of damage.

Of the patients receiving 6,300 rads peak dose in 25 to 26 days neurological symptoms were complained of by 73%, and of the group receiving 5,775 rads peak dose by 15%. In the higher-dose group the majority of patients with symptoms had abnormal neurological signs.

Pathological data in two cases are given and mention is made of factors other than radiation which may have contributed to the nerve damage noted. It is concluded that high-dose, small-field megavoltage irradiation following radical surgery leads to delayed damage to the brachial plexus, the incidence being related to the level of dosage. Our past experience with other techniques has been analysed for purposes of comparison.

We wish to thank Dr. P. Bladin, of St. Vincent's Hospital, Melbourne, for his co-operation in the electromyographic studies mentioned, and Dr. W. P. Holman, Medical Director, for his constant interest in the clarification of this problem.

REFERENCES

- Ackland, T. H., Holman, W. P., and Stoll, B. A. (1960). *Med. J. Aust.*, **1**, 793.
 Arnold, M. C., Harrison, F., and Bonte, F. J. (1961). *Radiology*, **77**, 264.
 Clemenson, C. J., and Nelson, A. (1960). In *Mechanisms in Radiobiology*, vol. 2, p. 144, edited by M. Errera and A. Forssberg. Academic Press, New York.
 Innes, J. R., and Carsten, A. (1961). *Brookhaven Symp. Biol.*, **14**, 200.
 Janzen, A. H., and Warren, S. (1942). *Radiology*, **38**, 333.
 Linder, R. (1959). *Fortschr. Röntgenstr.*, **90**, 617. Quoted by R. Bergström, *Acta radiol. (Stockh.)*, 1962, **58**, 301.
 Thompson, W. A. L., and Kopell, H. P. (1959). *New Engl. J. Med.*, **260**, 1261.
 Treves, N. (1957). *Cancer (Philad.)*, **10**, 444.

Significance of the Complement-fixation Test in Diagnosis of Amoebiasis in an Endemic Area

R. M. KASLIWAL,* M.D., F.R.C.P., F.N.I., F.A.M.S.; MICHAEL KENNEY,† M.D.; M. L. GUPTA,* M.D.
 J. P. SETHI,* M.D.; JOSEPH S. TATZ‡; CLARISE H. ILLES†

Brit. med. J., 1966, **1**, 837-838

Amoebiasis is a disease of world-wide distribution but is particularly prevalent in tropical countries such as India. The condition may be manifested by intestinal or extra-intestinal symptoms. In intestinal amoebiasis the basis on which diagnosis is made is the presence of *Entamoeba histolytica* in the stools. In extra-intestinal amoebiasis difficulties are encountered in making a definite diagnosis, since the stools show *E. histolytica* in only a small percentage of cases. The decision in such cases is based on the clinical picture, haematological examination, and radiological signs. The need for a reliable laboratory test has long been felt.

Craig (1927, 1929, 1930, 1933, 1937) and Craig and Scott (1935) recognized the value of the complement-fixation test in the diagnosis of amoebiasis. Since then a number of reports have been published (Meleney and Frye, 1937; Rees *et al.*, 1942; Ghosh *et al.*, 1948; Terry and Bozicevich, 1948; Hussey and Brown, 1950; Dolkart *et al.*, 1951; McDearman and Dunham, 1952). There has been wide variation in the observations made by various workers, mainly because of the different types of antigen used and the techniques employed. Furthermore, the reliability of a complement-fixation test for amoebiasis in hyperendemic areas, where it is needed most, has often been questioned because of strong anamnestic reactions resulting from repeated infection with *E. histolytica*.

Present Investigations

This study was undertaken to evaluate the significance of the complement-fixation test in both intestinal and hepatic amoebiasis in India by means of an antigen which had proved to be a reliable diagnostic tool in New York.

Material and Methods.—Complement-fixation tests for amoebiasis were carried out on cases of chronic intestinal

amoebiasis, hepatic amoebiasis, and controls, including normal individuals and patients with conditions other than amoebiasis.

The diagnosis of amoebic hepatitis was made on the finding of an enlarged tender liver, together with a history of blood and mucus in the stools, and either positive stool culture for *E. histolytica* or sigmoidoscopic evidence of typical amoebic ulcers.

All the cases were evaluated by a detailed clinical history, a complete physical examination, laboratory measures, including liver-function tests, and repeated stool examination. The complement-fixation test was performed with the Micro-Kolmer technique as described by Kenney (1952). The antigen was prepared by the New York Group, using the method described by Kenney (1952), and shipped to India in a lyophilized state.

Results

Among 45 cases of intestinal amoebiasis the complement-fixation test was positive in only 7 (15.5%) cases (Table I). All of them had *E. histolytica* cysts in the stools. One patient harboured *E. histolytica* trophozoites in addition, and a

TABLE I.—Results of Complement-fixation Tests

Clinical Diagnosis	No. of Cases	Positive C.F.T.	
		No.	%
Intestinal amoebiasis	45	7	15.5
Amoebic hepatitis	12	10	83.3
Amoebic abscess of liver	5	5	100.0
Normal controls (no evidence of any disease)	10	0	0

complement-fixation test was positive. All five cases of amoebic abscess of the liver had positive complement-fixation tests. In 10 (83%) of the 12 cases originally regarded as amoebic hepatitis the complement-fixation test was positive. None of the 10 normal controls without evidence of any disease had a positive complement-fixation test.

* Department of Medicine, S.M.S. Medical College, Jaipur, India.

† Laboratory Service, Veterans Administration Hospital, New York.

‡ Area Reference Laboratory, Veterans Administration Hospital, Bronx, N.Y.