

Case report

Open Access

Monochorionic-triamniotic triplet pregnancy after intracytoplasmic sperm injection, assisted hatching, and two-embryo transfer: first reported case following IVF

Labib M Ghulmiyyah¹, Mark Perloe², Michael J Tucker², Julie H Zimmermann³, Daniel P Eller⁴ and E Scott Sills*²

Address: ¹Department of Obstetrics and Gynecology, Atlanta Medical Center; Atlanta, Georgia USA, ²Georgia Reproductive Specialists LLC/ Division of Reproductive Endocrinology and Infertility, Department of Obstetrics and Gynecology, Atlanta Medical Center; Atlanta Medical Center; Atlanta, Georgia USA, ³Northside Women's Specialists; Atlanta, Georgia USA and ⁴Maternal-Fetal Specialists; Atlanta, Georgia USA

Email: Labib M Ghulmiyyah - labloub@hotmail.com; Mark Perloe - mpmd@ivf.com; Michael J Tucker - mtucker@ivf.com; Julie H Zimmermann - drjulez@aol.com; Daniel P Eller - dreller@bellsouth.net; E Scott Sills* - dr.sills@ivf.com

* Corresponding author

Published: 08 August 2003

Received: 05 July 2003

BMC Pregnancy and Childbirth 2003, 3:4

Accepted: 08 August 2003

This article is available from: <http://www.biomedcentral.com/1471-2393/3/4>

© 2003 Ghulmiyyah et al; licensee BioMed Central Ltd. This is an Open Access article: verbatim copying and redistribution of this article are permitted in all media for any purpose, provided this notice is preserved along with the article's original URL.

Abstract

Background: We present a case of monochorionic-triamniotic pregnancy that developed after embryo transfer following in vitro fertilization (IVF).

Methods: After controlled ovarian hyperstimulation and transvaginal retrieval of 22 metaphase II oocytes, fertilization was accomplished with intracytoplasmic sperm injection (ICSI). Assisted embryo hatching was performed, and two embryos were transferred *in utero*. One non-transferred blastocyst was cryopreserved.

Results: Fourteen days post-transfer, serum hCG level was 423 mIU/ml and subsequent transvaginal ultrasound revealed a single intrauterine gestational sac with three separate amnion compartments. Three distinct foci of cardiac motion were detected and the diagnosis was revised to monochorionic-triamniotic triplet pregnancy. Antenatal management included cerclage placement at 19 weeks gestation and hospital admission at 28 weeks gestation due to mild preeclampsia. Three viable female infants were delivered via cesarean at 30 5/7 weeks gestation.

Conclusions: The incidence of triplet delivery in humans is approximately 1:6400, and such pregnancies are classified as high-risk for reasons described in this report. We also outline an obstetric management strategy designed to optimize outcomes. The roles of IVF, ICSI, assisted embryo hatching and associated laboratory culture conditions on the subsequent development of monozygotic/monochorionic pregnancy remain controversial. As demonstrated here, even when two-embryo transfer is employed after IVF the statistical probability of monozygotic multiple gestation cannot be reduced to zero. We encourage discussion of this possibility during informed consent for the advanced reproductive technologies.

Background

Although the developmental mechanisms responsible for monozygotic multiple gestation are poorly characterized, some laboratory procedures altering the zona pellucida (e.g., ICSI and assisted embryo hatching) have been proposed as important. In this report, we describe the first known case of monochorionic-triamniotic triplets after IVF, an unusual physiological event requiring the sequence of two properly timed, distinct embryo splitting events.

Case Report

A 21 year-old Caucasian nulligravida presented with her partner for assessment and treatment of primary male factor infertility of 24 months duration. Both were in good general health and the female's past gynecological history was unremarkable. The wife smoked approximately 1/2 pack of cigarettes daily, and used alcohol only rarely. Her only regular medication was a prenatal vitamin. Physical exam revealed no abnormality; BMI was 20 kg/m². Her blood type was O positive. Cervical cytology and laboratory tests results were all normal, and saline hystero-graphy identified no intracavitary defects. The patient had never used ovulation induction agents or periovulatory hCG.

The partner was a non-smoker and took no regular medications. He had commissioned no pregnancies in a prior marriage, and had been diagnosed with azoospermia four years earlier. Urological evaluation found no anatomical abnormality. Karyotype was normal 46, XY and Y-chromosome microdeletion analysis via polymerase chain reaction method was negative for any known mutation. Obstructive azoospermia (rete testes obliteration) had been diagnosed after exploratory scrotal surgery four years before presentation. The couple declined intrauterine insemination with anonymous donor sperm for personal reasons. Given the male factor infertility diagnosis necessitating intracytoplasmic injection (ICSI), the couple elected in vitro fertilization utilizing surgically retrieved spermatozoa. Full informed consent was obtained, including a discussion of multiple gestation risk.

Following pituitary downregulation with intranasal nafarelin acetate (0.4 mg/d), controlled ovarian hyperstimulation commenced using a combined FSH+hMG protocol. Subcutaneous hCG was administered on stimulation day 11, when serum estradiol was 2110 pg/ml. Twenty-two oocytes were retrieved via ultrasound-guided transvaginal needle aspiration, undertaken in parallel with spermatozoa collection via testicular biopsy (both procedures performed under intravenous sedation). Utilizing ICSI, 10 oocytes advanced to the 2pn stage. Two embryos (8 and 9-cell stage) were transferred fresh on post-fertilization day three after assisted hatching via acid

Tyrode's method. One blastocyst was cryopreserved. Serum hCG was 423 mIU/ml two weeks after embryo transfer.

Transvaginal 4 mHz sonogram (SDU400+, Shimadzu Corp; Kyoto, Japan) performed at eight weeks' gestation demonstrated a single 28 mm intrauterine gestational sac (chorion) with three distinct fetal poles, each with discrete cardiac activity. Amniotic membrane configuration could not be immediately determined. Follow-up transvaginal ultrasound one week later refined the diagnosis as monochorionic-triamniotic triplet pregnancy (Figure 1). Total daily folic acid dose was increased to 1 mg/d, and antenatal care was co-managed with periodic perinatal consultation. The obstetrical course was uncomplicated until ~19th gestational week, when cervical funneling became evident via transvaginal sonogram. Based on this finding, the patient was admitted to hospital and a McDonald (rescue) cerclage was placed without difficulty. The post-operative course was uneventful and the patient was discharged home the next day.

At 28 weeks' gestation, the patient was readmitted to hospital for mild preeclampsia with a blood pressure of 140/80. To promote fetal lung maturity, betamethasone (12 mg × 2 doses) was administered via intramuscular injection. The patient had no focal neurological signs and ALT and AST were elevated (97 and 121 u/l, respectively). Liver function tests normalized soon after admission. Platelet count was 157,000 and protein (325 mg) was present in 24 h urine collection. Multifetal biophysical profiles were performed every 48 h with reassuring results. At 30^{5/7} weeks' gestation, serum uric acid was 7.8 mg/dl, platelets had fallen to 115,000, and the patient began to experience visual scotomata. Based on these findings consistent with worsening preeclampsia, the patient underwent a primary low-transverse cesarean delivery (estimated blood loss = 1,000 ml) resulting in the births of three viable female infants (1475, 1021, and 1021 g); one vertex and two breech presentations. Apgar scores were 8/9, 9/9, and 8/9, respectively. A single three-umbilical cord placenta (weight = 639 g) was delivered without complication, and each umbilical cord was morphologically normal. The patient was discharged home after seven days in good condition, and two of the triplets were discharged home three weeks later. The other infant was discharged home at eight weeks age due to necrotizing enterocolitis that required surgery for intestinal obstruction. At six months follow-up, mother and babies continue to do well.

Discussion

Monozygotic twinning is thought to occur in 0.42% of all deliveries [1]. Not surprisingly triplet pregnancy in general accounts for even fewer births (1:6400), and the monochorionic triplet subset may occur only once in 100,000

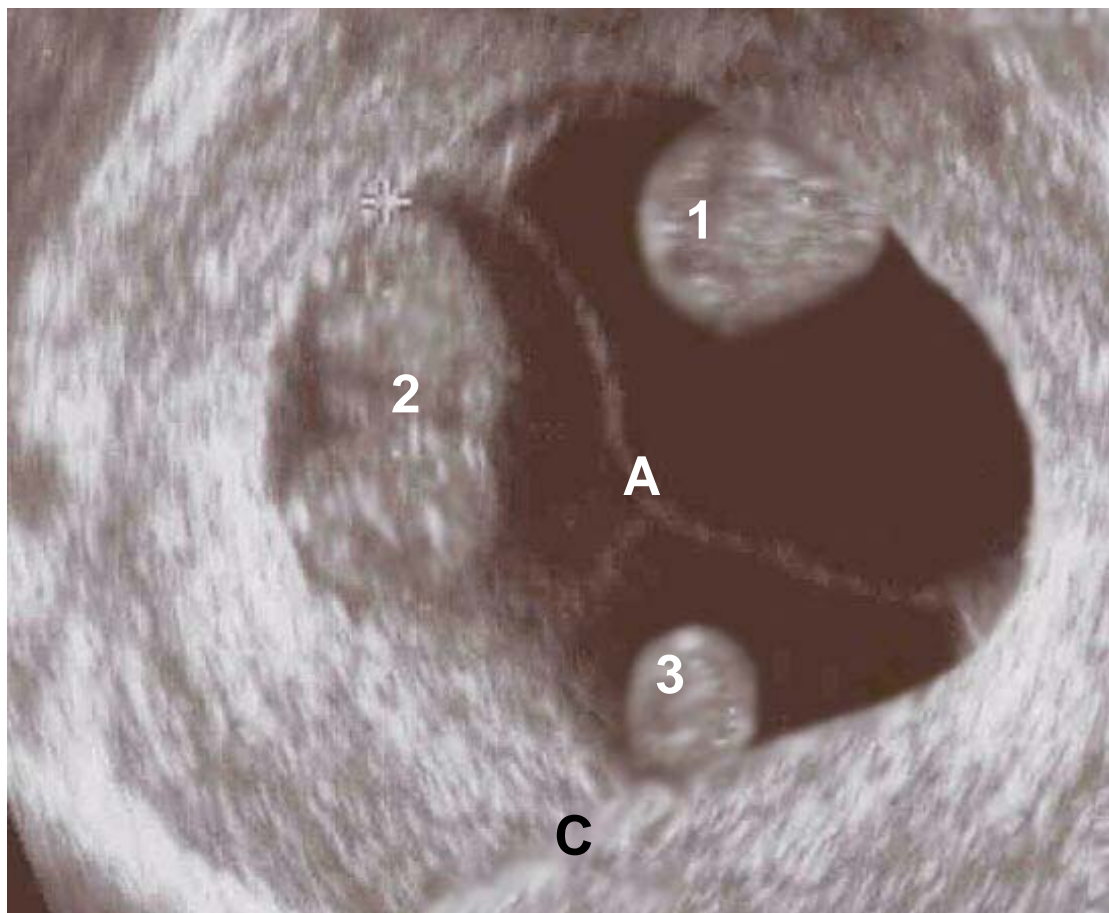


Figure 1

Transvaginal sonogram image of intrauterine monochorionic-triamniotic triplet pregnancy at 9 weeks' gestational age, demonstrating three separate embryos, distinct amniotic membranes (A), and unified chorion (C). The conception resulted from a two-embryo transfer following IVF+ICSI.

births. Monozygotic multiple gestations occur when a single fertilized ovum splits into genetically identical embryos (Figure 2). Exactly when this division occurs governs the configuration of chorion and amnion compartments, with later fission resulting in development of progressively greater shared tissue elements among conceptuses. While zygosity refers to the number of source zygotes comprising the gestational set (with profound life-long implications for a sibling cohort), the precise anatomical characterization of chorion and amnion for any multiple gestation is more important in intrapartum risk assessment and obstetrical management. Depending on time of embryo splitting, monozygotic multiplets may have separate chorions or placentas, yet monochorionic gestations must always develop in a monozygous context. Based on this relationship, the number of placentas corre-

lates with embryo number for multizygotic gestations, while monochorionic multiplets without mosaicism must be uniformly classified as monozygotic. Here we present the first known case of monochorionic-triamniotic triplets after IVF, a highly unusual occurrence necessitating a sequence of two properly timed, distinct embryo splitting events.

Previous investigators [2-4] have suggested at least three factors could modulate development of monozygotic multiple gestations in the setting of the advanced reproductive technologies: ovulation induction *per se*, certain IVF culture conditions, and zona pellucida architecture/micromanipulation. As these three variables commonly occur together, multiple regression analysis to quantify the individual contribution of each intervention has

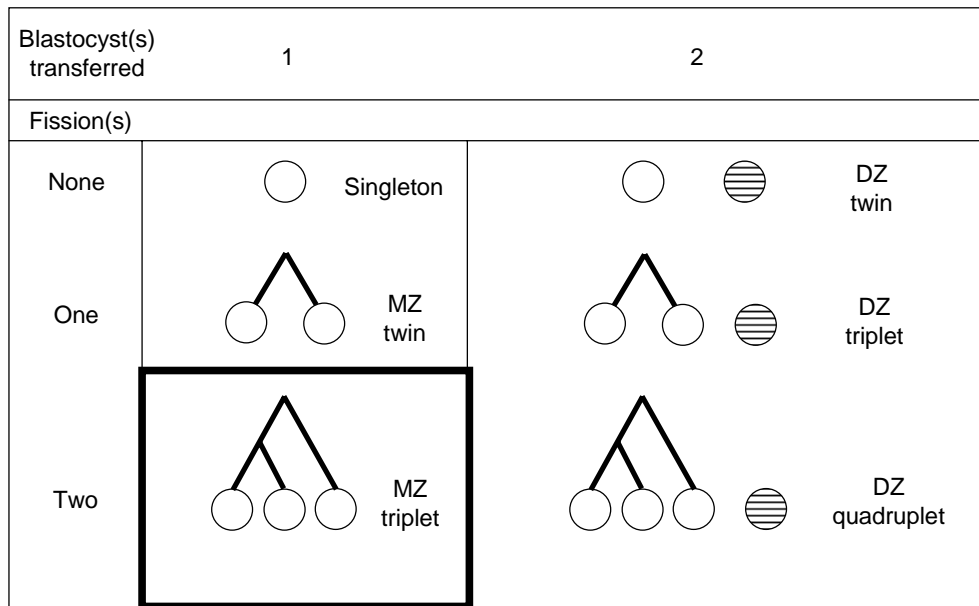


Figure 2
 Derom's developmental hypothesis (1987) of multiple births as a function of embryo fission (splitting) events and blastocyst implantation. Delivery outcomes assume 100% implantation. The incidence of human MZ triplets (black box) is estimated at 1:6400 deliveries. DZ = dizygotic MZ = monozygotic.

proven difficult. The potential impact of such iatrogenic influences on monozygotic gestations is reviewed elsewhere [5]. Whether or not spontaneous embryo splitting or duplication might occur as another mechanism by which monozygotic/monochorionic multiples develop remains controversial. Although rare, the *de novo* appearance of multiple inner-cell mass within a single embryo has been documented both in animals [6,7] and humans [8].

Intrapartum and neonatal challenges of triplet pregnancy include a higher risk of respiratory distress [9] and a known association between intratriplet birthweight discordance and overall neonatal mortality [10]. A recent Japanese study [11] revealed improved perinatal mortality rates among triplets over the interval 1980–1998, but

birthweight <2000 g persisted as a poor prognostic indicator of outcome throughout the study period. While the societal cost of multiple births has proven more difficult to study, previous work has shown depression and divorce rates to be higher among parents of multiple births compared to those who have only singleton deliveries [12,13].

Epidemiologists have rightly called attention to the problem of higher-order multiple births when a larger number of embryos are transferred [14], and some authors have suggested that a reduction in multiple gestations can only be obtained by transfer of one embryo after IVF [15]. However, this monozygotic/monochorionic triplet pregnancy occurred in the context of a single blastocyst

implantation after day three transfer of two embryos with IVF, a practice we regard as clinically conservative.

While the largest published series of monozygotic twin sets from one center found the frequency of monozygotic twinning not statistically different between zona manipulated and zona intact subgroups [8], summary research collected from multiple institutions (and embracing an even larger pooled sample) has offered a contrasting view [16]. Indeed, it must be acknowledged that our present report describes a triplet conception and delivery following both ICSI and assisted embryo hatching. Yet whether these zona manipulations were causative or merely associative interventions cannot be fully determined from available data. Further observational studies will be necessary to characterize more completely the physiology of monozygotic/monochorionic multiple pregnancy.

Conclusion

The exact mechanism of monozygotic multiple gestation is still poorly characterized. Procedures that modify the zona pellucida (e.g., ICSI and assisted embryo hatching) have been suggested as important in the monozygotic multiple gestation hypothesis, yet a definitive relationship between any clinical intervention during IVF and the subsequent development of multiple monozygotic gestation remains speculative. Nevertheless, even when the number of embryos transferred is limited, the potential for spontaneous embryo duplication escapes prediction. Accordingly, counseling should disclose such information during informed consent and offer a full opportunity to discuss number of embryos to transfer.

Competing interests

None declared.

Author contributions

LMG was resident physician associated with the case and drafted the manuscript. MP was chief medical attending. MJT was senior embryologist responsible for cell culture and assisted fertilization. JHZ was the lead obstetrician and primary surgeon at delivery. DPE was consulting perinatologist. ESS conceived of the research, directed the resident, and coordinated manuscript revisions.

Acknowledgements

Written consent was obtained from the patient for publication of this manuscript.

References

- Bulmer MG: **The Biology of Twinning in Man.** Clarendon Press, Oxford 1970.
- Edwards RG, Mettler L and Walters D: **Identical twins and in vitro fertilization.** *J In Vitro Fert Embryo Transfer* 1986, **3**:114-7.
- Derom C, Vleitnick R, Derom R, van den Bergh H and Thiery M: **Increased monozygotic twinning rate after ovulation induction.** *Lancet* 1987, **30**:1236-8.
- Alikani M, Noyes N, Cohen J and Rosenwaks Z: **Monozygotic twinning in the human is associated with the zona pellucida architecture.** *Hum Reprod* 1994, **9**:1318-21.
- Sills ES, Moomjy M, Zaninovic N, Veeck LL, McGee M, Palermo GD and Rosenwaks Z: **Human zona pellucida micromanipulation and monozygotic twinning frequency after IVF.** *Hum Reprod* 2000, **15**:890-5.
- Chida S: **Monozygous double inner cell masses in mouse blastocysts following fertilization in vitro and in vivo.** *J In Vitro Fert Embryo Transf* 1990, **7**:177-9.
- Ozdzenski W, Szczesny E and Tarkowski AK: **Postimplantation development of mouse blastocysts with two separate inner cell masses.** *Arch Gynecol Obstet* 1997, **195**:467-71.
- Sills ES, Tucker MJ and Palermo GD: **Assisted reproductive technologies and monozygous twins: implications for future study and clinical practice.** *Twin Res* 2000, **3**:217-23.
- Shinwell ES, Blickstein I, Lusky A and Reichman B: **Excess risk of mortality in very low birthweight triplets: a national, population based study.** *Arch Dis Child Fetal Neonatal Ed* 2003, **88**:F36-40.
- Jacobs AR, Demissie K, Jain NJ and Kinzler WL: **Birth weight discordance and adverse fetal and neonatal outcome among triplets in the United States.** *Obstet Gynecol* 2003, **101**(5 pt 1):909-14.
- Imaizumi Y: **Perinatal mortality in triplet births in Japan: time trends and factors influencing mortality.** *Twin Res* 2003, **6**:1-6.
- Nielsen J: **Parents of twins have a specifically higher divorce rate.** *Sygeplejersken* 1986, **86**:21.
- Garel M, Salobir C and Blondel B: **Psychological consequences of having triplets: a 4-year follow-up study.** *Fertil Steril* 1997, **67**:1162-5.
- Schieve LA, Peterson HB, Meikles SF, Jeng G, Danel I, Burnett NM and Wilcox LS: **Live-birth rate and multiple-birth rate risk using in vitro fertilization.** *JAMA* 1999, **282**:1832-8.
- De Neubourg D, Gerris J, Van Royen E, Mangelschots K and Valkenburg M: **Prevention of twin pregnancy after IVF/ICSI using embryo transfer.** *Verh K Acad Geneesk Belg* 2002, **64**:361-70.
- Schieve LA, Miekles SF, Peterson HB, Jeng G, Burnett NM and Wilcox LS: **Does assisted hatching pose a risk for monozygotic twinning in pregnancies conceived through in vitro fertilization?** *Fertil Steril* 2000, **74**:288-94.

Pre-publication history

The pre-publication history for this paper can be accessed here:

<http://www.biomedcentral.com/1471-2393/3/4/prepub>

Publish with **BioMed Central** and every scientist can read your work free of charge

"BioMed Central will be the most significant development for disseminating the results of biomedical research in our lifetime."

Sir Paul Nurse, Cancer Research UK

Your research papers will be:

- available free of charge to the entire biomedical community
- peer reviewed and published immediately upon acceptance
- cited in PubMed and archived on PubMed Central
- yours — you keep the copyright

Submit your manuscript here:
http://www.biomedcentral.com/info/publishing_adv.asp

