

CASE REPORT

The E Syndrome (Trisomy 17-18) Resulting from a Maternal Chromosomal Translocation

HUGH R. BRODIE, B.Sc., M.D., C.M.* and
LOUIS DALLAIRE, B.A., M.D.,† *Montreal*

THE clinical picture associated with trisomy for an "E" chromosome (the "E" group comprises chromosomes number 16, 17 and 18), as described by Patau *et al.*³ in 1961, includes apparent mental retardation, hypertonicity, flexion of fingers, low-set and malformed ears, small mandible, failure to thrive, dorsiflexion of the great toes, patent ductus arteriosus, interventricular septal defect and inguinal and/or umbilical hernia. So far, all such cases reported have shown simple trisomy with no other demonstrable chromosomal aberration, and the patients have died in the first few months of life. This report describes a patient who, because of the clinical findings, was suspected to be trisomic for an E chromosome, and was, in fact, found to have an excess of chromosomal material interpreted as resulting from translocation of part of a chromosome from the 17-18 (E) group to one of the 13-15 (D) group. The cells of the mother also had the translocation, and lacked one chromosome of the 17-18 group.

A male infant was born on October 17, 1961, at the Catherine Booth Hospital, Montreal, following a 40-week gestation. The weight at birth was 1650 g. The mother was 20 years old and had been in good health throughout the pregnancy. Her first pregnancy in 1960 aborted spontaneously at three months. Physical examination of the mother revealed no abnormalities and her history was not remarkable otherwise. The father was 23 years old and was unrelated to the mother. A maternal aunt was said to be a mongoloid imbecile.

Several unusual features were noted shortly after the birth of this infant. He had peculiar birdlike facies with a prominent nose, hypertelorism, micrognathia, high-arched palate, low-set ears and webbing of the neck. The first toes were both relatively short and small, with a bulbous terminal phalanx, and were somewhat dorsiflexed. The pulse rate was 160 per minute and the respiratory rate 60 per minute. A grade 2 harsh systolic murmur was heard along the left sternal border. The patient was maintained in an isolette with an oxygen flow rate of 6 l. per minute. A reduction in this flow rate or the removal of the infant from the isolette resulted in severe cyanosis within 15 to 30 seconds. The infant was transferred to The Montreal Children's Hospital on October 31, 1961.

The hemoglobin value, white blood cell count and differential cell count were within normal limits throughout the period of hospitalization. The urinary findings were normal until November 27, 1961, when a mass became palpable in the region of the left kidney, and at the same time red and white blood cells were seen in a voided urine specimen. Culture of this urine revealed a moderate growth of *Aerobacter aerogenes*, sensitive *in vitro* to chloramphenicol. Treatment with this drug was followed by a return to normal in the microscopic appearance of the urine. The electrocardiogram suggested combined ventricular hypertrophy, and a low P-R segment was noted. Radiographs of the chest revealed findings consistent with severe congenital heart disease, a probable left-to-right shunt, and pulmonary congestion. Radiographs of the skull demonstrated that the mandible was smaller than normal, the forehead appeared flattened and the right parietal area appeared larger than the left. Ophthalmological examination was normal. The infant was extremely ill throughout its hospital stay, and although there was a slight gain in weight (2250 g. at the time of death), the clinical condition deteriorated steadily and the infant died on December 4, 1961.

At autopsy, the heart revealed a large basilar ventricular septal defect without overriding of the aorta, a bicuspid, slightly stenotic aortic valve, and an abnormally patent (5 mm.) ductus arteriosus. A complete double ureter from the right kidney was noted, with stenosis of both ducts distal to the ureteropelvic junction and a ureterocele of the bladder associated with the upper ureter on the right side. The left kidney showed a single ureter with stenosis distal to the ureteropelvic junction. Both kidneys showed minimal hydronephrosis. The dermatoglyphic patterns unfortunately were not examined. No chromatin masses were seen in a buccal smear preparation.

CYTOLOGICAL FINDINGS

Blood was drawn from the patient for chromosomal analysis 24 days after birth, and the technique described by Moorhead *et al.*² was followed, with minor modifications. The cells were stained in 1% aceto-orcein. Fifty-nine cells were analyzed under the microscope, and 10 karyotypes were prepared from photographs (Fig. 1). Forty-seven cells had 46 chromosomes. One member of the 13-15 group was missing, and there was an unusually long acrocentric chromosome on which satellites could sometimes be seen on the short arm. The latter chromosome is interpreted as being a member of the 13-15 group with an addition to the long arm. The relative lengths of all the other chromo-

*Department of Pediatrics, McGill University, and the Department of Pediatric Medicine, The Montreal Children's Hospital, Montreal.

†Department of Genetics, McGill University, and the Department of Medical Genetics, The Montreal Children's Hospital, Montreal. Holder of a Fellowship from the Canadian Paediatric Society's Mead Johnson Educational Fund.

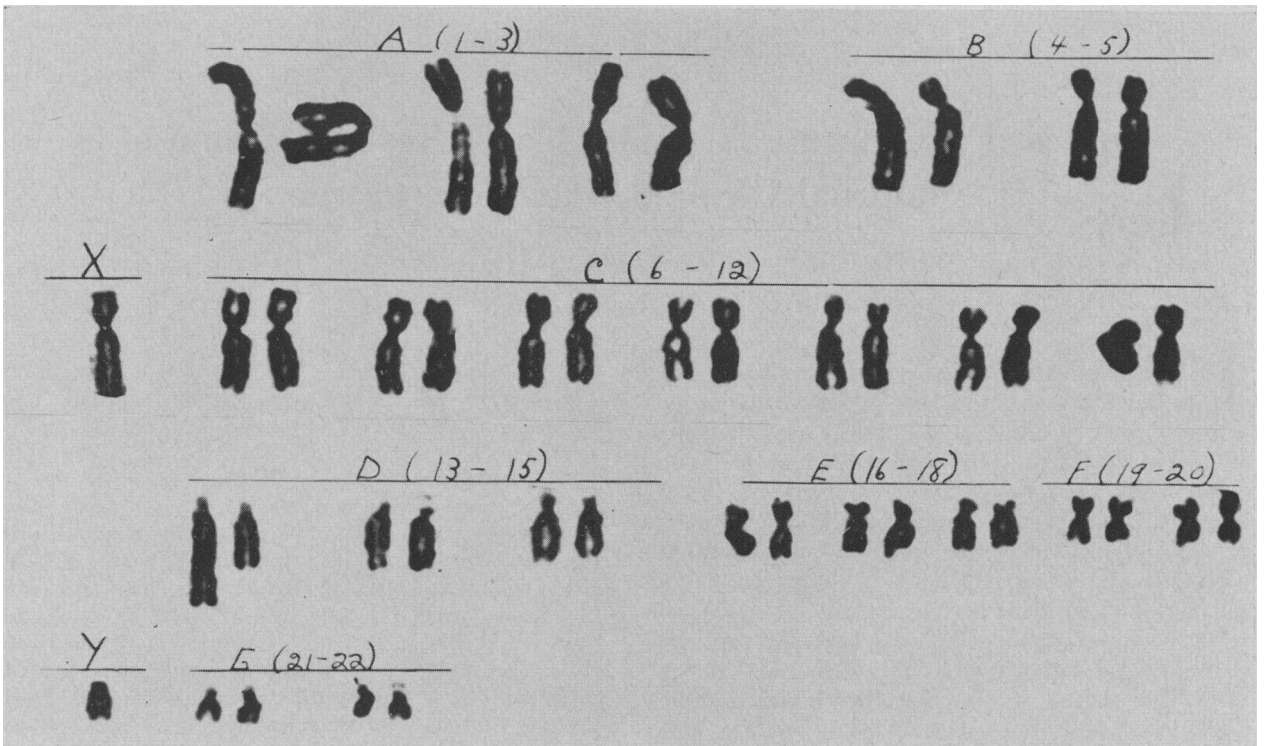


Fig. 1.—Karyotype of the child, illustrating 46 chromosomes including a long chromosome in group D (13-15). (X 1500 approx.)

somes appeared normal. Six cells had 47 chromosomes, the extra chromosome being apparently acentric, and similar in size to the 21-22 group.

The chromosomes of the parents were examined three months later (Table I). The father had a normal male karyotype, 44XY. The mother had the unusually long chromosome, like that of the patient, in all 50 cells examined. In 43 of her cells there were only 45 chromosomes, with one member

TABLE I.—CHROMOSOME NUMBERS IN PERIPHERAL LEUKOCYTE CULTURES FROM THE PATIENT AND HIS PARENTS

Number of chromosomes	44	45	46	47	48	Poly-ploid	Total
Child.....	1	3	48	6	1	0	59
Mother.....	4	43	1	0	0	2	50
Father.....	6	2	24	2	0	0	34

of the 17-18 group missing (Fig. 2). In almost all of these (40) a fragment (not counted here as a

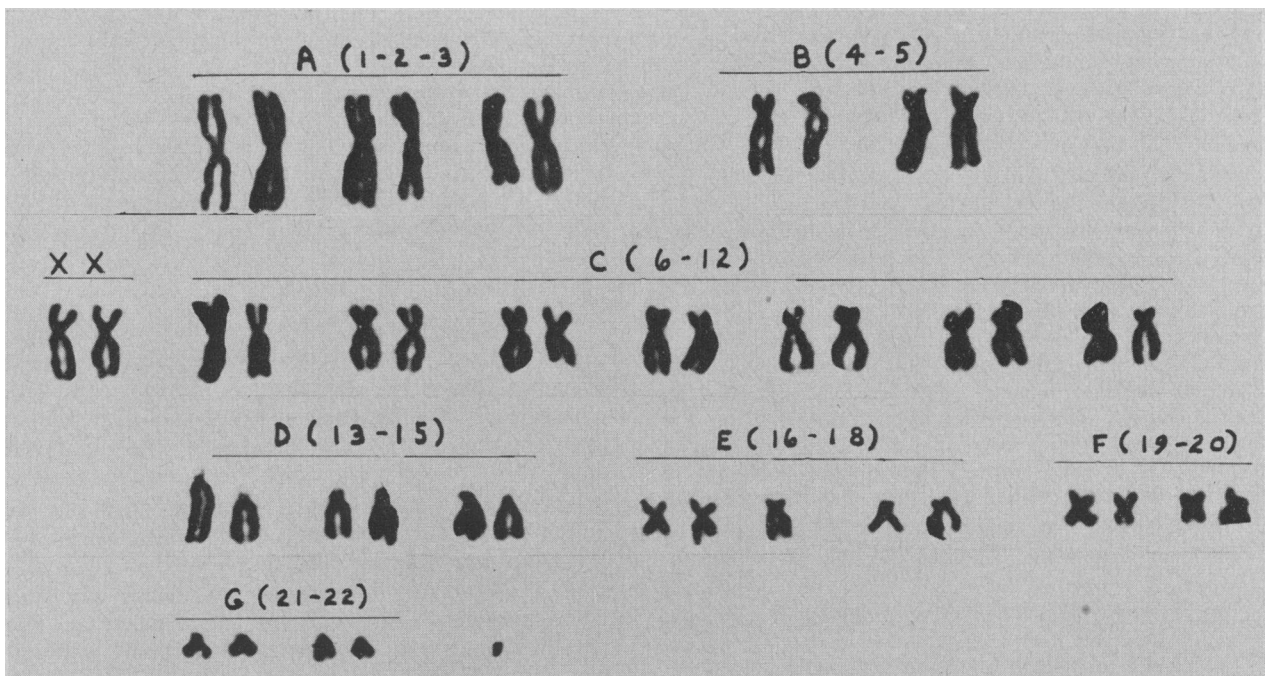


Fig. 2.—Karyotype of the mother, illustrating the long chromosome in Group D (13-15), a missing member of Group E (17-18), and a fragment. (X 1500 approx.)

chromosome), much smaller than a group 21-22 chromosome, was also present.

The unusually long chromosome was interpreted to be the result of a reciprocal translocation between a chromosome of the 13-15 (D) group and one of the 17-18 (E) group. The chromosome fragment in the mother is presumably the short arm of an E chromosome left behind after the transfer of most or all of its long arm to the long arm of a chromosome of the 13-15 (D) group. Presence of the fragment in most, but not all, of the mother's cells suggests that the translocation occurred early in her developmental history. The origin of the fragment seen in the child remains uncertain. Chromosomal studies of the rest of the family are in progress.

It would seem, therefore, that the E syndrome, like mongolism,¹ may occur either as the result of simple non-disjunction, with a low risk of recurrence in sibs of the affected individual, or as the result of a reciprocal translocation, presumably with a relatively high risk of recurrence in sibs.

SUMMARY

A case is presented of a child with the E syndrome, associated with partial trisomy for an E chromosome, resulting from a translocation of most of the long arm of an E chromosome to a D chromosome. The translocation is also present in the clinically normal mother.

ADDENDUM

Since submission of this manuscript, similar blood studies were carried out on both maternal grandparents. No abnormalities were noted in the chromosomes of either of these.

Financial support was provided by the Medical Research Council of Canada. We acknowledge with thanks permission from Dr. F. W. Wigglesworth, Director of the Department of Pathology, The Montreal Children's Hospital, to abstract the autopsy protocol; the technical assistance of Miss Joyce Morrell; and the helpful advice of Professors J. W. Boyes and F. C. Fraser.

REFERENCES

1. HAMERTON, J. L. *et al.*: *Lancet*, 2: 956, 1961.
2. MOORHEAD, P. S. *et al.*: *Exp. Cell Res.*, 20: 613, 1960.
3. PATAU, K. *et al.*: *Chromosoma*, 12: 280, 1961.

Pernicious Anemia in a 19-Year-Old Girl

H. BIRNBOIM, M.D.,* *St. Boniface, Man.*

WELL-documented cases of classical (Addisonian) pernicious anemia occurring in children and young adults are uncommon. Lambert *et al.*,² in a review of the literature up to 1960, found only seven cases, to which they added two cases of their own. In their review they excluded cases in which they felt that the diagnosis was not substantiated by modern methods, primarily the Schilling test. The condition most often confused with pernicious anemia and improperly excluded in the differential diagnosis was a low-grade or latent malabsorption syndrome; this view is shared by other authors.³ Of the patients reviewed by Lambert *et al.*, three had slight mental retardation and two had abnormal tendon reflexes.

Perillie and Nagler⁶ described a case of pernicious anemia in a 26-year-old man, proved on the basis of peripheral blood and bone marrow findings and the presence of achylia gastrica, and confirmed by gastroscopy, biopsy, gastric pH and decreased blood pepsin levels. The Schilling test and response to vitamin B₁₂ were confirmatory.

Three cases of pernicious anemia in Bantu women, aged 23, 28 and 34 years, have been described by Metz.⁴ The diagnosis was made in a population where other types of megaloblastic anemia occur more commonly. Confirmation rested

upon peripheral blood and bone marrow findings, serum vitamin B₁₂, Schilling test and fat balance studies, as well as on the response to the parenteral administration of vitamin B₁₂. The incidence of the disease in persons under the age of 30 years is cited as being 2.8% in a series of 1600 cases of pernicious anemia⁷ and 1.2% in another series of 329 cases.⁸

Clement¹ described studies of a 4-year-old boy with pernicious anemia who showed no signs of nervous system involvement. Morse⁵ described three cases of familial hypoparathyroidism, one of whom, an 18-year-old girl, had associated pernicious anemia with a uropepsin excretion level of 25 units per day, the normal level being 100 units per day.

The present case concerns a 19-year-old girl on whom hospital records of her birth and several subsequent admissions were available. Information about her family was obtained through hospital records of six members of her family who had been in attendance at the St. Boniface Hospital and from a partial investigation of her mother.

A 19-year-old French Canadian girl was admitted to hospital on October 3, 1961. The patient was grossly retarded mentally and was unable to walk. The history was obtained from the mother of the patient (herself rather dull) and corroborated by older siblings on another occasion.

*Junior Assistant Resident, Department of Medicine, St. Boniface Hospital, St. Boniface, Man.