

Case report

Open Access

Coronary artery-pulmonary artery fistula: case report

Ilaria Quatrini, Valerio Zacà* and Sergio Mondillo

Address: Department of Cardiology, University of Siena, Siena, Italy

Email: Ilaria Quatrini - ilaquatrini@virgilio.it; Valerio Zacà* - valezeta@libero.it; Sergio Mondillo - mondillo@unisi.it

* Corresponding author

Published: 11 April 2007

Received: 2 April 2007

Cardiovascular Ultrasound 2007, **5**:19 doi:10.1186/1476-7120-5-19

Accepted: 11 April 2007

This article is available from: <http://www.cardiovascularultrasound.com/content/5/1/19>

© 2007 Quatrini et al; licensee BioMed Central Ltd.

This is an Open Access article distributed under the terms of the Creative Commons Attribution License (<http://creativecommons.org/licenses/by/2.0>), which permits unrestricted use, distribution, and reproduction in any medium, provided the original work is properly cited.

Abstract

Background: Coronary artery fistulas are rare congenital or acquired coronary artery anomalies that can originate from any of the three major coronary arteries and drain in all the cardiac chambers and great vessels.

Case presentation: An 11-year-old boy was referred for evaluation of an exertional dyspnoea. He reported recent history of few episodes of shortness of breath associated with moderate intensity physical activity. At physical examination a mild continuous murmur could be heard mainly at the level of the second intercostal space of the left parasternal area. A transthoracic echocardiogram showed a continuous flow at color Doppler analysis in the high parasternal short axis view, originating from a small entry site on the wall of the main pulmonary artery. A selective left coronary angiography revealed a fistula connecting the proximal portion of the left anterior descending coronary artery with the main pulmonary artery.

Conclusion: A combination like the one described in the present case is unusual since fistulas originate from the left coronary artery in about 35% of cases and drainage into the pulmonary artery occurs in only 17%.

Background

Coronary artery fistulas are rare congenital or acquired coronary artery anomalies that can originate from any of the three major coronary arteries and drain in all the cardiac chambers and great vessels [1,2].

Case presentation

An 11-year-old boy was referred for evaluation of an exertional dyspnoea. He reported recent history of few episodes of shortness of breath associated with moderate intensity physical activity. At physical examination a mild continuous murmur could be heard mainly at the level of the second intercostal space of the left parasternal area. A transthoracic echocardiogram (Figure 1A) showed a continuous flow at color Doppler analysis in the high par-

asternal short axis view, originating from a small entry site on the wall of the main pulmonary artery (arrow). A selective left coronary angiography (Figure 1B) revealed a fistula connecting the proximal portion of the left anterior descending coronary artery (solid white arrow) with the main pulmonary artery (blank white arrow); black arrows indicated drainage into the pulmonary circulation.

Conclusion

Most fistulas originate from the right coronary artery or the left anterior descending and commonly drain in low-pressure structures including right-sided chambers, pulmonary artery, superior cava vein and coronary sinus [1,2]. A combination like the one described in the present case is unusual since fistulas originate from the left coro-

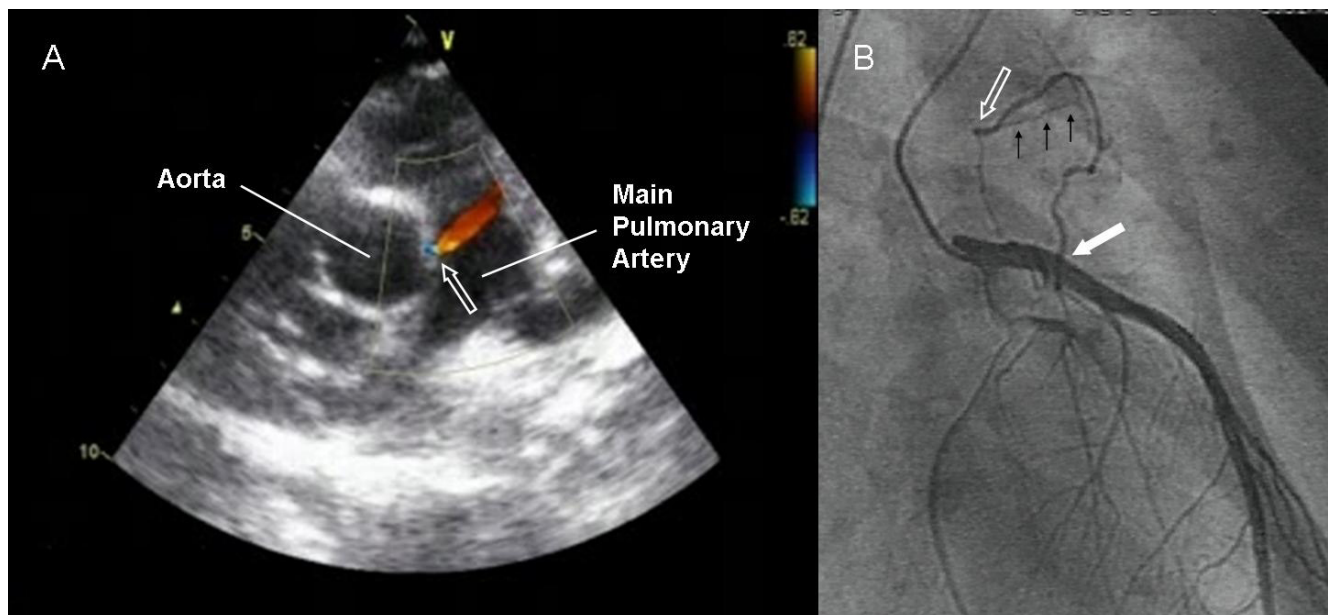


Figure 1

nary artery in about 35% of cases and drainage into the pulmonary artery occurs in only 17% [1,2].

Competing interests

The author(s) declare that they have no competing interests.

Authors' contributions

IQ collected the data relative to the Case Report; VZ composed the draft of the manuscript; SM is head of the Echo Lab and conceived the Case report and participated in the coordination, data analysis and elaboration and drafting of the manuscript. All authors read and approved the final manuscript.

Acknowledgements

Written consent was obtained from the patient for publication of the study.

References

1. Levin DC, Fellows KE, Abrams HL: **Hemodynamically significant primary anomalies of the coronary arteries: angiographic aspects.** *Circulation* 1978, **58**:25-34.
2. Gowda RM, Vasavada BC, Khan IA: **Coronary artery fistulas: clinical and therapeutic considerations.** *Int J Cardiol* 2006, **107**:7-10.

Publish with **BioMed Central** and every scientist can read your work free of charge

"BioMed Central will be the most significant development for disseminating the results of biomedical research in our lifetime."

Sir Paul Nurse, Cancer Research UK

Your research papers will be:

- available free of charge to the entire biomedical community
- peer reviewed and published immediately upon acceptance
- cited in PubMed and archived on PubMed Central
- yours — you keep the copyright

Submit your manuscript here:
http://www.biomedcentral.com/info/publishing_adv.asp

