



Dr. Abraham Ganel



Dr. Z. Aharonson



Dr. J. Engel

**"GAMEKEEPER'S THUMB"
INJURIES OF THE ULNAR COLLATERAL LIGAMENT OF THE METACARPOPHALANGEAL JOINT**

A. GANEL, MD, Z. AHARONSON, MD, J. ENGEL, MD

*Department of Orthopaedic Surgery A, Hand Surgery Unit, the Chaim Sheba Medical Center,
affiliated to the
Tel-Aviv University Sackler School of Medicine, Tel-Hashomer, Israel.*

The condition of chronic instability of the MP (metacarpophalangeal) joint of the thumb, may be the resultant of chronic strain of the ulnar collateral ligament of the MP joint. This condition was described in Scottish gamekeepers who used to kill hunted animals by a special manoeuvre subjecting the thumb to extension abduction force, and was termed "Gamekeeper's Thumb" (Campbell, 1955). Nowadays, such a chronic strain has been replaced by relatively frequent acute strains and tears subjected to the thumb during sport activities. The MP joint of the thumb, being a vulnerable one, is subjected to trauma on falling down with arms extended, during hand ball or volley-ball games, when the ball hits the distal end of thumb and subjects it to hyper-extension and hyper-abduction movement (Fig. 1), and in skiing. Injury to the base of the thumb is probably the most common ski injury of the upper extremity (Gutman et al 1974). The ski pole is held by the handle and the strap around the wrist prevents losing the stick while standing or skiing. However, when the ski-pole is relatively fixed to the ground and the skier falls, the deceleration impact takes place over the MP joint of the thumb and subjects the latter to forced abduction (Browne et al, 1976).

ILLUSTRATIVE CASE HISTORIES

Case I: A 19 year old football player sustained direct blow to his right thumb, while playing. Massive swelling developed at the base of the thumb and was associated with pain and limitation of movements. Radiographs revealed undisplaced fracture of the ulnar side of the proximal phalanx. Immobilization in plaster cast for one month was followed by physiotherapy. However, disability in holding objects developed, and instability of the metacarpo-phalangeal joint of the thumb was noticed. Arthrography performed more than two months following the initial trauma demonstrated leakage of contrast material along the adductor pollicis muscle, suggesting tear of the ulnar collateral ligament. At operation re-attachment of the avulsed ulnar collateral ligament was performed. Following plaster cast immobilization for four more weeks physiotherapy was started. At 3 months follow-up the patient had a stable joint, with 10° of limitation of extension. The patient was discharged from further follow-up and returned to full sport activities.

Case II: A 21 year old soldier was involved in a quarrel

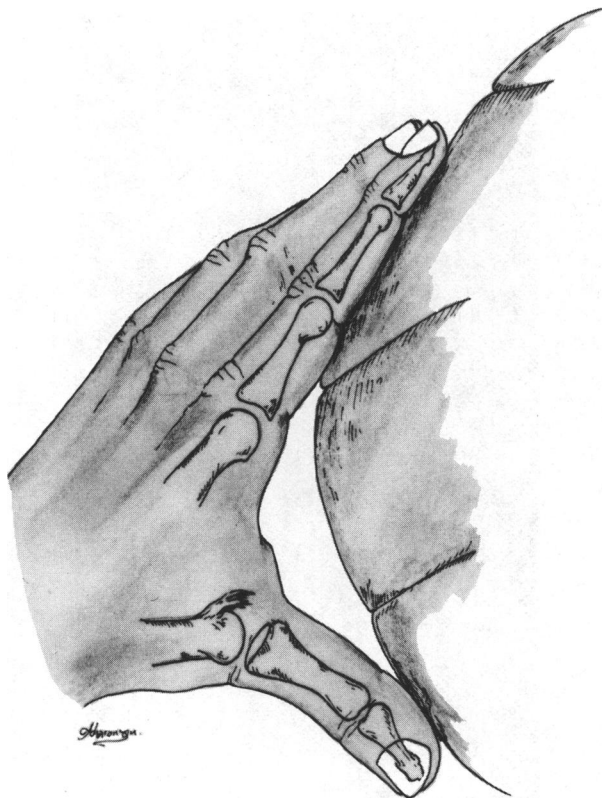

Fig. 1: A ball impact on abducted thumb, causing hyperabduction and hyperextension at the M-P joint of the thumb, with resultant tear of the ulnar collateral ligament.

during which his thumb was forcefully abducted. Plain radiographs were normal and initial treatment consisted of elastic bandaging. At a follow-up examination, 3 weeks later, he complained of continuous pain and disability. Abduction strain radiographs demonstrated mild instability. The thumb was immobilized in a plaster cast for 3 more weeks. However, his complaints continued. Under regional anesthesia marked instability of the metacarpo-phalangeal joint was demonstrated. At operation the attenuated ends of the collateral ligament were identified. A palmaris longus free tendon graft was used, for a figure of 8 collateral arthroplasty. Three months later he had a stable joint with marked limitation of movements.

The fine anatomy of the thumb MP joint has been described in detail by Kaplan (1961) Stener (1962) and Coonard and Goldner, (1968). The joint capsule, ulnar collateral ligament and the accessory ulnar collateral ligament are the stabilizing structures on the ulnar side of the MP joint (Fig. 2). The two major muscles in this area are the first dorsal interosseous muscle which forms

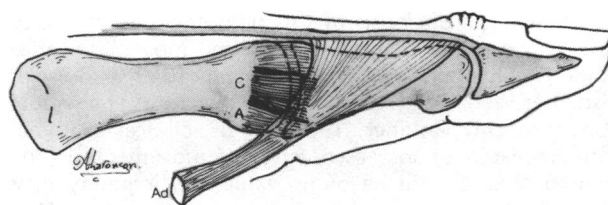


Fig. 2: The normal anatomy of the M-P joint. The collateral ligament (C) and accessory collateral ligament (A), stabilize the ulnar side of the joint. The close relation with the adductor pollicis (Ad) is demonstrated.

the massive bulge of the first web space, and the adductor pollicis muscle which is in a deeper layer, and is attached to the base of the proximal phalanx of the thumb. When the thumb is forcefully abducted the stabilizing ligaments of the MP joint are the most vulnerable structures, although the adductor muscle may partially tear. Several types of injuries have been detected radiologically. The joint capsule and the ulnar collateral ligament may detach from their insertion to the base of the proximal phalanx. There may be a detachment of a small fragment of bone from the base of the proximal phalanx, and in severe cases the bone fragment is bigger and is detached from the ulnar side as well as the ventral side of the phalanx. In severe cases there may be an associated tear of the volar plate (Moeberg and Stener, 1959; Moeberg 1960; Neviasser et al, 1971). Smith (1977) described 86 patients with post traumatic instability of the MP joint, 66 of which suffered from ulnar instability. Only 24 patients of the whole group had an avulsed fracture at the base of the proximal phalanx. This demonstrates the relative infrequency of fractures associated with instability of the MP joint. Kaplan/(1960) postulated that damage to the extensor mechanism of the thumb is responsible for subluxation of this joint. A similar finding was reported by Browne et al (1976) who described tears of the extensor-intrinsic hood mechanism in 12 patients who underwent surgery. Tear of the ulnar collateral ligament, which is the stabilizing ligament of the MP joint, results in imbalanced traction of the thumb over the first metacarpal bone. The extensor tendon pulls proximally, the adductor pulls to the ulnar side, thus the resultant pull tends to rotate and displaces the thumb over the metacarpal bone in a volar direction.

Theoretically these conditions could be treated conservatively by some elastic bracing or by plaster cast. However, it has been demonstrated that the detached ulnar collateral ligament may fold in such a way that its free end lies over the aponeurosis of the adductor muscle, thus no spontaneous anatomic repair is possible. (Bowers and Hurst, 1977; Parkish et al, 1976)

The clinical diagnosis of this pathology is difficult to assess. The typical range of the thumb movement varies among individuals (Harris and Joseph, 1949) and varies also between both thumbs of the same individual (Coonard and Goldner, 1968). Thus, clinical examination in search of increased range of movements in the injured thumb, will be of no value. Radiography may reveal the displaced avulsion fracture at the base of the proximal phalanx, the volar subluxation of the proximal phalanx over the metacarpal bone, and some joint space widening on the affected side. However, joint space widening may not be seen on standard X-ray exposures. That is the reason for stress films, taken when the thumb is subjected to abduction strain (Baily, 1963; Bowers and Hurst, 1977; Kessler, 1963; Sullivan 1976). However, not all patients will let the physician subject their injured thumb to further strain. Guarding and spasm of the adductor pollicis muscle may occur thus no movement will be detected in the MP joint, so stress films would preferably be taken after local or regional block. Lately the use of arthrography in the assessment of tears of the ulnar collateral ligament has been demonstrated (Bowers and Hurst 1977; Engel et al 1979). Leakage of the contrast material from the closed MP joint space, and demonstration of the heads of the adductor pollicis muscle, were found to be specific for tears of the ulnar collateral ligament (Fig. 3).

Tears of the ulnar collateral ligament have been treated surgically since 1928 (Milch, 1929), and it is generally accepted that best functional results are achieved in those patients operated upon at an early stage (Moeberg and Stener, 1959). Early diagnosis is therefore mandatory. In those cases where intra-articular fracture has occurred, Bowers and Hurst (1977) recommend open reduction and internal fixation. If the operation is performed shortly following the trauma it is possible to reinsert the avulsed fragment by means of a fine stainless-steel pullout wire. This is passed through the insertion of the ligament and is either drilled through the proximal phalanx or passed around the bone, and Weber, (1977) agrees. In cases where the bone fragment is big enough, transfixation of the avulsed fragment to the proximal phalanx, using a threaded wire, is a method commonly used. It is possible in cases of chronic instability to reinsert the adductor pollicis tendon to the ulno-dorsal margin of the base of the proximal phalanx, in order to achieve a dynamic repair of MP joint stability. In those cases with isolated detachment of the stabilizing ligaments, re-attachment using various techniques is recommended (Weber, 1977). Lately, the use of a periosteal flap from the adjacent phalanx to reinforce the repair of the ulnar collateral ligament has been described (Cowen et al, 1979). In long standing cases of joint instability repair of the ulnar collateral ligament may be performed by a figure of eight free tendon graft. Only the milder forms of instability with no arthrographic sign of tear of the ulnar collateral liga-

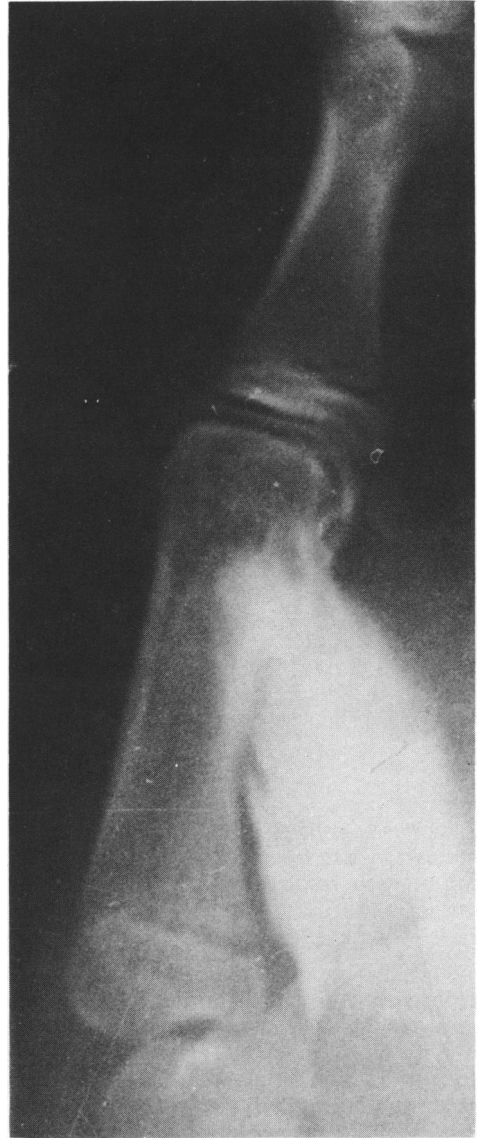

Fig. 3: Arthrographic demonstration of contrast material leaking from a joint space. In case of gamekeeper's thumb.

ment, according to Bowers and Hurst, could be treated efficiently by immobilizing the thumb in a plaster cast for four or more weeks.

As prevention is the best way of treating injuries, the new types of ski poles no longer have wrist straps and the skier can disconnect himself the moment he falls. Further improvements of equipment and preventive thumb bracing will markedly decrease the incidence of tears of the ulnar collateral ligament of the MP joint of thumb (Figs. 4, 5).

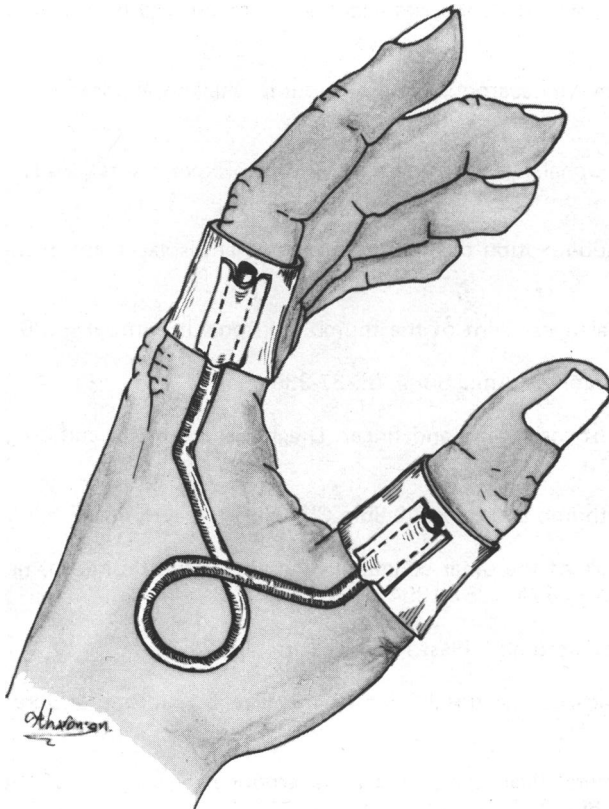


Fig. 4: Preventive splinting. A rubber band connecting 2 leather bands, limiting abduction and extension of the thumb.

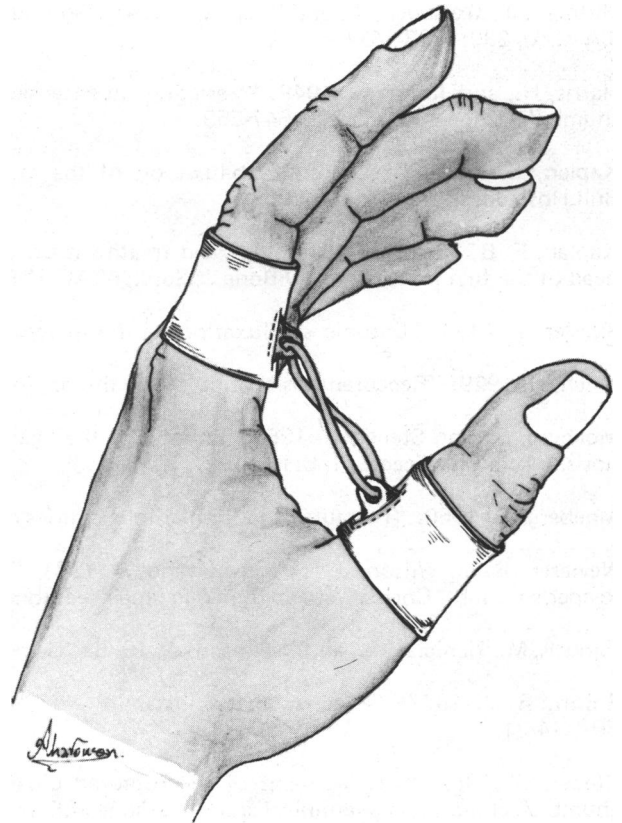


Fig. 5: Preventive splinting device. A bended spring preventing hyperabduction and hyperextension of the thumb.

REFERENCES

- Baily, R. J. A. 1963: "Some closed injuries to the metacarpophangeal joint of the thumb." *J.Bone Jt.Surg.*, 45B:428-429.
- Bowers, W. H., and Hurst, L. C. 1977: "Gamekeeper's thumb. Evaluation by arthrography and stress roentgenography." *J.Bone Jt.Surg.*, 59A:519-524.
- Browne, E. Z., Dunn, H. K., and Snyder, C. C. 1976: "Ski pole thumb injury." *Plast.Reconst.Surg.*, 58:19-23.
- Cambell, C. S. 1955: "Gamekeeper's thumb." *J.Bone Jt.Surg.*, 37B:148-149.
- Coonard, R. W., and Goldner, J. L. 1968: "A study of the pathological findings and treatment in soft tissue injuries of the thumb's metacarpophalangeal joint." *J.Bone Jt.Surg.*, 50A:439-451.
- Cowen, N. J., Brassard, P., and Ames, E. L. 1979: "A triple repair for collateral ligament ruptures in the hand." *Orthop. Rev.*, 8:111-116.
- Engel, J., Ganel, A., Ditzian, R., and Militeanu, J. 1979: "Arthrography as a method of diagnosing tear of the ulnar collateral ligament of the metacarpophalangeal joint of the thumb (gamekeeper's thumb)." *J.Trauma*, 19:106-109.

- Gutman, J., Weisbuch, J., and Wolf, M. 1974: "Ski injuries in 1972-1973. Repeat analysis of a major health problem." *J.A.M.A.*, 230:1423-1425.
- Harris, H., and Joseph, J. 1949: "Variations in extension of the metacarpophalangeal and interphalangeal joints of the thumb." *J.Bone Jt.Surg.*, 31B:547-559.
- Kaplan, E. B. 1960: "Lateral sub-luxation of the metacarpophalangeal joint of the thumb. Experimental study." *Bull.Hosp.Joint Dis.*, 21:200-205.
- Kaplan, E. B. 1961 "The pathology and treatment of radial sub-luxation of the thumb with ulnar displacement of the head of the first metacarpal." *J.Bone Jt.Surg.*, 43A:541-546.
- Kessler, I. 1963: "Chronic sub-luxation of the metacarpophalangeal joint of the thumb." *J.Bone Jt.Surg.*, 45B:805.
- Milch, H. 1929: "Recurrent dislocation of the thumb, capsulorrhaphy." *Am.J.Surg.*, 6:237-239.
- Moeberg, E., and Stener, B. 1959: "Injuries of the ligaments of the thumb and finger. Diagnosis, treatment and prognosis." *Acta Chir.Scand.*, 106:166-182.
- Moeberg, E. 1960: "Fractures and ligamentous injuries of the thumb and fingers." *Surg.Clin.North Amer.*, 40:297-309.
- Neviaser, R. J., Wilson, J. N., and Lievano, A. 1971: "Rupture of the ulnar collateral ligament of the thumb (gamekeeper's thumb). Correction and dynamic repair." *J.Bone Jt.Surg.*, 55A:1357-1364.
- Parkish, M., Nahigian, S., and Froimson, A. 1976: "Gamekeeper's thumb." *Plast.Reconst.Surg.*, 58:24-31.
- Smith, R. J. 1977: "Post traumatic instability of the metacarpophalangeal joint of the thumb." *J.Bone Jt.Surg.*, 59A:14-21.
- Stener, B. 1962: "Displacement of the ruptured ulnar collateral ligament of the metacarpophalangeal joint of the thumb. A clinical and anatomical study." *J.Bone Jt.Surg.*, 44B:869-879.
- Sullivan, M. F. 1976: "Injuries of the fingers and hand." In Watson — Jones R.: *Fractures and Joint Injuries*. Edinburgh, Churchill-Livingstone, p.p. 780-783.
- Weber, U. 1977: "Osseous ruptures of the ulnar collateral ligament of the metacarpophalangeal joint of the thumb." *Arch.Orthop.Unfall Chir.*, 88:27-35.
-