


## IMMEDIATE MANAGEMENT OF INJURIES

L. WALKDEN, MD

*Hon. Medical Officer, R.F.U.*



### ABSTRACT

Specific injuries are not confined to any particular sport, but regular injury patterns will occur among the players of any given sport. Emphasis is placed on the need for primary treatment facilities, the experience of the attendant, and the importance of a working knowledge of the sport involved. Diagnostic difficulties are described with reference to cervical, oral, ocular and other injuries. Immediate and long-term management of injuries to the lower limbs is considered.

All full-contact sports necessarily have their quota of injuries, which, though not sport-specific, do show regular injury patterns amongst participants.

#### FIRST AID TRAINING OF PERSONNEL

Facilities for early diagnosis and management of injuries vary considerably, and are frankly embarrassingly inadequate in too many pastimes. It is reasonable to expect that some members of a club will have attended a first aid course, and that the club will be equipped with an adequately stocked first aid bag and an easily accessible stretcher. Unfortunately, the era of the bucket and sponge persists; despite availability of courses run by the St. John Ambulance Brigade and the Red Cross, among others.

The attendant should be placed close to the pitch to observe the match or event with a minimum of disturbance, and have a working knowledge of the sport. Invariably he will only be called onto the field of play by the referee, in an advisory capacity; in sport as in the community at large, medicine is advisory rather than authoritative.

#### LAWS OF THE GAME AND ACCESSIBILITY TO THE INJURED

Sports vary in the time permitted for attention on the pitch to an injured player; rugby permits one minute (extended of course, where serious injury is suspected, to temporary suspension of the game for the necessary period of treatment). Otherwise, in minor trauma, treatment is expected to continue off the pitch. It should

be axiomatic to avoid treatment before having a rough idea as to the diagnosis, being ever mindful of what not to do. Basic principles of history, observation and inspection can be applied quickly, before further examination, to establish the presence of normal vital functions such as breathing, consciousness and limb movements, and the source of haemorrhage where indicated. The presence of a mouthguard is checked, and if present, removed. The incident should be managed quietly and with confidence, but without interference. The attendant will have arrived at a time envied by a Casualty surgeon — before the onset of painful muscle spasm, exudate and bruising can cloud the diagnosis.

#### MANAGEMENT OF THE ACUTE INJURY

The range of movement can be assessed with the player's co-operation, rarely using passive movements, and comparing the injured and uninjured sides where there is diagnostic doubt. The presence of long standing injury or deformity must be taken into account.

An injured player should not be dragged to his feet, but taken off when, in the opinion of the attendant, continued participation in the game would cause worsening of the injury, and a substitute called in, when permitted.

#### INJURIES IN RUGBY FOOTBALL

The head, neck and face are the site of approximately 55% of injuries in rugby, and cuts and lacerations predominate. 75% of lacerations occur to the front five forwards, and half usually require suture. If there are

adequate facilities, suturing is best completed forthwith, otherwise no later than after four hours. The numbing effect of the injury obviates the need for a local anaesthetic, allowing close apposition of the wound edges in the absence of exudate. Eyebrows should not be shaved off as regrowth can be uncertain, and tetanus immunisation should be up to date.

### HEAD INJURY

Momentary insensibility followed by confusion, retrograde amnesia, unsteadiness and inco-ordination indicates the risk of primary brain damage or, at least, concussion. The player must be removed from the field of play.

If there has been reasonable doubt as to loss of consciousness (with brief memory loss), and the player appears alert at the time of examination on the pitch, he should be seen to rise promptly to his feet, to be able to stand firmly with eyes closed, and to "shuttle run" briskly to a set point. Only then may he continue in the game, closely observed by the attendants and fellow players.


The technically knocked-out casualty can provide difficulty. He may be dazed, unsteady, nauseated, amnesic, possibly aggressive to the attendant, and repetitive in expressed thought. He must be taken off, even under protest, if necessary with enforcement of the decision by the captain and referee. Hospital referral should be mandatory. No concussed player should play again for three weeks at least, and then ideally only after medical confirmation, backed by a normal electroencephalogram.

### ASPHYXIA


Unconsciousness presents an emergency and asphyxia necessitates prompt resuscitation. A clear airway is essential; with the deeply probing index finger any loose teeth, a loosely fitting mouthguard or dentures, or a piece of chewing gum (a not uncommon laryngeal foreign body) should be searched for and removed. Concurrently mouth-to-mouth resuscitation with the neck extended and chin well forward should be commenced. If no expansion of the chest occurs, or restlessness, lividity or foaming at the mouth appear rapidly, airway obstruction is most likely. The player should be sat up, one of the attendant's hands should support the thoracic spine, and pressure is then applied sharply just below the ribs with the heel of the other hand, to expel forcibly any foreign body. Speed is essential, and if this manoeuvre is unsuccessful the player may be inverted rapidly by others and given a sharp blow between the shoulder blades — in practice, a life saving measure, especially applicable to children. A respiratory arrest must be removed to hospital forthwith; the recovery position should be used, but only if neck injury is not suspected.

### CERVICAL INJURY

A sportsman may suffer a neck injury from, for example, an accident in the gymnasium or on the trampoline or martial arts mat, or in a rugby scrum collapse, tackle or ruck. The attendant may not be aware immediately of the presence or absence of severe injury produced by hyperextension, hyperflexion, rotation and compression; there may be a simple acute muscular spasm with the head held in flexion, or acute wry neck with the chin rotated and pointing upwards to the opposite side of an apophyseal joint injury. Limb movements may be present, but should the player experience tingling or any sensation disorder down the arms (no matter how transitory), or high interscapular pain, he should not be moved even if semi-prone. Maximal immobilisation is necessary before removal by ambulance. At Twickenham R.F.U. ground a Ferney-Washington "scoop" stretcher is always available for such an eventuality, allowing the player to be moved in the position in which he is found. If the casualty is in the supine position, neck immobilisation with a soft collar may be utilised, with neck traction by the very skilled maintained until arrival at hospital.



*Fig. 1a: The Scoop stretcher in open position.*



*Fig. 1b: The Scoop stretcher in closed position.*

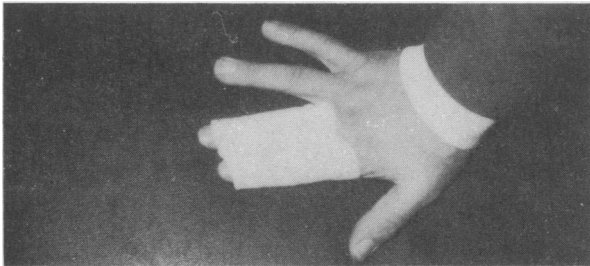
Mouthguards, correctly made by a dental surgeon for the individual, can reduce drastically cranial, dental and facial injury, which gives confidence and enables a hard game to be played. An avulsed tooth can be washed under the tap and replaced under firm sustained pressure. If oral examination reveals bleeding of the lower gum, or if biting on a handkerchief produces localised pain, a jaw fracture should be suspected, even before swelling has appeared.

### CHEST INJURIES

Pressure applied anteriorly and laterally will produce pain at the site of a suspected rib fracture. Confirmatory X-ray is essential. Match fitness cannot occur until exertional pain is absent; this usually takes five to six weeks.

### LIMB INJURIES

Fractures, particularly of the ulna, the head of radius, the lower third of the fibula or the mandible, may not necessarily be painful immediately; loss of power may be the initial symptom preceding exudate, haematoma and consequent pain.



*Fig. 2: The Bradford finger splint.*

A suspected dislocation should be compared with the uninjured side. Whether or not prompt reduction is attempted by a competent medical attendant, subsequent X-ray is essential. A Bradford splint is best for finger injuries.

Team sports ultimately depend on "runability". High injuries producing quadriceps muscle haematoma demand immediate ice, compression and elevation. Inability to flex the knee to 90° after 48 hours indicates an intramuscular haematoma.

Knee injuries should be examined on the pitch, with the player sitting. Locate the joint line and site of maximal tenderness should be located, and quadriceps contraction encouraged. An acutely painful, unstable knee joint means that the player should be sent off without bearing any weight on the injured limb. An effusion that develops within an hour or two is indicative of a haemarthrosis, possibly from cruciate ligament damage. Even if the knee injury seems minor, with a full painless range of movement, the player who cannot, for instance, hop on the afflicted knee should be sent off.

The ankle joint, when injured, must be treated with ice, compression and elevation; these immediate measures lead to more rapid recovery after subsequent medical treatment. The ankle wrap support commonly used in the USA should be applied before the match to reduce ankle injuries when studded shoes are worn.

Certainly, prompt treatment, competently carried out and allied with measures of prevention, can give further enjoyment to sporting pastimes.