

## MERALGIA PRAEETHETICA – A SPORTS LESION IN GIRL GYMNASTS

J. MACGREGOR, B.Sc., M.Sc., Ph.D., M.I.Biol.<sup>(1)</sup>

and

J. A. MONCUR, T.D., M.B., Ch.B., D.Phys.Med., D.P.E.<sup>(2)</sup>

<sup>1</sup> Reader in Tissue Biomechanics, Bioengineering Unit, University of Strathclyde, Glasgow, Scotland.

<sup>2</sup> Medical Officer, Scottish School of Physical Education, Jordanhill College, Glasgow, Scotland.

### ABSTRACT

Investigation into thigh pain in two girl gymnasts has established the likely relationship between the point of impact on the thighs during exercises on the asymmetric bars and mild neuropathy of the lateral femoral cutaneous nerve.

The clinical and biomechanical steps taken to elucidate the problem are described. Local infiltration of anaesthetic has confirmed a definitive diagnosis of meralgia paraesthetica in one case.

### INTRODUCTION

We were recently invited by a gymnastic coach to consider the cases of two of his more advanced athletes. Both girls complained of 'thigh pain' exacerbated by 'beating' on the asymmetric bars which resolved after resting. The supposition was that the symptoms were due to a muscle or connective tissue lesion. Investigation suggested that the discomfort was produced by mechanical compression of the lateral femoral cutaneous nerve resulting in a neuropathy classically described as "Meralgia paraesthetica" (Roth 1895).

The lateral femoral cutaneous nerve arises from the roots of L2 and L3 (see Fig. 1). It crosses the iliacus and passes towards the anterior superior iliac spine under the attachment of the internal oblique muscle. The nerve is entirely cutaneous in its distribution, supplying the anterior lateral aspect of the thigh. It usually enters the thigh by passing through a tunnel in the lateral attachment of the inguinal ligament to the anterior superior iliac spine. At first it lies beneath the deep fascia of the upper thigh but it soon becomes superficial. Many variations in the detailed course of the nerve are reported including routes through, rather than deep to, the inguinal ligament, "bowing" of the nerve as it crosses the iliacus fascia, passage through the sartorius muscle and even passage of the nerve lateral to and posterior to the anterior superior iliac spine (see Ghent, 1961; Kitchen & Simpson, 1972). It is generally agreed that some disturbance to this nerve produces the typical burning sensation in the antero-lateral portion of the thigh. The wide range of possible causes have been postulated. McIntyre (1971), lists 14 suspected causes of the condition and includes physical trauma. On the one hand, Lockhart

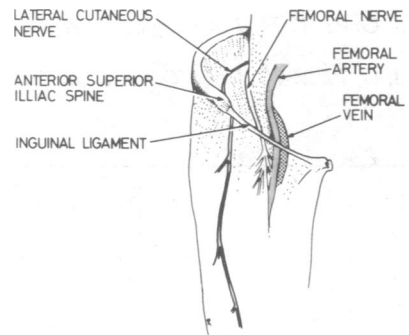


FIG. 1 Anatomy of Lateral Femoral Cutaneous Nerve

(1965) describes the condition as rare, whereas John (1974) reported an incidence of almost 7% in a series of 100 cases of leg discomfort referred for evaluation.

In an excellent recent review, Spillane (1975) was of the opinion that the majority of cases of meralgia paraesthetica had no history of preceding trauma believing that compression or kinking of the nerve in its course most probably near the opening in the inguinal ligaments itself was responsible. He feels that in many cases no pain is experienced, the patient simply becoming more aware of an area of numbness or coldness in the thigh. He states that it is rare in the female, except temporarily during pregnancy, and although more commonly characteristically seen in obese men, has found it in all physical types. His experience includes cases occurring in diabetics and occasionally it appears to be familial (Eibel, 1974) the outstanding example of which was Sigmund Freud and one of his sons. Beresford (1961) reported

the condition after trauma to the region of the anterior iliac spine by the seat belt during a motor vehicle collision.

The present investigation draws attention to yet another cause of the condition. In ladies' gymnastics an increasing number of visually attractive routines and exercises on the asymmetric bars require that the gymnasts swing around the hands placed on the upper bar with the body extended so that it strikes the lower bar just below the anterior superior iliac spines (see Fig. 2).

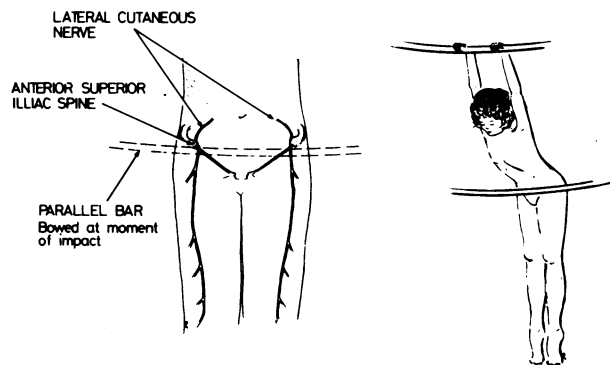


FIG. 2 Gymnast on Asymmetric Bars

Flexion of the body around the bar, coupled with the elastic behavior of the bar itself, results in a storage of energy which on the "rebound" produces the necessary momentum for further rotations around the equipment. The impact is on the lower abdomen and across the upper parts of the thigh, but below the anterior superior iliac spines.

## CASE HISTORIES

1. An eighteen-year old girl who has participated seriously in gymnastics for four years and now has reached Grade III (BAGA). There was no frank injury to the legs, but she complained of a 'pulling' and a 'burning' sensation in the lower lateral area of the right thigh after "beating the bar". The thigh is then numb on standing for about 2 minutes until the feeling passes off. Physical examination revealed relative thickening of the soft structures around the right anterior superior iliac spine, but there was no tenderness and no obvious sign of cutaneous sensory deficit.

2. A fourteen-year old girl, who has trained seriously for three years and obtained Grade V (BAGA). She complained of pain in the left thigh for the past two months — the pain was described as a 'shooting' pain, antero-laterally. When it first occurred, she was rested for 3 weeks by which time the pain was less severe, but did not disappear. On resuming training, considerable

discomfort was experienced especially when "beating" on the asymmetric bar. On examination, a superficial bruise was noted over the right anterior iliac spine. Such bruising is not uncommon in gymnasts, but of more significance perhaps, was the tenderness found to be relatively greater below the left anterior superior iliac spine. There was no obvious deficit of cutaneous sensation.

## BIOMECHANICAL INVESTIGATION

There seems little doubt that the lesions described were attributable to the bar-beating exercise. The question remains as to why the lesions should be unilateral and it seemed desirable to identify the anatomical relationship of the point of impact with some precision.

Information on the magnitude of the forces applied dynamically to the abdominal and thigh structures would be of considerable biomechanical interest and possibly of some clinical significance. However, a definitive instrumentation requires very considerable expensive technical effort and there is a natural reluctance to "instrument" the apparatus used routinely by a very large number of individuals. It was therefore decided to study the point of contact of the bar on the body in some detail in the first of the two cases. A method was developed to provide evidence on the point of contact of the bar on the body. It consisted of sheets of high quality white paper, typewriter carbon paper, fine plastic mesh, and a further sheet of thin paper was added to transmit force relatively uniformly to the plastic mesh. The entire device (see Fig. 3) was formed into a sandwich by securing the periphery with adhesive tape and then tailored so that it could be attached from a line just above the anterior superior iliac spines to the lines of the groin and in such a way as not to inhibit flexion of the hip.

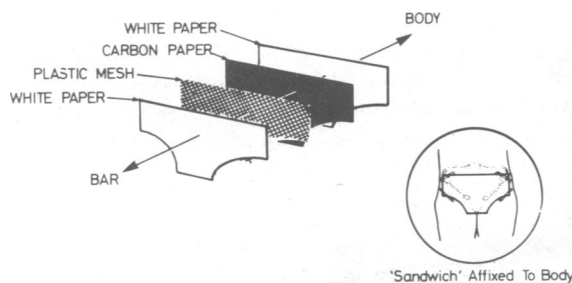


FIG. 3 Pressure Sensitive 'Sandwich'

The pressure sensitive sandwich was attached to the subject with clinical plastic tape lining up the anterior superior iliac spine with pre-selected landmarks on the sandwich. On completion of the 'beating' manoeuvre, the sandwich was removed and opened up and the car-

bon 'imprinting' observed. Results are shown in Fig. 4. The test was repeated.

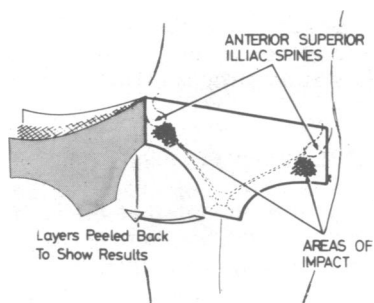


FIG. 4 Representation of Results

## RESULTS

On the right the centre of the area of impact was just on the lower margin of the anterior superior iliac spine and on the left, the area of impact passed below the region of the anterior superior iliac spine. After some discussion with the coach, we decided to recommend that the relative position of the asymmetric bars be changed to increase the radius of rotation around the upper bar to the point of impact on the lower bar. In the first instance the distance between the bars was increased by about half an inch. It was felt that this might be sufficient to remove the area of the impact to below the critical point on the hip.

After a period of 3 weeks, the subject reported a significant reduction in discomfort although there were a few residual symptoms exacerbated by 'beating'. A further series of tests were then completed using pressure sensitive strips (see Fig. 5) over each thigh. A series of three trials showed consistent differences, the points of impact still being higher on the right than on the left. In each case, the point of impact was about 1 to 2 cms lower than the previous trial.

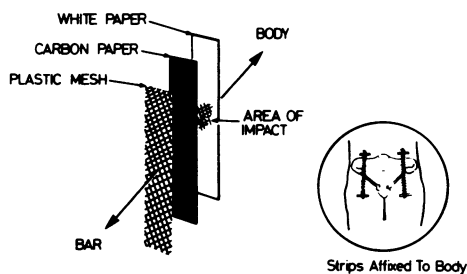


FIG. 5 Pressure Sensitive Strips.

## FURTHER INVESTIGATION

In view of the continuing discomfort, it seemed justifiable to make a single injection of 2 ml of 2% Xylocaine subcutaneously about 2 cm medial and 2 cm inferior to the right anterior superior iliac spine. Symptoms typical of cutaneous nerve anaesthesia were produced over the surface of the thigh and the characteristic pain first reported was temporarily abolished thus proving that the lesion was in the area of supply of the lateral cutaneous nerve of the thigh and excluding root pressure as a cause.

## DISCUSSION

The highly characteristic history provided by the subjects, coupled with the relationship of the changes in history to changes in technique and changes in the position of the area of impact, all support the view that the subject suffered from 'meralgia paraesthetica' as a result of 'beating' on the lower of the asymmetric bar in regular gymnastic routines. The response of one subject to local infiltration of an anaesthetic agent makes the diagnosis definitive in that case.

Although only two cases are reported here, the incidence in what is after all a relatively small number of active gymnasts, suggests that the lesion may be more common than is generally appreciated. Coaches and club doctors might wish to enquire into 'muscular aches and pains' in the thighs, with a view to excluding a developing neuropathy. It remains to be seen whether adjustment of the relative positions of the bars in individual cases will remove the risk entirely.

Attention was drawn to this problem by reports of unrelieved discomfort, but it is a matter of speculation whether milder degrees of impairment may be present in greater numbers of subjects which will only be elucidated by careful investigation of a larger number of gymnasts.

## ACKNOWLEDGEMENT

We are indebted to the officers and members of Glasgow Central Gymnastic Club for their enthusiastic co-operation throughout the study and to Mr. F. Bain for drawing our attention to the problem initially at the Annual Scottish BASM meeting at Inverclyde House.



#### REFERENCES

- Beresford, H. R., 1971. Meralgia paraesthetica after seat-belt trauma. *J.Trauma*, **II**, 629-630.
- Eibel, P., 1974. Meralgia paraesthetica (Letter to Ed.), *Canad.med.Assoc.J.*, **III**, 1299.
- Ghent, W. R., 1961. Further studies on meralgia paraesthetica. *Canad.med.Assoc.J.*, **85**, 971-875.
- Jones, R. K., 1974. Meralgia paraesthetica as a cause of leg discomfort. *Canad.med.Assoc.J.*, **III**, 541-542.
- Kitchen, C. & Simpson, J., 1972. Meralgia paraesthetica – a review of 67 cases. *Acta Neurol.Scandinav.*, **48**, 547-555.
- Lockhart, R. D., Hamilton, G. F. & Fyfe, F. W., 1965. *Anatomy of the Human Body*, (2nd Ed). Faber and Faber, (London), 298.
- McIntyre, I., 1971. Meralgia paraesthetica. *Practitioner*, **206**, 250-252.
- Roth, V. K., 1895. Bernhardt's disturbance of sensation. *Meeting of the Physico-Medical Society of Moscow – March 20*.
- Spillane, J. D., 1975. *An Atlas of Clinical Neurology*, (2nd Ed). Oxford University Press, London, 198-200.