

## SCIENTIFIC LETTER

## Impact of cinematic viewing on endothelial function

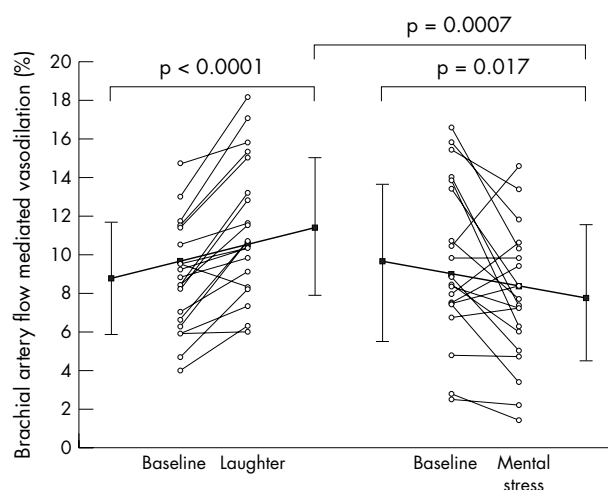
M Miller, C Mangano, Y Park, R Goel, G D Plotnick, R A Vogel

Heart 2006;92:261–262. doi: 10.1136/hrt.2005.061424

Chronic life stressors such as depression, anxiety, hostility, and anger may contribute to increased risk of coronary heart disease,<sup>1</sup> in part by impairing endothelial function.<sup>2,3</sup> Although coronary heart disease may also be associated with attenuated positive emotions as shown by reduced situational humour,<sup>4</sup> little if any information is available regarding the potential impact of positive emotions on vascular reactivity. Because cinematic viewing evokes a range of negative and positive emotions, the present study was designed to compare the effect of mental stress versus laughter on endothelial function.

## METHODS

Twenty non-smoking, healthy men and women, mean (SD) age 33 (7) years, with normal blood pressure, cholesterol, and blood glucose provided written informed consent to participate in this randomised and counterbalanced, crossover study approved by the institutional review board. After an overnight fast that included abstinence from alcohol, vitamins, herbs, and aerobic activity, volunteers had a baseline brachial artery reactivity test and were then randomly assigned to view a 15–30 minute segment of a movie designed to induce either mental stress or laughter. Each subject was instructed to watch as much of the movie as necessary until they felt they had been affected by viewing it. Volunteers watched the movie while lying in a recumbent position in a temperature controlled room (22°C). An example of a movie causing mental stress is the opening scene of *Saving Private Ryan* (DreamWorks, 1998). Laughter was readily elicited when observing selected scenes of a comedy such as the movie *Kingpin* (MGM, 1996) or *There's something about Mary* (20th Century Fox, 1998). Because the time course of the effects of laughter or mental stress on endothelial function has not been established, a minimum of 48 hours elapsed between the two arms of the trial to minimise the possibility of an interphase effect. Baseline brachial artery reactivity was tested in each of the two phases and one ultrasonographer performed all studies. Brachial artery flow mediated (endothelial dependent) vasodilatation (FMD) was measured with an 11.5 MHz broadband linear array transducer and baseline images were acquired after a 15 minute supine equilibration period by well established methods.<sup>5</sup> Post-stimulus images were acquired one minute  $\pm$  15 seconds after the release of a five minute upper arm occlusion. A total of 160 arterial measurements were taken including measurements before and one minute after laughter and mental stress phases. FMD was quantified as the percentage diameter change of the post-occlusion arterial diameter measurement relative to baseline. An experienced investigator blinded to the subject's identity and study phase analysed the end diastolic frames. The paired *t* test was used to compare brachial artery FMD before versus after the laughter phase, as well as before versus after the mental stress phase. The two baseline phases and the post-laughter/post-mental stress phases were also compared.



**Figure 1** Brachial artery flow mediated vasodilatation at baseline and after a 15–30 minute movie segment causing laughter or mental stress.

## RESULTS

Brachial artery FMD was reduced in 14 of the 20 volunteers after watching the movie clips that caused mental stress. In contrast, brachial vasodilatation was increased in 19 of 20 volunteers after watching the movie segments that generated laughter ( $p < 0.0001$ ). Significant changes in flow mediated reactivity were noted between baseline and the laughter phase ( $p < 0.0001$ ) and between baseline and the mental stress phase ( $p = 0.017$ ). Overall, mean (SD) upper arm FMD was increased 22 (15)% during laughter and reduced 35 (47)% during mental stress ( $p < 0.0001$ ) with absolute changes of 2.6 (1.9)% and  $-1.9$  (3.2)%, respectively ( $p = 0.0007$ ) (fig 1). The groups did not differ in baseline diameters or baseline flow mediated reactivity (9.6 (4.1)% and 8.8 (2.8)% in the mental stress and laughter phases, respectively) suggesting consistent image acquisition scan technique and internal consistency of measurements.

## DISCUSSION

The overall difference in brachial artery FMD between the mental stress and laughter phases exceeded 50% in healthy men and women. Brachial artery FMD that was impaired as a consequence of viewing a movie that induced mental stress is similar in magnitude to provocations caused by anger recall and mental arithmetic.<sup>2</sup> As well, improvement in FMD after laughter has been previously observed after aerobic activity or statin initiation.<sup>6,7</sup> Because mental stress may impair nitric oxide mediated vasodilatation,<sup>2</sup> these data raise the possibility that positive emotions such as mirthful laughter have an opposite effect on the endothelium. Such effects may be attributable to attenuation of neuroendocrine hormones (for example, cortisol) involved in the downregulation of endothelial dependent vasodilatation<sup>8,9</sup> or, potentially, by activation of nitric oxide synthase. However, the present

study was not designed to test mechanisms and, therefore, further studies are required to understand the mechanistic effects of the emotions elicited by film viewing.

#### ACKNOWLEDGEMENTS

We thank J Gottdiener for critical review of the manuscript. The study was supported by NIH grant HL61369 and a Veterans Affairs Merit Award to MM.

#### Authors' affiliations

M Miller, C Mangano, Y Park, R Goel, G D Plotnick, R A Vogel, University of Maryland, Baltimore, Maryland, USA

All authors participated in the conception and design of the study, and drafting and revision of the manuscript and provided administrative, technical, or material support.

Correspondence to: Dr Michael Miller, University of Maryland Medical Center, Center for Preventive Cardiology, Rm S3B06, 22 South Greene Street, Baltimore, MD 21201, USA; mmiller@medicine.umaryland.edu

Accepted 12 May 2005

#### REFERENCES

- 1 Strike PC, Steptoe A. Psychosocial factors in the development of coronary artery disease. *Prog Cardiovasc Dis* 2004;**46**:337–47.
- 2 Gottdiener JS, Kop WJ, Hausner E, et al. Effects of mental stress on flow-mediated brachial arterial dilation and influence of behavioral factors and hypercholesterolemia in subjects without cardiovascular disease. *Am J Cardiol* 2003;**92**:687–91.
- 3 Harris KF, Matthews KA, Sutton-Tyrrell K, et al. Associations between psychological traits and endothelial function in postmenopausal women. *Psychosom Med* 2003;**65**:402–9.
- 4 Clark A, Seidler A, Miller M. Inverse association between sense of humor and coronary heart disease. *Int J Cardiol* 2001;**80**:87–8.
- 5 Corretti MC, Plotnick CD, Vogel RA. Technical aspects of evaluating brachial artery vasodilation using high-frequency ultrasound. *Am J Physiol* 1995;**268**:H1397–404.
- 6 Vogel RA, Corretti MC, Plotnick GD. Changes in flow-mediated brachial artery vasoactivity with lowering of desirable cholesterol levels in healthy middle-aged men. *Am J Cardiol* 1996;**77**:37–40.
- 7 Rywik TM, Blackman MR, Yataco AR, et al. Enhanced endothelial vasoreactivity in endurance-trained older men. *J Appl Physiol* 1999;**87**:2136–42.
- 8 Spieker LE, Hurlimann D, Ruschitzka F, et al. Mental stress induces prolonged endothelial dysfunction via endothelin-A receptors. *Circulation* 2002;**105**:2817–20.
- 9 Berk LS, Tan SA, Fry WF, et al. Neuroendocrine and stress hormone changes during mirthful laughter. *Am J Med Sci* 1989;**298**:390–6.

## IMAGES IN CARDIOLOGY

doi: 10.1136/hrt.2005.068429

### Intramyocardial bridging of the left anterior descending artery: appearance of arterial compression on ECG gated multidetector row CT

A 38 year old man presented with a history of multiple hospital admissions with recurrent exertional related chest pain. On each occasion there was no elevation in cardiac troponin. Exercise stress testing revealed myocardial ischaemic change but coronary angiography failed to demonstrate underlying coronary disease although myocardial bridging of the left anterior descending artery (LAD) was suspected.

ECG gated 16 detector row coronary computed tomography (CT) was performed. The Agatston calcium score was zero, making occlusive atherosclerotic coronary disease unlikely, and on initial review of images in the end diastolic phase (75–95% of R-R interval), the coronary anatomy was normal. Three dimensional volume rendered images clearly demonstrated intramyocardial bridging of the proximal LAD (panel A: 75% R-R interval; arrow), confirming this impression on the axial data; using “cardiac transparency” software (General Electric Medical Systems, Milwaukee, USA) removal of the myocardium revealed a normal calibre LAD (panel B). However, review of the images in the end systolic phase (35–45% of R-R interval) confirmed compression of the intramyocardial segment of the LAD (panel C: 35% R-R

interval; arrow) and reduced calibre of the more distal aspect of this vessel; the myocardium and left ventricular cavity have been selectively removed.

An epicardial segment of coronary artery that “tunnels” through the myocardium is termed “myocardial bridging”. This segment is compressed during systole, though its clinical relevance is debated. Generally considered a benign condition, it has been associated with angina, ischaemia, infarction, dysrhythmias, compromised left ventricular function, and sudden death. CT is a non-invasive alternative for diagnosis, where location, length, and depth of the tunnelled segment is readily assessed.

Although motion artefact is minimal in end diastole when reviewing CT coronary angiography, it is important to remain aware that symptomatic myocardial bridging can be demonstrated clearly on the systolic phases.

N E Manghat  
C A Roobottom  
A J Marshall  
docnatman@msn.com

