

## SCIENTIFIC LETTER

# Usefulness of quantitative myocardial contrast echocardiography for prediction of ventricular function recovery after myocardial infarction treated with primary angioplasty

E Pérez-David, M A García-Fernández, J Quiles, P Mahía, J L López-Sendón, E López de Sa, M J Ledesma, M Moreno, M Desco, E García

*Heart* 2006;92:693–694. doi: 10.1136/hrt.2005.071357

Up to 30% of patients with acute myocardial infarction (AMI) treated with reperfusion and with an apparently successful result have microvascular dysfunction. Multiple techniques are available for the diagnosis of this condition, but little information is available comparing their ability to predict ventricular recovery after AMI. The objective of our study was to compare the accuracy of myocardial contrast echocardiography (MCE) with that of myocardial blush grade (MBG) for this purpose, introducing quantitative MCE analysis.

## METHODS

This was a prospective study of 68 consecutive patients undergoing primary angioplasty in our institution for a first ST segment elevation AMI < 24 hours after symptom onset. Patients with wall motion abnormalities in more than one vascular territory in the initial echocardiogram, previous coronary artery bypass surgery, or haemodynamic instability were excluded. Informed consent was obtained from all participants. Our institutional review board approved the study.

Standard echocardiography and real time MCE in apical views (contrast pulse sequencing; Acuson-Siemens) were performed 24–72 hours after reperfusion. MCE was performed with intravenous continuous infusion of the contrast agent BR-1 (Bracco), at a low mechanical index (0.17–0.23) and a frame rate of 20 Hz. Microbubbles were destroyed with bursts of high mechanical index (1.2) during three cardiac cycles (interval between bursts of 200 ms), allowing subsequent myocardial refilling. A follow up study was performed six months later.

Two experienced readers scored segmental wall motion as 1 (normal), 2 (hypokinetic), 3 (akinetic), or 4 (dyskinetic). Akinetic-dyskinetic segments on the initial echocardiographic study constituted the risk area. Left ventricular function recovery was defined as an improvement in left ventricular ejection fraction, assessed by Simpson's method,  $\geq 9\%$  during follow up.<sup>1</sup>

Segmental opacification was visually scored as normal, patchy, or absent (0).<sup>1,2</sup> The background subtracted video intensity in a number of regions of interest was quantified with proprietary software, giving time–video intensity curves corresponding to microbubble myocardial refilling curves. Curves were fitted to exponential functions of the type  $y = A(1 - e^{-Bt})$ . Myocardial blood flow index was determined as the product of  $A \times B$ . This parameter was normalised to the highest video intensity segment in the corresponding echocardiographic view.<sup>1</sup> MCE indices were derived for each patient as mean visual score (visual index) and mean myocardial blood flow index (quantitative index) in the risk area.

Two investigators, unaware of echocardiographic studies, reviewed coronary angiographies and determined post-angioplasty MBG (0–3) in the culprit artery.<sup>2</sup>

Receiver operating characteristic curves were generated to predict left ventricular recovery with MCE and MBG. Logistic regression was used to assess independent predictors of absence of ventricular recovery.

## RESULTS

The study group comprised 59 patients (nine could not complete the follow up study). Mean (SD) age was 65 (13) and 42 (71%) patients were men. The infarct related artery was the left anterior descending in 32 patients (54.2%), right coronary in 24, and left circumflex in three. In the final angiogram, TIMI (thrombolysis in myocardial infarction) flow in the infarct related artery was grade 3 in 45 patients (76.3%), grade 2 in 10 (16.5%), and grade 0–1 in four (6.8%). MBG grade 2–3 was observed in 38 patients (64.4%), grade 1 in 13 (22%), and grade 0 in eight (13.6%). No adverse effects were observed during MCE studies.

Among the patients studied, 372 segments were akinetic-dyskinetic. Interpretable data with both MCE analyses were obtained in 342 (92%) segments (6 (2) segments for each patient).

Left ventricular recovery during follow up was observed in 26 (44%) patients. With visual MCE, the area under the receiver operating characteristic curve for left ventricular recovery was 0.77 (95% confidence interval (CI) 0.64 to 0.89). It increased to 0.88 (95% CI 0.79 to 0.96) with quantitative analysis, whereas it was lower with MBG (0.65, 95% CI 0.52 to 0.78). In a logistic regression model including MCE indices, MBG, and AMI size, only a decreasing MCE quantitative index (odds ratio (OR) 0.002, 95% CI 0.0005 to 0.04) and increasing peak creatine kinase (OR 1.007, 95% CI 1.002 to 1.012) were independent predictors of the absence of left ventricular recovery (table 1).

## DISCUSSION

As previously reported, we found better diagnostic accuracy for MCE than for MBG to predict left ventricular recovery after AMI.<sup>3</sup> MBG does not allow assessment of myocardial perfusion itself (that is, tissue blood flow at the capillary level).<sup>4</sup> In addition, MBG is assessed immediately after reperfusion, when reactive hyperaemia can mask microvascular dysfunction, whereas we avoided this period with MCE.

**Abbreviations:** AMI, acute myocardial infarction; CI, confidence interval; MBG, myocardial blush grade; MCE, myocardial contrast echocardiography; OR, odds ratio; TIMI, thrombolysis in myocardial infarction

**Table 1** Logistic regression model evaluating predictors of absence of left ventricular recovery

	Univariate analysis (OR (95% CI))	p Value
Peak CK-MB*	1.007 (1.002 to 1.012)	0.01
Q waves	2.2 (1.2 to 3.8)	0.007
MBG	0.45 (0.26 to 0.85)	0.01
Visual MCE	0.113 (0.02 to 0.52)	0.005
Quantitative MCE*	0.002 (0.0005 to 0.04)	0.0005

\*Independent predictor in multivariate analysis.  
CI, confidence interval; CK, creatine kinase; MBG, myocardial blush grade; MCE, myocardial contrast echocardiography; OR, odds ratio.

In our opinion, the improvement in diagnostic accuracy obtained with quantitative MCE is based on a better assessment of myocardial blood flow. Visual MCE analysis relies on MCE peak signal intensity assessment (A) but does not take into account the other component of myocardial blood flow (blood velocity). Quantitative analysis can estimate blood velocity through the rate of rise of signal intensity and therefore provide a true MCE derived myocardial blood flow index.<sup>5</sup> This technique can therefore improve diagnosis of microvascular dysfunction and risk stratification of patients with AMI.

#### ACKNOWLEDGEMENTS

We thank C Allué, M Díaz, E Alberruche, and A Barrio for their assistance.

#### Authors' affiliations

E Pérez-David, M A García-Fernández, J Quiles, P Mahía, J L López-Sendón, E López de Sa, M Moreno, M Desco, E García, Hospital Gregorio Marañón, Madrid, Spain  
M J Ledesma, ETSIT-Universidad Politécnica de Madrid, Madrid, Spain

Competing interests: None declared.

The Ethics Committee for Clinical Studies of Hospital Gregorio Marañón approved the study.

Correspondence to: Dr Miguel A García-Fernández, Hospital Gregorio Marañón, C/Doctor Esquerdo, 46, 28007 Madrid, Spain; magfeco@primus.es

Accepted 18 August 2005

#### REFERENCES

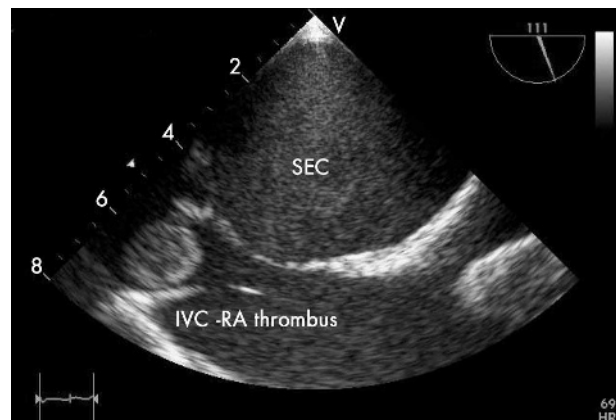
- 1 Shimoni S, Frangogiannis NG, Aggeli CJ, *et al.* Identification of hibernating myocardium with quantitative intravenous myocardial contrast echocardiography: comparison with dobutamine echocardiography and thallium-201 scintigraphy. *Circulation* 2003;**107**:538–44.
- 2 Gibson CM, Cannon CP, Murphy SA, *et al.* Relationship of the TIMI myocardial perfusion grades, flow grades, frame count, and percutaneous coronary intervention to long-term outcomes after thrombolytic administration in acute myocardial infarction. *Circulation* 2002;**105**:1909–13.
- 3 Lepper W, Sieswerda GT, Vanoverschelde JL, *et al.* Predictive value of markers of myocardial reperfusion in acute myocardial infarction for follow-up left ventricular function. *Am J Cardiol* 2001;**88**:1358–63.
- 4 Kaul S. Coronary angiography cannot be used to assess myocardial perfusion in patients undergoing reperfusion for acute myocardial infarction. *Heart* 2001;**86**:483–4.
- 5 Wei K, Jayaweera AR, Firoozan S, *et al.* Quantification of myocardial blood flow with ultrasound-induced destruction of microbubbles administered as a constant venous infusion. *Circulation* 1998;**97**:473–83.

## IMAGES IN CARDIOLOGY

doi: 10.1136/hrt.2005.078030

### Thrombus at the junction of the inferior vena cava and right atrium: a contraindication for transfemoral percutaneous mitral commissurotomy

A 37 year old woman, with severe rheumatic mitral stenosis, chronic atrial fibrillation (AF) and a history of recurrent strokes, presented with troponin T positive unstable angina. She was on long term oral anticoagulants and had an international normalised ratio (INR) within target range. An angiogram showed normal coronary arteries. Percutaneous mitral commissurotomy (PTMC) was planned, as the valve was found pliable on transthoracic echocardiography. Transoesophageal echocardiography revealed dense spontaneous echo contrast, but no clot in the left atrium. An 18 × 16 mm thrombus was seen at the entry of the inferior vena cava (IVC) to the right atrium (RA). The thrombus was presumably related to the AF, as there was no deep vein thrombosis or any other evident thrombophilic states. Transjugular PTMC was not planned due to lack of previous experience in the centre. An elective mitral valve replacement and clot removal from the inferior vena cava was done under circulatory arrest. The IVC-RA junction can be an uncommon site of isolated thrombus in rheumatic patients with AF, and can hinder a successful transfemoral PTMC in an otherwise pliable mitral valve.



S Bohora  
K K N Namboodiri  
K M Krishnamoorthy  
kknamboodiri@sctimst.ac.in