

Infection Dynamics and Clinical Features of Cryptosporidiosis in SCID Mice

JAN R. MEAD,^{1,2*} NURÇAN ILKSOY,¹ XIANGDONG YOU,¹ YELENA BELENKAYA,¹
MICHAEL J. ARROWOOD,³ MICHAEL T. FALLON,^{2,4} AND RAYMOND F. SCHINAZI^{1,2}

Departments of Pediatrics¹ and Pathology,⁴ Emory University School of Medicine, Atlanta, Georgia 30022; Veterans Administration Medical Center, Decatur, Georgia 30033²; and Division of Parasitic Diseases, National Center for Infectious Diseases, Centers for Disease Control and Prevention, Atlanta, Georgia 30333³

Received 14 October 1993/Returned for modification 16 November 1993/Accepted 28 January 1994

Cryptosporidial infections in severe combined immune deficient (SCID) mice produce a chronic disease state which in the later stages leads to extraintestinal involvement and hepatic dysfunction. To further characterize the infection dynamics in this model and monitor the changes in the hepatic system, a dose titration of the oocyst inoculum was performed and alkaline phosphatase levels in the sera were assayed. Ten SCID mice per dose were inoculated with 10^3 , 10^4 , 10^5 , 10^6 , or 10^7 oocysts. Oocyst shedding in the feces was quantified by microscopic enumeration. Mice inoculated with 10^6 oocysts and those inoculated with 10^7 oocysts demonstrated similar oocyst shedding patterns, but the 10^7 -oocyst group exhibited signs of distress (e.g., weight loss and icterus) earlier. The intensity of the infection increased markedly approximately 14 days postinoculation (p.i.) and continued to increase steadily over the next 6 weeks. Inoculation with lower oocyst doses produced a delay in patency (e.g., it occurred 7 days later with the 10^5 -oocyst inoculum and 14 days later with the 10^4 -oocyst inoculum). Mean serum alkaline phosphatase levels in the 10^7 -oocyst group were more than twice control values at 5 weeks p.i. and continued to increase over the next 8 weeks. Oocyst doses and alkaline phosphatase levels were positively correlated with hepatobiliary colonization ($r = 0.71$) and liver necrosis ($r = 0.65$) at 13 weeks p.i. A strong positive correlation between hepatobiliary colonization and liver necrosis at 13 weeks p.i. ($r = 0.87$) was observed.

Cryptosporidium parvum is an opportunistic protozoan that causes short-term, self-limiting diarrheal illness in immunocompetent hosts. Human immunodeficiency virus type 1-infected individuals with cryptosporidiosis, however, differ from immunocompetent individuals in that their infections may become chronic and severe and may involve anatomic sites outside the gastrointestinal tract, such as the epithelium of the gallbladder, pancreas, and biliary ducts. Currently, there is no effective treatment for this disease, and as a consequence approximately 50% of the AIDS patients that acquire the disease do not recover from the infection (4).

The incidence of extraintestinal cryptosporidiosis in AIDS patients is not known but has been reported to be approximately 15% in a New York hospital (4) and as high as 46% in a Paris hospital (5). Patients from the latter institution experienced diarrhea with a mean duration of 7 months or longer. There is strong evidence that extraintestinal cryptosporidiosis contributes to the mortality of AIDS patients and is responsible for relapsing or recurring infections. Approximately half of all human immunodeficiency virus-infected individuals develop recurrent cryptosporidiosis. It is not known if these are reinfections or if a biliary reservoir contributes to the chronicity. Clinical deterioration (including that of those who relapsed) occurred in 70% of those patients with bile duct involvement (5).

Elevated liver enzyme levels have been associated with biliary cryptosporidiosis in AIDS patients. Increases in serum aspartate transaminase and alanine aminotransferase levels (14) and elevated alkaline phosphatase (AP) levels (6-8) have

been reported for AIDS patients with biliary cryptosporidiosis. More recently, serum AP and gamma glutamyl transferase levels were reportedly increased, while serum bilirubin and transaminase levels remained normal (4). In a study by McGowan and colleagues (10) involving 38 AIDS patients, the majority of the patients with cryptosporidiosis (57%) had abnormal liver parameters (increased aspartate transaminase and AP levels). All but 1 of the 10 patients monitored, including 4 patients whose diarrhea was in remission, still had abnormal liver parameters 2 months later. Although other factors (e.g., hepatitis B or C virus infection or drug toxicity) may be responsible for the liver abnormalities, 5 of the 16 patients had no other AIDS-associated diagnosis at the onset of cryptosporidial diarrhea.

Given the potentially severe outcome of cryptosporidial infections in immunosuppressed or immunocompromised patients, existing animal models for chronic cryptosporidiosis need to be better characterized and refined for use in evaluating potential therapeutic agents and for the study of host immune responses during persistent infections. These models should reflect the range of immunodeficiencies manifest in human immunodeficiency virus-infected patients and the different stages of the disease that may require treatment. In particular, later stages of the infection in an animal model have not been fully characterized. To correct these and other shortcomings, we have further developed our adult animal model using severe combined immune deficient (SCID) mice (12) by investigating dose responses to oocyst inocula and monitoring changes that occur in the hepatobiliary system in the later stages of infection. To investigate whether serum liver enzyme levels increase in the SCID murine model and whether these increases are predictive of extraintestinal colonization, serum samples were collected for analysis at 5, 9, and 13 weeks postinfection (p.i.). Pathologic features resulting from chronic

* Corresponding author. Mailing address: VA Medical Center, Medical Research 151, 1670 Clairmont Rd., Decatur, GA 30033. Phone: (404) 728-7711. Fax: (404) 728-7726.

infection of the small and large intestines and colonization of extraintestinal sites (e.g., hepatobiliary duct epithelium) were correlated with physical signs and changes in the levels of the liver enzyme AP in serum.

MATERIALS AND METHODS

Production of *C. parvum* oocysts. The *C. parvum* isolate used for this study was the IOWA bovine isolate originally obtained from Harley Moon (National Animal Disease Center, Ames, Iowa). The IOWA isolate was generated in newborn holstein bull calves as previously described (1). Newborn calves were placed in isolation quarters in customized pens and infected at 2 days of age with approximately 10^8 oocysts. All fecal material passed during the peak of oocyst shedding (days 5 to 12 p.i.) was collected and stored at 4°C in 2.5% potassium dichromate ($K_2Cr_2O_7$) aqueous solution.

Purification of oocysts was initiated by sequential passage of fecal material through stainless steel sieves having progressively finer pore sizes to a final mesh size of 230 (63 μ m pore size). Further oocyst purification was achieved by sequential centrifugation procedures involving discontinuous sucrose gradients (1.064 g/ml over 1.103 g/ml) as previously described (1). Purified oocysts were stored at 4°C in 2.5% $K_2Cr_2O_7$ aqueous solution. Oocysts used to inoculate mice were ≤ 4 months old.

Animals. Female C.B-17 *scid/scid* (SCID) mice, ages 6 to 8 weeks, were purchased from the University of Wisconsin Gnotobiotic Laboratory (Madison). Mice were maintained at the American Association for the Accreditation of Laboratory Animal Care-accredited Veterans Administration Medical Center (Decatur, Ga.) animal facility in an isolation room under pathogen-free conditions. Mice were housed in microisolator cages (Nalgene Labware, Rochester, N.Y.) in high-efficiency particulate air (HEPA)-filtered laminar flow racks (Lab Products, Inc., Maywood, N.J.). All cages, food, water, and bedding were sterilized before use. Sterilized surgical clothing (i.e., mask, gown, and gloves) was worn when mice were handled. All manipulations were performed in a HEPA-filtered hood.

All SCID mice were evaluated for immunologic "leakiness" (production of immunoglobulin). Serum samples were collected, diluted appropriately, and assayed in a commercially available radial immunoassay system (The Binding Site, Birmingham, England) for quantification of murine immunoglobulin G and immunoglobulin M.

A random subset of the mice were evaluated for concurrent infection by other agents. Specifically, necropsy results (i.e., results of histologic evaluation by a pathologist) and ImmunoComb screening (Charles River) excluded mouse hepatitis virus infection as a factor in this study.

Experimental design. Groups of 10 SCID mice per dose were infected as adults (≥ 6 weeks of age) with 10^3 , 10^4 , 10^5 , 10^6 , or 10^7 oocysts by gastric intubation on day 0. Mouse fecal samples were collected at 3- to 4-day intervals to determine oocyst shedding characteristics by using an immunofluorescence assay (IFA). Mice were euthanized by cervical dislocation and necropsied at 13 weeks p.i. for histologic analyses of tissue samples. Blood was collected at 5, 9, and 13 weeks p.i. for assays of immunoglobulin levels and serum AP levels. Oocyst shedding and tissue parasite load data were evaluated by linear regression for possible correlation with pathologic features and physical signs (i.e., body weight, icterus, emaciation, skin turgor, diarrhea, and AP levels).

An additional 30 SCID mice were inoculated with 10^6 oocysts as adults (≥ 6 weeks of age) in order to study the long-term effects of chronic cryptosporidiosis. Mouse fecal

samples were collected at weekly intervals to determine oocyst shedding characteristics by using the IFA mentioned above. Blood was collected at 4, 7, and 13 weeks p.i. for assays of immunoglobulin levels (as described above) and assays of AP levels (see below) using a modified AP kit (Sigma Chemical Co., St. Louis, Mo.). Histologic analyses of the distal small intestine and proximal large intestine, stomach, pancreas, liver, and gallbladder were performed 24 weeks p.i. or earlier. Animals were euthanized by cervical dislocation and necropsied before 24 weeks p.i. if they displayed signs of imminent death, including severe icterus or wasting, or if serum AP levels indicated significant liver damage. Oocyst shedding and tissue parasite load data were correlated with pathologic features and physical signs.

Quantification of oocysts in the feces. The parasite load was monitored by quantifying oocysts in mouse fecal samples with an oocyst-specific IFA (2, 3). Briefly, fecal pellets were collected into sterile microcentrifuge tubes and suspended in 10% buffered formalin (approximately 400 μ l of buffered formalin per fecal pellet). The fecal pellets were homogenized by extensive vortexing, and the suspension was diluted to 1 ml with saline and centrifuged at $400 \times g$ for 2 min. Supernatants were discarded, and the pellets were resuspended in 1 ml of saline. Ethyl acetate (300 μ l) was added to each tube, and then the tubes were vortexed for 15 s and centrifuged at $400 \times g$ for 2 min. The ethyl acetate plugs and supernatants were gently aspirated, and the fecal sediment was resuspended in saline. The saline diluent volume was varied with each sample to achieve a 1:1 ratio of fecal sediment to saline. Aliquots (2 μ l) were placed on the wells of a 10-well slide (Medical Packaging Corp., Camarillo, Calif.) and allowed to dry. Slides were heat fixed and processed through the IFA (2) before being evaluated by epifluorescence microscopy. Oocysts were enumerated at a magnification of $\times 250$ by counting the numbers of fluorescing oocysts in 30 randomly selected microscopic fields in each well. Numbers were summed and analyzed statistically as described below.

Histological examination of tissues. Tissue samples were removed from euthanized mice and fixed in 10% buffered formalin. Fixed tissues were embedded in paraffin, sectioned, and stained with hematoxylin-eosin. Small and large intestine tissue sections were examined at a magnification of $\times 250$ and scored as follows: 0, no cryptosporidial organisms observed; +1, few organisms observed (1 to 10 per villus or crypt); +2, moderate colonization (15 to 25 organisms per villus or crypt); +3, large numbers of organisms observed (25 to 35 per villus or crypt); and +4, very heavy colonization (>35 organisms per villus or crypt). The area of colonization (expressed as a percentage of the total area) was estimated for each tissue section, since the parasite was not always uniformly distributed across the tissue. The number of necrotic liver lesions and the area the lesions covered (expressed as a percentage of the total section area) were determined for each tissue section and scored as follows: +1, 1 to 2 lesions ($<10\%$ tissue involvement); +2, 2 to 3 lesions (10 to 20% tissue involvement); +3, 3 to 4 lesions (20 to 30% tissue involvement); and +4, >4 lesions ($>30\%$ tissue involvement).

AP enzyme assay. A commercially available assay for the determination of AP levels in serum samples (Sigma) was used in this study. The kit was adapted for use in a 96-well microtiter plate format and was standardized by using purified AP (Sigma).

Statistical analysis. Oocyst shedding (parasite load) data were evaluated by Student's *t* test and analysis of variance. A correlation table was prepared for the oocyst doses, AP levels, hepatobiliary duct colonization scores, and liver lesion scores.

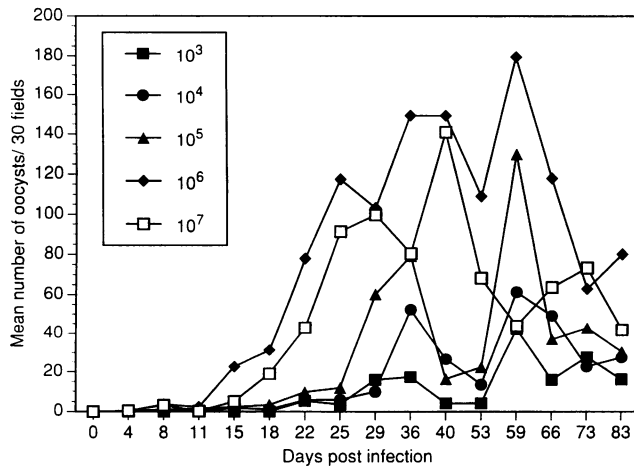


FIG. 1. Oocyst shedding patterns in SCID mice infected with *C. parvum* in five doses (see inset) as assessed by IFA. The declining oocyst levels near the end of the experiment resulted from the loss, due to death or euthanization, of mice shedding high numbers of oocysts.

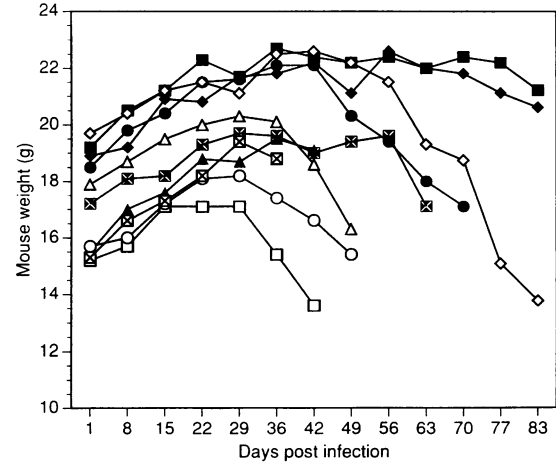


FIG. 2. Weight changes through week 12 p.i. in SCID mice infected with 10^7 *C. parvum* oocysts. Note the declines in weights of individual mice that died or were euthanized before week 12 (84 days). Each symbol represents an individual mouse.

Linear regression was employed to evaluate the significance of the interaction among the variables.

RESULTS

Enumeration of parasite load in the feces. The oocyst shedding patterns of the mice infected with five different oocyst doses are summarized in Fig. 1. The mouse group inoculated with 10^6 oocysts and the mouse group inoculated with 10^7 oocysts demonstrated similar oocyst shedding patterns. The intensity of the infection increased markedly after day 14 p.i. and continued to increase steadily over the next 6 weeks. Infections induced by lower oocyst doses exhibited longer prepatent periods (e.g., 7 days longer for the 10^5 -oocyst inoculum), and a longer period of time was required for parasite loads to increase to the levels observed in mice inoculated with 10^6 or 10^7 oocysts. Mice inoculated with 10^3 oocysts and mice inoculated with 10^4 oocysts exhibited even longer delays in the onset of oocyst shedding and had substantially lower parasite loads. Decreases in the mean oocyst shedding rates at 50 to 70 days for groups receiving the largest inocula (i.e., 10^6 and 10^7 oocysts) coincided with the loss (by death or euthanization) of mice shedding high numbers of oocysts.

Weight loss. Significant weight loss was not evident upon examination of the mouse group mean weights. However, individual mice in the 10^7 -oocyst group (Fig. 2) and in the 10^6 -oocyst group lost 3 to 4 g 2 to 3 weeks before death or euthanization. This pattern of weight loss was also observed for the other mouse groups as individuals deteriorated clinically (i.e., developed icterus and dehydration).

Liver enzyme levels. Mean AP levels in the sera of SCID mice are shown in Fig. 3. A marked increase in the mean enzyme level of mice infected with 10^7 oocysts was evident by 5 weeks p.i., and this level continued to increase over the next 8 weeks to six times that for control mice. Serum AP levels were significantly higher than those of controls at 13 weeks p.i. ($P < 0.05$). The increase in the mean AP level was largely contributed by marked increases in levels in one-third of the mice at 5 weeks p.i. and in three-quarters of the mice at 13 weeks p.i. Smaller increases in the mean enzyme levels observed at 13 weeks p.i. for other infected groups (e.g., the

10^6 -oocyst group) were due to two or three high individual values in each group.

In a separate experiment in which 30 mice were infected with 10^6 oocysts, infections were monitored for up to 4 months. Oocyst shedding levels rose gradually, as previously observed, with a marked increase at 12 to 13 weeks p.i. A corresponding increase in the AP levels is presented in Fig. 4. As observed with the previous experimental group, the increase in AP preceded death or necessary euthanization by approximately 2 to 3 weeks.

The group means do not indicate the differences in serum AP levels between mice with and mice without hepatobiliary colonization or pathology. See Table 1 for a comparison of the AP levels in these mice.

Pathology. Heavy cryptosporidial colonization in both the small intestine (i.e., in the terminal ileum) and the colon was observed for all titration groups by 13 weeks p.i. Variable

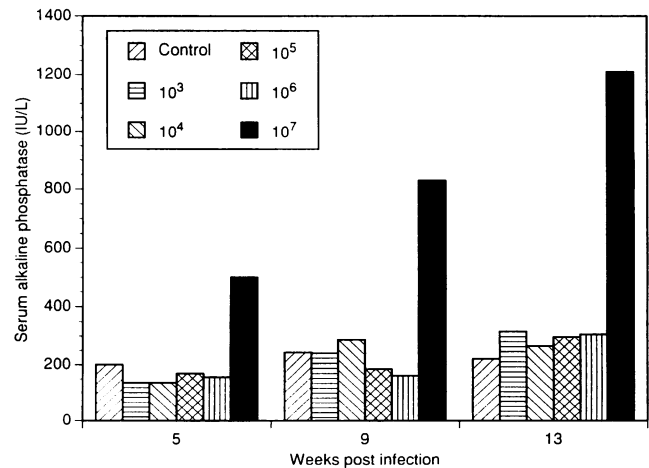


FIG. 3. Mean serum AP levels at 5, 9, and 13 weeks p.i. in SCID mice infected with *C. parvum* oocysts in five doses (see inset). Serum AP levels for mice infected with 10^7 oocysts were significantly higher than those for controls at 13 weeks p.i. ($P < 0.05$).

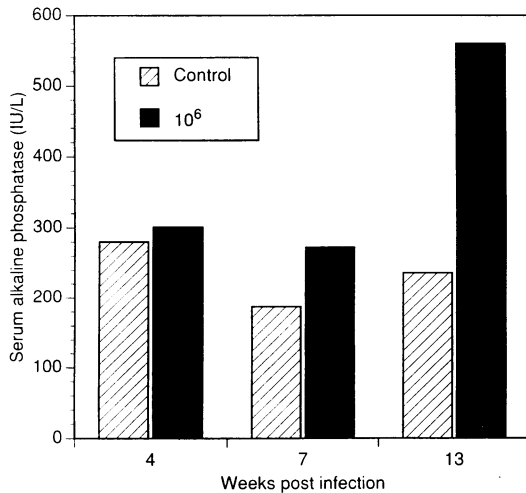


FIG. 4. Mean serum AP levels at 4, 7, and 13 weeks p.i. in SCID mice infected with 10^6 *C. parvum* oocysts compared with those in uninfected controls.

colonization of the stomach prevented useful correlation of this colonization with the inoculum dose. The percentages of mice displaying hepatic lesions and colonization of the hepatobiliary ducts are presented in Table 1. These data include the number of hepatic lesions (necrosis score), the intensity of hepatobiliary infection (colonization score), and the serum AP levels observed for the mice with and the mice without hepatobiliary involvement. Moderate numbers of mice (30 to 40%) in the 10^3 - to 10^5 -oocyst groups exhibited colonization of the hepatic ducts and hepatic lesions by 13 weeks p.i. The majority of the mice (80 to 90%) in the 10^7 -oocyst group demonstrated liver involvement, with moderate to severe numbers of lesions and heavy colonization of the hepatic ducts (Table 1).

Table 2 summarizes the linear regression and correlation results from the comparison of oocyst dose, hepatobiliary colonization score, liver necrosis score, and serum AP level. A log transform of the oocyst dose values was applied before analyses were performed. A strong positive correlation ($r = 0.87$) between hepatobiliary colonization and liver necrosis was

TABLE 2. Correlation and linear regression analyses of oocyst dose versus hepatobiliary colonization score, liver necrosis score, and serum AP levels

Independent data	Dependent data	N ^a	R ^b	Significance of F ^c
Oocyst dose	AP level at 5 wk p.i.	58	0.18	0.17
Oocyst dose	AP level at 9 wk p.i.	46	0.15	0.31
Oocyst dose	AP level at 13 wk p.i.	49	0.32	<0.05
Oocyst dose	Hepatobiliary colonization score	59	0.53	<0.001
Oocyst dose	Liver necrosis score	59	0.46	<0.001
Oocyst dose + AP level at 13 wk p.i.	Hepatobiliary colonization score	49	0.71	<0.001
Oocyst dose + AP level at 13 wk p.i.	Liver necrosis score	49	0.65	<0.001
Hepatobiliary colonization score	Liver necrosis score	59	0.87	<0.001

^a Number of mice with paired data.

^b Correlation coefficient.

^c Significance of regression based on F distribution. Values less than 0.05 are significant.

observed at 13 weeks p.i. (i.e., as the colonization score increased, the corresponding liver necrosis score increased). The oocyst dose was positively correlated with colonization and liver necrosis at 13 weeks p.i. (i.e., the significance of regression statistic F was <0.001). The appearance of clinical signs (icterus and dehydration) occurred earliest in the 10^7 -oocyst group (i.e., at 5 to 6 weeks p.i.).

Levels of AP in serum were elevated in mice with hepatobiliary involvement (Table 1). The enzyme levels at 5, 9, and 13 weeks p.i. were positively correlated with the oocyst doses, (i.e., as the dose increased, the corresponding enzyme level increased). Regression analysis was significant for AP levels at 13 weeks p.i. (significance of F, <0.001). AP levels at 13 weeks p.i. were positively correlated with hepatobiliary colonization and liver necrosis (significance of F for both, <0.001). Including the oocyst dose with AP levels at 13 weeks p.i. yielded a stronger positive correlation with bile duct colonization and liver necrosis (significance of F for both, <0.001). We were unable to perform comparable analyses of gallbladder coloni-

TABLE 1. Histologic localization of cryptosporidial organisms in *C. parvum*-infected SCID mice 13 weeks following inoculation with five doses of oocysts

Oocyst dose	Site of infection				Amt of AP (IU/liter) ^a in:	
	Liver		Hepatic duct		Negative mice ^d	Positive mice ^e
	% of mice with necrosis	Necrosis score ^{a,b}	% of mice colonized	Colonization score ^{a,c}		
0	0	0	0	0	183 ± 18	NA ^f
10^3	40	1.8 ± 0.3	30	1.6 ± 0.8	188 ± 61	507 ± 182
10^4	30	2.0 ± 0.7	40	2.8 ± 0.6	149 ± 34	438 ± 193
10^5	40	2.3 ± 0.3	40	3.0 ± 0.4	132 ± 9	626 ± 286
10^6	44	1.1 ± 0.5	78	2.6 ± 0.5	125 ± 33	379 ± 146
10^7	80	2.6 ± 0.5	90	3.0 ± 0.4	NA	1,211 ± 605

^a Mean ± standard error of the mean at 13 weeks p.i.

^b Number of hepatic lesions.

^c Intensity of hepatobiliary infection.

^d Mice with no liver lesions or hepatic duct colonization.

^e Mice with liver lesions and/or hepatic duct colonization.

^f NA, not available.

zation because of limited access to well-sectioned gallbladder tissue. Nevertheless, marked colonization of the gallbladder and bile ducts was observed for mice with overt hepatic lesions.

DISCUSSION

SCID mice become chronically infected with *C. parvum* after inoculation with 10^6 or 10^7 viable oocysts (9, 11–13). In the present study, we employed an adult SCID mouse model of cryptosporidiosis to examine the relationship between the oocyst dose and the resulting pathology. Considerable variability among the numbers of oocysts shed by mice in any one group was evident by 4 weeks p.i. We did not find, however, great fluctuation in numbers shed by individual mice from week to week. Consequently, the mice were monitored individually. Delays in the onset of oocyst shedding were observed in lower-dose groups (10^3 to 10^5 oocysts) but not in the 10^6 - and 10^7 -oocyst groups. We observed that 10^6 oocysts was the lowest dose that achieved 100% infectivity and that this dose maintained the shortest prepatency period. These observations confirm our earlier report that 10^6 oocysts yielded >95% infection in adult SCID mice (12). No significant difference in oocyst shedding between the 10^6 - and 10^7 -oocyst groups was demonstrated by IFA. However, mice inoculated with 10^7 oocysts experienced severer infections as evidenced by earlier increases in serum AP levels (i.e., by 5 weeks p.i.), the severity of hepatic lesions, and elevated parasite loads in the hepatobiliary ducts at earlier time points. Weight loss and death also occurred earlier in the 10^7 -oocyst group.

Elevated AP levels were detected as early as 5 weeks p.i. in the mice infected with 10^7 parasites. Increases in AP were also observed in the 10^6 -oocyst group, but these were delayed (detected at 13 weeks p.i.). Although not all mice within each oocyst inoculum group demonstrated increased AP levels, we found that for those that did, the increases appeared approximately 2 to 3 weeks before death. This enzyme may be a useful, noninvasive indicator of extraintestinal colonization and hepatic necrosis in the SCID mouse model.

The terminal (i.e., lethal) stages of cryptosporidial infections in the SCID mouse model were investigated to characterize the relationship between oocyst dose and extraintestinal involvement. We were particularly interested in determining whether the later stages of infection in the murine model would produce clinical features found in human immunodeficiency virus-infected patients and in determining whether a noninvasive test to predict the colonization of the gallbladder and hepatobiliary duct epithelium could be developed. We observed that a subset of the mice in all oocyst inoculum groups eventually developed extraintestinal infections. Mice inoculated with 10^7 oocysts showed the earliest (5 weeks p.i.) development of hepatobiliary colonization. This group also had the highest proportion (90%) of mice exhibiting extraintestinal involvement within 13 weeks. AP in the serum increased more rapidly and to higher levels in the 10^7 -oocyst group than in the other inoculum groups. The strong correlation between the oocyst dose, the AP level in the serum, hepatobiliary colonization, and liver lesions strongly suggests that the serum AP level can be used as an indicator of extraintestinal infection and consequent liver damage.

The combination of an appropriate oocyst dose and the monitoring of serum AP levels allows the SCID mouse model to be used to evaluate potential anticryptosporidial agents, especially those that may work systemically as opposed to agents that are active only in the lumen of the gastrointestinal tract.

The SCID mouse model of lethal, extraintestinal cryptosporidiosis should have application beyond the evaluation of potential therapeutic agents. Mead and colleagues showed that SCID mice recover from chronic cryptosporidial infections after immunologic reconstitution during the acute stage (approximately 4 weeks p.i.) (11). By applying the modifications to the SCID model described here, it should be possible to use immunologic reconstitution to study the immunologic mechanisms responsible for recovery from lethal, extraintestinal infections.

ACKNOWLEDGMENTS

We thank Dirk Dillehay (Emory University) for pathological assessment and Sonya Webb for excellent technical assistance with histology specimens.

This work was supported by National Institutes of Health contract NO1-AI-25144 and the Department of Veteran Affairs.

REFERENCES

1. Arrowood, M. J., and C. R. Sterling. 1987. Isolation of *Cryptosporidium* oocysts and sporozoites using discontinuous sucrose and isopycnic Percoll gradients. *J. Parasitol.* **73**:314–319.
2. Arrowood, M. J., and C. R. Sterling. 1989. Comparison of conventional staining methods and monoclonal antibody-based methods for *Cryptosporidium* oocyst detection. *J. Clin. Microbiol.* **27**:1490–1495.
3. Garcia, L. S., T. C. Brewer, and D. A. Bruckner. 1987. Fluorescence detection of *Cryptosporidium* oocysts in human fecal specimens by using monoclonal antibodies. *J. Clin. Microbiol.* **25**:119–121.
4. Gellin, B. G., and R. Soave. 1992. Coccidian infections in AIDS. Toxoplasmosis, cryptosporidiosis, and isosporiasis. *Med. Clin. North Am.* **76**:205–234.
5. Gerard, L., G. Daleine, P. Longuet, J. Le Bras, C. Lepout, and J. L. Vilde. 1993. Intestinal cryptosporidiosis in 37 HIV infected patients: prognostic significance of biliary tract involvement, abstr. WS-B13-4, p. 56. Abstr. Ninth International Congress on AIDS 1993.
6. Gross, T. L., J. Wheat, M. Bartlett, and K. W. O'Connor. 1986. AIDS and multiple system involvement with *Cryptosporidium*. *Am. J. Gastroenterol.* **81**:456–458.
7. Hinnant, K., A. Schwartz, H. Rotterdam, and C. Rudski. 1989. Cytomegaloviral and cryptosporidial cholecystitis in two patients with AIDS. *Am. J. Surg. Pathol.* **13**:57–60.
8. Kahn, D. G., J. M. Garfinkle, D. C. Klonoff, L. J. Pembroke, and D. J. Morrow. 1987. Cryptosporidial and cytomegaloviral hepatitis and cholecystitis. *Arch. Pathol. Lab. Med.* **111**:879–881.
9. Kuhls, T. L., R. A. Greenfield, D. A. Mosier, D. L. Crawford, and W. A. Joyce. 1992. Cryptosporidiosis in adult and neonatal mice with severe combined immunodeficiency. *J. Comp. Pathol.* **106**:399–410.
10. McGowan, I., A. S. Hawkins, and V. D. Weeler. 1993. The natural history of cryptosporidial diarrhoea in HIV-infected patients. *AIDS* **7**:349–354.
11. Mead, J. R., M. J. Arrowood, M. C. Healey, and R. W. Sidwell. 1991. Cryptosporidial infections in SCID mice reconstituted with human or murine lymphocytes. *J. Protozool.* **38**:S59–S61.
12. Mead, J. R., M. J. Arrowood, R. W. Sidwell, and M. C. Healey. 1991. Chronic *Cryptosporidium parvum* infections in congenitally immunodeficient SCID and nude mice. *J. Infect. Dis.* **163**:1297–1304.
13. Perryman, L. E., K. A. Kegerreis, and P. H. Mason. 1993. Effect of orally administered monoclonal antibody on persistent *Cryptosporidium parvum* infection in scid mice. *Infect. Immun.* **61**:4906–4908.
14. Schneiderman, D. J., J. P. Cello, and F. C. Laing. 1987. Papillary stenosis and sclerosing cholangitis in the acquired immunodeficiency syndrome. *Ann. Intern. Med.* **106**:546–549.