

In our patient it would not have been possible to dissect the cyst away from the vessel wall, but in two of the reported cases (Atkins and Key, 1947; Holmes, 1960) the cyst was enucleated substantially intact, the specimen resembling a myxoma or ganglion. We therefore prefer to call the disease "cystic myxomatous degeneration of the popliteal artery." The myxomatous type of case may represent a later stage in pathogenesis with development of a definite lining to the cyst wall.

Treatment

Where stenosis alone is present, without secondary thrombosis, either dissection and excision or incision and evacuation of the cyst is followed by return of normal pulsation and blood-flow.

Where obstruction due to the cyst has produced secondary thrombosis and a block of the arterial lumen either excision and grafting or thrombo-endarterectomy will be required. All reported cases to date have been grafted.

A five-year follow-up of these would be useful in order to know if evacuation leads to aneurysm formation and if grafts still remain patent. The case of Tytgat *et al.* (1958), in which recrudescence of symptoms occurred after four months, suggests that grafts may have a rate of failure similar to that found in atherosclerosis.

Summary

A case of cystic myxomatous degeneration of the popliteal artery is described. The literature on this condition is reviewed.

This is a rare cause of intermittent claudication in young adults which may be readily confused with Buerger's disease.

The cardinal features of the disease are:

Aetiology: It is a condition of unknown pathogenesis occurring in young adults, especially manual workers in heavy industry. Females are occasionally affected.

Clinical picture: The onset is sudden with cramps in the leg, followed by typical intermittent claudication. Signs of ischaemia are present and may be exacerbated by full flexion of the knee. Arteriography shows a smooth-walled stenosis or complete block in the popliteal artery with an otherwise normal arterial tree.

Pathology: A unilocular or multilocular mucin-containing cyst is present within the wall of the artery, compressing the lumen.

Treatment: In most cases evacuation of the cyst is sufficient. Thrombo-endarterectomy or excision and grafting may be necessary when secondary thrombosis of the lumen has occurred.

Prognosis: The immediate prognosis after surgical treatment appears to be excellent. The long-term prognosis is as yet unknown.

We wish to thank Mr. W. P. Greening, under whose care the initial investigations were performed, for permission to publish this case. We also thank Miss P. Turnbull for the medical photography.

REFERENCES

- Andersson, T., Gothman, B., and Lindberg, K. (1959). *Acta radiol. (Stockh.)*, **52**, 455.
 Atkins, H. J. B., and Key, J. A. (1947). *Brit. J. Surg.*, **34**, 426.
 Ejrup, B., and Hierton, T. (1954). *Acta chir. scand.*, **108**, 217.
 Hierton, T., and Lindberg, K. (1957). *Ibid.*, **113**, 72.
 ——— and Rob, C. (1957). *Brit. J. Surg.*, **44**, 348.
 Holmes, J. G. (1960). *J. Amer. med. Ass.*, **173**, 654.
 Ishikawa, K., Mishima, Y., and Kobayashi, S. (1961). *Angiology*, **12**, 357.
 Patel, J., Faquet, J., and Piwnica, A. (1958). *Presse méd.*, **66**, 1164.
 Sutton, D. (1962). *Arteriography*, p. 84. Livingstone, Edinburgh.
 Tytgat, H., Derom, F., and Galinsky, A. (1958). *Acta chir. belg.*, **57**, 188.

INTERMITTENT CLAUDICATION DUE TO CYSTIC DEGENERATION OF POPLITEAL ARTERY

BY

DEREK G. LAMBLEY, M.B., B.Sc., F.R.C.S.
 Northampton General Hospital

Since Atkins and Key (1947) reported a case of myxomatous tumour arising in the adventitia of the left external iliac artery in 1946, only six other cases of this condition have been reported. In four of these the popliteal artery was the site of the degeneration (Ejrup and Hierton, 1954; Hierton, Lindberg, and Rob, 1957).

Case Report

A master builder aged 47 was first seen in June, 1962, complaining of cramp in the left leg when he walked 50 yards, which was relieved by four to five minutes' rest. The intermittent claudication had been present for six weeks and was of sudden onset. He found himself unable to mow his lawn or to climb ladders at work. He sought medical advice and was prescribed bed rest, anticoagulants, and antispasmodics for two weeks. When he resumed activity at the end of this time the pain was rather worse than before. I first saw him six weeks after the onset of his symptoms, when the limb appeared completely normal at rest. Femoral, popliteal, dorsalis pedis, and posterior tibial pulses were all easily palpable and equal in volume compared with those of the normal limb. The popliteal artery on the left side was easily palpable and appeared to be more prominent and broader than the right artery. A provisional diagnosis of popliteal aneurysm was made

and he was admitted to Northampton General Hospital for investigation.

Wassermann reaction and Reiter's complement-fixation test were negative. There was some evidence of mitral stenosis and the blood-pressure was 154/76. A percutaneous left femoral arteriogram, performed on July 2, revealed a little narrowing of the femoral artery just above the femoral condyle with a rather abrupt deviation of the vessel laterally at this level. Otherwise the appearances were normal. There was no evidence of obstruction or arteriosclerotic lesion, and the appearances were said to favour an extrinsic pressure rather than an intrinsic vascular lesion (Fig. 1).

In view of the clinical abnormality of the popliteal artery its exploration seemed justifiable, since I felt there was interference with the arterial circulation at this level in spite of the comparatively normal arteriographic picture.

Operation.—The left popliteal fossa was explored under general anaesthesia (Dr. F. F. Waddy) on July 4. The popliteal artery showed a bluish uniform enlargement over a distance of 5 cm., the greatest thickness of which was 2 cm. The whole tumour pulsed. The upper limit of abnormality appeared to be at the lower end of Hunter's canal, the lower limit about 1.5 cm. above the arterial bifurcation. The condition was not recognized as a cystic degeneration of the popliteal artery and was regarded as an aneurysm. It was resected with as little

interference with the collateral circulation as possible. A Teflon prosthesis was inserted between the common femoral artery and the lower part of the popliteal artery 1 cm. above its bifurcation, the proximal anastomosis being end-to-side and the distal anastomosis end-to-end. The subsequent course proved uneventful; the patient made a rapid recovery and has been completely relieved of his symptoms.

The pathological report on the specimen (Dr. W. E. Bryan) was as follows: "A specimen of the popliteal artery. At one side of the artery there is a cystic space filled with mucoid

material. The cyst is lined by flattened cells. The wall is mainly fibrous with some smooth muscle and a little elastic tissue. The structure does not suggest an origin from a muscular artery, but it could be derived from a vein, although the amount of elastic tissue in the wall is less than would be expected. The popliteal artery shows eccentric internal thickening and partial reduplication of the internal elastic lamina, with patchy fibrosis of the media. There is no evidence of aneurysm or dilatation."

Discussion

In this case it is apparent that tension in the wall of the artery produced by the presence of the cyst prevented dilatation of the artery at the time of exercise. This produced relative ischaemia and consequent intermittent claudication. In previous cases (Hiertonn *et al.*, 1957) arteriography always demonstrated some stenosis of the affected artery. However, Jaquet and Meyer-Burgdorff (1960) stated that a cyst may manifest itself as a localized stenosis which allows the passage of blood only at the very peak level of systolic blood-pressure. It may therefore be possible to take a series of x-ray films some of which may illustrate stenosis and others the normal calibre of the artery.

In the present case no abnormality was found in the calibre of the artery, nor was any stenosis produced. It is apparent that the arterial flow was not affected until at the time of exercise the cyst prevented the usual increase in flow of blood. It is suggested that in similar cases if there is evidence of thickening in the region of the popliteal artery there is a case for exploration of the artery from this point of view alone, even if the arteriogram is normal. It would also be possible in many cases to preserve the artery and to deal with the condition either by simple incision or by an attempt to dissect the cyst away from the artery. If this fails and there is some necrosis of the media as has been reported (Hiertonn *et al.*, 1957), then it is probably best to excise the affected segment and to restore continuity either by a short Teflon prosthesis or by a vein graft (Taylor, 1962).

Summary

A case of cystic degeneration of the popliteal artery, an apparently rare cause of intermittent claudication, is reported. Arteriography showed very little deviation from normal. Tension of the cyst produced impairment of the arterial flow only at the time of exercise.

Evidence of thickening in the region of the popliteal artery should be regarded as an indication for its exploration in this type of case. A plea is made for conservative surgery in the treatment of this condition.

I acknowledge with thanks the great help of my colleague, Mr. K. Halstead Smith, at the time of operation and in the management of this case. I am grateful to Dr. W. E. Bryan and Dr. Geoffrey Hollingsworth for their helpful comments, and to Mr. E. J. Pameley and Mr. G. B. Dun for the photographs.

REFERENCES

- Atkins, H. J. B., and Key, J. A. (1947). *Brit. J. Surg.*, **34**, 426.
 Ejrup, B., and Hiertonn, T. (1954). *Acta chir. scand.*, **108**, 217.
 Hiertonn, T., Lindberg, K., and Rob, C. (1957). *Brit. J. Surg.*, **44**, 348.
 Jaquet, G. H., and Meyer-Burgdorff, G. (1960). *Chirurg*, **31**, 481.
 Taylor, G. W. (1962). *Ann. roy. Coll. Surg. Engl.*, **31**, 168.

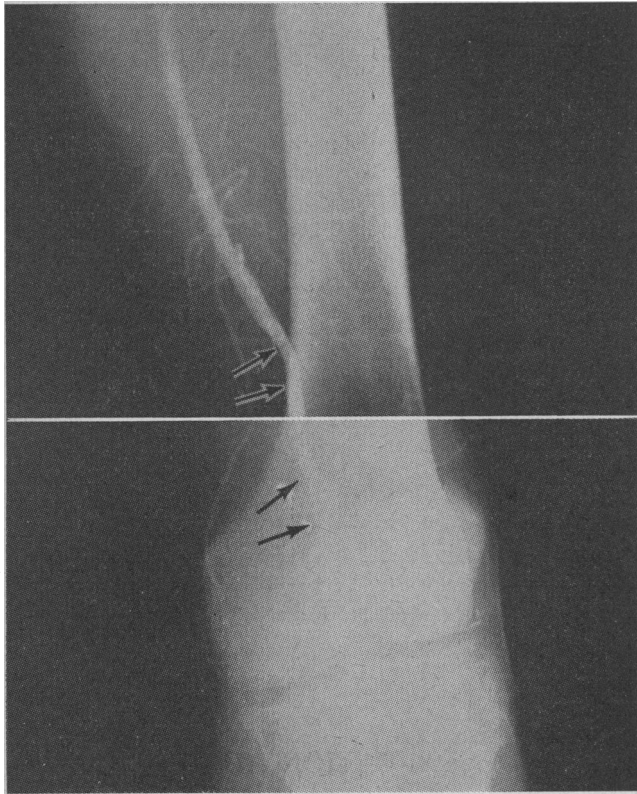


FIG. 1.—Top arrows indicate site of "kink" and slight narrowing. Lower arrows approximate widest extent of tumour.

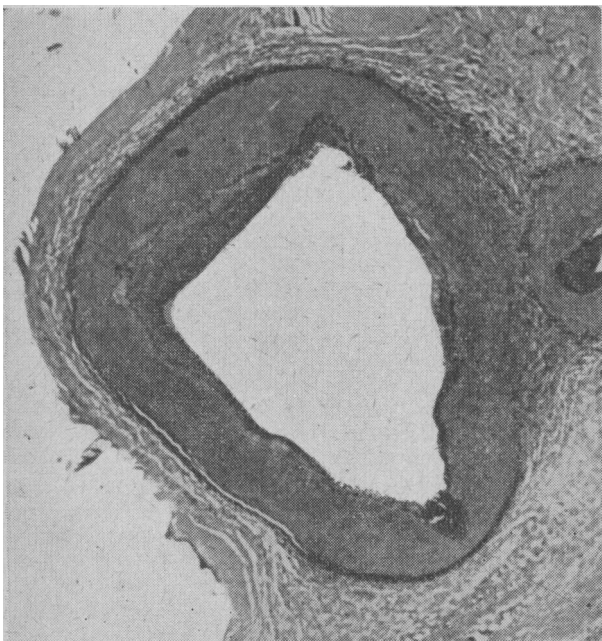


FIG. 2.—Photomicrograph of part of the cyst with popliteal artery adjacent to the right.

A card of convenient size, which has been specially designed for the "stroke" patient who can read and understand but is unable to speak, has been printed by the Chest and Heart Association. This word and picture chart costs 1s. a copy, or 7s. 6d. for 10 copies, from the Chest and Heart Association, Tavistock House North, Tavistock Square, London W.C.1.