

aneurysm during systole amounted to 19 ml/beat and the systolic flow across the aortic valve was 65 ml/beat. The forward stroke volume, measured by the Fick principle, was 45 ml/beat (heart rate, 120 beats/min); therefore, the regurgitant stroke volume across the aortic valve was 20 ml/beat.

Three months later the aneurysm was resected. Diffuse, dense adhesions made dissection of the aneurysm difficult. During dissection the patient became severely hypotensive and the electroencephalogram became temporarily abnormal. Therefore, cardiopulmonary bypass was instituted immediately. The aneurysm was found to be connected to the apex of the left ventricle through a passage approximately 1 cm in diameter and 12 mm in length. The wall of the aneurysm was removed and the defect closed in two layers with Mersilene sutures backed with Ivalon pledgets. With three interrupted sutures the neck of the aneurysm was obliterated and several more sutures were placed as a second layer.

The wall of the aneurysm was approximately 0.5 cm thick and lined by blood clot. Microscopic examination of the wall revealed only scar tissue and no intact myocardium.

The patient recovered satisfactorily except for some athetoid movements and hallucinations in the postoperative period. Twelve months after the second operation he was in good health except for slight impairment of his memory. Physical examination and chest radiography revealed no recurrence of the aneurysm.

## Discussion

The first case of a left ventricular aneurysm developing after mitral valvotomy was reported in 1950.<sup>1</sup> Occurrence of a right ventricular aneurysm following repair of tetralogy of Fallot was reported in 1954<sup>2</sup> and 1955,<sup>3</sup> the procedures having been, respectively, closed pulmonary valvotomy and infundibular resection. Subsequently, a left ventricular aneurysm developing after aortic valvotomy was reported.<sup>4,5</sup> In these cases the aneurysm occurred at the site where the ventricle was incised to permit introduction of the instrument. Formation of a left ventricular aneurysm following myotomy for idiopathic hypertrophic subaortic stenosis was reported in 1971.<sup>8</sup> In 1972 the first case of a false left ventricular aneurysm occurring at the site of left ventricular venting following aortic valve replacement was reported.<sup>11</sup> To our knowledge, our paper is only the second report of a false aneurysm developing at the site of a left ventricular vent.

We assume that the aneurysm formed in this patient because of localized weakening of the left ventricular wall at the site of venting. It seemed to us that the aneurysm was enlarging progressively before it was removed

and that the chest pain was due to irritation of the pleura by the aneurysm.

Prompt recognition and surgical management is vital in order to prevent rupture of the aneurysm and sudden death.

## References

- SMITHY HG, BOONE JA, STALLOWORTH JM: Surgical treatment of constrictive vascular disease of the heart. *Surg Gynecol Obstet* 90: 175, 1950
- CAMPBELL M, DEUCHAR DC, BROCK R: Results of pulmonary valvotomy and infundibular resection of 100 cases of Fallot's tetralogy. *Br Med J* 2: 111, 1954
- MCCORD MC, BLOUNT SG: Complications following infundibular resection in Fallot's tetralogy. *Circulation* 11: 754, 1955
- SMITH RC, GOLDBERG H, BAILEY CP: Pseudoaneurysm of the left ventricle: diagnosis by direct cardioangiography. *Surgery* 42: 496, 1957
- SEGEL N, FATTI L, ADLER D, et al: Aortic

stenosis: an evaluation of results of surgery in 20 cases. *S Afr Med J* 31: 899, 1957

- WADA J, IDEDA K, KADOWAKI Y, et al: Right ventricular aneurysm following open cardiomyotomy for correction of tetralogy of Fallot. *Ann Thorac Surg* 1: 184, 1965
- KERR WF, WILKEN DEL, STEINER RE: Incisional aneurysms of the left ventricle. *Br Heart J* 23: 88, 1961
- WYNCHULIS AR, FRYE RL, KINCAID OW, et al: Postventriculotomy aneurysm in patients with idiopathic hypertrophic subaortic stenosis. *Am J Cardiol* 27: 322, 1971
- LITTLER WA, MEADE JB, HAMILTON DI: Ventricular aneurysms after cardiac surgery. *Br Heart J* 33: 962, 1971
- MCVAUGHN H, JOYNES CR, PIERCE WS, et al: Repair of subvalvular left ventricular aneurysm occurring as a complication of mitral valve replacement. *J Thorac Cardiovasc Surg* 58: 291, 1969
- FALLAH-NEJAD M, ABELSON DM, BLAKEMORE WS: Left ventricular pseudoaneurysm. A rare complication of open-heart surgery with unusual Doppler manifestations. *Chest* 61: 90, 1972
- SANDLER H, DODGE HT: The use of single plane angiocardigrams for the calculation of left ventricular volume in man. *Am Heart J* 75: 325, 1968

# Yellow-nail syndrome: report of three cases

E.M. NAKIELNA,\* MB, CH B, MRCP, DCH, FRCP[C];  
J. WILSON,† MD; H.S. BALLON,‡ MD, FRCP[C]

The yellow nail syndrome, a combination of yellow discoloration of and dystrophic changes in the nails, pleural effusions and lymphedema, is thought to be relatively rare; to date 44 cases have been reported. Of a further three patients with this syndrome, one had all three features, one had the yellow nails alone and the other had pleural effusions and lymphedema without classic nail changes. Each had recurrent lower respiratory tract infections; and of all 47, chronic pulmonary infections occurred in approximately one quarter and were frequently associated with chronic sinus infections.

The underlying abnormality is presumed to be a congenital defect of the lymphatics, but so far this has not been demonstrated to be the cause of the nail changes, the pathogenesis of which remains obscure.

Le syndrome des "ongles jaunes", qui associe une décoloration jaune et des changements dystrophiques des

ongles, des effusions pleurales et un lymphoedème, est une affection que l'on croit relativement rare; jusqu'à maintenant 44 cas ont été signalés. Chez trois nouveaux patients atteints de ce syndrome un présentait les trois caractéristiques, un avait seulement les ongles jaunes, et on notait chez le troisième des effusions pleurales et un lymphoedème en l'absence des changements classiques des ongles. Les trois souffraient d'infections du tractus respiratoire inférieur; des infections pulmonaires chroniques étaient présentes chez approximativement le quart des 47 cas signalés et elles étaient souvent accompagnées de sinusites infectieuses chroniques.

On croit que l'affection sous-jacente est une anomalie congénitale du système lymphatique mais, jusqu'à maintenant, on n'a pu démontrer que ceci puisse entraîner une modification des ongles, la pathogénèse de ces changements demeurant obscure.

The yellow nail syndrome, an association of characteristically deformed and discoloured nails, pleural effusions and primary lymphedema, is a relatively newly described entity. Samman and White<sup>1</sup> were the first to report, in 1964, the association of slow-growing, yellow, discoloured nails with primary lymphedema and they called it the yellow nail syndrome. The respiratory component

From the respiratory division, department of medicine, University of British Columbia and Vancouver General Hospital

†Former research fellow, respiratory division

‡Clinical assistant professor, department of medicine, University of British Columbia

Reprint requests to: Dr. E.M. Nakielna, Department of medicine, University of British Columbia, Vancouver, BC V5Z 1M9

was added to the syndrome by Emerson,<sup>2</sup> who, in 1966, described three cases of idiopathic pleural effusion associated with chronic lymphedema, in two of which there was yellow discoloration of the nails. Since then, the number of cases in the literature has grown steadily, and to date 44 cases have been fully reported:<sup>1-3,4-16</sup> all three manifestations of the syndrome, however, were present in only 10 cases. Samman<sup>3</sup> has reported briefly a further 55 cases, without clinical detail.

In this paper we describe another three cases, encountered over a 3-year period (1972-74) at Vancouver General Hospital, with the three essential features of the syndrome in different combinations.

## Case reports

### Patient 1

A 62-year-old woman with a long history of productive cough and mild dyspnea was seen at the University of British Columbia respiratory clinic in March 1972.

Her respiratory complaints had started at the age of 29 with pleurisy and pneumonia, from which she recovered uneventfully. At the age of 50 she had several further episodes of pneumonia, which left persistent shadows in the right middle and lower lobes. Bronchograms revealed bilateral lower lobe bronchiectasis. At this time she noticed changes in both toe- and fingernails; initially the nails grew slowly; later they became thick and brittle and developed a yellow discoloration. Ankle swelling unresponsive to diuretic therapy appeared at the same time; the swelling extended gradually to the knees. More recently periorbital swelling was noticed. Pleural effusions occurred repeatedly from the age of 56, and over a 4-year period she required eight thoracenteses.

Previous problems included thyrotoxicosis, for which partial thyroidectomy was

performed, and maxillary fenestrations. The family history was noncontributory.

Thickening and yellow discoloration of the nails, pitting edema of the ankles without evidence of cardiac failure, and coarse rales at both lung bases, which cleared partially on coughing, were noted. Mucoid thickening of the maxillary sinuses and opacification of the ethmoid sinuses were revealed by sinus radiography, and an encysted right pleural effusion, left pleural thickening, and crowding of the bronchovascular markings at the bases were demonstrated by chest radiography (Fig. 1). A pleural biopsy revealed chronic nonspecific inflammatory changes. The sputum contained no acid-fast bacilli, fungi or malignant cells.

Her hemoglobin concentration was 12.5 g/dl and her leukocyte and differential counts were within the normal range. Serum immunoglobulin concentrations were normal. Lymphocyte stimulation tests with phytohemagglutinin, pokeweed mitogen and concanavalin A gave normal responses. Tests for cold agglutinin, LE cells and rheumatoid factor were negative. Results of blood biochemistry and liver function tests and serum thyroxine concentration were normal. Results of pulmonary function studies are shown in Table I. Lymphangiography demonstrated poor lymphatic drainage in the legs.

The patient was given postural drainage and short courses of antibiotic therapy for intercurrent chest infections. At present she is well and there has been no recurrence of the pleural effusion, but the yellow nails and peripheral edema persist.

### Patient 2

A 32-year-old woman was seen in December 1974 because of a persistent cough and large amounts of purulent sputum.

She was a nonsmoker and had been in good health until April 1974, when, after an attack of flu, a persistent cough developed, with production of about 30 ml of purulent sputum per day. By August the daily sputum volume had increased to 60 ml and the cough had become disabling, frequently keeping her awake

at night. About this time she noticed that the nails of her thumbs and index fingers had turned yellow and that nail growth had ceased. By December the remaining fingernails had turned yellow and the nails of the thumbs and index fingers were separating from the nail beds. She denied any peripheral edema or exertional dyspnea. Previous illnesses included whooping cough and three episodes of tonsillitis. The family history was noncontributory.

The nails of the fingers of both hands contained no lunulas. The yellow discoloration was most pronounced in the distal two thirds of the nails of the thumbs and index fingers, which also had an increased side-to-side curvature. There was no peripheral edema or other physical abnormality. Mucosal thickening of the right posterior ethmoid and sphenoid sinuses was noted on radiographs of the paranasal sinuses. Chest radiographs showed areas of subsegmental atelectasis with minimal consolidation in the lateral basal segments of the left lower lobe. Bronchoscopy revealed purulent secretions originating in both main bronchi, and an underlying inflamed mucosa. The sputum contained only normal flora and no acid-fast bacilli, fungi or malignant cells. Nail clippings contained no evidence of fungi.

The hemoglobin concentration was normal. The leukocyte count was  $13.5 \times 10^9/l$  (neutrophils, 72%; stab cells, 2%; lymphocytes, 19%; monocytes, 7%). Serum immunoglobulin concentrations were normal. A right bronchogram was normal; because of a mild hypersensitivity reaction to the contrast medium a left bronchogram was not performed. Results of pulmonary function studies are shown in Table I.

The patient was given a course of tetracycline; this had a slight beneficial effect on her cough and sputum production.

### Patient 3

A 34-year-old woman presented in September 1972 with a 6-month history of gradually increasing swelling of her face and hands, which was partially reduced by hydrochlorothiazide therapy. She had had similar symptoms during her only pregnancy, at the age of 23.

She was a heavy smoker and for the past 10 years had had acute bronchitis twice a year and a chronic cough productive of sputum. Her exercise tolerance had diminished recently. Apart from recurring urinary tract infections, there were no other current or past medical problems. She had been taking oral contraceptives for the past 9 years.

She was overweight and had cushingoid features. Her fingernails were normal but her toenails had slightly yellow transverse bands. She had moderate ankle and sacral edema but was normotensive, and there was no evidence of cardiac failure. At the bases of the lungs, air entry was impaired and the chest was dull to percussion. There were no other abnormal physical findings. Bilateral pleural effusions were demonstrated by chest radiography. Thoracentesis revealed an exudate with a protein concentration of 4 g/dl, a glucose concentration of 46 mg/dl and a lactic dehydrogenase concentration of 404 IU/ml.

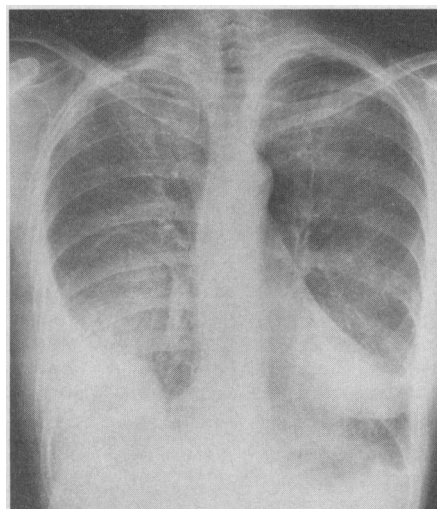


FIG. 1—Encysted right pleural effusion and thickening of pleura on the left in patient 1, who also had yellow nails and primary lymphedema.

Table I—Results of pulmonary function studies in patients with yellow nail syndrome

Variable	Observed value (and % of normal)	
	Patient 1	Patient 2
Vital capacity (l)	2.37 (65)	2.95 (94)
Functional reserve capacity (l)	3.02 (90)	2.24 (92)
Forced expiratory volume in 1 second, FEV <sub>1</sub> (l)	1.64 (61)	2.03 (78)
FEV <sub>1</sub> /forced vital capacity (%)	73	69
Maximum midexpiratory flow rate (l/s)	1.25 (46)	1.5 (44)
Diffusing capacity for carbon monoxide (ml/min. mm Hg)	12.3	15.1

Cultures of sputum for acid-fast bacilli, fungi and bacteria were negative. Her liver and renal function studies, which included intravenous pyelography, yielded normal results. There was no evidence of protein in two 24-hour urine specimens. Her serum albumin concentration was 3.49 g/dl.

Immunoelectrophoresis showed complete absence of IgA on several occasions. Antinuclear factor, LE cell, latex fixation and VDRL tests were all negative. Several skin biopsies revealed lymphedema and lymphatic dilatation. Lymphangiography was unsuccessful because of difficulty in cannulation, attributed to lymphatic hypoplasia.

Because of these findings and the negative results of investigations for other causes of generalized lymphedema with bilateral pleural effusions it was considered that this patient had the yellow nail syndrome. She was discharged taking diuretics alone and advised to stop smoking. Pleurodesis or pleurolectomy was to be considered if the recurrent effusions became a severe problem in the future.

### Discussion

Of the three patients described, only one (no. 1) demonstrated the triad of yellow nails, primary lymphedema and pleural effusions. She also manifested two other conditions frequently associated with the syndrome — bronchiectasis and sinusitis. In patient 3 the nail changes were not classic, consisting of transverse yellow ridges in the toenails. She had a 10-year history of recurrent chest infections. In patient 2 the nail changes were typical but the other two features of the syndrome were lacking, her presenting symptoms being a persistent cough productive of large amounts of purulent sputum. She also had radiologic changes suggestive of chronic sinusitis.

The diagnosis of yellow nail syndrome is based entirely on a combination of clinical findings for which all other possible causes have been excluded. No confirmatory tests exist and the pathogenesis of the condition is poorly understood. It has been suggested that this syndrome is basically the result of a congenital abnormality of the lymphatics and therefore could be related to primary lymphedema, a category in the classification of lymphedema proposed by Allen, Barker and Hines.<sup>17</sup>

In both primary lymphedema and the yellow nail syndrome females predominate. In a combined review of 479 cases of lower limb lymphedema Kinmonth<sup>18</sup> noted that 76% of the patients were female. In our review of all known cases of the yellow nail syndrome, of the 37 patients with lymphedema 70% were female.

Kinmonth also reviewed the lymphangiographic findings in 100 patients with primary lymphedema and found that 87 had lymphatic hypoplasia; 5,

aplasia; and 8, hyperplasia. Of the 44 cases of the yellow nail syndrome we reviewed, in 12 lymphangiography was performed; hypoplasia was demonstrated in 8, aplasia in 1 and normal lymphatics in 3.

The yellow nail syndrome, if included in the category of primary lymphedema, constitutes a distinctive subgroup in view of its two other features, pleural effusions and yellow nails, the pathogenesis of which is likewise ill-defined. Emerson<sup>2</sup> postulated that the pleural lymphatics are also hypoplastic and, like the lymphatics in the legs, may function normally for many years but when stressed are unable to maintain adequate drainage, so that pleural effusions result. Nothing is known of the mechanism of production of the nail changes; there is no proof so far that they result from impaired function of the lymphatics.<sup>3</sup>

In any new syndrome one always looks for other possible associations. Among the 44 cases reported in the literature, and in our own 3 cases, the commonest association was chronic pulmonary infection, which occurred in 13 cases, and chronic sinus infection, which occurred in 9 (Table II). Immunologic abnormalities have been noted in four cases, including one of ours — patient 3, who had complete absence of IgA. Two patients had lymphopenia; serum gamma globulin concentration was greatly reduced in one of them and the other had a high serum titre of rheumatoid factor; the latter died of Hodgkin's-type lymphoma.<sup>4</sup> D'Souza<sup>5</sup> reported a case with macroglobulinemia.

Thyroid abnormalities have been

noted in four patients, including one of ours. These included Hashimoto's thyroiditis,<sup>11</sup> thyroid enlargement,<sup>11</sup> hypothyroidism<sup>13</sup> and thyrotoxicosis — in our patient 1.

Malignant disease has caused three of the five deaths reported; the tumours were a lymphoma,<sup>4</sup> a malignant melanoma<sup>2</sup> and an anaplastic undifferentiated tumour thought to be a sarcoma.<sup>6</sup> The other two deaths were due to cor pulmonale and respiratory failure,<sup>4</sup> and to "metabolic acidosis".<sup>2</sup> The earliest age at which nail changes have been noted was 10 years<sup>7</sup> and the latest, 65 years.

The various combinations of the three major features of the yellow nail syndrome are listed in Table III. Seven patients, including one of ours (no. 3), with lymphedema and pleural effusions did not have classic nail changes at the time of reporting. The individual features of the syndrome may occur at wide intervals, so that absence of the classic nail changes does not preclude the diagnosis, provided all other possible causes of pleural effusions and lymphedema have been excluded.

It is likely that the condition is not as rare as it appears from the number of published reports, and a greater awareness of its various forms will probably lead to more frequent diagnosis.

### References

1. SAMMAN PD, WHITE WF: The "yellow nail syndrome" *Br J Dermatol* 76: 153, 1964
2. EMERSON PA: Yellow nails, lymphoedema and pleural effusions. *Thorax* 21: 247, 1966
3. SAMMAN PD: The yellow nail syndrome. *Trans St. John's Hosp Dermatol Soc* 59: 114, 1973
4. SIEGELMAN SS, HECKMAN BH, HASSON J: Lymphedema, pleural effusions and yellow nails — associated immunologic deficiency. *Dis Chest* 56: 114, 1969
5. D'SOUZA MF: Generalized lymphoedema with yellow nails, pleural effusions and macroglobulinaemia. *Proc R Soc Med* 63: 456, 1970
6. HILLER E, ROSENOW E, OLSEN A: Pulmonary manifestations of yellow nail syndrome. *Chest* 61: 452, 1972
7. ZERFAS AJ: Yellow nail syndrome with bilateral bronchiectasis. *Proc R Soc Med* 59: 448, 1966
8. AYRES S JR, MIHAN R: Yellow nail syndrome: response to vitamin E. *Arch Dermatol* 108: 267, 1973
9. HURWITZ PA, PINALS JD: Pleural effusion in chronic hereditary lymphedema (Nonne, Milroy, Meige's disease). Report of two cases. *Radiology* 82: 246, 1964
10. WELLS GC: Yellow nail syndrome: with familial primary hypoplasia of lymphatics, manifest late in life. *Proc R Soc Med* 59: 447, 1966
11. DILLEY JJ, KIERLAND RR, RANDALL RV, et al: Primary lymphedema associated with yellow nails and pleural effusions. *JAMA* 204: 670, 1968
12. BOWERS D: Unequal breasts, yellow nails, bronchiectasis and lymphoedema. *Can Med Assoc J* 100: 437, 1969
13. MARKS R, ELLIS JP: Yellow nails: a report of six cases. *Arch Dermatol* 102: 619, 1970
14. DWEK JH, GREENBERG GM: Yellow nails, lymphedema and pleural effusions. *NY State J Med* 73: 1093, 1973
15. KLEINMAN PK: Congenital lymphedema and yellow nails. *J Pediatr* 83: 454, 1973
16. SOMORIN AO: Yellow nail syndrome. *Trans St. John's Hosp Dermatol Soc* 59: 272, 1973
17. ALLEN EV, BARKER NW, HINES EA: *Peripheral Vascular Diseases*, Philadelphia, Saunders, 1962, p 684
18. KINMONTH JB: *The Lymphatics — Diseases, Lymphography and Surgery*, London, Arnold, 1972, p 93

Abnormality	No. of patients
Yellow nails	40
Lymphedema	34
Pleural effusions	18
Chronic pulmonary infections	13
Sinus infections	9

Combination	No. of patients
Yellow nails and lymphedema	18
Yellow nails, lymphedema and pleural effusions	11
Yellow nails alone	11
Lymphedema and pleural effusions	7
Yellow nails and pleural effusions	0
Total	47