

- gnosis of hypothyroidism. *Q J Med* 38: 255, 1969
11. LAMBERG BA, HEINONEN OP, ARO A, et al: Statistical evaluation of symptoms and clinical signs in the diagnosis of hyperthyroidism. *Acta Endocrinol [Suppl] (Kbh)* 146: 37: 1970
  12. CLEMENTS FW: Health significance of endemic goitre and related conditions. *WHO Monogr Ser* 44: 235, 1960
  13. Nutrition Canada: *Nutrition — A National Priority*, Ottawa, Information Canada, 1973
  14. IAEA Panel: Thyroid radionuclide uptake measurements. *Int J Appl Radiat Isot* 23: 305, 1972
  15. THORSON SC, MINCEY EK, MCINTOSH HW, et al: Evaluation of a new in-vitro blood test for determining thyroid status: the effective thyroxine ratio. *Br Med J* 2: 67, 1972
  16. PETT LB, OGLIVIE GF: The Canadian weight-height survey. *Hum Biol* 28: 177, 1956
  17. RALL JE, ROBBINS J, LEWALLEN CG: The thyroid (chap 3), in *The Hormones*, vol 5, PINCUS G (ed), New York, Acad Pr, 1964, pp 159-439
  18. DOTY RL, SILVERTHORNE C: Influence of menstrual cycle on volunteering behaviour. *Nature* 254: 139, 1975
  19. Nutrition Canada: *The British Columbia Survey Report*, Ottawa, Information Canada, 1975
  20. GILBERT N: Transformations (chap 5), in *Biometrical Interpretation*, Oxford, Clarendon Pr, 1973, pp 56-9
  21. KEELING DH, WILLIAMS ES: Secular changes in thyroid uptake. *Br J Radiol* 47: 432, 1974
  22. SACHS BA, SIEGEL E, HORWITT BN, et al: Bread iodine content and thyroid radioiodine uptake: a tale of two cities. *Br Med J* 1: 79, 1972
  23. FISHER KD, CARR CJ: *Iodine in foods: chemical methodology and sources of iodine in the human diet*, FDA publ no 71-294, Bethesda, MD, Fed Am Soc Exp Biol, Life Sci Research Office, 1974, pp 47-51
  24. WOLFF J: Iodide goiter and the pharmacologic effects of excess iodide. *Am J Med* 47: 101, 1969
  25. GREIG WR, McDUGALL IR, GRAY HW: The diagnosis of thyrotoxicosis. *Postgrad Med J* 49: 469, 1973
  26. CONNOLLY RJ: An increase in thyrotoxicosis after an increase in dietary iodine in southern Tasmania. *Med J Aust* 1: 1268, 1971
  27. PAIN RW: In vitro testing of thyroid function: a review. *Pathology* 7: 1, 1975
  28. AZIZI F, VAGENAKIS AG, PORTNAY GI, et al: Pituitary-thyroid responsiveness to intramuscular thyrotropin-releasing hormone based on analyses of serum thyroxine, triiodothyronine and thyrotropin concentrations. *N Engl J Med* 292: 273, 1975
  29. BRITTON KE, QUINN V, BROWN BL, et al: A strategy for thyroid function tests. *Br Med J* 3: 350, 1975
  30. NILSSON G, MOLLERT T: Age variation in the uptake of radioiodine in thyrotoxicosis. *Acta Radiol [Ther] (Stockh)* 13: 201, 1974
  31. ODDIE TH, MYHILL J, PIRNIQUE FG, et al: Effect of age and sex on the radioiodine uptake in euthyroid subjects. *J Clin Endocrinol Metab* 28: 776, 1968
  32. QUIMBY EH, WERNER SC, SCHMIDT C: Influence of age, sex and season upon radioiodine uptake by the human thyroid. *Proc Soc Exp Biol Med* 75: 537, 1950

## Application of special diagnostic techniques in the management of nodular goitre

PAUL G. WALFISH, MD, FRCP[C], FACP; MURRAY MISKIN, MD, FRCP[C]; IRVING B. ROSEN, MD, FRCS[C], FACS; HARRY T.G. STRAWBRIDGE, MB, CH B, MRCP (EDIN), FRCP[C]

The primary challenge in the management of nodular goitre is to establish which thyroid nodules are malignant. Since selection of patients for operation on the basis of palpation of nodules alone gives a low yield of malignant disease, physicians have sought criteria for selection that combine the information obtained from special laboratory procedures with thoughtful clinical appraisal. Such special procedures, which include radioisotope scintiscanning, echography by B-mode ultrasonography, and either large- or fine-needle aspiration and cytologic examination of the aspirate, are considered valuable in a proposed clinical approach to the management of thyroid nodules.

Le principal défi rencontré lors du traitement du goitre nodulaire consiste à identifier quels sont les nodules thyroïdiens malins. La sélection des patients établie à partir de la simple palpation des nodules ne révèle qu'un petit nombre de lésions malignes; les médecins ont donc recherché des critères de sélection associant l'information obtenue à partir de tests

spéciaux de laboratoire et une évaluation clinique attentive. Ces tests spéciaux, qui incluent la scintigraphie radioisotopique, l'échographie par ultrasonographie B-modale, et l'examen cytologique des spécimens obtenus par aspiration à l'aiguille fine ou large, sont considérés utiles dans l'approche clinique proposée au traitement des nodules thyroïdiens.

In the management of nodular goitre the primary challenge facing the physician is to establish which thyroid nodules are malignant. Since it has been generally established that selection of patients for operation on the basis of palpation of nodules alone results in a low yield of malignant disease, there has been an increased awareness of the need for further selection criteria that combine the information obtained from special laboratory procedures with thoughtful clinical appraisal.

The purpose of this presentation is to review some of the special diagnostic techniques that have been proposed for evaluating thyroid nodules and to demonstrate how some of them may be used to assist in the practical management of clinical problems.

### Primary special diagnostic techniques

#### Radioisotope scintiscanning

Scintiscanning with radioactive iodine ( $^{131}\text{I}$ ) permits classification of thyroid nodules according to their functional activity into "hot" (hyper-

functional), "warm" (isofunctional or nondelineated) and "cool" or "cold" (hypofunctional) lesions. Hot nodules, which constitute approximately 25% of solitary palpable nodules, are rarely, if ever, malignant.<sup>1</sup> Of the remaining 75% of palpable solitary nodules 10 to 20% are malignant and the rest are a heterogeneous group of benign hypofunctioning lesions (Table I). For these reasons, palpation of a solitary nodule and delineating by scintiscanning that it is hypofunctioning are not adequate surgical selection criteria for a consistently high yield of malignant disease.

In addition to  $^{131}\text{I}$ , other isotopes have been proposed for scintiscanning of thyroid nodules (Table II). Although  $^{99\text{m}}\text{Tc}$ -pertechnetate ( $^{99\text{m}}\text{TcO}_4$ ) provides a rapid "same-day" scan with less radiation exposure, it occasionally produces a misleading scan appearance of neoplastic lesions as hot nodules; these lesions are more reliably visualized as cold nodules on  $^{131}\text{I}$  scintiscans. Also, a

Table I—Types of solitary hypofunctioning thyroid nodules

Type	%
Cystic	20
Solid and mixed	
Carcinoma	13 — 20
Benign	40
Other non-tumour conditions e.g., colloid nodules, localized subacute or chronic thyroiditis, multinodular goitre, degenerative, hemorrhagic or calcified lesions	20 — 27

From the departments of medicine, radiologic sciences, surgery and pathology, University of Toronto and Mount Sinai Hospital, Toronto

Presented in part at the symposium "Assessment and management of thyroid function", sponsored by Ames Education Foundation, at Bristol Place Hotel, Toronto, May 2, 1975

Reprint requests to: Dr. Paul G. Walfish, Clinical investigation centre, Ste. 640, Mount Sinai Hospital, 600 University Ave., Toronto, ON M5G 1X5

variety of isotopes have been proposed for the study of the rate of cellular activity and protein synthesis within thyroid nodules.<sup>2,3</sup> Malignant lesions, with their increased cellular activity, would be expected to appear hot on a scan with such an isotope but would appear cold (i.e., hypofunctioning) on a scan with <sup>131</sup>I. However, our preliminary experience with radioactive selenomethionine (<sup>75</sup>Se) scintiscanning, in agreement with the observations of other workers,<sup>2,3</sup> suggests that it frequently gives false-positive results for benign neoplasms and inflammatory lesions such as those of chronic thyroiditis, whereas it may give false-negative results for slow-growing carcinomas. These conflicting results make questionable the value of information obtained by such special isotope scanning techniques.

### Echography

Recently we have obtained more information on the physical properties of hypofunctioning solitary nodules by using ultrasound.<sup>4</sup> Differences in acoustic density detected by ultrasonography (A- and B-mode) provide diagnostic echographic patterns and permit the differentiation of predominantly cystic lesions from solid or mixed (solid and cystic) lesions. Our experience<sup>4,5</sup> and that of others<sup>3,6</sup> indicate that this is a highly accurate procedure, the results correlating with pathologic findings in more than 92% of cases. It is a simple, safe, noninvasive, nonradioactive test,

with little patient discomfort, and it provides diagnostic information not available from palpation, scintiscanning or radiography.

Ultrasound echography cannot provide reliable diagnostic information about lesions less than 1 cm in diameter because of inadequate resolution, and will not detect retrosternal lesions. Errors in interpretation may occur in 8% of cases because of varying degrees of cystic change or loculation within the lesions. Mixed (solid and cystic) lesions more than 4 cm in diameter and predominantly solid hypofunctioning lesions of any size are considered at risk for malignant disease. With current ultrasonographic techniques, differentiation of carcinoma from other solid benign lesions is not feasible.<sup>4,5</sup>

Study of 61 solid hypofunctioning nodules selected for surgical treatment showed that 18% were malignant and 51% were benign adenomas, the total proportion of neoplasms thus being 69% (Table III). It is anticipated that, as predominantly cystic lesions of less than 4 cm in diameter are recognized by echography and managed conservatively, the proportion of malignant lesions in the remaining patients with solid or mixed hypofunctioning nodules referred for operation will increase.<sup>7</sup>

### Cytology

In order to obtain further preoperative information on hypofunctioning solid nodules, there has been renewed interest in obtaining thyroid nodule tissue for cytologic study by a variety of office procedures. While the desirability and safety of these preoperative invasive techniques have been controversial, recent opinion has been changing rapidly in favour of these techniques.<sup>8</sup> Percutaneous Vim-Silverman needle biopsy has been advocated<sup>9</sup> but is a technically difficult procedure, with a theoretically higher risk of seeding the needle tract with malignant cells. Crile, who first reported such a complication,<sup>10</sup> has not seen another case in more than 2000 needle biopsies.<sup>11</sup> He suggests that the risk is indeed small

and has continued using large-needle aspiration routinely to obtain tissue for pathologic diagnosis. We have occasionally used open-needle biopsy under local anesthesia in patients who were poor surgical risks, but this may also have technical difficulties when the lesions are very vascular.

**Large-needle aspiration:** Predominantly cystic lesions can be managed conservatively by aspiration with an 18- to 20-gauge needle,<sup>4,10,12</sup> almost invariably without local anesthesia — a simple office procedure. The aspirate may vary from clear yellow, indicating a completely benign degenerative process, to bright red to brown, indicating various degrees of hemorrhage, which suggests a vascular adenoma or carcinoma. When bright red blood is obtained the nodule is usually reduced in size only transiently, blood reaccumulating within minutes; this usually indicates a neoplasm. A brown aspirate indicates old hemorrhage into an adenoma and contains hemosiderin-laden macrophages. This type of aspirate should be centrifuged and the sediment examined for possible malignant cells. A mixed (solid and cystic) lesion more than 4 cm in diameter that contains brown fluid and numerous atypical epithelial cells is more at risk for carcinoma; we usually refer patients with such recurring lesions for surgical treatment to exclude malignant disease.

**Fine-needle aspiration biopsy:** Although advocated by Scandinavian<sup>13</sup> and European workers for the diagnosis of cancer in many sites, including breast, thyroid, prostate and lymph nodes, this procedure has been used little in North America. The recent Canadian experience of Crockford and Bain<sup>8</sup> confirming the feasibility of using this technique to assess thyroid disease sparked our interest. Furthermore, with the use of an improved exfoliative cytologic technique and with increasing experience, pathologists have been able to diagnose more confidently thyroid cancer and other types of tumours from aspiration cytology<sup>8,13</sup> or study of needle biopsy material.<sup>9,11</sup>

Accordingly, we have been assessing fine-needle (i.e., 27- to 30-gauge) aspiration biopsy without local anesthesia for all solitary hypofunctioning solid nodules. The aspirate is smeared on a slide, as with a peripheral blood film, and is fixed immediately with Cyto-spray (Ormont Drug and Chemical Co. Inc., Englewood, New Jersey; manufactured in Canada by Winley-Morris Co. Ltd., Montreal), to be stained by a modified Papanicolaou method for cytologic examination. In our preliminary experience with more than 90 solitary nodules using this technique we have been able to detect preoperatively papil-

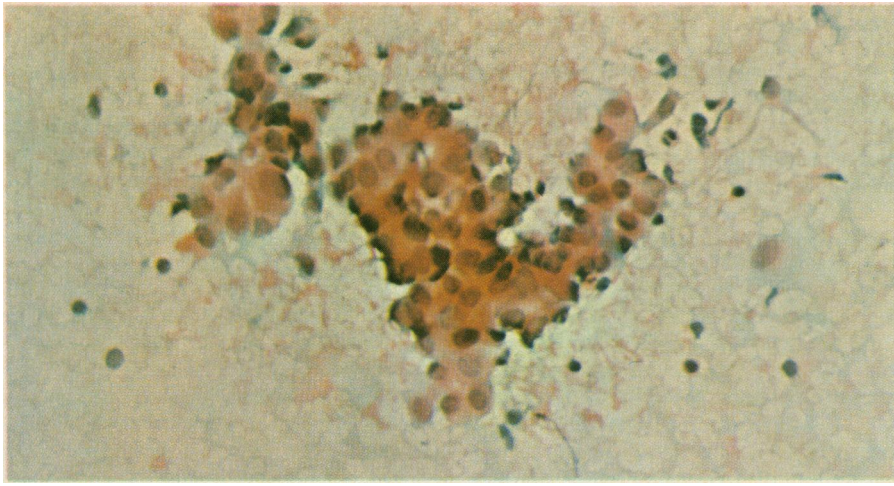
Table II—Scintiscanning agents currently used for the study of thyroid nodules

Function tested	Isotope	Appearance of malignant lesion
Trapping	<sup>99m</sup> Tc	Cold
Trapping, organification and synthesis	<sup>131</sup> I, <sup>125</sup> I, <sup>123</sup> I	Cold
Rate of protein synthesis	<sup>75</sup> Se, <sup>67</sup> Ga, <sup>131</sup> Cs, <sup>197</sup> Hg	Hot

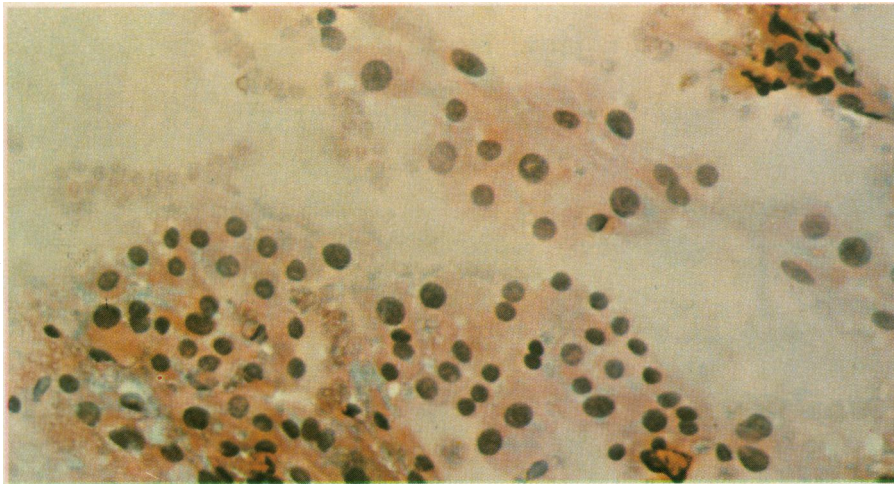
Table III—Results of investigation of and operation for 100 solitary thyroid nodules

	Investigative technique		
	Palpation	Radioisotope scintiscanning	Echography
100 solitary nodules		Hot, 25 Cold, 75	Cystic, 14 Solid, 61
			Carcinoma, 11 (18%) Adenoma, 31 (51%) Non-tumour, 19 (31%)

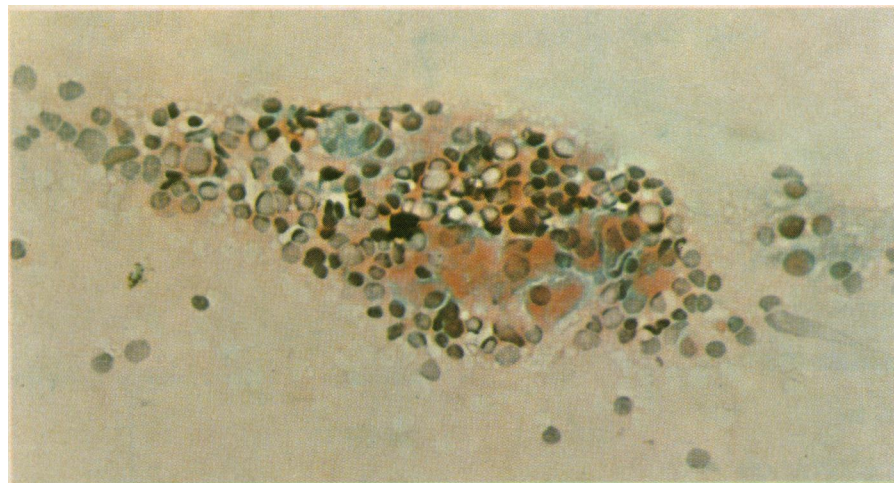




**FIG. 1**—Typical diagnostic signs of malignant disease — pleomorphism and irregular nuclei of thyroid epithelial cells and cellular adhesiveness — in smear of aspirate obtained by fine-needle aspiration biopsy of thyroid nodule in a case of papillary carcinoma diagnosed preoperatively (Papanicolaou stain; original magnification, x250).



**FIG. 2**—Sheets of uniform, regular thyroid epithelial cells, with uniform size and shape of nuclei (in contrast to appearance of cells in Fig. 1) in smear of aspirate obtained by fine-needle aspiration biopsy of thyroid nodule in a case of benign follicular adenoma (papanicolaou stain; original magnification x250).



**FIG. 3**—Mixed picture of benign thyroid epithelial cells and clumps of lymphocytes and Hürthle cells in smear of aspirate obtained by fine-needle aspiration biopsy of thyroid nodule in a case of Hashimoto's thyroiditis (Papanicolaou stain; original magnification, x 250).

lary carcinoma (Fig. 1), which can be differentiated easily from benign-looking adenoma (Fig. 2). Degenerating lesions can be identified when hemosiderin-laden macrophages and foam cells are discerned. Abundant colloid and benign epithelial cells are noted in colloid nodules. Accuracy of 92% has been obtained for solid nodules, with no false-negatives for carcinoma except among cystic or mixed lesions greater than 4 cm in diameter.<sup>14</sup> This procedure has also been used to assess nontoxic goitre lesions. A diagnosis of chronic thyroiditis can be made when a mixed picture of benign thyroid epithelial cells, clumps of lymphocytes and Hürthle cells (Fig. 3) is observed.

In our experience this technique has been confirmed to be a safe office procedure that does not require local anesthesia and can provide additional information about solid solitary thyroid nodules. However, because the sample obtained is random and limited, this technique may not always permit differentiation of benign follicular adenomatous lesions from invasive carcinoma without total examination of the nodule. Hence, it has been our practice to follow carefully such lesions, with the patient receiving a trial of thyroid hormone suppression therapy. Depending upon clinical appraisal, most of our patients with highly cellular follicular or Hürthle-cell adenomas, particularly if there is evidence of atypia or mitoses, are referred for an operation to obtain a complete examination of the nodule and exclude malignant disease. Preoperative awareness of the diagnosis of thyroid carcinoma may be of particular advantage to the surgeon, who can then select the appropriate surgical approach.

#### Secondary special diagnostic techniques

Other diagnostic aids that are not as specific and of less value may be used in assessing thyroid nodules.

#### Radiologic study

Radiologic investigation for nodule calcification may show one of two patterns: fine stippling (psammoma bodies), which suggests the lesion is malignant, or coarse, dense conglomerations, which suggests the lesion is benign and degenerating. Radiographic studies may show displacement of the trachea and the esophagus by a thyroid mass.

#### Hematologic and endocrinologic study

Measurements of parameters of thyroid function, such as serum concentrations of total thyroxine, triiodothyronine ( $T_3$ ) and thyrotropin, and  $T_3$  resin uptake (an index of plasma thyroxine-binding globulin), may provide addi-

tional diagnostic clues since the presence of hypothyroidism usually, but not invariably, indicates a benign process. Thyroid antibody titres, as well as concentrations of serum calcium, inorganic phosphorus and alkaline phosphatase could help exclude chronic thyroiditis and parathyroid gland lesions, respectively. However, these two conditions have been known to coexist with thyroid tumours, including carcinoma. Routine leukocyte and differential counts and the sedimentation rate can be determined to exclude inflammatory lesions such as acute or subacute thyroiditis. Serum calcitonin studies, if available, could be performed when medullary carcinoma is suspected. Serum thyroglobulin concentrations have recently been reported to be a sensitive marker of thyroid carcinoma and its metastasis<sup>15</sup> but also have been reported to be elevated in hyperthyroidism and during the acute phase of subacute thyroiditis.<sup>16</sup>

**Proposed special laboratory procedures of limited application**

A number of other special laboratory procedures proposed for the study of thyroid nodules do not appear to have practical clinical application at this time.

*Angiography*

There have been conflicting reports<sup>3</sup> on the value of selective angiography of the neck, a procedure that has many technical limitations and difficulties of interpretation. Cancer of the thyroid is suggested angiographically by abnormal vascular patterns, including irregularity and heterogeneity of the tumour stain with a ragged contour in a contrast-loaded gland.

*Thermography*

Thermography, based upon the detection of increased amounts of heat emitted from malignant tissue, has also been found to have limited application.<sup>3</sup>

*Fluorescent scanning*

Fluorescent scanning has been proposed to help discriminate malignant from benign hypofunctioning solid nodules by measurement of iodine content by means of spectrophotometric analysis of x-rays emitted from the thyroid during excitation by an external source of  $\gamma$ -radiation — americium-241. While the initial report on this technique<sup>17</sup> suggested that it was not effective in detecting malignant lesions, Hollifield and colleagues<sup>18</sup> have obtained better results using a computerized analytic technique for comparing the iodine content of the nodule with that of the unaffected contralateral lobe. Although fluorescent scanning involves less radia-

tion exposure, it is technically difficult and requires special equipment that, at present, has no other clinical application.

**Current approach to the clinical management of thyroid nodules**

At Mount Sinai Hospital, Toronto, the practical management of the palpable solitary thyroid nodule and the assessment of the risk for malignant disease have been guided by the combination of careful clinical appraisal and the primary special diagnostic aids of <sup>131</sup>I scintiscanning, B-mode ultrasonography and either large- or fine-needle aspiration of hypofunctioning nodules.

*Hyperfunctioning thyroid nodules*

Our approach to the management of the hot nodule is summarized in Fig. 4. On the basis of results of initial <sup>131</sup>I scintiscanning, the proportion of hot nodules among solitary palpable nodules is approximately 25%. To guide management further, additional studies are performed — either a standard T<sub>3</sub>-suppression test or the more recently available thyrotropin-releasing hormone (TRH) test<sup>19</sup> — to establish if the nodule is nonautonomous and, thus, suppressible with thyroid hormone replacement therapy, or autonomous and non-suppressible. The likelihood of a hot nodule being malignant is considered

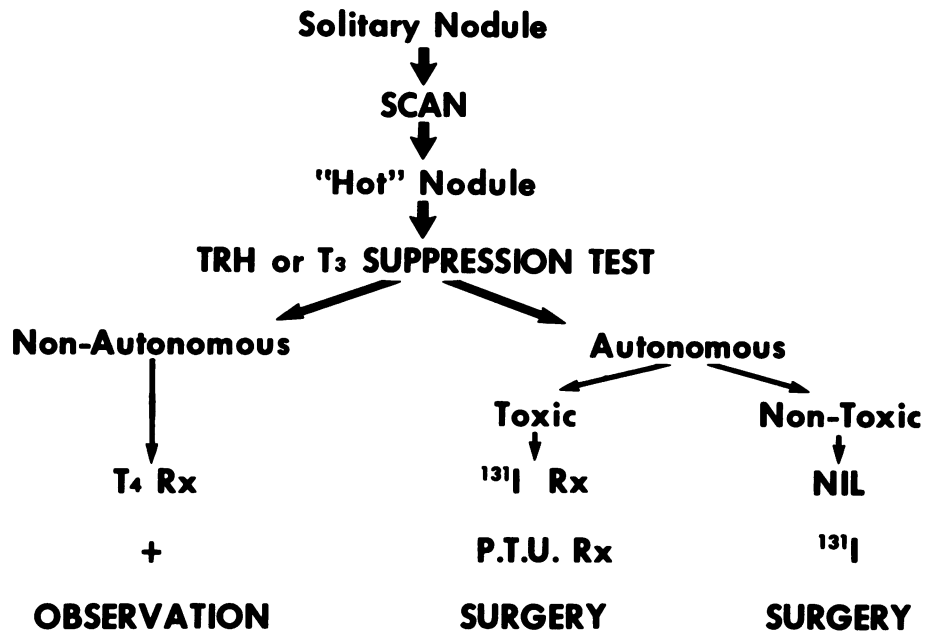


FIG. 4—Schematic flow diagram indicating use of special diagnostic techniques in clinical management of solitary "hot" thyroid nodule.

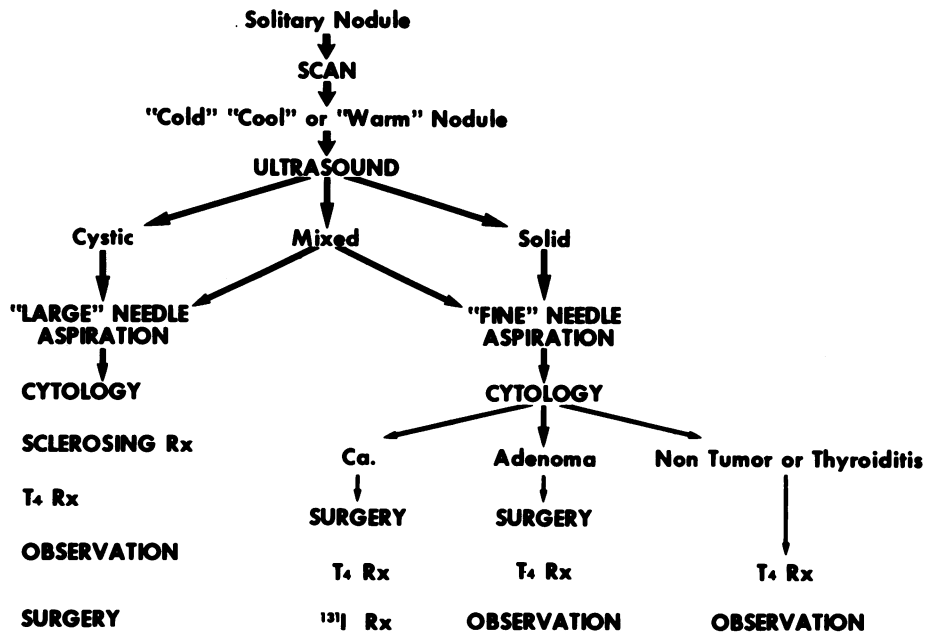


FIG. 5—Schematic flow diagram indicating use of special diagnostic techniques in clinical management of hypofunctioning thyroid nodule.



to be extremely small.<sup>1</sup> Since a hyperfunctioning nodule would be expected to be solid, there would be little need to consider B-mode ultrasonography except to follow the size of such a lesion. Fine-needle aspiration biopsy is also rarely necessary because one would expect to find that the nodule is a benign follicular adenoma.

#### *Hypofunctioning or isofunctioning thyroid nodules*

Our current approach to the management of hypofunctioning or isofunctioning nodules is summarized in Fig. 5. We have observed that approximately 20% of hypofunctioning solitary nodules from 1 to 4 cm in diameter were predominantly cystic,<sup>4,5</sup> a proportion similar to that observed in other series with reported, proven pathologic findings.<sup>6,10,12</sup> Since less than 2% of predominantly cystic lesions within the thyroid gland that are less than 4 cm in diameter have been found to be malignant,<sup>10-12</sup> these lesions may be managed conservatively, in the office, by large-needle aspiration. The aspirate should undergo cytologic examination. This may be followed by long-term thyroid hormone suppression therapy if the patient is under the age of 50 and has no coexisting autonomous hot nodules, or by repeat aspiration and injection of a sclerosing solution such as sodium tetradecyl sulfate.<sup>10,11</sup> However, depending on the colour of the aspirate and other clinical circumstances, some patients with cystic lesions may ultimately be referred for surgical excision, particularly if the lesion is larger than

4 cm in diameter.

On the other hand, solid hypofunctioning lesions or mixed lesions more than 4 cm in diameter are more likely to be malignant. Fine-needle aspiration may be attempted preoperatively with solid lesions. When the cytologic report indicates thyroid carcinoma or an adenomatous lesion with increased cellularity and atypia the nodule should be excised. Large mixed lesions with numerous epithelial cells, depending on clinical circumstances, should also be excised. If an operation appears contraindicated for medical reasons, occasionally a closed- or open-needle biopsy has been performed, under local anesthesia, to exclude malignant disease. Following the operation almost all patients receive long-term thyroid hormone replacement therapy and periodic evaluation. Patients over the age of 50 with multinodular goitres should be checked for autonomous, nonsuppressible nodules, since they will be at risk for cardiovascular complications from excessive thyroid hormone replacement therapy.

We are indebted to the collaborative efforts of Dr. Marko Mihic for his technical advice on the fine-needle aspiration technique, Dr. Elizur Hazani for data analysis, Mrs. Ingrid Foldes and the staff of the cytology division of the department of pathology, as well as Mr. Winston Bradshaw of the echography division of the department of radiologic sciences, Mount Sinai Hospital. The assistance of Instructional Media, Mount Sinai Hospital, directed by Mr. Ivan Gareau, and the skilled secretarial assistance of Miss M.M. Simpson in the preparation of this manuscript are gratefully acknowledged.

#### References

- MILLER MM, HAMBURGER JI: The hot nodule — the thyroid scintigram. *Radiology* 84: 66, 1965
- THOMAS CG JR, PEPPER FD, OWEN J: Differentiation of malignant from benign lesions of the thyroid gland using complementary scanning with selenomethionine and radioiodine. *Ann Surg* 170: 396, 1969
- ROSENBERG IN: Newer methods for evaluating thyroid nodules (E). *N Engl J Med* 287: 1197, 1972
- MISKIN M, ROSEN IB, WALFISH PG: B-mode ultrasonography in the assessment of thyroid gland lesions. *Ann Intern Med* 79: 505, 1973
- Idem: Ultrasonography of the thyroid gland. *Radiol Clin North Am* 13: 479, 1975
- BLUM M, GOLDMAN AB, HERSKOVIC A, et al: Clinical applications of thyroid echography. *N Engl J Med* 287: 1164, 1972
- MISKIN M, ROSEN IB, WALFISH PG: Thyroid nodules and ultrasound. *Ann Intern Med* 80: 113, 1974
- CROCKFORD PM, BAIN GO: Fine-needle aspiration biopsy of the thyroid. *Can Med Assoc J* 110: 1029, 1974
- MALOOF F, WANG CA, VICKERY AL: Nontoxic goiter — diffuse or nodular. *Med Clin North Am* 59: 1221, 1975
- CRILE G: Treatment of thyroid cysts by aspiration. *Surgery* 59: 210, 1966
- CRILE G, HAWK WA: Aspiration biopsy of thyroid nodules. *Surg Gynecol Obstet* 136: 241, 1973
- MILLER JM, ZAFAR SU, KARO JJ: The cystic thyroid nodule: recognition and management. *Radiology* 110: 257, 1974
- HOLM HH, PEDERSEN JF, KRISTENSEN JK, et al: Ultrasonically guided percutaneous puncture. *Radiol Clin North Am* 13: 493, 1975
- WALFISH PG, HAZANI E, ROSEN IB, et al: Combined B-scan ultrasound and needle aspiration cytology in the management of hypofunctioning thyroid nodules (to be published)
- VAN HERLE AJ, ULLER RP: Serum thyroglobulin (Tg): a sensitive marker of thyroid carcinoma and its metastases. *Clin Res* 22: 352A, 1974
- VAN HERLE AJ, ULLER RP, MATHEWS NL, et al: Radioimmunoassay for measurement of thyroglobulin in human serum. *J Clin Invest* 25: 1320, 1973
- HOFFER PB, GOTTSCHALK A: Fluorescent thyroid scanning: scanning without radioisotopes: initial clinical results. *Radiology* 99: 117, 1971
- HOLLIFIELD JW, PATTON JA, LEE GS, et al: Differentiation of malignant from benign thyroid nodules by fluorescent thyroid scanning. Paper, 56th annual meeting, Endocrine Society, Atlanta, GA, June 1974, p A-123
- HERSHMAN JM: Clinical application of thyrotropin-releasing hormone. *N Engl J Med* 290: 886, 1974

#### Tinnitus

*The noises grow — unceasing, loud,  
As from a roused and hostile crowd,  
The roar of which is hemm'd within  
This fragile sphere of bone and skin.  
The sound swells like a storm at sea  
And hinders my attempt to be  
Unruffled, calm of mind, contain'd —  
The kind of man I'd hoped was trained  
To disregard the harshest sounds —  
Alas, cacophony rebounds  
In whistle, clamour, strident ring —  
— The threnode a living thing  
That strips composure from the soul  
And hurls it, shattered, on the shoal  
Of never-ending, piercing scream.  
Would that it were a normal dream,  
Or instruments gone wild, and lo,  
T'would fade away with morning's glow,  
As voices from the walls grow soft  
With memories of days that oft  
Spelt quiet hours of childhood joy,  
Those golden times when, as a boy,  
No brass bands played within my head,  
And angels guarded me in bed.*

*And yet, and yet, there is some good  
In raucous, haunting sounds that could,  
Within imagination's fold,  
Become the battle-cries of old,  
Of tribal kings, who bravely shed  
Their martyr's blood for those they led  
From vassaldom to freedom's light —  
In verdant vales, where streams ran bright  
As legends, spun from words of gold,  
Immortalizing heroes bold —  
Or far-off keening harps that thrumm'd  
With poignant tales of grandeur, strumm'd  
By minstrels in forgotten caves,  
Of people who would not be slaves.  
For when the body shrinks from strife  
From stresses, trials of this life,  
The mind will grasp remember'd things,  
And promise of the spirit brings  
The strength of joy to fill all dreams  
And silence all harsh inner screams.  
The covenant with duty sworn,  
To hope that purpose be reborn,  
Helps me to live with what I've found —  
This paradox — silence with sound.*

TERENCE P. LALOR, MD, FRCP[C]  
177 Breezy Pines Dr.  
Mississauga, ON

(Dr. Lalor has been deaf since his early teens. — Ed.)