

Airway obstruction following smoke inhalation

S.P. PIETAK, MD; D.J. DELAHAYE, MD

Respiratory distress with episodes of cyanosis, intercostal retraction and sibilant rhonchi occurred in a 2-year-old boy over a 48-hour period following serious smoke inhalation. Worsening of the child's condition accompanied these findings, culminating in sudden loss of air entry, severe respiratory distress and loss of consciousness, which necessitated endotracheal intubation for resuscitation. Pronounced improvement followed removal of two pseudomembranous bronchial casts from the airway by suctioning, and thereafter recovery was uneventful.

Une détresse respiratoire, des épisodes cyanotiques, une rétraction intercostale et des râles sibilants sont apparus chez un garçonnet de 2 ans dans les 48 heures qui ont suivi une forte inhalation de fumée. Avec ces observations on a constaté une aggravation de l'état de l'enfant qui a culminé avec la perte de l'entrée d'air, une profonde détresse respiratoire et la perte de conscience; on a dû procéder à une intubation endotrachéale comme mesure de réanimation. Une amélioration marquée a suivi l'enlèvement par aspiration de deux cylindres bronchiques pseudomembraneux des voies respiratoires. La guérison s'est faite ensuite sans incident.

Pulmonary complications have been recognized as important factors in illness and death in over 50% of patients who die because of severe burns.¹ The significance of smoke inhalation alone and the complications that may follow is often not appreciated in the absence of cutaneous burns. The following case report illustrates a delayed complication resulting in airway obstruction, which occurred following asphyxia secondary to smoke inhalation, with no direct burns of the body.

Case report

A 2-year-old, 9.6-kg boy was admitted to hospital after inhaling smoke while

trapped in a fire on the second floor of his parents' house. When the child was rescued by firemen the floor and contents of his room were burning but he and his crib had not been burned directly. There were, however, copious soot stains on his face and blankets. He was unconscious for 15 to 30 minutes following rescue but was alert by the time of hospital admission.

Cyanosis was absent but moderate sternal retraction was noted. Diffuse sibilant rhonchi and coarse crepitations were heard throughout both lung fields. Chest radiograph was normal.

His health had previously been good except for mild mental retardation and slow development.

He was given intravenously (IV) hydrocortisone sodium succinate (Solu-Cortef), 50 mg q6h, ampicillin, 125 mg q6h, and fluids in a croupette with added oxygen and mist. Over the next 48 hours respiratory distress increased. Cyanosis, increased respiratory effort and exaggerated sternal and intercostal indrawing followed several coughing episodes. After the most severe of these on the 3rd hospital day he became flaccid, comatose and peripherally mottled, and air entry was poor. Assisted ventilation by Ambu bag, mask and oropharyngeal airway was required for approximately 2 hours. Epinephrine, 0.5 ml of a 1/1000 solution given subcutaneously, did not improve breath sounds.

Because of deterioration he was transferred to the Kingston General Hospital that day. On arrival he was alert. His heart rate was 104 beats/min, respiratory rate was 50/min and rectal temperature was 37°C. Mottling was present over the buttocks and lower limbs. Central cyanosis was observed while he was breathing room air. Mild pharyngeal hyperemia was present but there was no evidence of burns in the nose or throat and no stridor. Breath sounds were heard bilaterally; the expiratory phase was moderately prolonged. Coarse expiratory rhonchi and crepitations were present diffusely in the lungs. No sternal or intercostal indrawing was seen. There were no cardiac murmurs or findings suggestive of congestive heart failure.

Hemoglobin value was 10.5 g/dl and leukocyte count, $14.4 \times 10^9/l$ with a normal differential count. Values for serum electrolytes, blood urea nitrogen and blood glucose were normal. While the child was breathing approximately 30% oxygen in a croupette, arterial blood gas values were as follows: pH, 7.40; P_{O_2} , 85 mm Hg; P_{CO_2} , 35 mm Hg; standard bicarbonate, 22 mmol/l; and arterial oxygen saturation, 96.5%. Central lung markings were prominent bilaterally on the chest radiograph and were interpreted as signs of probable peribronchial inflammatory change, but there was no evidence of parenchymal infiltration.

Two hours after admission, while the child was undergoing a cutdown for intravenous therapy, severe respiratory distress occurred suddenly. He rapidly became unresponsive, with cyanosis, tachycardia and tachypnea. High-pitched, sibilant expiratory rhonchi and decreased air entry were detected diffusely in both lungs. Epinephrine, 0.2 ml of a 1/1000 solution administered subcutaneously, and aminophylline, 50 mg IV, produced no improvement. A 4.0-mm Portex oral endotracheal tube was inserted and ventilation was controlled, with difficulty because of poor lung compliance. Suctioning of the airway via the endotracheal tube yielded scanty loose, soot-stained mucus initially. With persistence, however, two plugs of dense material resembling tissue, 3.5 x 0.3 cm and 5 x 0.2 cm, were recovered. Lung compliance and breath sounds improved immediately and the rhonchi diminished. When spread out, the aspirated material was seen to consist of dense, whitish-grey, soot-stained spiral casts of the bronchial tree (Figs. 1, 2 and 3). Histologic study showed their

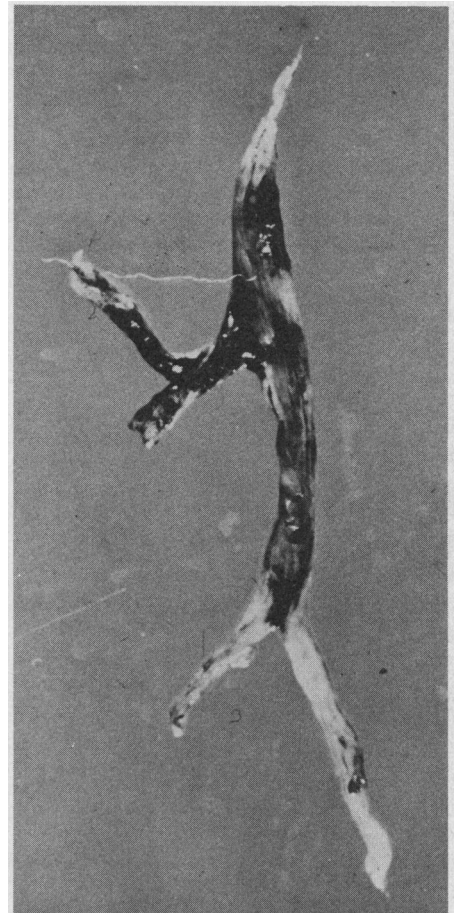


FIG. 1—Small cast obtained initially by suctioning through endotracheal tube following airway obstruction due to smoke inhalation.

From the departments of anesthesia (S.P.P.) and pediatrics (D.J.D.), Kingston General Hospital, Queen's University, Kingston, Ont.

Reprint requests to: Dr. S.P. Pietak, Department of anesthesia, Queen's University, Kingston, ON K7L 3N6

composition to be fibrin, mucus, black pigment, cellular debris and acute as well as chronic inflammatory cell infiltrates. In view of the size of the casts, bronchoscopy was not performed.

No further assistance to ventilation was required. The endotracheal tube was maintained for further suctioning and chest physiotherapy and was humidified via a Puritan nebulizer and a T-piece. While the child was breathing 40% oxygen the blood gas values were as follows: arterial pH, 7.54; PO_2 , 157 mm Hg; PCO_2 , 22 mm Hg; standard bicarbonate, 18 mmol/l; and arterial oxygen saturation, 98%. Gram-staining of the sputum revealed gram-positive cocci and pus cells. Methicillin, 125 mg IV q6h, was then added to the treatment regimen for 7 days. Ampicillin was continued at 750 mg IV q6h for 3 days. Aminophylline and epinephrine were not required subsequently. Hydrocortisone sodium succinate, 50 mg IV q6h, was continued for three more doses. Postural drainage and percussion were performed hourly for the next 20 hours. No further respiratory difficulty was noted and no additional casts were obtained by suction.

The morning after intubation no gas leak was audible around the endotracheal tube on manual inflation of the lungs. Because a leak had been detected the previous day, it was thought desirable to remove the tube and, if necessary, replace it with a smaller nasotracheal tube. Following removal of the tube there was no stridor and although the cough was hoarse it produced loose sputum. A nasotracheal tube was not inserted and the child was observed closely while chest physiotherapy was continued. His subsequent course was uneventful. The next day, while he was breathing humidified room air, the arterial blood gas values were as follows: pH, 7.44; PO_2 , 74 mm Hg; PCO_2 , 39 mm Hg; standard bicarbonate, 26 mmol/l; and arterial oxygen saturation, 96%. Chest

radiograph showed scattered atelectatic densities in the right upper and left lower lobes. Eight days after the smoke inhalation the radiographic appearance was normal, and 5 days later the child was discharged home.

Discussion

Respiratory damage following smoke inhalation and thermal injury is not uncommon. Of a series of 932 burned patients reviewed by Phillips and Cope,² 19% had respiratory symptoms. Of those burned about the mouth and nose 59% had respiratory difficulty. Serious pulmonary damage following smoke inhalation without any burn injury was much less common: only seven patients were sufficiently ill to require hospitalization, and of these, the two who were unconscious at the time of rescue had the serious findings of cyanosis, stridor and sternal retraction. One other patient who had mild respiratory difficulties was only dazed by the smoke exposure but the pharynx was hyperemic. Confinement in an enclosed space during inhalation increases the risk of serious pulmonary damage: almost 50% of the patients who were burned indoors had respiratory difficulties, compared with 13% who were burned outdoors.

Smoke contains numerous toxic chemicals that may cause airway damage, producing edema and inflammatory changes of both the upper and lower respiratory tract, copious mucus and frequently a fibrin-like pseudomembrane.¹ In addition to trapping bacteria and secretions, the pseudomembrane may dislodge, occluding major airways, as in this case, or may

fragment, obstructing small airways and thus causing atelectasis and pneumonia. The presence of airway edema and cellular and exudative debris also results in physical findings suggestive of intense bronchospasm resistant to bronchodilator therapy.

The amount of chemical trauma to the lung depends in part on the material that was burning. Burning wood, cotton and newspaper yield acetaldehyde, acetic acid, formaldehyde and methane, while burning wool and silk yield ammonia, hydrogen sulfide and hydrogen cyanide.³ Heat itself is relatively unimportant in injury to the lower respiratory tract, for most is absorbed by the larynx and upper airway.⁴

In the present case the asphyxia, causing unconsciousness, the hyperemic pharynx and sibilant rhonchi, and the respiratory distress evident by the time of admission were important prognostic indications of serious pulmonary damage. Somewhat unusual was the occurrence of diffuse airway injury without evidence of laryngeal edema and without radiologic evidence of pulmonary damage.

The management of such cases depends greatly on the history, physical findings and subsequent complications. For purposes of classification, complications can be grouped as follows: acute-stage injuries, presenting within 48 hours of exposure; delayed complications, appearing within 2 to 5 days; and complications occurring weeks to months later. During initial resuscitation, hypoxia is a major problem in all patients sufficiently ill to manifest respiratory distress. The rapidly progressive bronchospasm and airway edema produce maldistribution of inspired gas, with resultant increases in pulmonary venous admixture. Supplemental oxygen administered by mask during resuscitation, transport and evaluation is vital because carbon monoxide poisoning may be increasing the tissue hypoxia. Subsequent management in hospital must be guided by arterial blood gas values. Following the child's admission to our hospital, oxygen therapy was directed at maintaining an arterial oxygen tension of between 80 and 100 mm Hg, with as low an inspired oxygen concentration as possible to prevent oxygen toxicity.

During the early hours in hospital the patient must be observed closely for development of upper airway obstruction with stridor and impending respiratory acidosis. Serious laryngeal edema necessitates endotracheal intubation and often tracheostomy, especially when the pulmonary injury is diffuse. Allen and Steven⁵ have successfully treated children, without subsequent laryngeal damage, by pro-

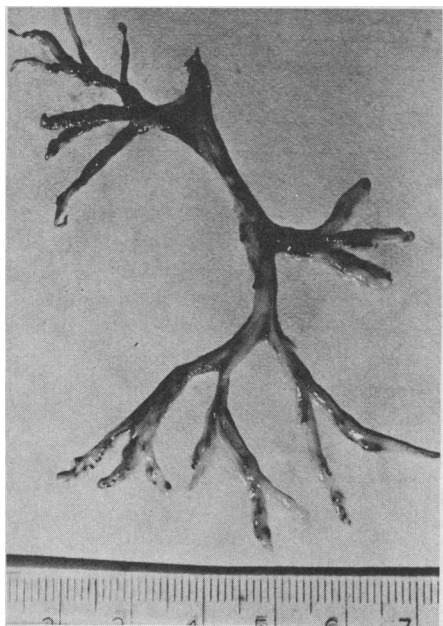


FIG. 2—Pseudomembranous cast removed by suction through endotracheal tube. Note resemblance to right lobar bronchial pattern.

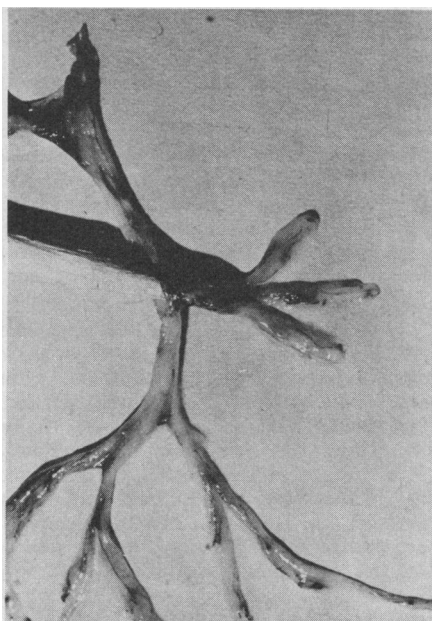


FIG. 3—Cast of Fig. 2, with probe cannulating main branch to demonstrate tubular configuration.

longed nasotracheal intubation with a small tube having a large air leak around it. In the presence of poor pulmonary compliance, requiring assisted ventilation, and viscous secretions, which easily plug and crust in small tubes, a tracheostomy is safer and easier to manage. Our patient probably escaped tracheostomy because of the clearance of the large casts and the lack of laryngeal edema. Prophylactic tracheostomy is not favoured because of the high risk of airway contamination, pneumonia and tracheomalacia when the cannula is removed in young children. Endotracheal intubation, tracheostomy and assisted ventilation are indicated also when the child cannot cough and is becoming hypoxic and exhausted because of lower airway obstruction, even if carbon dioxide is not yet being retained.

When artificial ventilation is undertaken, strict aseptic techniques of hand-washing, masking and gloving should be observed during tracheobronchial toilet, for cross-contamination by medical personnel is the major source of infection in these patients.⁶ Adequate humidification is vital to prevent airway crusting and plug formation, but the potential of humidifiers and nebulizers to disseminate infection should be remembered and such equipment should be changed every 12 hours.

The use of prophylactic broad-spectrum antibiotics upon admission to hospital is favoured by many in view of the injury and debris present. In the experience of Di Vincenti, Pruitt and Reckler⁷ pneumonia commonly developed as a delayed complication by the 3rd to 5th day after inhalation. In order of frequency the causative organisms were *Staphylococcus*, *Klebsiella-Aerobacter*, *Escherichia coli* and *Pseudomonas aeruginosa*. Indiscriminate use of broad-spectrum antibiotics enhances selection of one of these more resistant organisms. It is preferable to base antibiotic selection and use on the results of daily examination of Gram-stained sputum and clinical indications, even if sputum samples must be obtained by direct suction. For this reason methicillin was added in our case, although the value of the continued use of ampicillin at the same time is debatable.

During the acute phase of inhalation injury, bronchospasm and airway edema are major complications requiring therapy. Although it is difficult to separate reversible bronchospasm from obstruction due to edema and necrotic debris, optimal plasma concentrations of bronchodilators should be sought. Aminophylline, 6 mg/kg IV over 20 minutes, followed by a con-

stant intravenous infusion of 1.1 mg/kg·h, has been recommended by Piafsky and Ogilvie⁸ to produce a plasma concentration of 5 to 10 mg/dl. If a satisfactory response is not obtained and toxic symptoms do not appear, further doses of 3 mg/kg and 1.65 mg/kg·h can be given. If acidosis is present it should be controlled by artificial ventilation and intravenous administration of bicarbonate solution to obtain maximum effects from the bronchodilator.⁹

The use of steroids in the management of these patients is controversial. It is difficult to prove that steroids are of much benefit in reducing airway edema and obstruction. The risks of enhancing pulmonary infections and gastric erosions with stress must be weighed against the advantages of these drugs as bronchodilators. If bronchoconstriction is not adequately controlled by aminophylline, trial therapy with a steroid for 48 to 72 hours is justified in an attempt to avoid endotracheal intubation and assisted ventilation.⁷ Steroids with pure glucocorticoid activity, such as methylprednisolone or dexamethasone, may be preferable to hydrocortisone since the first two do not cause sodium retention and fluid overload. Because well controlled studies on the use of steroids are scarce, it is difficult to recommend their use or the most beneficial dose.

During the delayed phase of pulmonary complications progressive pulmonary dysfunction may develop as airway obstruction, atelectasis and pneumonia progress. It is common to obtain soot-stained mucus and necrotic debris during suctioning or coughing, but the size and completeness of the casts obtained in our patient are uncommon. Vigorous chest physiotherapy with percussion, vibration and hourly turning of the patient are important in preventing pooling of secretions. Nurses and physiotherapists must be aware of the possible causes of a sudden attack of respiratory distress following an episode of coughing or during physiotherapy. Facilities should be available at the bedside for immediate endotracheal intubation and suction or bronchoscopy.

If secretions are viscous and difficult to remove by suctioning, 1 to 2 ml of isotonic saline may be instilled in the trachea prior to suctioning. Bronchoscopy may be required if this technique fails; however, the procedure is technically difficult in a 10-kg child and relatively traumatic to an airway that is already injured.

In our patient the lack of upper airway obstruction from edema and the ability of the nursing staff to keep the child free from retained secretions

by postural drainage and chest physiotherapy were likely the most important factors in his uneventful recovery. Nevertheless, complications such as bronchiectasis and bronchial stenosis can occur later,⁷ so long-term follow-up is required.

References

- HARRISON HN: Respiratory tract injury, pathophysiology and response to therapy among burned patients. *Ann NY Acad Sci* 150: 627, 1968
- PHILLIPS AW, COPE O: Burn therapy. III. Beware the facial burn! *Ann Surg* 156: 759, 1962
- THOMAS DM, CONNOR EH: Management of the patient "overcome by smoke". *J Ky Med Assoc* 66: 1051, 1968
- MORITZ AR, HENRIQUES FC JR, MCLEAN R: The effects of inhaled heat on the air passages and lungs. *Am J Pathol* 21: 311, 1945
- ALLEN TH, STEVEN IM: Prolonged nasotracheal intubation in infants and children. *Br J Anaesth* 44: 835, 1972
- LOWBURY EJ, THOM BT, LILLY HA, et al: Sources of infection with *Pseudomonas aeruginosa* in patients with tracheostomy. *J Med Microbiol* 3: 39, 1970
- DI VINCENTI FC, PRUITT BA JR, RECKLER JM: Inhalation injuries. *J Trauma* 11: 109, 1971
- PIAFSKY KM, OGILVIE RI: Drug therapy: dosage of theophylline in bronchial asthma. *N Engl J Med* 292: 1218, 1975
- MITHOEFER JC, PORTER WF, KARETZKY MS: Indications for the use of sodium bicarbonate in the treatment of intractable asthma. *Respiration* 25: 201, 1968

Environmental carcinogens

According to one estimate, 80 to 90% of all cancers are directly or indirectly caused by environmental factors, particularly chemical agents. In industry the main agents are asbestos dust, vinyl chloride monomer, chromate pigments and dyestuff intermediates. Other environmental hazards of concern to the general population are benzo[a]-pyrene (in exhausts of jets and cars) and nitrosamines (in the atmosphere and some food products).

Analysis and determination of environmental carcinogens is today much more sophisticated than it was even a few years ago. Similarly, many countries have enforced environmental protection regulations quite recently. Even so, protection against carcinogenic agents remains expensive.

A "wait and see" attitude toward environmental carcinogenesis is no longer acceptable. Predictive tests, long-term tests and rapid screening tests will likely become essential arms of health policy.

(Source: Cancer hazards in the environment. *WHO Chron* 30: 121, 1976)