Lung density: clinical method for quantitation of pulmonary congestion and edema

E.S. Garnett, mb, frcp[c]; C.E. Webber, m phil; G. Coates, mb; W.P. Cockshott, mb, frcp[c];
C. Nahmias, b sc; N. Lassen, md

The density of a defined volume of the human lung can be measured in vivo by a new noninvasive technique. A beam of γ-rays is directed at the lung and, by measuring the scattered γ-rays, lung density is calculated. The density in the lower lobe of the right lung in normal man during quiet breathing in the sitting position ranged from 0.25 to 0.37 g•cm^{-3}. Subnormal values were found in patients with emphysema. In patients with pulmonary congestion and edema, lung density values ranged from 0.33 to 0.93 g•cm^{-3}.

The lung density measurement correlated well with the findings in chest radiographs but the lung density values were more sensitive indices. This was particularly evident in serial observations of individual patients.

On peut mesurer in vivo la densité d'un volume défini de poumon humain au moyen d'une nouvelle technique nontraumatique. Un faisceau de rayons γ est dirigé sur le poumon, dont on calcule la densité en mesurant les rayons γ dispersés. La densité du lobe inférieur du poumon droit chez l'homme normal en position assise durant la respiration calme a varié de 0.25 à 0.37 g•cm^{-3}. Des valeurs sous la normale ont été retrouvées chez des patients souffrant d'emphysème. Chez les patients atteints de congestion pulmonaire et d'oedème, la densité a varié de 0.33 à 0.93 g•cm^{-3}.

La mesure de la densité pulmonaire a montré une bonne corrélation avec les résultats des radiographies thoraciques mais les valeurs de densité pulmonaire ont procuré un index plus sensible. Ceci a été particulièrement évident dans les observations sériées chez des patients individuels.

Physical examination of the chest and chest radiography are the methods available for assessing clinically suspected congestion and edema of the lung. These methods are subjective and qualitative rather than quantitative. The auscultatory signs are notoriously late to develop.[1] Radiographic changes may be subtle, so careful technique and interpretation are essential for evaluation.[2] Several complex techniques have been proposed for the quantitation of both congestion and edema: chest impedance and indicator injection methods and recently an indicator inhalation method.[3,4] The indicator techniques at best measure only half the extravascular water even in the normal lung.[5] A microwave method has recently been investigated but again the results are largely qualitative.[6]

We have developed a simple, atraumatic, bedside procedure that measures lung density — the mass of lung tissue, blood and interstitial fluid per unit volume of lung. The procedure is based on the Compton scatter principle, which has been applied to clinical measurement of bone density.[7,8] Preliminary data on lung density in children,[9] dogs[10] and healthy adult humans[11] have been described. We report the results of measurements in healthy volunteers and patients in whom pulmonary venous congestion or pulmonary edema was suspected clinically.

Methods and subjects

Methods

When monoenergetic γ-rays impinge upon any tissue the density of a defined volume of that tissue can be determined by measuring the scattered fraction of the incident γ-rays.

From a 1.5-Ci source of radioactive samarium (^{153}Sm) 103-keV γ-rays are directed at the lower lobe of the right lung through a lead collimator (bore, 6 mm; length, 2.5 cm). Two NaI (Tl) detectors (2.5 cm x 0.75 mm) are collimated in the same way as the incident beam. One is positioned in line with the beam from the ^{153}Sm source and the other at right angles to the beam; the first detects the transmitted photons and the second, the scattered photons. Corrections for attenuation of the incident and scattered beams are made by means of an 84-keV source of radioactive thulium (^{170}Tm) placed opposite the detector of scattered photons. The sources and detectors are mounted on an adjustable horizontal C-frame. The details of the correction procedure and the calculation of the result are similar to those already described for the measurement of bone density.[8] Corrections for multiple scattering[12] were made with the use of phantoms constructed of wooden blocks of known density.

Measurements are made with the patient sitting either on a chair or in bed and breathing quietly. The location of the volume of the lung being measured is defined from frontal and lateral radiographs obtained after radiopaque skin markers have been placed on the sites of entry and exit of the incident and scattered ^{153}Sm beams, respectively.

During each 15-minute procedure a calculated maximum dose of 1 rad was absorbed by the volume of lung examined. The error in the density measurement, due to counting statistics, was 4% and the procedure gave reproducible results within the limits of the method. Five measurements of lung density in the same subject were within the range 0.32 to 0.36 g•cm^{-3}.

Comparisons were made between the measured lung density and a radiologic assessment of pulmonary congestion and edema by two independent observers using the arbitrary scoring system shown in Table I.

Subjects

Six members of staff aged 20 to 50

Table I—Arbitrary scoring system for radiologic assessment of pulmonary congestion and edema

Feature	No. of points
Prominence of upper lobe veins	+ 1
Upper lobe vein larger than lower lobe vein	+ 1
Blurring of outline of perihilar structures	+ 1
Kerley lines	+ 1
Pulmonary edema	+ 1
Fluid in pleural cavity	+ 1
Local factor affecting lung density	+ 1
Radiologic evidence of emphysema	− 2

From the department of radiology, McMaster University, and the department of clinical physiology, Bispebjerg Hospital, Copenhagen

Reprint requests to: Dr. E.S. Garnett, Department of nuclear medicine, McMaster University Medical Centre, Hamilton, Ont. L8S 4J9

years who understood the nature of the procedure served as healthy control subjects.

Thirty-eight patients aged 40 to 80 years with left-sided heart failure were studied. Pulmonary congestion or edema or both had been diagnosed by routine clinical procedures in all. Because some had various degrees of obstructive airway disease, two patients with gross clinical emphysema but without evidence of heart failure were also studied.

Results

In the six control subjects lung density averaged 0.32 g•cm^{-3} (range, 0.25 to 0.37 g•cm^{-3}). In the two patients with emphysema it was 0.11 and 0.28 g•cm^{-3}. In the patients with pulmonary congestion and edema the range was 0.33 to 0.93 g•cm^{-3}.

Lung density and radiologic scores are compared in Fig. 1, and the changes in lung density that occurred during the course of therapy in eight patients are shown in Fig. 2.

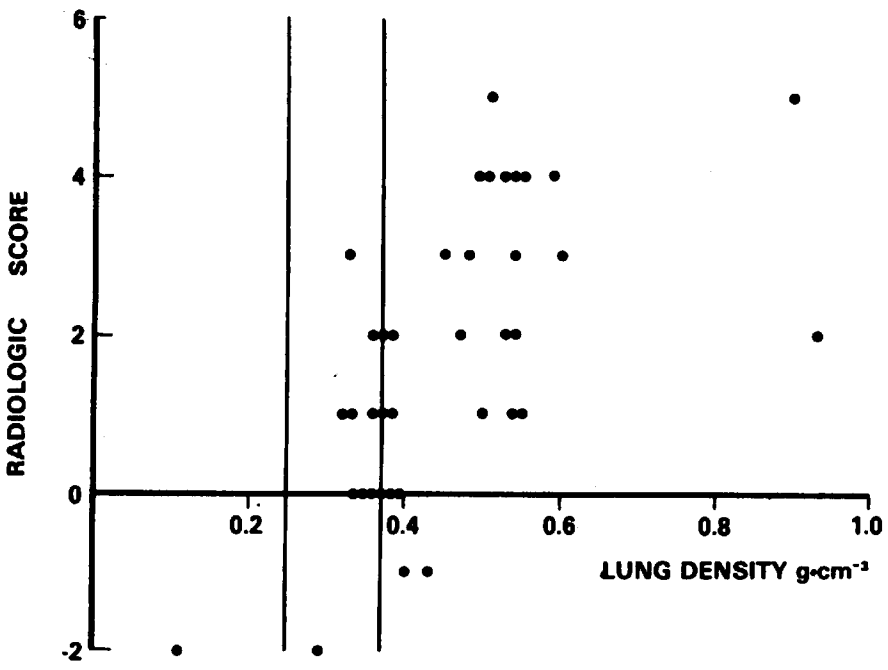

FIG. 1—Comparison between radiologic assessment of pulmonary congestion and edema and Compton scatter measurement of lung density. Vertical lines indicate normal range for lung density.

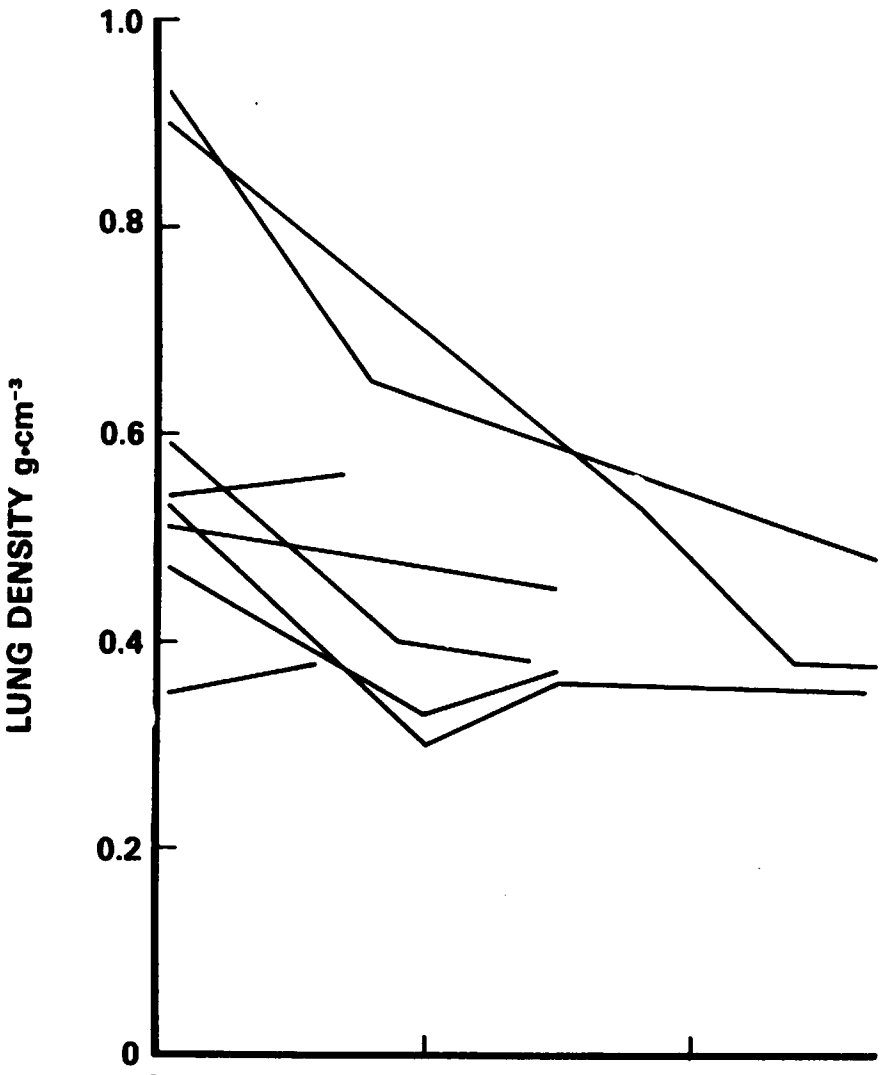

FIG. 2—Changes in lung density during treatment of pulmonary congestion and edema.

Discussion

The Compton scatter technique for the measurement of lung density gives reproducible results and in normal man the range of values is narrow. Clearly the degree of inflation of the lung will influence its density. Therefore all measurements should be made during quiet tidal breathing; thus density is averaged for a defined intrathoracic volume over a period of time. Tidal breathing at high lung volume produces densities in the range we found in patients with emphysema.

The range of values for lung density that we found in healthy adults agrees with that recently reported by Gamsu and colleagues[11] — 0.21 to 0.31 g•cm^{-3} in a selected group of seated healthy subjects; they did not study anyone with abnormal lungs. Reiss and Schuster[9] measured lung density in children: in healthy children less than 6 years of age, values ranged from 0.30 to 0.46 g•cm^{-3}, while in children of the same age with pneumonia, values were as high as 0.72 g•cm^{-3}. It is known that the number of alveoli in the lung increases exponentially up to the age of 8 years, during which time the volume proportion of lung tissue declines.[13] It is therefore not unreasonable to expect that the lung density of a child will be greater than that of an adult.

The range of density in the cardiac patients was wide. A patient with a large pleural effusion would be expected to have a lung density of approximately 1.0 if the volume measured lay within the area of effusion. On the other hand a patient who had been adequately treated would be expected to have a lung density in the normal range (Fig. 2). Thus a sensitive and simple method of measuring lung density may help the physician assess a patient's progress, particularly since radiologic changes lag behind clinical improvement. We found that approximately 20% of recovering patients had radiologic evidence of pulmonary congestion at a time when their lung density was normal (Fig. 1). Whether the same applies during the onset of left-sided decompensation is unknown but likely. Accordingly, the density readings can provide a precise quantitative clinical measurement for assessing alterations in pulmonary circulation.

Radiologic assessment of pulmonary congestion is subjective. In addition, interpretation of the accepted signs is still contentious.[14] The coexistence of emphysema and congestion may explain some of the variance between radiologic scores and lung density.

Unlike the more complicated techniques that measure only a fraction of total lung water, measurements of lung density include all of the water and tissue. Although current techniques for measuring lung density give no information about the distribution of this water within the vascular or extravascular compartment, even this information may become available if a suitable physical method can be devised.

Other approaches to the problem of the quantitation of lung density would include the measurement of either scattered or attenuated x-rays. This technique forms the basis of computer-assisted tomography (CAT), from which a measurement related to density can be obtained. However, CAT scanners are still very expensive. Our instrument costs only a fraction of that of a CAT scanner and can be used readily in an intensive care unit.

We thank Dominion Foundries and Steel Limited for their generous financial support.

References

1. Wood PH: *Diseases of the Heart and Circulation*, 3rd ed, Philadelphia, Lippincott, 1968, p 57
2. Chait A: Interstitial pulmonary edema. *Circulation* 45: 1323, 1972
3. Staub NC: Pulmonary edema. *Physiol Rev* 54: 678, 1974
4. Louderbough H, Ozanne G, Severinghaus JW: Lung weight and pulmonary blood flow determination in man and dogs by soluble gas uptake. *Fed Proc* 35: 792, 1976
5. Chinard FP: Estimation of extravascular lung water by indicator-dilution techniques. *Circ Res* 37: 137, 1975
6. Bragg DG, Durney CH, Pederson PC, et al: Monitoring and diagnosis of pulmonary abnormalities by microwave radiography (abstr 12), in *Proceedings of the Association of University Radiologists*, Boston, May 1976, p 3
7. Garnett ES, Kennett TJ, Kenyon DB, et al: A photon scattering technique for the measurement of absolute bone density in man. *Radiology* 106: 209, 1973
8. Webber CE, Kennett TJ: Bone density measured by photon scattering — a system for clinical use. *Phys Med Biol* 21: 760, 1976
9. Reiss KH, Schuster W: Quantitative measurements of lung function in children by means of Compton back scatter. *Radiology* 102: 613, 1972
10. Kaufman L, Gamsu G, Savoca S, et al: Measurement of absolute lung density by Compton-scatter densitometry. *IEEE Trans Nucl Sci* 23: 594, 1976
11. Gamsu G, Kaufman L, Savoca C, et al: Absolute lung density in canine pulmonary edema (abstr 116), in *Proceedings of the Association of University Radiologists*, op cit, p 11
12. Kennett TJ, Webber CE: Bone density measured by photon scattering: inherent sources of error. *Phys Med Biol* 21: 770, 1976
13. Dunnill MS: Postnatal growth of the lung. *Thorax* 17: 329, 1962
14. Grainger RG: Septal lines. *Lancet* 1: 753, 1976