

# Development of Osteoarthritic Lesions in Mice by "Metabolic" and "Mechanical" Alterations in the Knee Joints

Peter M. van der Kraan, Elly L. Vitters,  
Levinus B. A. van de Putte,  
and Wim B. van den Berg

From the Department of Rheumatology, Academic  
Hospital St. Radboud, Geert Grooteplein zuid 8,  
6525 GA Nijmegen, The Netherlands

*Male, 10-week-old C57B110 mice received a single intraarticular injection in the knee joints with papain, iodoacetate, or collagenase. This led to osteoarthritic lesions, such as matrix depletion, chondrocyte proliferation, and osteophyte formation, in the injected knee joints within several weeks. After injection of iodoacetate and papain, the main osteoarthritic alterations were localized in the femoropatellar joint, whereas injection of collagenase led to marked osteoarthritic lesions in the femorotibial joint. The mechanism of induction of these alterations appears to differ for iodoacetate and papain on one site and collagenase on the other site. Data are presented that collagenase injection, by way of damaging ligaments and tendons, destabilizes the knee joint eventually leading to osteoarthritic alterations. In contrast, injection of papain or iodoacetate directly interferes with cartilage metabolism resulting in osteoarthritic changes. (Am J Pathol 1989, 135:1001-1014)*

Osteoarthritis is an age-related disease of diarthrodial joints in which the predominant characteristic is degeneration of articular cartilage.<sup>1</sup> This process is often associated with proliferation of chondrocytes and formation of new cartilage and bone at joint margins leading to the formation of osteophytes. Osteoarthritis is presently considered the clinicopathologic consequence of various etiologic factors, and most researchers agree that osteoarthritis is not a single disease entity.<sup>1,2</sup> The various forms of human osteoarthritis can be characterized as the result of abnormal biomechanical stress or intrinsic or acquired abnormalities of articular cartilage. The final common

pathway of this multifactorial disease is disturbed cartilage integrity.

Many changes occur in the articular cartilage as a result of the osteoarthritic process. Hydration of the extracellular matrix and the extractability of proteoglycans is increased in osteoarthritic cartilage compared with normal cartilage, both in human and experimental osteoarthritis.<sup>3-5</sup> Synthesis of cartilage proteoglycans is increased while the quantity of proteoglycans is reduced in osteoarthritic cartilage, indicating a highly increased breakdown of proteoglycans.<sup>6-9</sup> Also, changes in the biochemical properties of proteoglycans from osteoarthritic cartilage were reported.<sup>5,11-15</sup> The normally nonproliferating articular cartilage chondrocytes are stimulated to divide as a result of the osteoarthritic process.<sup>3,16-24</sup>

Besides changes in the articular cartilage, other joint structures also undergo alterations in the osteoarthritic joints. Formation of osteophytes at the joint margins is highly associated with the osteoarthritic changes in the articular cartilage.<sup>16-26</sup> Proliferation of synovial cells is observed both in human osteoarthritis and in animal models.<sup>18,21,24,27-31</sup> Another phenomenon seen in osteoarthritic joints is sclerosis of subchondral bone below the degenerated cartilage.<sup>17,24,25,32,33</sup> These observations point to anabolic processes in the joint, in addition to the catabolic degeneration of articular cartilage.

Because the pathogenesis of osteoarthritis can not be adequately studied in humans, interest has been directed to animal models of osteoarthritis that simulate the human disease. Spontaneous osteoarthritis has been studied in mice, guinea pigs, and dogs.<sup>4,24,25,33-40</sup> In addition, osteoarthritis was induced in animal knee joints in two different ways, induction of instability of the joint by surgical methods and intra-articular injection of chemicals interfering with cartilage metabolism. Induction of joint instability has been carried out by partial meniscectomy, frequently in combination with dissection of collateral ligaments, and

---

This work was supported by the Dutch League against Rheumatism.

Accepted for publication July 28, 1989.

Address reprint requests to Peter M. van der Kraan, Department of Rheumatology, Academic Hospital St. Radboud, Geert Grooteplein zuid 8, 6525 GA, Nijmegen, The Netherlands.

dissection of cruciate ligaments or myectomy.<sup>5,9,14,18-23,27,41-44</sup> The intra-articular injection of papain or sodium iodoacetate leads to osteoarthritic alterations in the injected joints.<sup>45-57</sup>

Because osteoarthritis is considered to be the final result of a multifactorial pathogenesis, we used three different ways of osteoarthritis induction in C57B110 mice. Knee joints of the mice were injected with papain, sodium iodoacetate, or collagenase. Papain induces degeneration of cartilage proteoglycans, sodium iodoacetate is an inhibitor of cell metabolism, and collagenase mainly attacks joint structures such as tendons and ligaments that contain collagen type I.

## Materials and Methods

### Animals

Male C57B1/10 mice aged 10 weeks were used in all experiments. The animals were kept in boxes in an air-conditioned room at constant temperature and were fed a standard laboratory diet (Hope Farms, Deventer, The Netherlands) with access to tap water *ad libitum*.

### Induction of Osteoarthritis

The right knee joints of the mice were injected once, intra-articularly through the patellar ligament, with a 6-ml solution of papain, sodium iodoacetate, or collagenase. The left control knee joint was injected with 6  $\mu$ l physiologic saline. Papain (type IV, double crystallized, 15 units/mg, Sigma Chemical Co., St. Louis, MO) was used in a concentration of 0.5%, 1.0%, and 2.0% (w/v), and these solutions were supplemented with 0.03 M L-cysteine HCl (Sigma) to activate the papain. Sodium iodoacetate (Sigma) was injected in a concentration of 0.1%, 0.5%, and 1.0% (w/v), whereas collagenase (Clostridial, 248 units/mg, Worthington Biochemical Corporation, Freehold, NJ) was injected in the following concentrations: 0.5%, 1.0%, and 1.5% (w/v). Before injection the solutions were filtered through a 0.2- $\mu$ m filter to remove bacteria.

### Histology

Groups of five mice injected with papain or collagenase were killed by cervical dislocation 1, 3, 7, 21, and 42 days after intra-articular injection, whereas an additional group of mice injected with iodoacetate was also killed after 64 days. Carefully dissected knee joints were fixed in phosphate-buffered formalin (pH 7.4) for 5 days and subsequently decalcified in 5% formic acid for 4 days. Standard

processing of the knee joints in an automatic tissue processing apparatus was followed by embedding of the knee joints in paraffin wax. Frontal whole knee joint sections were prepared (6  $\mu$ m) and stained with safranin O and fast green.

### Determination of Joint Swelling

Soft tissue joint swelling after intra-articular injection was assayed on day 1, 3, 7, 21, 41, and 64 (iodoacetate) by the <sup>99</sup>Tc-pertechnetate uptake method as described previously.<sup>58</sup> In short, mice were injected with 15  $\mu$ Ci <sup>99m</sup>Tc and sedated with choral hydrate (intraperitoneally). After 30 minutes, the quantity of radiolabel in the right and left knee joints was determined by measuring the gamma radiation with a collimated NaI-scintillation crystal while the knee joint was in a fixed position. Joint swelling was scored as the ratio of the radiolabel in the right and the left knee joint.

### Glycosaminoglycan Synthesis

After 1, 3, 7, 21, 42, and 64 (iodoacetate) days, groups of five mice were killed and the whole patellae, along with a standard amount of surrounding tissue, were dissected from both the left and the right knee joints, according to the method of van den Berg et al.<sup>59</sup> Patellae were incubated in RPMI 1640 DM medium (Flow Laboratories, Irvine, UK) containing 20  $\mu$ Ci [<sup>35</sup>S]sulfate (1200 Ci/mmol, Radiochemical Centre Amersham, Amersham, UK) for 2 hours at 37 C in a humidified 5% CO<sub>2</sub> atmosphere. The inorganic sulfate concentration was 0.8 mM. After incubation the patellae were washed twice with physiologic saline to remove nonincorporated label and fixed in 4% phosphate-buffered formalin (pH 7.4). The patellae were isolated from the surrounding tissue after overnight decalcification in 5% formic acid. The patellae were digested with Lumasolve (Hicol, Oud-Beijerland, The Netherlands), and the incorporated radiolabel was determined by liquid scintillation counting. Radiolabel is incorporated almost exclusively in the proteoglycans of the patellar cartilage. Almost no label is found in the underlying bone and bone marrow cells.<sup>60</sup>

### Statistical Evaluation

The glycosaminoglycan synthesis was evaluated by analysis of variance in combination with the two-tailed Student's *T*-test. Joint swelling was evaluated with the Wilcoxon Rank Sum test. A *P* value less than 0.05 was considered significant.

## Results

### Effect of Intra-Articular Injection on Joint Swelling

Papain was injected intra-articularly in the right knee joint of mice in three different concentrations: 0.5%, 1.0% and 2.0%. One day after the injection of 2% papain, the right knee joint was significantly thicker than the left knee joint injected with physiologic saline, as determined by the amount of radiolabel in the knee joints (Figure 1A). At later stages, a significant joint swelling was not observed at any concentration. The injection of 0.5% and 1.0% iodoacetate resulted in a significant joint swelling 1 day after injection, whereas the injection of 0.1% did not result in a significant response (Figure 1B). The injection of collagenase had the most pronounced effects on joint swelling. All concentrations (0.5%, 1.0%, and 1.5%) induced a significant joint swelling on days 1 and 3 after intra-articular injection (Figure 1C).

### Effect of Intra-Articular Injection on Glycosaminoglycan Synthesis

The intra-articular injection of papain resulted in a concentration-dependent inhibition of glycosaminoglycan synthesis in patellar cartilage after 1 day (Figure 2A). After 3 days, the glycosaminoglycan synthesis in the patellae from mouse knees injected with 0.5% or 1.0% papain was significantly elevated, whereas the synthesis in the patellae from knee joints injected with 2% papain was still inhibited. Seven days after the injection of papain, there was a slight but nonsignificant elevation of glycosaminoglycan synthesis in the patellae of all papain-injected knee joints.

Injection of iodoacetate in the knee joints resulted in an inhibition of patellar glycosaminoglycan synthesis of up to more than 80% after 1 day (Figure 2B). The glycosaminoglycan synthesis in the patellae of knee joints injected with 1% iodoacetate continued to be inhibited from day 1 until day 64. However, 3 days after injection of 0.1% iodoacetate, the glycosaminoglycan synthesis in the patellae was significantly increased compared with the control patellae. The patellae from the knee joints injected with 0.5% iodoacetate showed a normal overall synthesis of glycosaminoglycans in the whole patellae after 3 and 7 days but was significantly decreased at later stadia.

Figure 2C shows the effect of collagenase injection on the patellar glycosaminoglycan synthesis. After 1 day, injection of 1.0% or 1.5% collagenase resulted in a significant inhibition of patellar glycosaminoglycan synthesis, whereas a significantly elevated synthesis was observed after injection of 0.5% or 1.5% on day 7. An increased synthesis was also observed at all concentra-

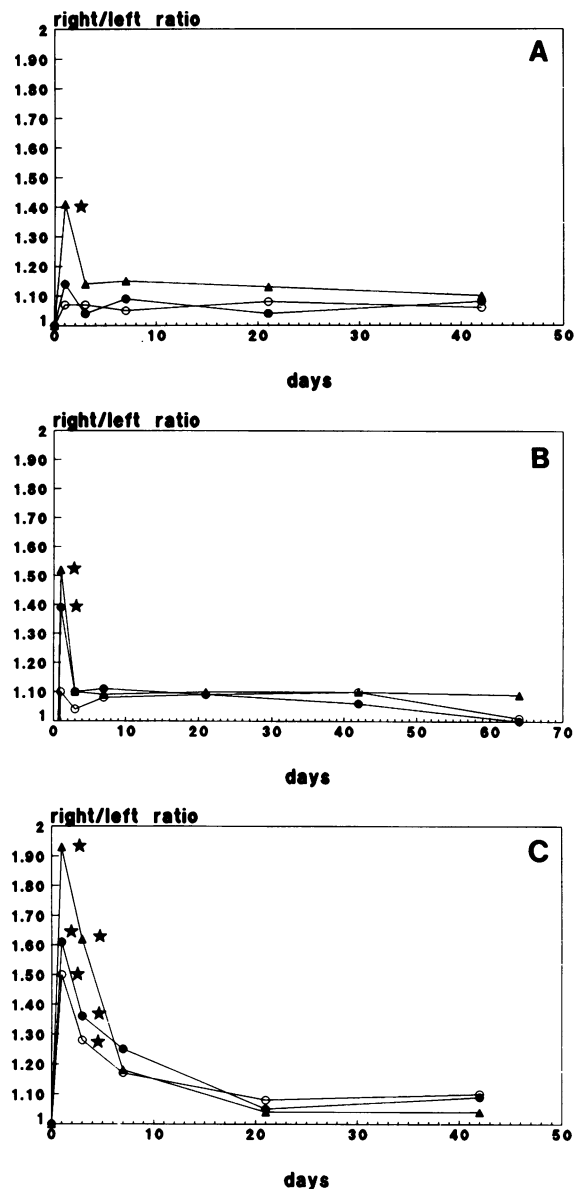
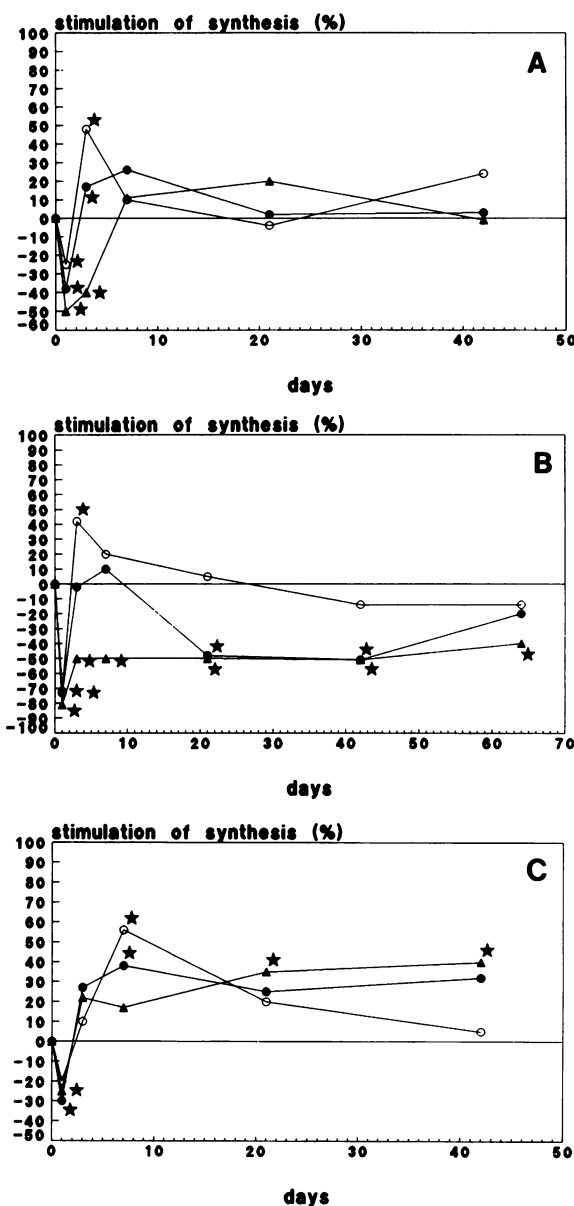


Figure 1. Joint swelling after injection with papain, collagenase, or iodoacetate. Mice were injected with radioactive technetium and after 30 minutes the quantity of radiolabel in the left and right knee joint was determined. Joint swelling was scored as the ratio of the radiolabel in the right to that in the left knee joint. Expressed are mean values of at least five mice. A: Papain 0.5%, 1.0%, and 2.0%. B: Iodoacetate 0.1%, 0.5%, and 1.0%. C: Collagenase 0.5%, 1.0%, and 1.5%. \*, Significantly different from control joints.

tions on day 21 and at 1.0% and 1.5% on day 42, but this was only significant for 1.0%.

### Histologic Observations

Three concentrations of papain, iodoacetate, or collagenase were used to induce osteoarthritic changes in the



**Figure 2.** Glycosaminoglycan synthesis, as measured by sulfate incorporation, in patellar cartilage after injection of papain, iodoacetate, or collagenase. The glycosaminoglycan synthesis is compared with the glycosaminoglycan synthesis in the left control joint. Expressed are the mean values of at least five patellae. A: Papain 0.5%, 1.0%, and 2.0%. B: Iodoacetate 0.1%, 0.5%, and 1.0%. C: Collagenase 0.5%, 1.0%, and 1.5%. \*, Significantly different from control joints.

right knee joints of C57B110 mice. The joint alterations were essentially similar at all three concentrations, and only quantitative differences were observed. The results of 1% papain, 1% collagenase, and 0.5% iodoacetate will be reported, and only major differences at other concentrations will be discussed. The results are summarized in Table 1 and Table 2. Table 1 shows the changes in the articular cartilage, whereas Table 2 presents the changes in other joint structures and the grade of inflammation.

None of the control knee joints showed any evidence of osteoarthritic alterations.

### Day 1

One day after the injection of papain, there was a pronounced depletion of safranin O staining in all the noncalcified articular cartilage of the joint, indicating a reduced proteoglycan concentration (Figure 3). Injection with 2% papain even led to disruption of noncalcified cartilage from the calcified cartilage along the tidemark or to degradation of the cartilage surface. The effect of papain on articular cartilage was most extreme on the central part of the patella. The injection of iodoacetate had no effect on the safranin O staining or structure of the articular cartilage. One day after the intra-articular injection of collagenase, a medial translocation of the patella was observed in four of five injected joints (Figure 4). The cartilage of the patellaris femoris and the patella showed a mild loss of safranin O staining whereas the cartilage of the femorotibial joint was stained normally.

Signs of inflammation were observed in all three models. A low-grade synovial leukocyte infiltration and exudation of inflammatory cells in the joint cavity were found. This was most pronounced in the cavity of the femoropatellar joint.

### Day 3

The depletion of safranin O staining in the femorotibial joint was less marked 3 days rather than 1 day after papain injection. This was not observed in the femoropatellar joint. The intermediate zone of the femorotibial cartilage showed signs of chondrocyte proliferation, and cell clusters could be seen in the safranin O-depleted cartilage. Acellular areas in the tibial cartilage could be seen in the group injected with 2% papain. The knee joints of mice injected with iodoacetate showed a very mild depletion of staining in the central part of the femoropatellar joint, but other changes were not observed. Medial dislocation of the patella was evident in four of five mice injected with collagenase. The depletion of safranin O staining in the femoropatellar joint was decreased compared with the depletion observed 1 day after collagenase injection.

The exudate of inflammatory cells in the joint cavity was greatly reduced compared with the exudate present after 1 day in all three models studied. Only a few cells could still be seen in the joint cavity. A mild infiltration of the synovium with inflammatory cells could still be observed.

**Table 1.** *Histologic Observation of Alterations in the Articular Cartilage of Papain (1%), Iodoacetate (0.5%), and Collagenase (1%) - Injected Knee Joints of Male C57B110 Mice*

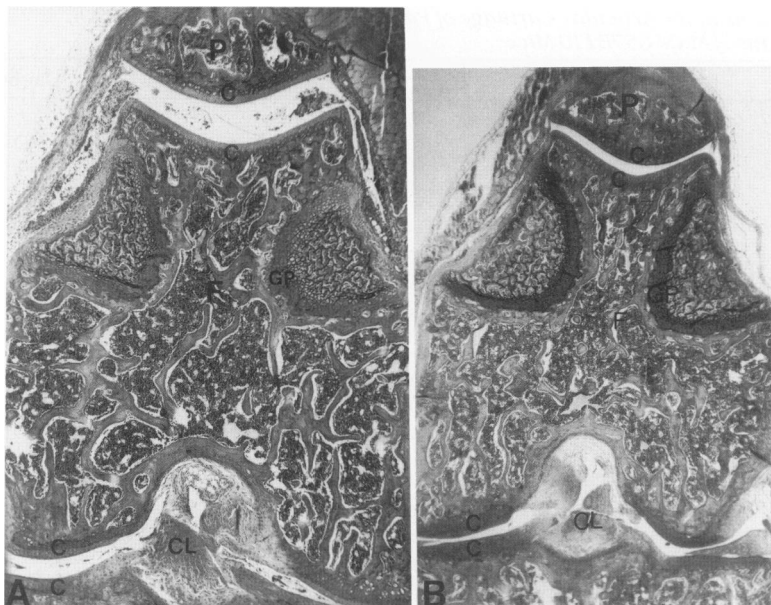
	Day 1	Day 3	Day 7	Day 21	Day 42	Day 64
<b>Cartilage fibrillation</b>						
Papain	++	++	++	++	++	ND
Iodoacetate	0	0	0	+	+	++
Collagenase	0	0	0	++	++	ND
<b>Erosion of noncalcified cartilage</b>						
Papain	+	+	+	++	++	ND
Iodoacetate	0	0	0	0	+	++
Collagenase	0	0	0	++	+++	ND
<b>Erosion of calcified cartilage</b>						
Papain	0	0	0	0	0	ND
Iodoacetate	0	0	0	0	0	0
Collagenase	0	0	0	+	+++	ND
<b>Chondrocyte death</b>						
Papain	+	+	+	++	++	ND
Iodoacetate	+	++	++	++	++	++
Collagenase	0	0	0	++	+++	ND
<b>Chondrocyte clusters</b>						
Papain	0	+	++	++	++	ND
Iodoacetate	0	0	0	+	+	+
Collagenase	0	0	0	+	+	ND
<b>Loss of safranin O staining</b>						
Papain	+++	++	+	++	++	ND
Iodoacetate	0	0	+	++	+++	+++
Collagenase	+	0	+	++	+++	ND

0, no alterations; +++, pronounced pathologic alterations; ND, not determined.

**Table 2.** *Histologic Observations of Inflammation and Alterations in Nonarticular Cartilage Joint Structures in Murine C57B1 Knee Joints after Injection with Papain (1%), Iodoacetate (0.5%), and Collagenase (1%)*

	Day 1	Day 3	Day 7	Day 21	Day 42	Day 64
<b>Patella displacement</b>						
Papain	0	0	0	0	0	ND
Iodoacetate	0	0	0	0	0	0
Collagenase	++	++	++	++	++	ND
<b>Erosion of bone</b>						
Papain	0	0	0	0	0	ND
Iodoacetate	0	0	0	0	0	0
Collagenase	0	0	0	+	+++	ND
<b>Sclerosis of subchondral bone</b>						
Papain	0	0	0	0	0	ND
Iodoacetate	0	0	0	0	0	0
Collagenase	0	0	0	+	++	ND
<b>Osteophyte formation</b>						
Papain	0	0	0	+	++	ND
Iodoacetate	0	0	+	++	++	++
Collagenase	0	0	0	++	+++	ND
<b>Synovium hyperplasia</b>						
Papain	0	++	+	0	0	ND
Iodoacetate	0	++	++	+	+	0
Collagenase	0	0	++	+++	+++	ND
<b>Inflammatory exudation</b>						
Papain	++	+	0	0	0	ND
Iodoacetate	++	+	0	0	0	0
Collagenase	++	+	0	0	0	ND
<b>Synovial infiltration</b>						
Papain	++	+	+	+	0	ND
Iodoacetate	++	+	+	+	0	0
Collagenase	+	+	+	+	+	ND

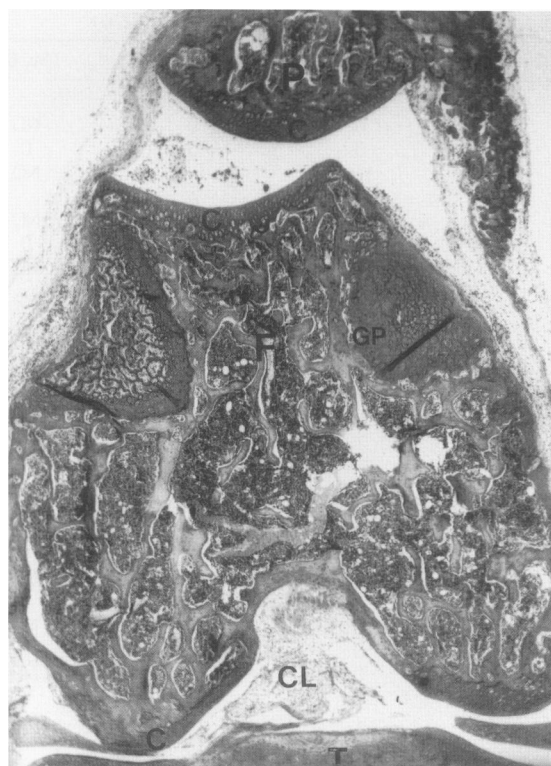0, no alterations; +++, pronounced pathologic alterations; ND, not determined.



**Figure 3.** C57B110 knee joint 1 day after the intra-articular injection of 1% papain. Note the depletion of safranin O staining in the noncalcified cartilage A: Injected joint. B: Control joint (frontal section, safranin O-fast green, original magnification  $\times 40$ ). P, patella; F, femur; T, tibia; GP, growth plate; C, cartilage; B, bone; CL, cruciate ligaments; O, osteophyte, L, ligament.

### Day 7

Seven days after papain injection the noncalcified patellar cartilage showed areas devoid of cells lying next to hyper-



**Figure 4.** Patellar displacement to the medial side of the joint 1 day after injection of 1% collagenase (frontal section, safranin O-fast green, original magnification  $\times 40$ ). For legend and control joint see Figure 3.

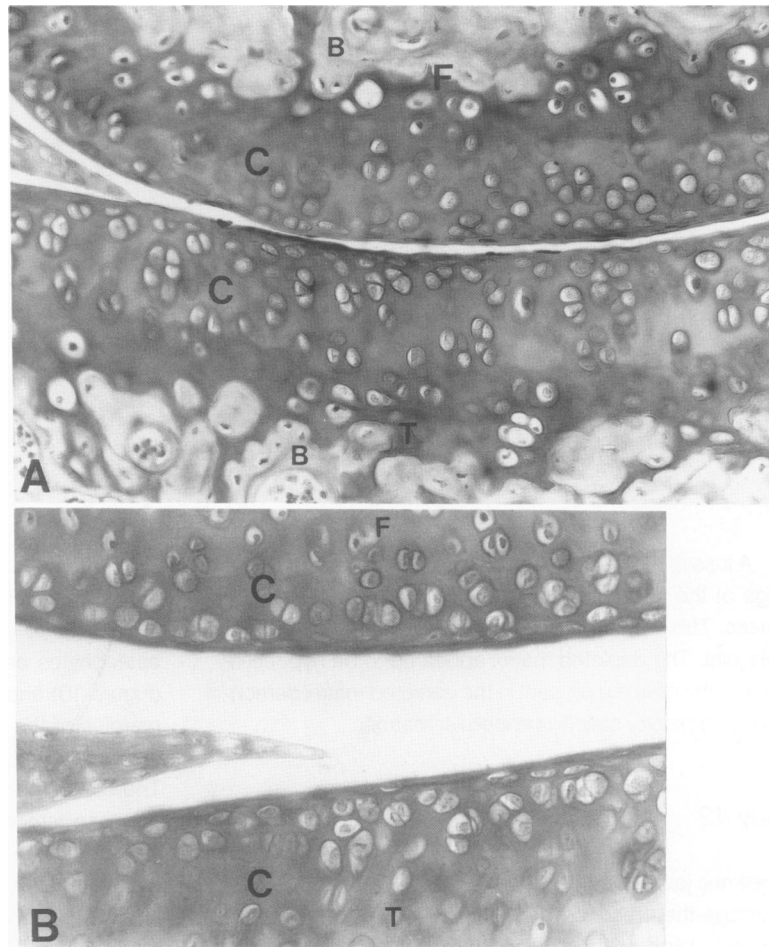
cellular areas with numerous cell clusters (Figure 5). Highly safranin O-staining halos were seen around the cell clusters. Proliferation of cells and cluster formation were also evident in the femorotibial cartilage and the menisci. The synovium appeared to be slightly thickened in the papain-injected knee joints.

Cell death was observed in the central part of the patella and to a minor extent in the patellaris femoris in the knee joints of mice injected with iodoacetate (Figure 6). The same cartilage areas also showed a moderate depletion of safranin O staining. In the depleted matrix some cells were present that markedly stained with safranin O. Proliferation of chondrocytes was not observed. The femorotibial joint also showed a slight depletion of safranin O staining after injection with 1% iodoacetate. Early signs of osteochondrocyte formation was evident at the margins of the femoropatellar joint and, in a few animals, also at the margins of the femorotibial joint to a minor extent.

In the collagenase-injected joints, the cartilage of the femorotibial joint showed a loss of safranin O staining whereas the staining of the femoropatellar cartilage was comparable with the staining of control joints. The synovial tissue on the medial side of the joint was markedly thickened by proliferation of synovial cells, whereas the synovium on the lateral side was only slightly thickened (Figure 7). Inflammatory cell infiltration in the synovial tissue was not observed.

### Day 21

Injection with papain led to acellular areas in the patellar cartilage lacking significant safranin O staining whereas

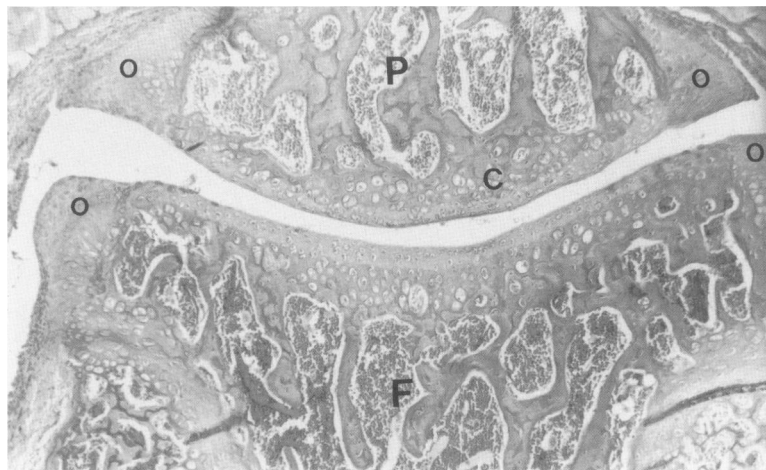


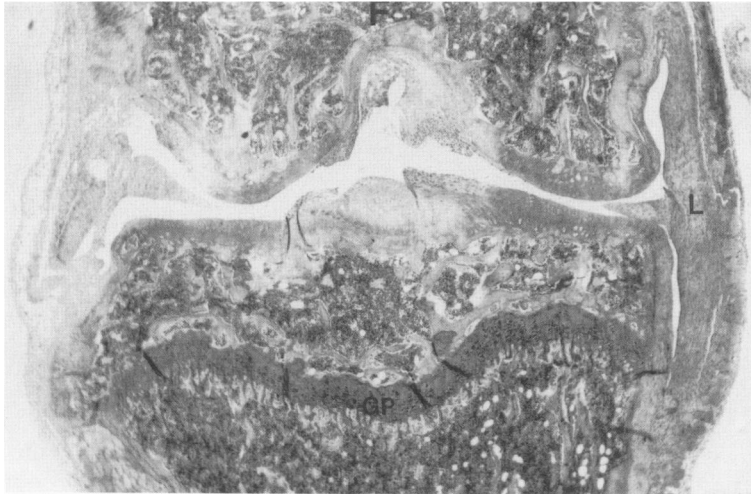
**Figure 5.** Proliferation of chondrocytes in the femorotibial joint after the intra-articular injection of papain. **A:** Injected joint. **B:** Control joint. (day 7, frontal section, safranin O-fast green, original magnification  $\times 250$ ). For legend, see Figure 3.

other areas showed hypercellularity and a strongly staining matrix indicating cartilage repair (Figure 8). Loss of cartilage in the depleted areas was seen in two of five animals. Most pronounced formation of osteophytes could be seen at the medial side of the femoropatellar joint, but in one of five animals at the medial side of the femoropatellar joint also.

In the knees injected with iodoacetate a pronounced depletion of the central part of the patella was observed, whereas some areas adjacent to the central part showed chondrocyte clusters with a markedly stained pericellular matrix. Also, the femorotibial areas showed signs of chondrocyte proliferation. Osteophyte formation was seen at the margins of the femoropatellar joint.

**Figure 6.** Femoropatellar knee joint 7 days after the injection of 0.5% iodoacetate. Formation of osteophytes at the margins of the joint and acellular areas in the central part of the patella can be seen (frontal section, safranin O-fast green, original magnification  $\times 100$ ). For legend see Figure 3.





**Figure 7.** Proliferation of synovial cells 7 days after the injection of 1% collagenase. Note the difference in proliferation on the medial side of the joint in contrast to the proliferation on the lateral side of the joint (frontal section, safranin O-fast green, original magnification  $\times 40$ ). For legend see Figure 3.

A loss of safranin O staining was observed in the cartilage of the femorotibial joint of the collagenase-injected knees. This was most pronounced at the medial side of this joint. The depleted matrix appeared to be hypocellular, but the cells still present in the depleted matrix demonstrated a heavily stained pericellular matrix.

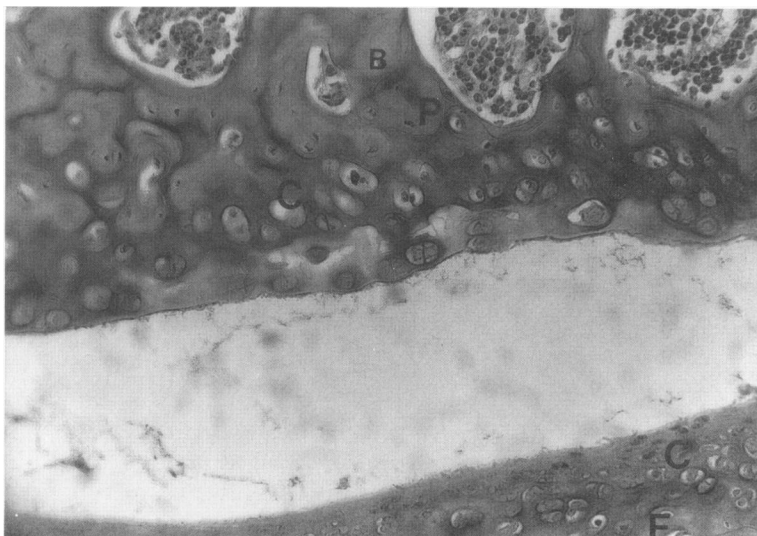
#### Day 42

The knee joints injected with papain showed in the patellar cartilage the presence of chondrocyte clusters in an intensely stained extracellular matrix adjacent to acellular safranin O-depleted areas. Pieces of cartilage were disrupted from the degenerated cartilage. This was to a lesser extent also observed in the femoris patellaris. Osteophytes were observed on the margins of the femoropatellar joint, mainly on the medial side of this joint (Figure

9). Osteophytes on the femorotibial joint were less common. There were no signs of inflammation in the joints.

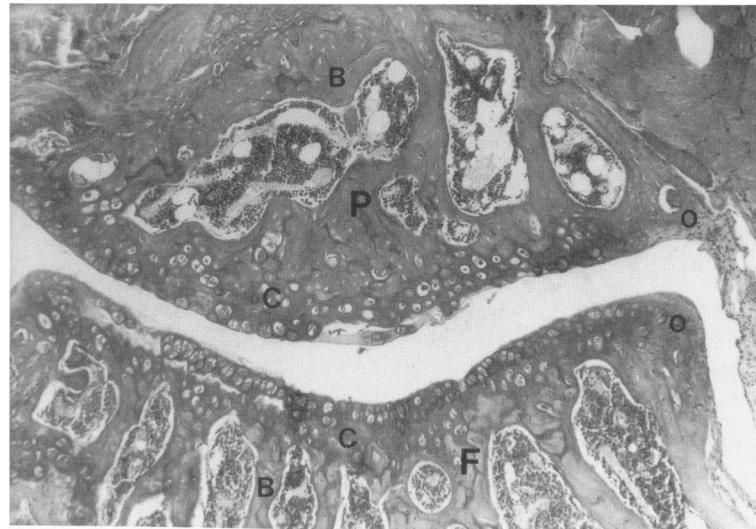
Injection of iodoacetate led to the formation of large osteophytes on the margins of the femoropatellar joint (Figure 10) and sometimes to small osteophytes on the margins of the femorotibial joint. The osteophyte formation was most marked at the medial side of the joints. The central part of the patella and to a lesser extent the opposite femoral cartilage showed a significant loss of safranin O staining. Areas adjacent to depleted areas were hypercellular in some of the animals. Loss of safranin O staining was also observed in the cartilage of the tibial plateau. Signs of inflammation were absent in the joints.

The injection of collagenase resulted in a gross change in the appearance of the knee joints. Due to osteophyte formation, thickening of the collateral ligaments and synovium, and erosion of cartilage and bone, the



**Figure 8.** Cartilage of the femoropatellar joint 21 days after the injection of 1% papain. Acellular areas in the patellar cartilage with little safranin O staining are observed lying next to highly stained cellular areas (frontal section, safranin O-fast green, original magnification  $\times 250$ ). For legend see Figure 3.





**Figure 9.** Femoropatellar joint 42 days after the injection of 1% papain. Cartilage fragments are disrupted from the cartilage surface and osteophytes are present on the margins of the joint (frontal section, safranin O-fast green, original magnification  $\times 100$ ). For legend see Figure 3.

height of the joints was decreased and the width was increased. The osteoarthritic lesions were severe. Cartilage at the medial side of the femorotibial joint was totally

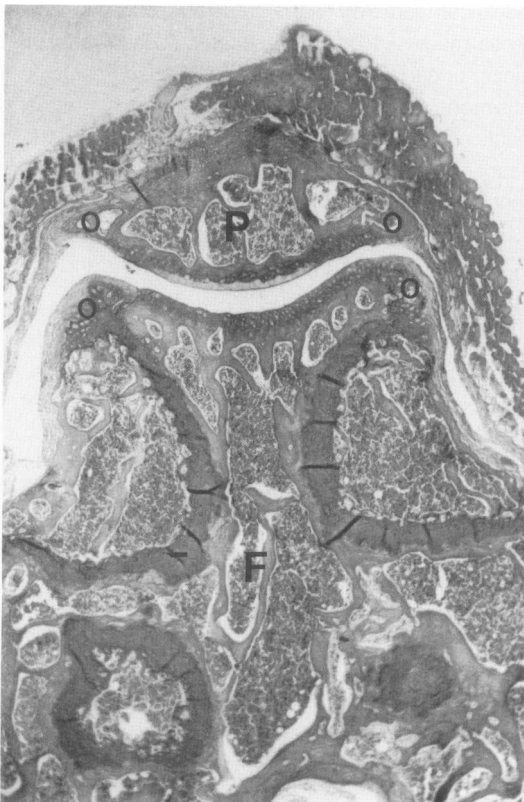eroded, and the subchondral bone had become sclerotic (Figure 11). In two of five mice the subchondral bone on the medial side of the femorotibial joint was exposed to the surface. Changes on the lateral side of the joint were always less pronounced than those on the medial side of the joint. Formation of cartilage-like tissue, as indicated by safranin O staining, was observed in the collateral ligaments.

#### Day 64

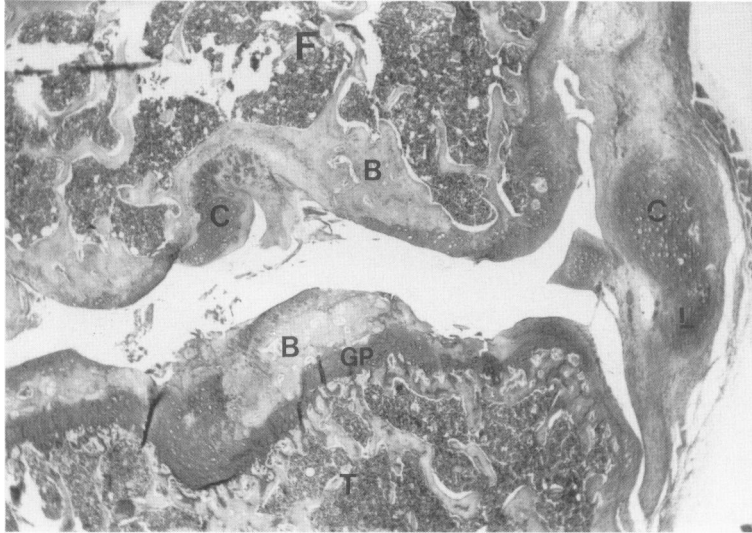
Sixty-four days after the injection of iodoacetate the cartilage in the central parts of the patella appeared to be thinner in the iodoacetate-injected knee joints than in the physiologic saline-injected knee joints. The central part of the patella was depleted of safranin O staining whereas chondrocyte clusters could be seen in nondepleted parts. Osteophytes were present most markedly at the medial side of the femoropatellar joint but also at the other joint margins.

#### Discussion

A single injection of male C57B110 mice with papain, iodoacetate, or collagenase led to osteoarthritic-like lesions in the injected knee joints after a few weeks. Interference with joint stability by injection of collagenase in the knee joints resulted in joint changes similar to changes observed in murine osteoarthritis (compare Figure 11 and Figure 12). Injection of papain or iodoacetate led to degenerative alterations in the knee joints as a result of cartilage damage, which in many respects are similar to those alterations seen with osteoarthritis.



**Figure 10.** Formation of osteophytes of the femoropatellar joint 42 days after the injection of 0.5% iodoacetate. The cartilage of the femoropatellar joint clearly shows depletion of safranin O staining (frontal section, safranin O-fast green, original magnification  $\times 40$ ). For legend see Figure 3.



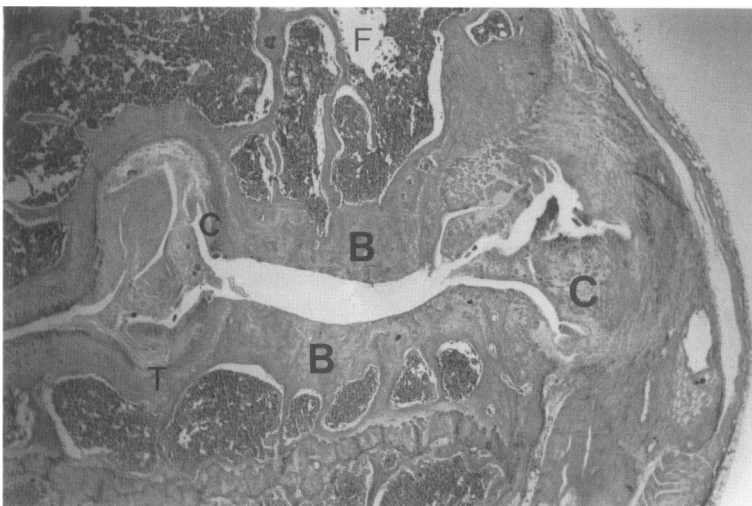
**Figure 11.** Destruction of the femorotibial joint 42 days after the injection of 1% collagenase. Erosion of bone is clear on the medial side of the tibial plateau, and the ligaments show cartilaginous alterations (frontal section, safranin O-fast green, original magnification  $\times 40$ ). For legend see Figure 3.

The injection of papain, iodoacetate, or collagenase led in the initial phase to a moderate inflammatory reaction in the knee joint. This inflammatory response was characterized by synovial infiltration with inflammatory cells and the presence of these cells in the joint cavities. The exudate was transient in all three models and had almost disappeared 3 days after injection. A low-grade synovial infiltrate could be observed until day 21. An inflammatory response was also indicated by the joint swelling observed after injection of papain, iodoacetate, or collagenase. The joint swelling, as indicated by radiolabel uptake of the knee joints, was also transient, and significant joint swelling was not observed by 3 days after intra-articular injection. The joint swelling induced by the injection of collagenase was higher than could be expected by the histologic evaluation of the inflammatory response in the injected knee joints.<sup>58</sup> The collagenase injection probably has a direct effect on endothelial structures in the joint and

leads in this way to a more pronounced joint swelling than would be expected by the observed inflammation.

The inflammatory response in all three models was low grade when compared with the inflammatory response in the murine arthritis models we routinely use in our laboratory.<sup>61-63</sup> Because a grade of inflammation in the arthritis models comparable with the grade observed in the osteoarthritis models does not result in a loss of safranin O staining or cartilage damage in the later stages in the arthritis models, the role of the inflammatory response in the induction of the osteoarthritic lesions would be an insignificant one. In addition, 18-month-old C57B110 mice with spontaneous osteoarthritis also showed a low-grade synovial infiltrate. An inflammatory reaction was also observed in other animal models of osteoarthritis and is regularly a component of human osteoarthritis.<sup>64-69</sup>

Injection of collagenase resulted after 1 day in a high incidence of patellar dislocation to the medial side of the



**Figure 12.** Spontaneous osteoarthritis in an 18-month-old C57BL/10 mouse (frontal section, safranin O-fast green, original magnification  $\times 40$ ). For legend see Figure 3.

injected knee joint. Injection of papain, iodoacetate, or physiologic saline never led to patellar displacement. Patellar dislocation to the medial side of the knee joints has also been associated with spontaneous osteoarthritis in STR/IN and STR/ORT mice.<sup>25,33,37-39</sup> The patella dislocation demonstrates the presence of joint instability, either as a result of inherent joint malformation (STR/IN and STR/ORT strains) or as the consequence of the collagenase injection. The effect of collagenase on collagen type I-containing joint structures, such as ligaments and tendons, induces the observed joint instability. Collagenase (1%) had no degradative effect on the anatomically intact cartilage of patellae after *in vitro* incubation but degraded sliced bovine cartilage under the same conditions (data not shown).

The injection of papain and iodoacetate had the most pronounced effects on the cartilage of the femoropatellar joint, whereas the injection of collagenase resulted in marked pathologic changes in the femorotibial joint. The central parts of the patellae, and to a lesser extent the opposite side on the femur, expressed the most distinct depletion of safranin O and cell death after the injection of papain or iodoacetate. A similar predisposition was observed in the antigen (methylated bovine serum albumin)-induced arthritis model in C57B110 mice in our laboratory.<sup>59</sup> Moreover, *in vitro* incubation of murine patellae with hydrogen peroxide resulted in more severe inhibition of proteoglycan synthesis and higher cell death in the central chondrocytes than in more peripheral situated chondrocytes.<sup>70</sup> This indicates that chondrocytes from certain areas of knee joint cartilage are more vulnerable to the effects of harmful compounds than chondrocytes from other areas. As the central part of the patella in mice is one of the load-bearing parts of the joint, the susceptibility of chondrocytes in this area may be related to the *in vivo* stress on these chondrocytes.

Osteoarthritic lesions on the medial side of the femorotibial joint were the most pronounced effects on the knee joint cartilage of mice injected with collagenase. Also, the spontaneous osteoarthritis models in STR/IN and STR/ORT mice showed a preferential development of the osteoarthritic lesions on the medial side of the femorotibial joint; the same localization was also reported for the spontaneous osteoarthritis in guinea pigs.<sup>24,25,33,37-39</sup> Intrinsic factors in the structure of the knee joints of these animals, or of the chondrocytes on the medial side of the femoral joint,<sup>71</sup> may predispose the animals to osteoarthritis in this area. A similar localization of the osteoarthritic lesions was observed in some of the surgically induced models of osteoarthritis but this may be due to the location of the surgical intervention.<sup>18,20,21,23</sup>

In all three models, one of the main and first observed aspects of the alterations in the cartilage, preceding the erosive alterations, was loss of safranin O staining. After

injection of papain this could already be seen after 1 day, but in the other models depletion of stages severely affected cartilage areas in later stages, could be observed from day 7. A cellular reaction could be seen in these proteoglycan-depleted cartilage in all three models, as in human osteoarthritis.<sup>1</sup> Some areas showed a decrease of cell number, whereas other adjacent areas showed chondrocyte proliferation and the presence of chondrocyte clusters. Chondrocyte proliferation was observed in the papain-injected knee joints after 3 days but in the knee joints injected with iodoacetate or collagenase proliferation was only observed at day 21 and at later stages. Also, the number of cell clusters observed was much greater after injection of papain than after injection of iodoacetate or collagenase. A high proliferative response of chondrocytes, indicating an attempt to repair the damaged matrix, was also observed in rabbits and guinea pigs after intra-articular papain injection.<sup>48,51,52,72</sup> Proteoglycan loss from cartilage matrix may trigger a proliferative response in chondrocytes. The proliferative response may be related to the depletion of proteoglycans after injection of papain, which is more pronounced than after injection of the other two compounds. Iodoacetate could also have affected the chondrocyte metabolism in such a way that many of these cells lost the ability to proliferate whereas the changes in joint loading after collagenase injection may have limited the proliferative response in the severely affected cartilage of the femorotibial joint.

In all three models we found that the remaining cells in the proteoglycan-depleted matrix and the chondrocyte clusters were often surrounded with a pericellular halo of strongly staining matrix. Similar observations have also been reported in the spontaneous osteoarthritis in other mouse strains<sup>25,33,37-39</sup> and in the spontaneous osteoarthritis in 18-month-old C57B110 mice (the authors' observations, data not shown). The presence of the strong staining around the cells may demonstrate that the chondrocytes remaining in the proteoglycan-depleted matrix have a high rate of proteoglycan synthesis.

The glycosaminoglycan synthesis in the whole patellae shows a high rate of proteoglycan synthesis at certain stages (Figure 2). After an initial inhibition on day 1, an elevation of proteoglycan synthesis on days 3 and 7 after papain injection (1%) and a normal proteoglycan synthesis on days 3 and 7 after iodoacetate injection were observed. As chondrocyte death was observed after the injection of iodoacetate or papain, the high level of proteoglycan synthesis in the whole patella showed that certain chondrocytes had an increased rate of proteoglycan synthesis. However, the rate of proteoglycan synthesis measured in the whole patella after 7 days and at later stages can be affected by the formation of osteophyte cartilage at the margins of the patellae. The stimulation of proteoglycan synthesis in the patellae at days 3 and 7 after colla-

genase injection may be due to the initial depletion of proteoglycans observed in the patellae on days 1 and 3. At later stages, the elevated synthesis can be caused by osteophyte formation. Autoradiography studies are being carried out at the moment to resolve these issues.

The osteoarthritic alterations observed after the injection of iodoacetate, papain, or collagenase were not confined to changes in the articular cartilage. Osteophyte formation, a characteristic of osteoarthritis in humans and in animal models, could be seen in all three models. Like the erosion of cartilage, the formation of osteophytes was also most pronounced at the margins of the femoropatellar joint after papain or iodoacetate injection and at the margins of the femorotibial joint after injection of collagenase. This demonstrates that the localization of osteophyte formation is associated with the localization of cartilage erosion in these models. The osteophytes were most times bigger on the medial side of the joint than on the lateral side of the joint. This can be related to the distribution of loading in the mouse knee joint.

Metaplastic changes were observed in the synovial tissue in all three models. This was most pronounced in the knee joints of mice injected with collagenase. The collateral ligaments on the medial side of the joints and to a lesser extent on the lateral side showed striking cartilaginous changes. Sclerosis of subchondral bone was evident 42 days after the injection of collagenase but not in the other two models. The last phenomenon may be related to the erosion of the calcified part of the cartilage, which was observed in the collagenase model but not in the other two models. Similar changes, ie, metaplasia of synovium and sclerosis of ligaments and subchondral bone, have been reported for the spontaneous mouse models.<sup>25,33-35,37-39</sup>

## References

1. Mankin HJ, Brandt KD, Shulman LE: Workshop on etiopathogenesis of osteoarthritis: Proceedings and recommendations. *J Rheumatol* 1986, 13:1130-1160
2. Peyron JG: Osteoarthritis: The epidemiological viewpoint. *Clin Orthop Rel Res* 1986, 213:13-19
3. Brocklehurst R, Bayliss MT, Maroudas A, Coysh HL, Obst D, Freeman MAR, Revell PA, Ali SY: The composition of normal and osteoarticular cartilage from human knee joints. *J Bone Joint Surg* 1984, 66A:95-106
4. Rostand KS, Baker JR, Caterson B, Christner JE: Articular cartilage proteoglycans from normal and osteoarthritic mice. *Arthritis Rheum* 1986, 29:95-105
5. Moskowitz RW, Howell DS, Goldberg VM, Muniz O, Pita JC: Cartilage proteoglycan alterations in an experimentally induced model of rabbit osteoarthritis. *Arthritis Rheum* 1979, 22:155-163
6. Mankin HJ, Dorfman H, Lipiello L, Zarins A: Biochemical and metabolic abnormalities in articular cartilage from osteoarthritic human hips. II. Correlation of morphology with biochemical and metabolic data. *J Bone Joint Surg* 1971, 53A:523-537
7. Mankin HJ, Johnson ME, Lipiello L: Biochemical and metabolic abnormalities in articular cartilage from osteoarthritic human hips. III. Distribution and metabolism of amino sugar-containing macromolecules. *J Bone Joint Surg* 1981, 63A:131-139
8. Schwartz ER, Levielle CR, Stevens JW, OH WH: Proteoglycan structure and metabolism in normal and osteoarthritic cartilage of guinea pigs. *Arthritis Rheum* 1981, 24:1528-1538
9. Sandy JD, Adams ME, Billingham MEJ, Plaas A, Muir H: In vivo and in vitro stimulation of chondrocyte biosynthetic activity in early experimental osteoarthritis. *Arthritis Rheum* 1984, 27:388-397
10. Inerot S, Heinegard D: Articular-cartilage proteoglycans in aging and osteoarthritis. *Biochem J* 1978, 169:143-156
11. Santer V, White RJ, Roughly PJ: Proteoglycans from normal and degenerate cartilage of the adult human tibial plateau. *Arthritis Rheum* 1981, 24:691-700
12. Cox MJ, McDevitt CA, Amoczky SP, Warren RF: Changes in the chondroitin sulfate-rich region of articular cartilage proteoglycans in experimental osteoarthritis. *Biochem Biophys Acta* 1985, 840:228-234
13. Carney SL, Billingham MEJ, Muir H, Sandy JD: Structure of newly synthesized (<sup>35</sup>S)-proteoglycans and (<sup>35</sup>S)-proteoglycan turnover products of cartilage explants cultures from dogs with experimental osteoarthritis. *J Orthop Res* 1985, 3:140-147
14. Orford CR, Gardner DL, O'Connor P, Bates G, Swallow JJ, Brito-Babapulle LAP: Ultrastructural alterations in glycosaminoglycans of dog femoral condylar cartilage after surgical division of an anterior cruciate ligament: A study with cupromeronic blue in a critical electrolyte concentration technique. *J Anat* 1986, 148:233-244
15. Teshima R, Treadwell BV, Trahan CA, Mankin HJ: Comparative rates of proteoglycan synthesis and size of proteoglycans in normal and osteoarthritic chondrocytes. *Arthritis Rheum* 1983:1225-1230
16. Mankin HJ, Lipiello L: Biochemical and metabolic abnormalities in articular cartilage from osteoarthritic human hips. *J Bone Joint Surg* 1970, 52A:424-434
17. Telhag H, Lindberg L: A method for inducing osteoarthritic changes in rabbits' knees. *Clin Orthop Rel Res* 1972, 86:214-223
18. Moskowitz RW, Davis W, Sammarco J, Martens M, Baker J, Mayor M, Burstein, Frankel VH: Experimentally induced degenerative joint lesions following partial meniscectomy in the rabbit. *Arthritis Rheum* 1973, 16:397-405
19. McDevitt C, Muir H: An experimental model of osteoarthritis early morphological and biochemical changes. *J Bone Joint Surg* 1977, 59B:24-35
20. Schwartz ER, Levielle CR: Experimentally induced osteoarthritis in guinea pigs. *Arthritis Rheum* 1981, 24:1345-1355
21. Colombo C, Butler M, O'Byrne E, Hickman L, Swartzen-

- druber D, Selwyn M, Steinetz B: A new model of osteoarthritis in rabbits. I. Development of knee joint pathology following lateral meniscectomy and section of the fibular collateral and sesamoid ligaments. *Arthritis Rheum* 1983, 26:875-886
22. Vignon E, Arlot M, Hartmann D, Moyon B, Ville G: Hypertrophic repair of articular cartilage in experimental osteoarthritis. *Ann Rheum Dis* 1983, 42:82-88
  23. Bendele AM: Progressive chronic osteoarthritis in femorotibial joints of partial medial meniscectomized guinea pigs. *Vet Pathol* 1987, 24:444-448
  24. Bendele AM, Hulman JF: Spontaneous cartilage degeneration in guinea pigs. *Arthritis Rheum* 1988, 31:561-565
  25. Walton M: Degenerative joint disease in the mouse knee: Histological observations. *J Pathol* 1977, 123:109-122
  26. Moskowitz RW, Goldberg VM: Osteophyte evolution: Studies in an experimental partial meniscectomy model. *J Rheumatol* 1987, 14(suppl):116-118
  27. Lukosheshek M, Schaffler MB, Burr DB, Boyd RD, Radin EL: Synovial membrane and cartilage changes in experimental osteoarthritis. *J Orthop Res* 1988, 6:475-492
  28. Pelletier JP, Martel-Pelletier J, Altman RD, Ghandur-Mnaymeh L, Howell DS, Woessner JF Jr: Collagenolytic activity and collagen matrix breakdown of the articular cartilage in the Pond-Nuki dog model of osteoarthritis. *Arthritis Rheum* 1983, 26:866-874
  29. Lindblad S, Hedfors E: Arthroscopic and immunohistologic characterization of knee joint synovitis in osteoarthritis. *Arthritis Rheum* 1987, 30:1081-1088
  30. Goldenberg DL, Egan MS, Cohen AS: Inflammatory synovitis in degenerative joint disease. *J Rheumatol* 1982, 9:204-209
  31. Cantatore FP, Benazzo F, Ribatti D, Lapadula G, D'Amico S, Tursi A, Pipitone V: Early alterations of synovial membrane in osteoarthritis. *Clin Rheumatol* 1988, 7:214-219
  32. Altman RD, Fries JF, Bloch DA, Carstens J, Cooke TD, Genant H, Gofton P, Groth H, McShane DJ, Murphy WA, Sharp JT, Spitz P, Williams CA, Wolfe F: Radiographic assessment of progression in osteoarthritis. *Arthritis Rheum* 1987, 30:1214-1225
  33. Schünke M, Tilmann B, Brück M, Müller-Ruchholtz, W: Morphologic characteristics of developing osteoarthrotic lesions in the knee cartilage of STR/IN mice. *Arthritis Rheum* 1988, 31:898-905
  34. Sokoloff L: Natural history of degenerative joint disease in small laboratory animals: 1. Pathological anatomy of degenerative joint disease in mice. *Arch Pathol* 1956, 62:118-128
  35. Sokoloff L: Natural history of degenerative joint disease in small laboratory animals. 2. Epiphyseal maturation and osteoarthritis of the knee of mice of inbred strains. *Arch Pathol* 1956, 62:129-135
  36. Wilhelmi G, Faust R: Suitability of the C75B1 mouse as an experimental animal for the study of skeletal changes due to aging, with special reference to osteoarthrosis and its response to tribenoside. *Pharmacology* 1976, 14:289-296
  37. Walton M: Degenerative joint disease in the mouse knee: Radiological and morphological observations. *J Pathol* 1977, 123:97-107
  38. Walton M: Studies of degenerative joint disease in the mouse knee joint: Scanning electron microscopy. *J Pathol* 1977, 123:211-217
  39. Walton M: Patella displacement and osteoarthritis of the knee joint in mice. *J Pathol* 1979, 127:165-172
  40. Bingle SA, Sande RD, Wight TN: Undersulfated chondroitin sulfate in cartilage from a miniature poodle with spondyloepiphyseal dysplasia. *Connect Tissue Res* 1986, 15:283-302
  41. Pelletier JP, Martel-Pelletier J: Cartilage degradation by neutral proteoglycanases in experimental osteoarthritis. *Arthritis Rheum* 1985, 28:1393-1401
  42. Arsever CL, Bole GG: Experimental osteoarthritis induced by selective myectomy and tendotomy. *Arthritis Rheum* 1986, 29:251-261
  43. Manicourt DH, Pita JC: Progressive depletion of hyaluronic acid in early experimental osteoarthritis in dogs. *Arthritis Rheum* 1988, 31:538-544
  44. Pidd JG, Gardner DL, Adams ME: Ultrastructural changes in the femoral condylar cartilage of mature American foxhounds following transection of the anterior cruciate ligament. *J Rheumatol* 1988, 15:663-669
  45. Murray DG: Experimentally induced arthritis using intra-articular papain. *Arthritis Rheum* 1964, 7:211-219
  46. Bentley G: Papain-induced degenerative arthritis of the hip in rabbits. *J Bone Joint Surg* 1971, 53B:324-337
  47. Scheck M, Sakovich L: Degenerative joint disease of the canine hip. *Clin Orthop Rel Res* 1972, 86:115-120
  48. Farkas T, Bihari-Varga M, Biro T: Thermoanalytical and histological study of intra-articular papain-induced degradation and repair of rabbit cartilage. I. Immature animals. *Ann Rheum Dis* 1974, 33:385-390
  49. Farkas T, Bihari-Varga M, Biro T: Thermoanalytical and histological study of intra-articular papain-induced degradation and repair of rabbit cartilage. II. Mature Animals. *Ann Rheum Dis* 1976, 35:23-26
  50. Shaw NE, Lacey E: The influence of corticosteroids on normal and papain-treated cartilage in the rabbit. *J Bone Joint Surg* 1973, 55B:197-205
  51. Havdrup T, Telhag H: Papain-induced changes in the knee joints of adult rabbits. *Acta Orthop Scan* 1977, 48:143-149
  52. Moriizumi T, Yamashita N, Okada Y: Papain-induced changes in the guinea pig knee joint with special reference to cartilage healing. *Vichows Arch* 1986, 51:461-474
  53. Kalbhen DA: Degenerative joint disease following chondrocyte injury: Chemically induced osteoarthrosis, *Degenerative Joints*. Edited by G Verbruggen, EM Veys. Amsterdam, Elsevier Science Publishers BV 1985, pp 299-309
  54. Kalbhen DA, Scherbach E, Felten K: Histological investigations of the antiarthrotic effect of tribenoside (Glyvenol) in experimental osteoarthrosis. *J Rheumatol* 1983, 10:267-281
  55. Williams JM, Brandt KD: Temporary immobilization facilitates repair of chemically induced articular cartilage injury. *J Anat* 1984, 138:435-446
  56. Williams JM, Brandt KD: Exercise increases osteophyte formation and diminishes fibrillation following chemically induced articular cartilage injury. *J Anat* 1984, 139:599-611

57. Williams JM, Brandt KD: Immobilization ameliorates chemically-induced articular cartilage damage. *Arthritis Rheum* 1984, 27:208-216
58. Kruysen MWM, van den Berg WB, van de Putte LBA: Detection and quantitation of experimental joint inflammation in mice by measurement of <sup>99</sup>Tc-pertechnetate uptake. *Agents Actions* 1981, 11:640-642
59. Van den Berg WB, Kruysen MWM, van de Putte LBA: The mouse patella assay: An easy method of quantitating articular cartilage chondrocyte function in vivo and in vitro. *Rheumatol Int* 1982, 1:165-169
60. De Vries BJ, van den Berg WB, Vitters E, van de Putte LBA: Quantitation of glycosaminoglycan metabolism in anatomically intact articular cartilage of the mouse patella: In vitro and in vivo studies with <sup>35</sup>S-sulfate, <sup>3</sup>H-glucosamine and <sup>3</sup>H-acetate. *Rheumatol Int* 1986, 6:273-281
61. Kruysen MWM, van den Berg WB, van de Putte LBA: Sequential alterations of pericellular structures in antigen-induced arthritis in mice: Histological observations on fibrous capsule, ligaments, bone and muscles, using whole joint knee sections. *Br J Exp Pathol* 1983, 64:298-305
62. Kruysen MWM, van den Berg WB, Van den Putte LBA: Significance of severity and duration of murine antigen-induced arthritis for cartilage proteoglycan synthesis. *Arthritis Rheum* 1985, 28:813-819
63. Van den Berg WB, Kruysen MWM, van de Putte LBA, van Beusekom HJ, van der Sluis M, Zwarts WA: Antigen-induced and zymozan induced arthritis in mice: Studies on in vivo cartilage proteoglycan synthesis and chondrocyte death. *Br J Exp Pathol* 1981, 62:308-316
64. Goldenberg DL, Egan MS, Cohen AS: Inflammatory synovitis in degenerative joint disease. *J Rheumatol* 1982, 9:204-209
65. Katona G: Osteoarthritis—an inflammatory disease? *Int J Tissue React* 1984, 6:453-461
66. Pelletier J-P, Martel-Pelletier J, Ghandur-Mnaimneh L, Howell DS, Woessner JF: Role of synovial membrane inflammation in cartilage matrix breakdown in the Pond-Nuki dog model of osteoarthritis. *Arthritis Rheum* 1985, 28:554-561
67. Cooke TDV, Chir B: Immune pathology in polyarticular osteoarthritis. *Clin Orthop Rel Res* 1986, 213:41-49
68. Lindblad S, Hedfors E: Arthroscopic and immunohistologic characterization of knee joint synovitis in osteoarthritis. *Arthritis Rheum* 1987, 30:1081-1088
69. Revell PA, Mayston V, Lalor P, Mapp P: The synovial membrane in osteoarthritis: A histological study including the characterization of the cellular infiltrate present in inflammatory osteoarthritis using monoclonal antibodies. *Ann Rheum Dis* 1988, 47:300-307
70. Schalkwijk J, van den Berg WB, van de Putte LBA, Joosten LAB: Hydrogen peroxide suppresses the proteoglycan synthesis in articular cartilage. *J Rheumatol* 1985, 12:205-210
71. Altmann FP: A metabolic dysfunction in early murine osteoarthritis. *Ann Rheum Dis* 1981, 40:303-306
72. Coulais Y, Marcelon G, Cros J, Guiraud R: Etude d'un modele experimental d'arthrose. I. Induction et etude ultrastructurale. *Pathol Biol (Paris)* 1983, 31:577-582