

# Expression of Nerve Growth Factor Receptor in Paraffin-Embedded Soft Tissue Tumors

PATRICIA M. PEROSIO, BS, and  
JOHN J. BROOKS, MD

*From the Department of Pathology and Laboratory Medicine,  
Division of Surgical Pathology, Hospital of the University of  
Pennsylvania, Philadelphia, Pennsylvania*

Identification of growth factors and receptors in mesenchymal tumors may be crucial to understanding of growth regulation in sarcomas. During an immunohistochemical study of the expression of growth factors and receptors in human soft tissue tumors (STT), only 1 antisera capable of working in paraffin-embedded tissue was noted. A detailed study of 141 STT was undertaken to determine the frequency of expression of nerve growth factor receptor (NGF-R), its specificity and sensitivity for neural tumors, and the effect of fixation on detection. In normal mesenchymal tissue, only nerve sheath and perivascular staining was seen. No immunoreactivity was seen in many tumors including rhabdomyosarcoma, angiosarcoma, liposarcoma, Ewing's sarcoma, and alveolar soft part sarcoma. Less than 15% of tumors of smooth muscle,

fibrous, or fibrohistiocytic origin showed immunoreactivity, usually focal. In contrast, a high frequency of immunoreactivity was noted in tumors of neural origin (74%). This included granular cell tumors (100%), Schwannoma/neurofibroma (91%), malignant Schwannoma (78%), neuroblastoma/neuroepithelioma (60%), and paraganglioma (57%). A high rate of reactivity was also seen in synovial sarcomas (80%), undifferentiated sarcomas (60%), and hemangiopericytomas (43%), suggesting a potential relationship to the neural phenotype. Among the neural tumors, Bouin's fixation was superior to formalin, suggesting that immunoreactivity for NGF-R is affected by fixation. This antibody may be a useful adjunct marker diagnostically. (*Am J Pathol* 1988, 132:152-160)

RECENTLY, INTEREST IN viral oncogenes has grown as associations between viral oncogene products and cellular transformation and tumorigenesis have been discovered. Although functional correlates of many of these viral and cellular oncogene products have not been determined, 2 have been investigated and shown to be related to known growth factors and receptors. The transforming protein of the Simian Sarcoma virus, p<sup>28v-sis</sup>, was the first oncogene product shown to have significant sequence homology with a growth factor, platelet-derived growth factor (PDGF), a mitogen for fibroblasts, glia, and smooth muscle cells in culture.<sup>1,2</sup> In addition, in-depth investigations of the receptor for epidermal growth factor have shown that the erb B product of the erythroblastosis virus is similar to the intracellular portion of this receptor.<sup>3</sup>

Interest has continued with the nerve growth factor/receptor system because of the importance of nerve growth factor (NGF) in regulating development of sympathetic and sensory neurons.<sup>4</sup> Other targets

for NGF include tumors of neural crest origin including neurofibroma, pheochromocytoma, neuroblastoma, and malignant melanoma.<sup>5-7</sup> Although no viral oncogene product has yet been identified in these tumors, the receptor for NGF (NGF-R) is a possible candidate. This receptor has been identified in cells derived from pheochromocytomas, neuroblastoma, and melanoma, as well as Schwann cells from traumatic neuromas and neurofibromata.<sup>6-10</sup> Support for the hypothesis that the nerve growth factor receptor may be a potential oncogene-associated cellular protein is the discovery that nevi and melanomas, benign and malignant tumors of melanocytes, express NGF-R, whereas normal melanocytes do not.<sup>11</sup> Thus, expression of NGF-R may be related to tumorigenic potential and malignant transformation of melanocytes.

Accepted for publication February 29, 1988.

Address reprint requests to John J. Brooks, MD, Section of Surgical Pathology, Department of Pathology and Laboratory Medicine, Hospital of the University of Pennsylvania, Philadelphia, Pennsylvania 19104

Table 1—Study Cases: Benign and Malignant Mesenchymal Lesions

Phenotype	Benign (43)	Malignant (98)
Neural (47)	PNS*†‡ (11)	PNS* (9)
	Neuroma (3)	Neuroepithelioma/Neuroblastoma (10)
	Ganglioneuromatosis (2)	Paraganglioma** (7)
	Granular cell tumor (3)	Malignant granular cell tumor (1)
Fibrous (21)	Fibromatosis** (3)	Clear cell sarcoma (1)
	Fibroma <sup>‡</sup> (2)	Malignant fibrous histiocytoma (MFH)†† (14)
	DFSP† (1)	
	Fibrous pseudotumor <sup>‡</sup> (1)	
	Leiomyoma‡‡ (8)	
Smooth muscle (16)		Leiomyosarcoma‡‡ (8)
Skeletal muscle (4)		Rhabdomyosarcoma (4)
Lipomatous (7)	Lipoma** (4)	Liposarcoma** (3)
Vascular (11)	Hemangioma <sup>‡</sup> (1)	Hemangiopericytoma <sup>‡</sup> (7)
	Lymphangioma <sup>‡</sup> (1)	Angiosarcoma (2)
Other (35)	Fibrothecoma <sup>‡</sup> (1)	Synovial sarcoma** (10)
	Angiomyolipoma <sup>‡</sup> (1)	Sarcoma, NOS‡† (5)
	Atrial myxoma <sup>‡</sup> (1)	Skeletal Ewings (4)
		ASPS§ (5)
		Epithelioid sarcoma (1)
		Kaposi's sarcoma <sup>‡</sup> (1)
	Cystosarcoma phyllodes <sup>‡</sup> (2)	
	Uterine stromal sarcoma <sup>‡</sup> (1)	
	Malignant mixed Mesodermal tumor** (3)	

\* Peripheral nerve sheath tumor.

† Dermato fibrosarcoma protuberans.

‡ Undifferentiated sarcoma, not otherwise specified.

§ Alveolar soft part sarcoma.

The number of cases is given in parenthesis. Note the broad distribution of benign and malignant mesenchymal neoplasms across the various phenotypes. Frozen tissue was available and was tested with this antibody to NGF-R in 58 of these tumors. The number of cases are indicated above as follows:

<sup>‡</sup> One case.

<sup>†</sup> Two cases.

\*\* Three cases.

†† Seven cases.

‡‡ Eight cases.

Our investigation into the frequency of expression of various growth factors and receptors in frozen sections of soft tissue tumors documented a relationship between their expression and biologic potential in these lesions.<sup>12</sup> As part of that study, we confirmed what others had observed, namely the preservation of NGF-R immunoreactivity in paraffin sections. We therefore undertook a formal study: 1) to determine the frequency of reactivity of NGF-R in paraffin sections of soft tissue tumors of various phenotypes; 2) to delineate the sensitivity and specificity of this receptor antibody for tumors of neural origin; and 3) to examine the effect of tissue fixation on expression of detectable antigen.

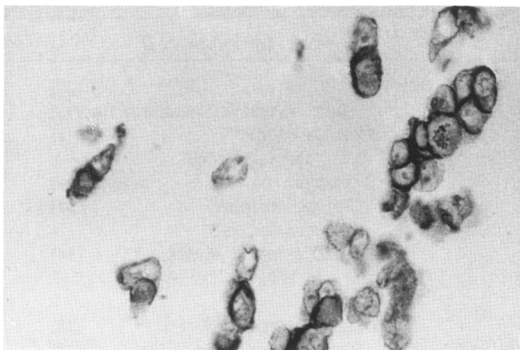
## Materials and Methods

### Case Selection

One hundred forty-one soft tissue tumors were examined (Table 1). These tumors were chosen to cover a broad spectrum of benign and malignant mesenchy-

mal tumors. They were selected mainly from the files of the Hospital of the University of Pennsylvania, although some cases were retrieved from the Children's Hospital of Philadelphia and from the consultation files of one of the authors (JJB). The routine sections from each case were reviewed, and the diagnoses confirmed.

Where appropriate and possible, immunohistochemical staining was performed on paraffin sections to confirm the diagnosis. Hemangiopericytomas were distinguished from monophasic synovial sarcomas by the absence of monoclonal keratin immunopositive cells, the absence of clusters of cells on reticulin stain, and the typical vascular pattern throughout. Most other sarcoma types were identified based on morphologic criteria. Immunohistochemistry was helpful in differentiating between cases of leiomyosarcoma (desmin positive) and nerve sheath tumors (S100 positive). The clear cell sarcoma was S100 positive and the epithelioid sarcoma was cytokeratin positive. All rhabdomyosarcoma were positive for either myoglobin, desmin or both muscle markers.



**Figure 1**—Nerve growth factor receptor (NGF-R) in melanoma cell line, A875. Cell membrane reactivity is accentuated in many cells, which also showed light cytoplasmic staining. (Immunohistochemical stain, original magnification,  $\times 100$ )

### Immunoperoxidase

Immunohistochemical staining was carried out via the avidin-biotin complex immunoperoxidase technique.<sup>13</sup> Five-micron paraffin-embedded sections were cut and melted at 50–60 C for 30 minutes, deparaffinized, and washed in running water for 5 minutes. Endogenous peroxidase activity was quenched by a 15 minute wash in 1.2% hydrogen peroxide in methanol. The sections were sequentially incubated at 37 C with normal horse blocking serum (10 minutes), undiluted primary antibody (overnight at 4 C), biotinylated secondary antisera (30 minutes), and avidin-biotin complex reagent (45 minutes) (Vector Laboratory Systems, Inc., Burlingame, CA). Each incubation was followed by 2 5-minute washes in  $P_iNaCl$  (0.15 g%  $Na_2HPO_4$ , 0.069 g%  $NaH_2PO_4 \cdot H_2O$ , and 0.79 g%  $NaCl$ ) and one wash in  $P_iNaCl$  with 1% bovine serum albumin (BSA), except for the first step where excess normal serum only was removed. Sections were exposed to the chromagen reaction solution (0.05% 3,3 diaminobenzidine tetrahydrochloride in  $P_iNaCl$ /0.1% BSA and 0.0002% hydrogen peroxide) for 5 minutes. After washing in tap water, the sections were counterstained in hematoxylin, dehydrated, cleared, and mounted.

Immunoreactivity was scored as follows: 0 = none, 1 = focal (0–2% of cells), 2 = scattered (2–20%), 3 = prominent (20–50%), and 4 = diffuse (>50%).

The previously characterized monoclonal antibody to nerve growth factor receptor (NGF-R) (clone # ME 20.4S, IgG1) was obtained courtesy of Dr. Alonzo Ross of the Wistar Institute, University of Pennsylvania and used undiluted. Briefly, this antibody has been shown to be specific for NGF-R through competitive inhibition of  $^{125}I$ -NGF binding and by immunoprecipitation of affinity labeled nerve growth factor receptor.<sup>11</sup>

The human melanoma cell line, A875, was obtained from the Wistar Institute and served as the positive control. Confluent cultures grown in minimal Eagle's medium supplemented with 10% fetal bovine serum were pelleted and fixed in Bouin's solution prior to embedding in paraffin. These reacted similar to cytocentrifugation preparations of the cell lines briefly fixed in 95% ethanol and stored until use at  $-20$  C.

The method of fixation used for each case was recorded and results on formalin-fixed and Bouin's-fixed tissues were compared. Frozen tissue was available on 58 cases for further comparison (Table 1).

### Absorptions

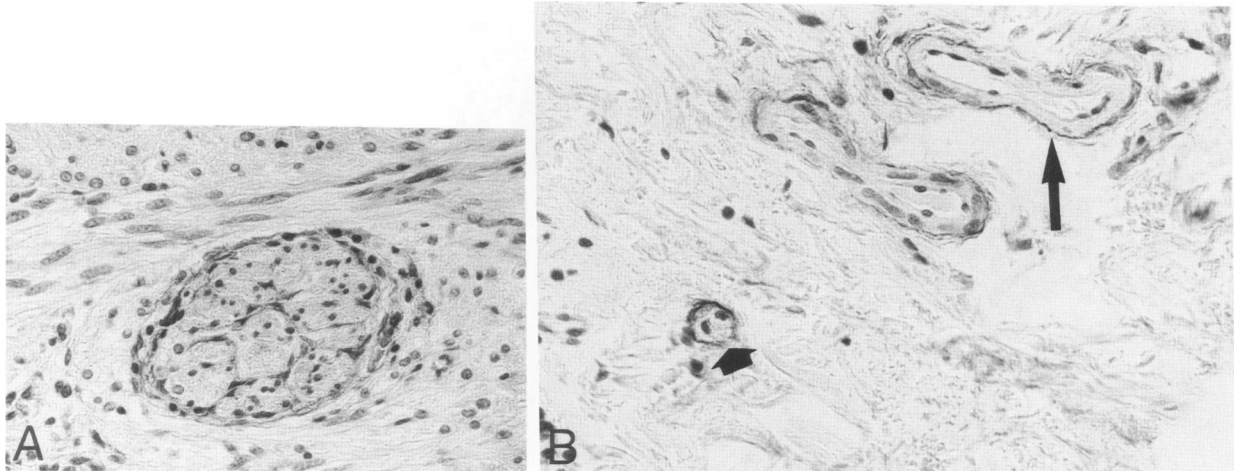
Approximately  $5 \times 10^6$  nondisrupted cells from the melanoma cell line A875 were used as the absorption reagent. This cell line is known to contain many copies of the NGF receptor identified as a soluble membrane protein of appropriate molecular weight that bound  $^{125}I$ -NGF.<sup>11</sup> Diluted antisera was added to the antigen and incubated overnight at 4 C, centrifuged (110,000g at 4 C for 30 minutes) and the supernatant stored at 4 C until use. Both the positive control and a representative tumor with known strong immunoreactivity were stained using absorption supernatant as the primary antisera. No immunoreactivity was observed after absorption of the antisera.

### Statistical Analysis

Classification analyses were used and corresponding *P* values reported. Where there were cell inadequacies, the Fisher's exact test was used.

### Results

Strong staining of the A875 control cell line was seen along the plasma membrane, with weaker reactivity of the cytoplasm (Figure 1). The strongest staining was seen in cells in active division. No immunoreactivity was observed after absorption. To identify NGF-R immunoreactivity among normal mesenchymal elements, 12 sections containing skeletal muscle, and over 20 sections containing areas of smooth muscle, endothelium, fibrous tissue, or adipose tissue adjacent to the tumors as well as in sections of skin and colon were examined. No evidence of reactivity was seen in these mesenchymal elements. In contrast, both the epineurium and endoneurium of nerves, seen in 18 sections adjacent to tumors, displayed strong immunoreactivity (Figure 2A). Ganglion cells and stellate support cells did not stain. In addition, strong perivascular staining was noted in many sec-



**Figure 2**—NGF-R in normal nerves. Epineurium and endoneurium, but not the axons, reacted with the monoclonal antibody (A). The thin perivascular reactivity (arrow) seen in many locations probably represented staining of nerve sheath of tiny nerve branches (B). Staining was even seen around capillaries (arrowhead). (Immunohistochemical stain,  $\times 100$ )

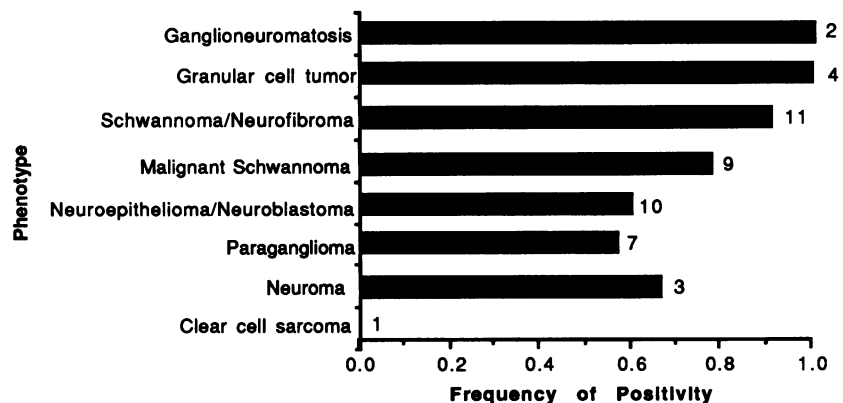
tions without staining of the vascular smooth muscle or endothelium. This was seen as a thin circular line of staining around vessels ranging from large muscular arteries to capillaries (Figure 2B). Although no nerves were identified, this probably represented staining of the nerve sheath of small nerve branches around these vessels. Germinal centers but not other lymph node elements reacted strongly. No epithelial staining was noted; however, the myoepithelium of breast ducts and eccrine glands exhibited immunoreactivity.

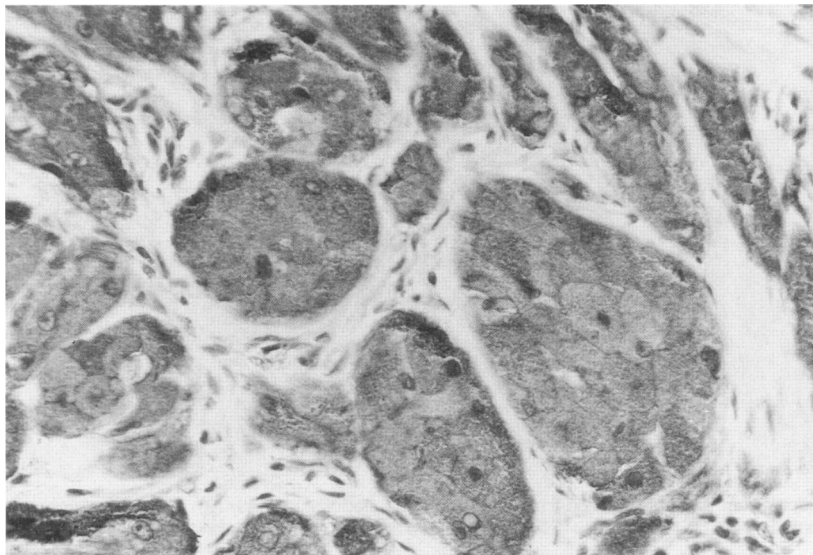
A high frequency of immunoreactivity was seen in both the benign and malignant neural tumors (74%, Figure 3). All of the granular cell tumors showed diffuse strong immunoreactivity, which in areas accentuated the cell borders (Figure 4). Similarly, the 2 cases of ganglioneuromatosis of the bowel showed strong staining of the spindled cell component but no staining of the ganglion cells. In addition, both benign and malignant peripheral nerve sheath tumors frequently expressed NGF-R (91 and 78% respectively)

(Figures 5 and 6). Included among the malignant Schwannomas were 2 cases of malignant Triton tumor. In 1 case the Schwannian component reacted while the rhabdomyosarcoma component did not; the other case showed no immunoreactivity of either element. Within neuroblastomas the immunoreactivity accentuated the rosette formations with strong staining of the centrally-placed cytoplasmic processes. Among paragangliomas, staining was typically focal, with scattered positive cells within the clusters. These “Zellballen,” however, were delineated by a prominent rim of staining (Figure 7). This probably represented perivascular staining noted around vessels of various sizes. Excluding the 1 case of clear cell sarcoma, >50% of all the neural tumors showed immunoreactivity with NGF-R.

The frequency of NGF-R immunoreactivity was compared among the various soft tissue tumor phenotypes (Figure 8). In addition to the neural tumors, there was a surprising degree of reactivity among 3

**Figure 3**—Comparison of NGF-R expression in neural tumors. The number of tumors of each type examined is identified at the end of the bar. Most entities exhibited a high-frequency of reactivity.

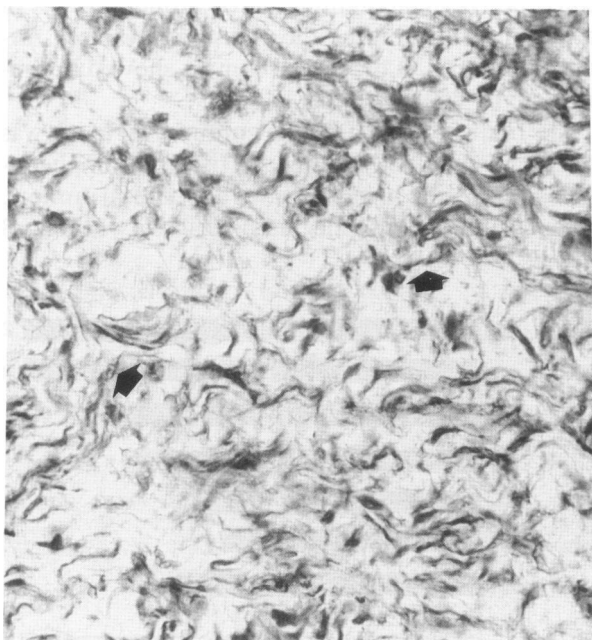



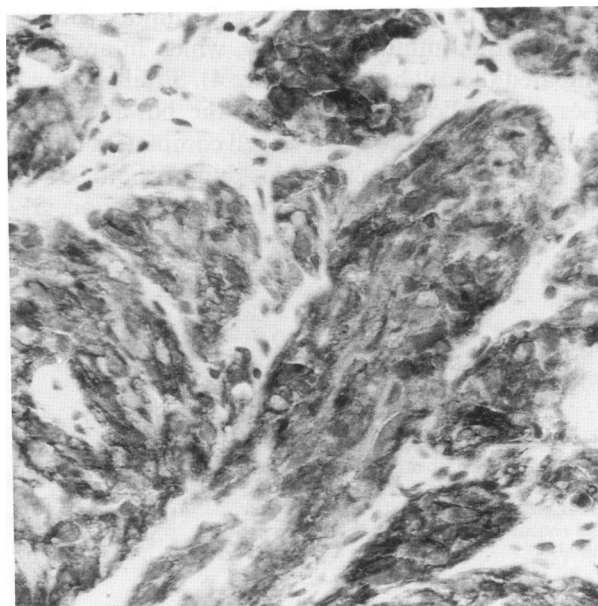
**Figure 4**—NGF-R in granular cell tumor. All cells in these lesions were darkly stained, often with prominent highlighting of the cell borders. (Immunohistochemical stain,  $\times 100$ )

other phenotypic groups including the synovial sarcomas (80%), the undifferentiated sarcomas (sarcoma, not otherwise specified, "NOS," 60%), and hemangiopericytomas (HPC, 43%). In the one biphasic synovial sarcoma, the glandular component showed strong immunoreactivity, while the spindled component reacted only focally with NGF-R (Figure 9). The spindled cell component of the monophasic tumors, however, typically showed diffuse positivity. Hemangiopericytomas were similar in this regard. The undifferentiated sarcomas also had areas of prominent immunoreactivity (Figure 10).

By comparison, only occasional reactivity was seen among the benign fibrous tumors (1/7) (# positive/# tested), benign and malignant smooth muscle tumors (2/16), and malignant fibrous histiocytoma (1/14). In contrast to many of the other tumors, the immunoreactivity seen in each of these cases was focal with  $<2\%$  of the cells staining. In addition, the staining in the leiomyosarcoma and the fibroma, although within lesional cells, was always adjacent to a blood vessel or nerve, raising the possibility of secondary uptake of antigen by the tumor cells.



**Figure 5**—NGF-R in neurofibroma. Note the prominent staining of the cell processes (arrow). (Immunohistochemical stain,  $\times 100$ )

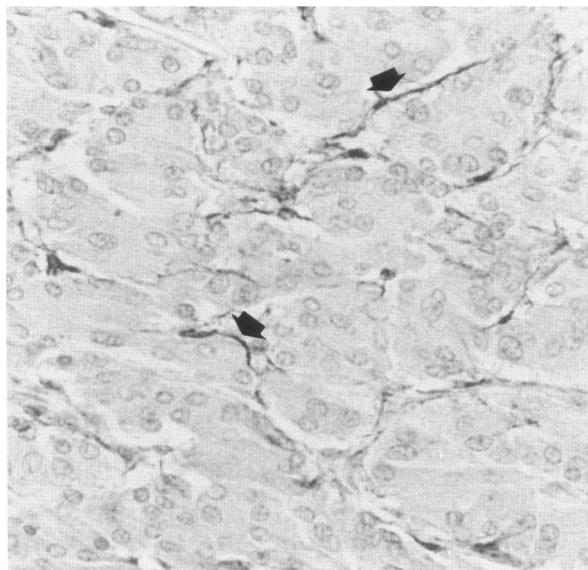


**Figure 6**—NGF-R in a superficial epithelioid malignant Schwannoma, one of the malignant peripheral nerve sheath tumors. Although this case showed diffuse, strong reactivity, such was not the case for all of the peripheral nerve sheath tumors. (Immunohistochemical stain,  $\times 100$ )

Of the other cases not displayed in Figure 8, the two cystosarcoma phylloides showed immunoreactivity, although focal or in scattered areas. Three malignant mixed mesodermal tumors (MMMT) all showed immunoreactivity to variable degrees within the mesenchymal components without epithelial reactivity. All of the remaining tumors, representing a broad spectrum of soft tissue tumor phenotypes, showed no immunoreactivity with NGF-R (Figure 8).

On examination of the sections, wide variability in the degree of staining of tumors was noted. This was most evident in the neural tumors, especially within certain subtypes (eg, Schwannoma), in which some cases showed diffuse positivity while others displayed only focal or no immunoreactivity. This led us to determine the method of fixation of the tissue prior to sectioning for immunohistochemistry as a potential source of this variability. Of the 47 neural tumors, 23 were fixed in Bouin's and 24 in formalin. Although the frequency of positive immunoreactivity was similar (83% of the Bouin's-fixed tumors vs. 67% of those formalin-fixed), the degree of reactivity was different between the 2 groups. Of the cases that showed reactivity, only 21% of the Bouin's-fixed sections had low reactivity scores (1 or 2) compared with 50% of the formalin fixed sections. This difference, although not statistically significant ( $P > 0.05$ ), suggested that fixation may influence immunoreactivity for NGF-R in paraffin sections. Bouin's fixation may better preserve this antigenicity.

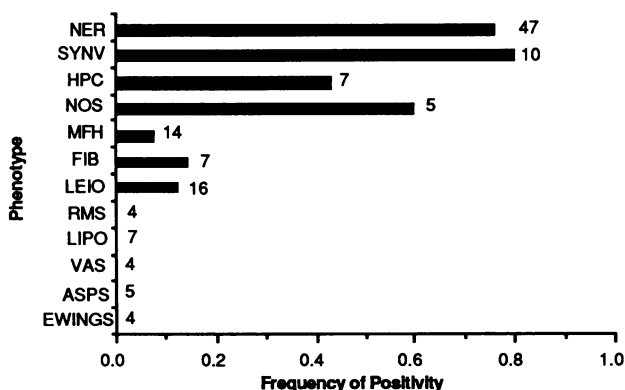
Fifty-eight of the soft tissue tumors examined also had frozen tissue available. These all had been stained with this antibody to NGF-R as part of another study and the results previously described.<sup>12</sup> All of the cases that showed immunoreactivity in paraffin-embedded sections also demonstrated immunoreactivity in the frozen section. In 5 cases, including 2 leiomyomata, 2 malignant fibrous histiocytomas, and 1 hemangiopericytoma, immunoreactivity was seen in the frozen section but not in paraffin. In all but the last, frozen tissue immunoreactivity was focal and may have represented uptake from adjacent nerves, a phenomenon observed in paraffin-embedded sections of other tumors. Thus, only 12% of the cases (5/58) showed a different immunoreactivity pattern in the frozen as compared to the paraffin-embedded section. This difference was not statistically significant ( $P > 0.25$ ), suggesting that paraffin embedding is comparable to frozen sections in preserving antigenicity for NGF-R. However, the fact that 5 cases showed staining in the frozen but not the paraffin section implies that fresh frozen tissue may better preserve NGF-R antigenicity, as it does for essentially all antigens.



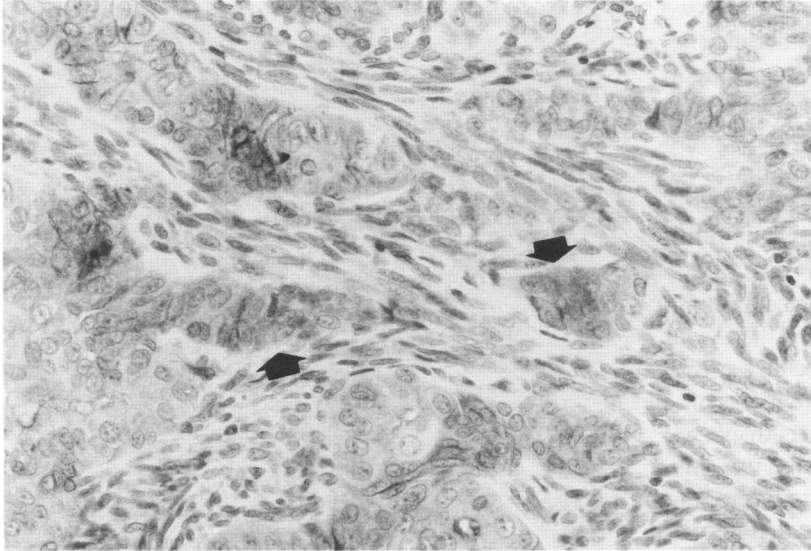
**Figure 7**—NGF-R in paraganglioma. Zellballen were outlined by a thin rim of reactivity (arrow). Only an occasional tumor cell exhibited a positive reaction, typically weak. (Immunohistochemical stain,  $\times 100$ )

## Discussion

Growth factors and growth factor receptors may play a crucial role in the understanding of the mechanisms of growth regulation in sarcomas. A recent study has shown that expression of growth factors and growth factor receptors was related to biologic potential of human soft tissue tumors, with malignant tumors more frequently expressing single or multiple factors and receptors.<sup>12</sup> In addition, recent investiga-



**Figure 8**—Expression of NGF-R across the soft tissue tumor phenotypes. Outside of the top four phenotypes displayed, only 4 of the remaining 61 tumors shown demonstrated immunoreactivity. In these, the staining was focal and occasionally suggested uptake from adjacent nerves. NER, neural; SYN, synovial sarcoma; HPC, hemangiopericytoma; NOS, undifferentiated sarcoma, not otherwise specified; MFH, malignant fibrous histiocytoma; FIB, benign fibrous; LEIO, leiomyoma and leiomyosarcoma; RMS, rhabdomyosarcoma; LIPO, lipoma and liposarcoma; VAS, benign vascular and angiosarcoma; ASPS, alveolar soft part sarcoma; EWINGS, skeletal Ewing's sarcoma.



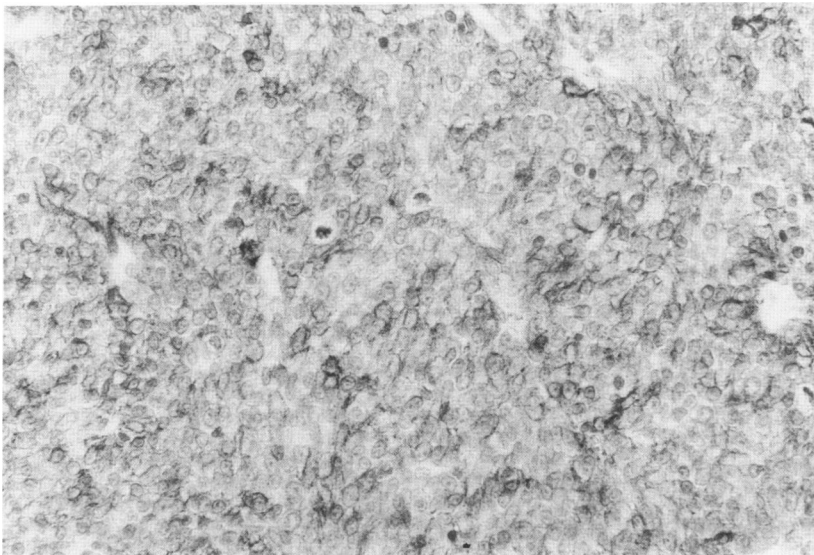
**Figure 9**—NGF-R in biphasic synovial sarcoma. Both epithelial and stromal cells stained, and outlines of individual cells can occasionally be seen. Note how the staining accented the glandular component of this tumor (arrow). (Immunohistochemical stain,  $\times 100$ )

tions of bombesin, a potent mitogen for small cell lung carcinoma cells in culture have shown that inhibition of binding of this growth factor inhibited the growth of these cells as tumors in nude mice.<sup>14-17</sup> Thus, increased expression of growth factors and/or receptors may allow neoplasms to escape exogenous controls on growth, thereby increasing their tumorigenic potential.

Expression of nerve growth factor receptor in particular may be an important influence on tumorigenic potential in soft tissue tumors, especially those of neural or neural crest origin. For example, NGF-R has been demonstrated in nevi and malignant melanoma but not in normal melanocytes.<sup>11</sup> It also has been shown in cultured Schwann cells from neurofibro-

mata and traumatic neuromas, as well as pheochromocytomas and neuroblastomas.<sup>6-10</sup> We undertook a detailed study of soft tissue tumors, with emphasis on the neural phenotype, to determine the frequency and specificity of NGF-R expression in these neoplasms.

In normal nerves, the staining was seen in the nerve sheath rather than within the axons or ganglion cells. Similarly, immunoreactivity to NGF-R was seen around blood vessels of various sizes, ranging from capillaries to muscular arteries. The endothelium and smooth muscle, in contrast, did not react. Such perivascular staining probably represented an immunoreactive nerve sheath of tiny neural processes known to be associated with blood vessels.<sup>18</sup> No other normal epithelial or mesenchymal tissue expressed NGF-R,



**Figure 10**—NGF-R in an undifferentiated sarcoma (sarcoma, not otherwise specified [NOS]). Diffuse strong reactivity, producing dark scanty cytoplasm rings encircling nuclei, was observed in this grade III sarcoma from near the knee. (Immunohistochemical stain,  $\times 100$ )

with the exception of the myoepithelial layer of breast and eccrine ducts.

Similar to normal nerve sheath, benign and malignant peripheral nerve sheath tumors expressed NGF-R frequently. Only a few cases of benign nerve sheath lesions had been previously tested, and our observations extend those results.<sup>11</sup> No differences in staining were noted between neurofibromata and Schwannomas nor between benign and malignant peripheral nerve sheath neoplasms. Immunoreactivity for NGF-R was also detected in many tumors of neural crest origin such as neuroblastomas and paragangliomas, as previously described by Ross et al.<sup>11</sup> Neuroepitheliomas showed similar reactivity. Interestingly, staining among the paragangliomas was focal, within scattered cells of the clusters or "Zellballen." However, strong perivascular staining surrounding the clusters was seen. Overall, 74% of the neural and neural crest tumors expressed NGF-R. The reactivity of NGF-R antibody in neural lesions did not necessarily parallel that of S100: occasional S100 negative malignant nerve sheath tumors were NGF-R positive, and neuronal tumors like neuroblastoma are consistently S100 negative but often NGF-R positive.

This high frequency of immunoreactivity to NGF-R was not limited to tumors of known neural origin. Similar high frequencies of NGF-R expression were seen among synovial sarcomas, undifferentiated sarcomas, and hemangiopericytomas (all of which are S100 negative lesions). Although considered to be mesenchymal tumors, the histogenesis of these tumors is unknown, and they could possibly be related. It is well known, for example, that synovial sarcomas often contain pericytomatous areas, however, the expression of cytokeratin confirms the diagnosis of monophasic synovial sarcoma.<sup>19,20</sup> Thus, synovial sarcomas and some hemangiopericytomas may be potential relatives, a concept supported by their similar reactivity with NGF-R. Likewise, some of the undifferentiated sarcomas may be related to the neural phenotype. After all, the undifferentiated sarcomas represent tumors that could not be classified into a particular sarcoma phenotype by standard histologic criteria or by immunohistochemical staining. Expression of NGF-R by these tumors suggests a possible link which might relate to the neural phenotype. One can postulate that these sarcomas are so undifferentiated that they no longer express diagnostic immunohistochemical markers such as S100 antigen.

In contrast, a low frequency of NGF-R expression (<15%) was seen in tumors of fibrous, fibrohistiocytic, and smooth muscle origin. In addition, this immunoreactivity was typically focal. In 2 of the 4 cases, the positive cells were adjacent to strong neural or peri-

vascular staining, suggesting the possibility of secondary uptake by the lesional cells. Thus, although NGF-R expression was not specific for the neural phenotype, it was seen infrequently among these other soft tissue tumor phenotypes. Among the other mesenchymal tumors examined (rhabdomyosarcomas, liposarcomas, lipomas, benign vascular tumors, Ewing's sarcomas, and alveolar soft part sarcomas), none expressed this receptor. In addition, no staining was seen in one case each of epitheloid sarcoma, Kaposi's sarcoma, uterine stromal sarcoma, atrial myxoma, fibrothecoma, or angiomyolipoma. Interestingly, immunoreactivity within cystosarcoma phyllodes may reflect that seen in normal myoepithelium. Differentiation toward a neural phenotype may explain the NGF-R reactivity seen in the stroma of malignant mixed mesodermal tumors.

On examination of the stained sections, variability in the frequency and degree of positive immunoreactivity were noted among the cases, especially within the neural phenotype. For example, of the 9 malignant Schwannomas, 4 showed diffuse immunoreactivity, 2 displayed focal reactivity, and 3 did not react. This led to the suspicion that the method of fixation of the sections was a factor in this variable staining. Indeed, when fixation was compared, Bouin's-fixed sections more frequently showed positive immunoreactivity, and more frequently showed diffuse rather than focal positivity. While Bouin's appeared superior to formalin fixation, these differences were not statistically significant.

Thus, this study suggests that the antibody to nerve growth factor receptor may play a role in future diagnostic immunohistochemistry as a valuable adjunct in conjunction with other markers as part of a panel in the evaluation of soft tissue tumors. Even though expression of NGF-R was frequently seen among tumors of the neural phenotype, expression was not limited to neural lesions and would not necessarily exclude another cell of origin for a soft tissue neoplasm. The good correlation of the staining in paraffin-embedded sections with that in frozen tissue further supports this role for routine diagnostic work. Finally, our study prompts further investigation into the possible relationships between hemangiopericytomas, synovial sarcomas, and the neural phenotype.

## References

1. Huang JS, Huang SS, Deuel TF: Transforming protein of simian sarcoma virus stimulates autocrine growth of SSV-transformed cells through PDGF cell-surface receptors. *Cell* 1984, 39:79-87
2. Deuel TF, Huang JS: Platelet-derived growth factor: Structure, function, and roles in normal and transformed cells. *J Clin Invest* 1984, 74:669-676



3. Ullrich A, Coussens L, Hayflick JS, Dull TJ, Gray A, Tam AW, Lee J, Yarden Y, Libermann TA, Schlessinger J, Downward J, Mayers ELV, Whittle N, Waterfield MD, Seeburg PH: Human epidermal growth factor receptor cDNA sequence and aberrant expression of the amplified gene in A431 epidermoid carcinoma cells. *Nature* 1981, 309:418-425
4. Yanker BA, Shooter EM: The biology and mechanism of action of nerve growth factor. *Ann Rev Biochem* 1982, 51:845-868
5. Greene LA, Tischler AS: Establishment of a noradrenergic clonal line of rat adrenal pheochromocytoma cells which respond to nerve growth factor. *Proc Natl Acad Sci* 1976, 73:2424-2428
6. Sonnenfeld KH, Ishii DN: Nerve growth factor effects and receptors in cultured human neuroblastoma cell lines. *J Neurosci Res* 1982, 8:375-391
7. Fabricant RN, DeLarco JE, Todaro GJ: Nerve growth factor receptors on human melanoma cells in culture. *Proc Natl Acad Sci* 1977, 74:565-569
8. Sonnenfeld KH, Bernd P, Sobue G, Lebwohl M, Rubenstein AE: Nerve growth factor receptors on dissociated neurofibroma schwann-like cells. *Cancer Res* 1986, 46:1446-1452
9. Schechter AL, Bothwell MA: Nerve growth factor receptors on PC12 cells: Evidence for two receptor classes with differing cytoskeletal association. *Cell* 1981, 24:867-874
10. Ross AH, Pleasure D, Sonnenfeld K, Atkinson B, Kreider B, Jackson DM, Taff I, Scarpini E, Lisak RP, Koprowski H: Expression of melanoma-associated antigens by normal and neurofibroma Schwann cells. *Cancer Res* 1986, 46:5887-5892
11. Ross AH, Grob P, Bothwell M, Elder DE, Ernst CS, Marano N, Ghirst BFD, Slemp CS, Herlyn M, Atkinson B, Koprowski H: Characterization of nerve growth factor receptor in neural crest tumors using monoclonal antibodies. *Proc Natl Acad Sci* 1984, 81:6681-6685
12. Perosio PM, Brooks JJ: Expression of growth factors and growth factor receptors in soft tissue tumors: implications for the autocrine hypothesis. *Lab Invest*, in press.
13. Hsu SM, Raine L, Fanger H: A comparative study of the peroxidase-antiperoxidase method and an avidin-biotin complex method for studying polypeptide hormones with radioimmunoassay antibodies. *Am J Clin Pathol* 1981, 75:734-738
14. Cuttitta F, Carney DN, Mulshine J, Moody TW, Fedorko J, Fischler A, Minna JD: Bombesin-like peptides can function as autocrine growth factors in human small-cell lung cancer. *Nature* 1985, 316:823-826
15. Moody TW, Pert CB, Gazdar AF, Carney DN, Minna JD: High levels of intracellular bombesin characterize human small-cell lung carcinoma. *Science* 1981, 214:1246-1248
16. Erisman MD, Linnolia RI, Hernandez O, DiAugustine RP, Lazarus LH: Human lung small-cell carcinoma contains bombesin. *Proc Natl Acad Sci* 1982, 79:2379-2383
17. Moody TW, Bertness V, Carney DN: Bombesin-like peptides and receptors in human tumor cell lines. *Peptides* 1983, 4:683-686
18. Simonescu N, Simonescu M: The cardiovascular system, *Histology: Cell and Tissue Biology*, 5th edition. Edited by L Weiss. New York, Elsevier Biomedical, 1977, pp 371-433
19. Fisher C: Synovial sarcoma: Ultrastructural and immunohistochemical features of epithelial differentiation in immunohistochemical features of epithelial differentiation in monophasic and biphasic tumors. *Hum Pathol* 1986, 17:996-1008
20. Abenzoa P, Manivel JC, Swanson PE, Wick MR: Synovial sarcoma: Ultrastructural study and immunohistochemical analysis by a combined peroxidase-antiperoxidase/avidin-biotin peroxidase complex procedure. *Hum Pathol* 1986, 17:1107-1115

### Acknowledgment

The authors thank Dr. Alonzo Ross for supplying the antibody to nerve growth factor receptor, Dr. Katrina Conard for assistance in assembling the cases for study, Dr. Ed Lusk for his assistance with the statistical analysis, and Bethann Gee, HT (ASCP) and David Chianese, CT (ASCP) (IAC) for their technical assistance and advice.