

Demonstration of Phenotypic Abnormalities of Thymic Epithelium in Thymoma Including Two Cases with Abundant Langerhans Cells

VIRGINIA B. KRAUS, MD,
ELIZABETH A. HARDEN, MD,
BENJAMIN WITTELS, MD,
JOSEPH O. MOORE, MD,
and BARTON F. HAYNES, MD

From the Department of Medicine, Division of Rheumatology and Immunology, Hematology and Dermatology, and the Departments of Surgery and Pathology, Duke University School of Medicine, Durham, North Carolina

A panel of monoclonal antibodies that phenotypically define stages of normal human thymic epithelial (TE) cell maturation was used to compare thymic epithelium of nine thymomas with hyperplastic thymic epithelium in myasthenia gravis (MG) and thymic epithelium of normal thymuses. It has been shown previously that normal thymic epithelial cells express antigens of early TE cell maturation (A2B5, TE-4) throughout thymic ontogeny and acquire antigens 12/1 - 2, TE8, and TE-15 at 14 to 16 weeks of fetal gestation. Hyperplastic MG thymic epithelial cells expressed TE antigens in phenotypic patterns similar to that seen in normal postnatal thymus, ie, TE in subcapsular cortex and medulla was TE4+, A2B5+, and 12/1 - 2+ and Hassall's bodies were reactive with antibodies TE8 and TE15. In contrast, thymic epithelium in primary mediastinal thymomas was TE4+, A2B5+, TE8-, and greater than 75% of thymoma epithelium was

12/1 - 2-, a thymic epithelial phenotype similar to that seen on normal fetal thymic epithelium at 14 to 16 weeks fetal gestation. In one subject with a mature epithelial histologic pattern, thymoma epithelium was found to be strongly TE8+, a phenotype suggestive of a later stage of TE maturation. Lymphocytes in five of seven thymomas with immature thymic epithelial cells predominately expressed immature thymocyte phenotype while two thymomas with immature epithelial phenotype showed a predominance of Langerhans cells and surrounding lymphocytes expressing a mature phenotype. Lymphocytes in the thymoma with differentiated epithelial cells expressed a mature thymocyte phenotype. Thus, in thymomas of varying histologic types, phenotypic abnormalities of thymic epithelium are present; these phenotypic abnormalities may reflect abnormal thymic epithelial maturation. (Am J Pathol 1988, 132:552-562)

THE THYMIC MICROENVIRONMENT is a complex specialized tissue that promotes T cell maturation by direct cell-cell contact and by secretion of thymic hormones.^{1,2} Thymomas are a heterogeneous group of malignancies that arise in the anterior mediastinum and are composed of both epithelial cells and lymphocytes. Although in many thymomas the nature of the neoplastic cell is not known, it is thought to be derived from thymic epithelium.^{3,4}

A panel of monoclonal reagents raised against human thymic epithelium has been developed that identifies distinct subsets of normal thymic epithelium.^{5,6} Moreover, it has been demonstrated that these reagents phenotypically define discrete stages of thymic epithelial cell maturation.^{5,6}

This study uses the panel of monoclonal antibodies directed against human thymic epithelium as well as monoclonal antibodies recognizing T cell differentiation antigens as probes to study thymic epithelial maturation and intrathymic T cell maturation in thymomas. Phenotypic abnormalities of thymic epithelium were found in eight of nine thymomas studied. Seven thymomas expressed thymic epithelial markers similar to those seen in 14 to 16 week fetal thymuses, while one thymoma expressed thymic epithelial antigens normally found only on terminally differentiated thymic epithelial cells (Hassall's bodies).

Accepted for publication April 26, 1988.

Address reprint requests to Barton F. Haynes, Box 3258, Duke University School of Medicine, Durham, NC 27707.

Table 1—Clinical Features of Thymoma Patients

Patient no.	Age/sex	Presenting symptoms	Radiographic findings	Weight of tumor (gm)	Histology
1	45/M	Myasthenia gravis	Anterior mediastinal mass	200	Lymphocyte predominance with occasional abortive HB, extending into adjacent lung
2	70/M	Myasthenia gravis × 21 years	Anterior mediastinal mass	102	Lymphocyte predominance
3	67/M	Persistent cough	Anterior mediastinal mass	900	Mixed population of lymphocytes and immature epithelial cells
4	61/F	Myasthenia gravis	Anterior mediastinal mass	NA	Mixed population of lymphocytes and immature epithelial cells
5	41/M	Myasthenia gravis	Anterior mediastinal mass	80	Immature epithelial cell predominance
6	47/M	Asymptomatic incidental finding at thoractomy for cardiac surgery	Normal chest x-ray	135	Immature epithelial cell predominance
7	52/M	Myasthenia gravis	Anterior mediastinal mass	86	Immature epithelial cell predominance extending into adjacent lung with abundant Langerhans cell
8	61/M	Asymptomatic incidental finding on chest x-ray	Anterior mediastinal mass	130	Immature epithelial cell predominance with abundant Langerhans cells
9	43/F	Persistent cough	Superior middle mediastinal mass	63	Mature epithelial cell predominance with occasional keratin deposit

Materials and Methods

Thymus and Thymoma Tissue

Portions of thymomas were obtained from the Department of Pathology, Duke Hospital, from nine patients undergoing therapeutic or diagnostic thoractomy for mediastinal masses or myasthenia gravis. The clinical characteristics and thymoma histology are shown in Table 1. Thymomas were defined as tumors of the thymus gland composed of lymphoid and epithelial cells in varying proportions according to the criteria of Rosai and Levine.⁷ The thymomas were morphologically subclassified on the basis of the relative amounts of lymphoid and epithelial cells and the state of maturity of the latter. Using these criteria, four categories were identified: lymphocyte—predominant type; mixed lymphocyte—immature epithelial cell type; immature epithelial cell predominant type; and mature epithelial cell type. Hyperplastic thymus was defined as lymphoid hyperplasia of thymus with the presence of germinal centers.⁷

Thymocyte single cell suspensions were prepared and characterized by a panel of monoclonal antibodies to T cell differentiation antigens as described previously.⁸

Four-micron frozen sections of eight normal thymuses, four hyperplastic MG thymuses, and nine thymoma specimens were assayed for reactivity with saturating amounts of monoclonal antibodies in indirect immunofluorescence assay as described in detail.⁹

The panel of monoclonal antibodies directed against T cell differentiation antigens included antibodies 35.1 (CD2) which defines the sheep erythrocyte rosette receptor,¹⁰ 3A1 (CD7) a pan T cell

marker,¹¹ anti-p80 (A1G3) against mature medullary thymocytes,¹² and NA1/34 (CD1) against the T6 antigen on cortical thymocytes.¹³ Medullary thymocytes strongly express the p80 antigen and cortical thymocytes weakly express the p80 antigen.¹² In this paper, weak reactivity of anti-p80 was scored as negative and strong reactivity of anti-p80 was scored as positive. The antigens defined by Leu 3a (CD4) (anti-T4) and Leu 2a (CD8) (anti-T8) are found on virtually all cortical thymocytes and on subsets of medullary thymocytes and peripheral blood T lymphocytes.¹⁴ WT31 against a common determinant of the alpha or beta chain of the T cell receptor for antigen defines mature T lymphocytes and was the gift of Dr. Wil Tax.¹⁵

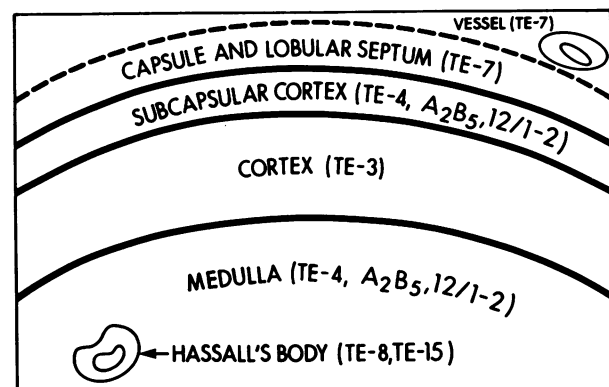


Figure 1A—Phenotypic characterization of epithelial zones of human thymus. The four categories of reagents used in this study represented in this figure are: A—antibody TE7 identifies mesodermally-derived fibrous capsule, lobular septae and vessels; B—antibodies TE4, A2B5, and 12/1-2 identify ectodermally-derived epithelium of thymus subcapsular cortex and medulla; C—antibody TE3 identifies endodermally-derived epithelium of cortex; and D—antibodies TE8 and TE15 selectively identify terminally differentiated medullary thymic epithelial cells in Hassall's bodies (adapted from reference 2).

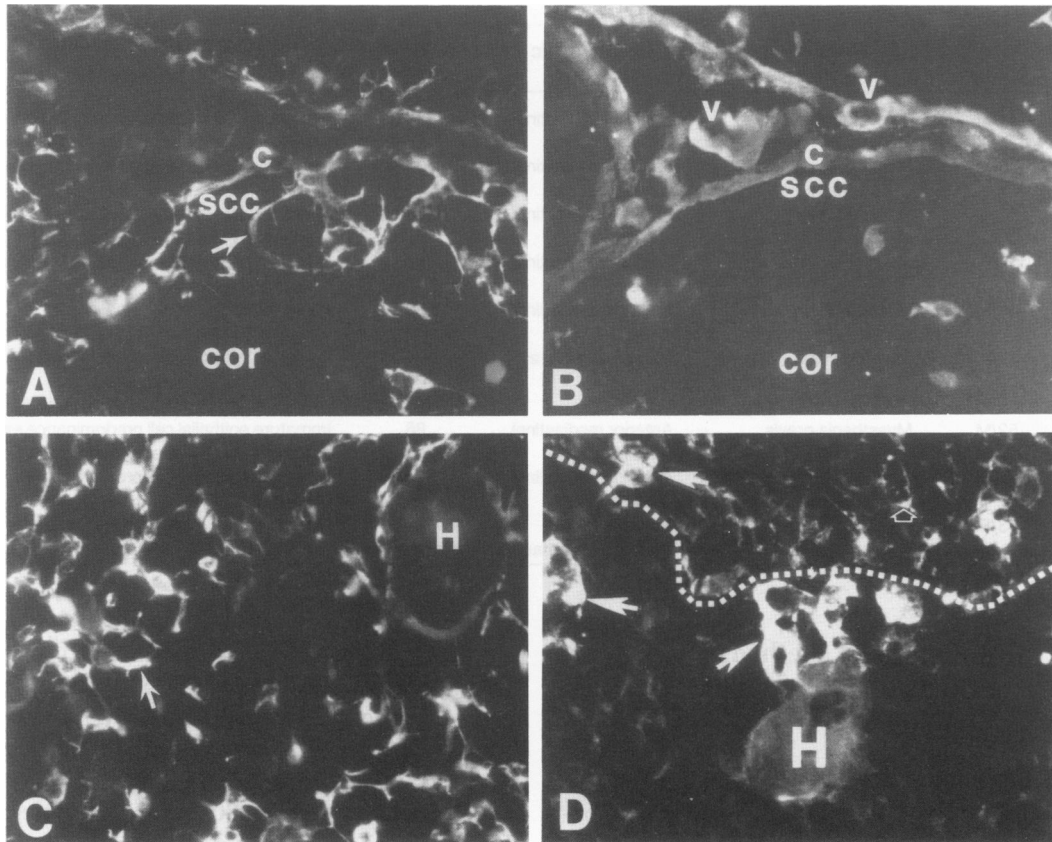


Figure 1B—Monoclonal antibody-defined regions of normal human postnatal thymus in indirect immunofluorescence assay using thymus tissue sections. A—antibody A2B5 identifies epithelium in the subcapsular cortex (SCC), but not in the inner cortex (COR). B—identical thymic region to that in panel A reacting in double immunofluorescent assay with antibody TE7 that reciprocally identifies fibrous stroma in the capsule (C) and lobular septum, and vessels (V), but does not react with A2B5+ thymic epithelium in the subcapsular cortex (SCC). C—antibody A2B5 identifies medullary thymic epithelium in the thymic medulla. D—antibody TE3 reacts with inner cortical epithelium (open arrow) and TE3 positive macrophages (closed arrows) but not with medullary thymic epithelium. H in panels C and D denotes Hassall's bodies. 400X

Monoclonal antibody BA1 binds to mature B cells.¹⁶ Anti-S100 antibody (Dako Corporation, Santa Barbara, CA) reacts with Langerhans cells.¹⁷

The panel of monoclonal antibodies directed against thymic stroma (Table 2) included monoclonal antibodies A2B5 and TE4 that define thymic hormone-containing thymic epithelial cells in the subcapsular cortex and medulla.^{5,18,19} Monoclonal antibody 12/1 - 2 was raised against the human T cell leukemia virus (HTLV) structural protein p19, and has been found to react with low molecular weight keratins of non-HTLV infected, thymic hormone-containing thymic epithelial cells.²⁰ Whereas A2B5 and TE-4 antigens are conserved in ontogeny on thymic epithelium beginning at 7 weeks fetal gestation, antibody 12/1 - 2 reactivity is acquired on fetal thymic epithelium beginning at 15 weeks fetal gestation,²⁰ with all TE5+, A2B5+ thymic epithelium reactive with antibody 12/1 - 2 by 36 months postnatally.²⁰ Thus, antibody 12/1 - 2 provides a unique marker for stages of thymic epithelial maturation.²¹ Antibody TE3 reactivity is acquired in thymus at 10 weeks fetal gestation and binds to an intracellular an-

tigen in cortical but not medullary thymic epithelium.²¹ Antibody TE7 defines mesodermal-derived thymic stroma, which includes the thymic capsule, interlobular septae, and vessels.⁵ Antibodies TE8 and TE15 react with thymic Hassall's bodies and have been shown previously to be markers of terminal differentiation of keratinized epithelium in skin and thymus.⁶

AE-1 and AE-3 are monoclonal antibodies to human epidermal keratins and were the generous gift of Dr. T. T. Sun, New York University, New York, NY.²⁵ Antibody AE1 identifies basal epidermal cells in skin and in thymus reacts with medullary thymic epithelium and Hassall's bodies. AE-3 reacts with all layers of epidermal keratinocytes in skin and in thymus reacts with medullary thymic epithelium and Hassall's bodies. Polyclonal antithymosin α 1 antibody was the generous gift of Dr. Allan Goldstein, George Washington University, Washington, D.C. Antibody EGFR-1 recognizes the human epidermal growth factor (EGF) receptor and was the gift of Dr. Peter Goodfellow (Oxford, England).²⁶

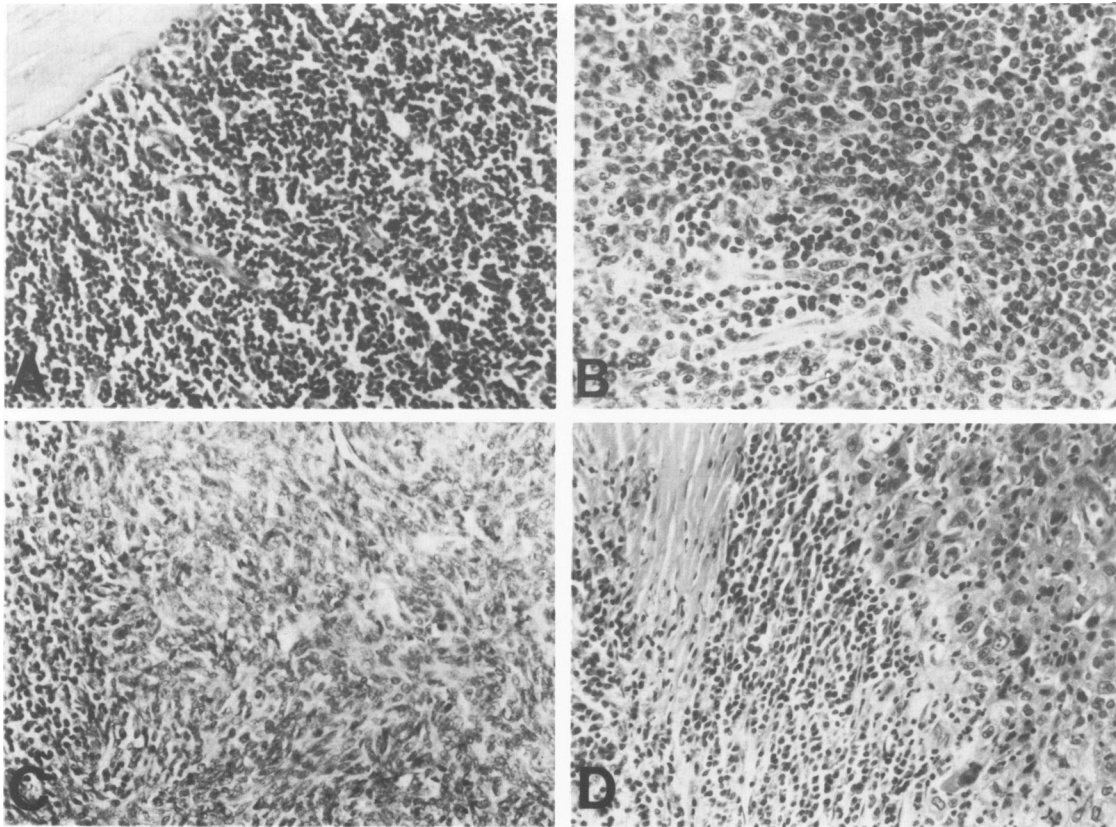


Figure 2—H & E-stained light micrographs of histologic types of thymoma. **A**—Thymoma with lymphocyte predominance $\times 250$ (patient no. 1). The majority of cells seen are small round lymphocytes. **B**—Thymoma with mixed population of lymphocytes and epithelial cells (patient no. 3). $\times 400$ The cells with the small round darker staining nuclei are lymphocytes, the cells with the paler staining polymorphous nuclei are immature epithelial cells. **C**—Thymoma with immature epithelial cell predominance (patient no. 6). $\times 250$ To the left of the photomicrograph is an area of small round lymphocytes while the remainder are immature epithelial cells. **D**—Thymoma with mature epithelial cell predominance (patient no. 9). $\times 250$ Pictured are areas containing fibrous septum, lymphocytes and mature epithelial cells. The epithelial cells manifest a squamous appearance.

Results

Phenotypic Characterization and Structure of Thymic Epithelial and Lymphoid Components in Normal Thymus

Anatomically, the normal human thymus can be divided into four regions: the fibrous capsule and interlobular septae, the subcapsular cortex, the inner cortex, and the medulla. Figure 1A demonstrates schematically the phenotypic characterization of these thymic regions from our previous work of the study of normal postnatal thymuses.^{2,5,6,20,21} Antibody TE7 defines the fibrous capsule vessels and interlobular septae while antibodies A2B5 and TE4 defines thymic epithelium in the subcapsular cortex and medulla.⁵ Antibody TE-3 defines the cortical epithelial component of thymus.²¹ It has been shown previously that normal A2B5+, TE4+ medullary thymic epithelial cells form TE4 negative Hassall's bodies, and in doing so acquire antigens defined by monoclonal antibodies TE8 and TE15.^{6,22-24} Antibody 12/1 - 2 defines a keratin antigen that is acquired in TE4+/

A2B5+ subcapsular cortical and medullary TE cells beginning at 14 to 16 weeks of fetal gestation with foci of subcapsular cortical TE cells becoming 12/1 - 2+.²⁰ By 36 weeks after birth, all TE4+/A2B5+ TE cells are 12/1 - 2+.²⁰

Thus, this panel of monoclonal antibodies defines ordered zones of normal thymus lobules (Figure 1B).² This panel of reagents was then used to study the phenotype of epithelium in four hyperplastic MG thymuses and nine thymomas.

Phenotypic Characterization and Structure of Thymic Epithelial and Lymphoid Components in Hyperplastic Myasthenia Gravis Thymus

Like normal thymuses, MG hyperplastic thymuses were organized into cortical and medullary zones. As previously reported, MG thymic epithelium in the subcapsular cortex and medulla was TE4+, A2B5+ and AE - 1+.²⁷ Additionally, like normal adult thymus, all TE - 4+ epithelium was 12/1 - 2+. Formed Hassall's bodies were present throughout the medul-

Table 2—Monoclonal Antibodies Against Thymic Stroma

Monoclonal antibody	Reactivity	Reference
A2B5	Medullary and subcapsular cortical thymic epithelium	17
TE4	Thymosin α -1 containing thymic epithelium conserved throughout thymic ontogeny	5
TE3	Cortical thymic epithelium	19
12/1 - 2	Antigen on keratin of thymic epithelium acquired in thymuses at 16 weeks fetal gestation	18
TE7	Nonepithelial thymic stroma	5
TE8	Hassall's bodies	6
TE15	Hassall's bodies	6

lary portion of hyperplastic MG thymuses and reacted with antibodies TE8 and TE15²⁷ (not shown).

It has been reported previously that analysis of the lymphoid component in frozen tissue sections of MG thymuses demonstrated, like normal thymocytes, cortical MG thymocytes were T6+ p80- while medullary thymocytes were T6- p80+.²⁷ In addition, the authors and others have described an expansion of medullary (p80+) thymocytes in MG.²⁷⁻²⁹

Phenotypic Characterization of Thymic Epithelial Components in Thymoma Tissue

Hematoxylin and eosin stained micrographs of histologic types of thymoma studied are shown in Figure 2. The phenotypic characterization of the epithelial components of nine thymomas revealed marked differences in the thymoma tissue as compared with normal or MG thymus. Like normal thymus, all thymomas contained epithelium that was TE4+ and A2B5+ (Table 3). In addition, all TE4+ thymic epithelial areas in thymoma contained thymosin α 1 by

indirect immunofluorescence assays (Figures 3B, 3G). Unlike normal thymus, the TE4+ thymic epithelium in thymomas was distributed homogeneously through the entire thymoma tissue with loss of the normal subcapsular cortex-medullary distribution (Figure 3B). Interestingly, unlike normal adult thymuses wherein all TE4+ epithelium was 12/1 - 2+, in eight of nine cases, only a minor subset or none of the TE4+ thymic epithelial cells were 12/1 - 2+ (Figure 3E). In four of nine mediastinal thymomas all TE4+ epithelium was completely nonreactive with 12/1 - 2, and in four of nine cases antibody 12/1 - 2 reacted with less than 25% of the TE4+ epithelial component (Table 3). In one case (no. 7) normal thymus tissue was available for analysis along with thymoma tissue. Whereas the thymoma tissue was 12/1 - 2-, normal TE4+ TE cells were all 12/1 - 2+ (not shown). Since all thymoma patients were adults and all TE4+ normal adult thymic epithelium is 12/1 - 2+, this lack of reactivity of anti-12/1 - 2 with TE4+ epithelium in eight of nine thymomas suggested a phenotypic similarity of these thymomas with fetal or neonatal TE4+, 12/1 - 2- thymic epithelium.³⁰

Reactivity of eight of nine thymoma specimens (exception thymoma no. 9) with antibodies that define terminal stages of keratinized epithelial cell maturation (TE8, TE15) *in vivo* was negative or showed reactivity only with a few (<5% total) scattered thymic epithelial cells (Figure 3H). Monoclonal antibodies AE-1 and AE-3 directed against keratins were strongly positive in all thymomas (Figure 3F, Table 3). In contrast, in one thymoma (no. 9) all TE cells were strongly TE8+ with scattered areas of weakly TE4+ staining TE cells (Figures 4B, 4D).

Unlike normal thymus, mediastinal thymomas contained TE7+ fibrous stroma that was not com-

Table 3—Phenotype of Epithelial Component of Thymoma Tissue as Defined by Monoclonal Antibodies to Thymic Epithelium

Antibody	Lymphocyte predominance		Mixed population lymphocytes & epithelial		Immature epithelial cell				Mature epithelial cell
	1	2	3	4	5	6	7	8	9
Patient no.	1	2	3	4	5	6	7	8	9
TE4	+	+	+	+	+	+	+	+	±
A2B5	+	+*	+	+	+	+*	+	+	-
TE3	+	+	+	+	+	+	+	+	+
12/1 - 2	-	-	-	-	+	-	-	-	-
TE8	-	-†	-	-	-	-	-†	-†	+
TE15	-	-	-	-	-	-	-†	-	-
AE-1	+	+	+	+	+	+	+	+	+
AE-3	+	+	+	+	+	+	+	+	+
EGFR ₁	+	+	+	+	+	+	+	+	+

* Staining though positive extremely weak in intensity.

† >90% of cells negative; rare cells positive.

+, >90% TE cells +.

±, >25%, <90% TE cells +.

-, <25% TE cells +.

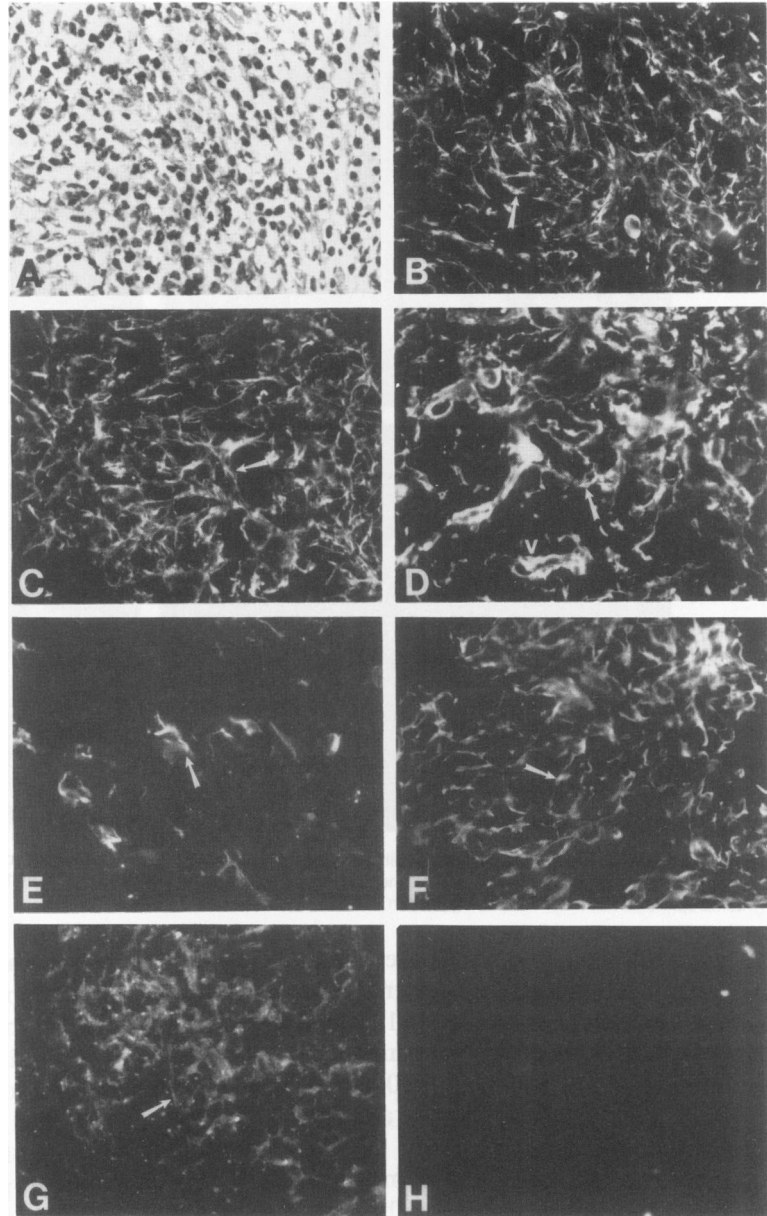


Figure 3—Phenotype of thymoma of immature epithelial type (patient no. 6). **A**—H & E-stained light micrograph. **B**—TE4 reactive thymoma epithelium (arrow). **C**—TE3 reactive epithelium (arrow). **D**—TE7 reactive fibrous tissue and vessels (V) (arrow). **E**—Rare epithelial cell reacting with antibody 12/1 - 2 (arrow). **F**—AE1 (anti-keratin) reactive thymoma epithelium (arrow). **G**—Thymosin α -1 reactive epithelium (arrow). **H**—TE8 negative epithelium. $\times 400$

partmentalized but rather was homogeneously intermixed with TE4+ epithelium (Figure 3D).

Monoclonal antibody EGFR1 reacted strongly with the nine thymoma specimens suggesting the presence of epidermal growth factor receptors on thymoma TE cells (Table 3).

Phenotypic Characterization of the Lymphoid Component of Thymoma

The lymphoid component of the thymomas was tested for reactivity with a monoclonal antibody panel directed against T cell differentiation antigens. The results are summarized in Table 4.

In frozen tissue section, the lymphoid component of thymomas was composed of T cells and was strongly reactive with monoclonal antibodies 35.1 (CD2) and 3A1 (CD7), as others have reported.³¹⁻³³ In six of nine the lymphoid component had the phenotype of cortical thymocytes, with 75% of lymphocytes strongly T6+ (CD1) and p80- (CD44) (Figure 5A). When present, p80+ cells were rare and existed in small clusters or as single cells. WT31 is an alternative marker to p80 for determining T lymphocyte maturity and was negative in the one case tested from this group with the cortical thymocyte phenotype (Figure 5E). There was no evidence of thymocyte corticomedullary organization. Thymocytes in single cell suspension were available for indirect immunofluorescence

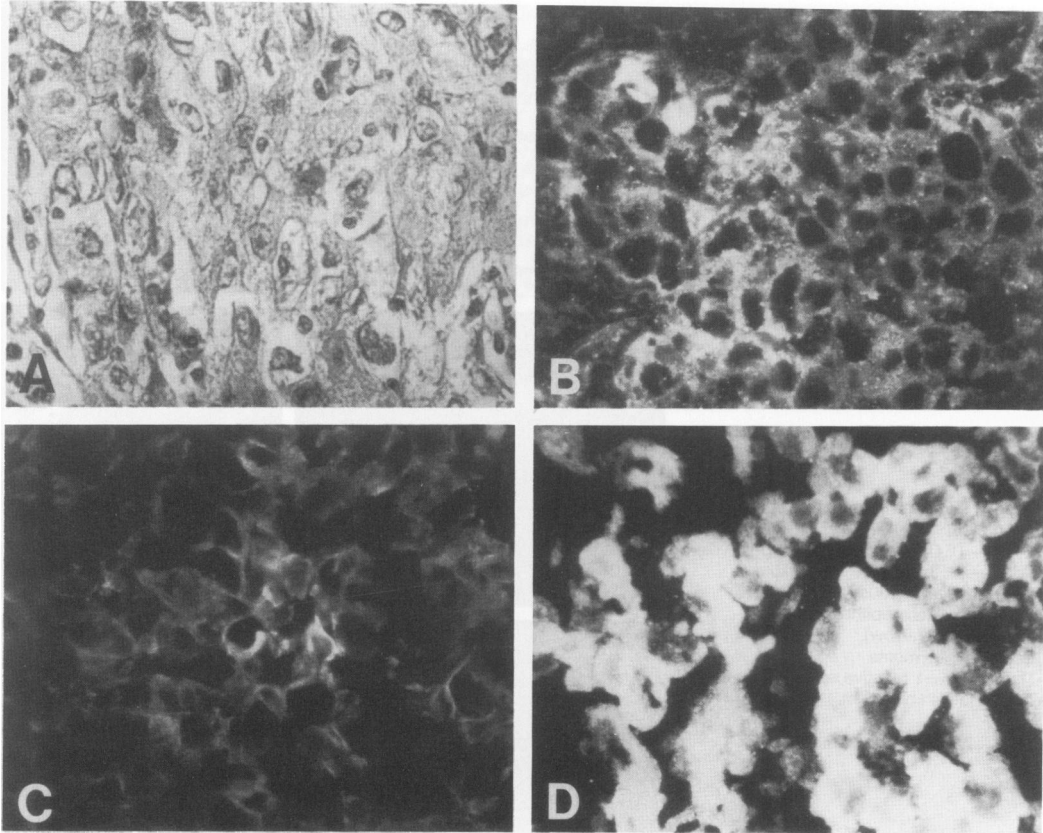


Figure 4—Phenotype of thymoma of mature epithelial type (patient no. 9). **A**—H & E-stained light micrograph showing mature epithelium with a squamous appearance. **B**—Representative view of one TE4 reactive area of epithelium. **C**—AE1 reactive thymoma epithelium. **D**—TE8 strongly reactive thymoma epithelium with dense-staining pattern. $\times 400$

analysis from three thymomas. Results confirmed the presence of immature T cell phenotype with greater than 90% of cells positive for NA1/34 (T6, CD1) (See Table 5). Interestingly, 21% of number 5 thymocytes coexpressed T6 (CD1) and p80 (CD44) antigens, whereas these antigens normally are expressed reciprocally on thymocytes.¹²

In contrast, the lymphoid component of the one thymoma (no. 9) that expressed the mature epithelial phenotype (TE4+, TE8+) was that of mature T cells, T6- (CD1), p80+ (CD44), WT31+ (Ti $\alpha\beta$) (Figures 5B, 5F). Two thymomas in the immature epithelial cell predominant group (nos. 7 and 8) showed a striking predominance of T6+ (CD1), S100+ large dendritic cells (Figures 6B and C) in a background of mature medullary thymocytes (T6-, p80+) (Figure 6E). In contrast, normal thymic medulla contains rare T6+ dendritic cells (Figure 6F). No corticomedullary organization was evident. Electron microscopy of thymoma no. 8 revealed Birbeck granules in the cytoplasm of the dendritic cells identifying them as Langerhans cells (Figure 6D).

Discussion

This study used a panel of monoclonal antibodies that define stages of thymic epithelial cell maturation

to compare the phenotype of thymic epithelium of nine thymomas with that of epithelium in MG and normal thymus. Hyperplastic MG thymic epithelium was similar to normal thymic epithelium in the expression of markers of early and late stages of thymic epithelial maturation. In contrast, the epithelial component of primary mediastinal thymomas exhibited marked phenotypic abnormalities compared with normal and MG thymuses.

In histologic sections of hyperplastic MG thymuses there was evidence of corticomedullary organization with the principle finding of an expanded medulla. The markers of neuroendocrine epithelium, TE4 and A2B5, were present in the subcapsular cortex as well as medulla. Additionally, all TE4+ cells were 12/1-2+. Formed TE8 and TE15-reactive Hassall's bodies were present in the medulla.^{27,28}

In contrast to normal and MG thymuses, the thymomas studied showed lymphoid and epithelial components diffusely admixed in varying proportions. Like normal and MG thymuses, all thymomas contained A2B5+/TE4+ thymic epithelium, but unlike normal thymus, the TE4+ epithelium was homogeneously distributed throughout the thymoma tissue. The thymomas also contained thy-

Table 4—Phenotype of Lymphoid Component of Thymoma Tissue

Antibody	Lymphocyte predominance		Mixed population lymphocytes & epithelial		Immature epithelial cell				Mature epithelial cell
	1	2	3	4	5	6	7*	8*	9
Patient no.									
T6 (CD1)	+	+	+	+	+	+	-	-	-
p80	-	±	-	-	±†	-	+	+	+
35.1 (CD2)	+	+	+	+	+	+	+	+	+
3A1 (CD7)	+	+	+	+	+	+	+	+	+
Leu 2a (CD8)	±	+	+	+	+	±	+	±	±
Leu 3a (CD4)	+	+	+	+	+	+	±	±	±
BA1	-	-	-	-	-	-	+	-	+

* Thymomas with abundant S100+, T6+ Langerhans cells.

† While 31% of thymocytes in suspension were p80+, 90% were also T6+ and 21% were both T6+ and p80+ (see Table 5). Normal thymocytes reciprocally express the T6 and p80 antigens.²⁵

+, >75% cells.

±, >25% <50% cells.

-, <25% cells.

mosin α 1, in agreement with the findings of others.³⁴ As reported previously by others,^{31,35} only a subset of thymic epithelial cells were 12/1 - 2+. Because all thymoma patients were adults, the lack of

reactivity of thymoma endocrine epithelium with antibody 12/1 - 2 suggested a phenotypic similarity of thymoma epithelium with fetal or neonatal TE4+, 12/1 - 2- thymic epithelium.^{2,30} Another

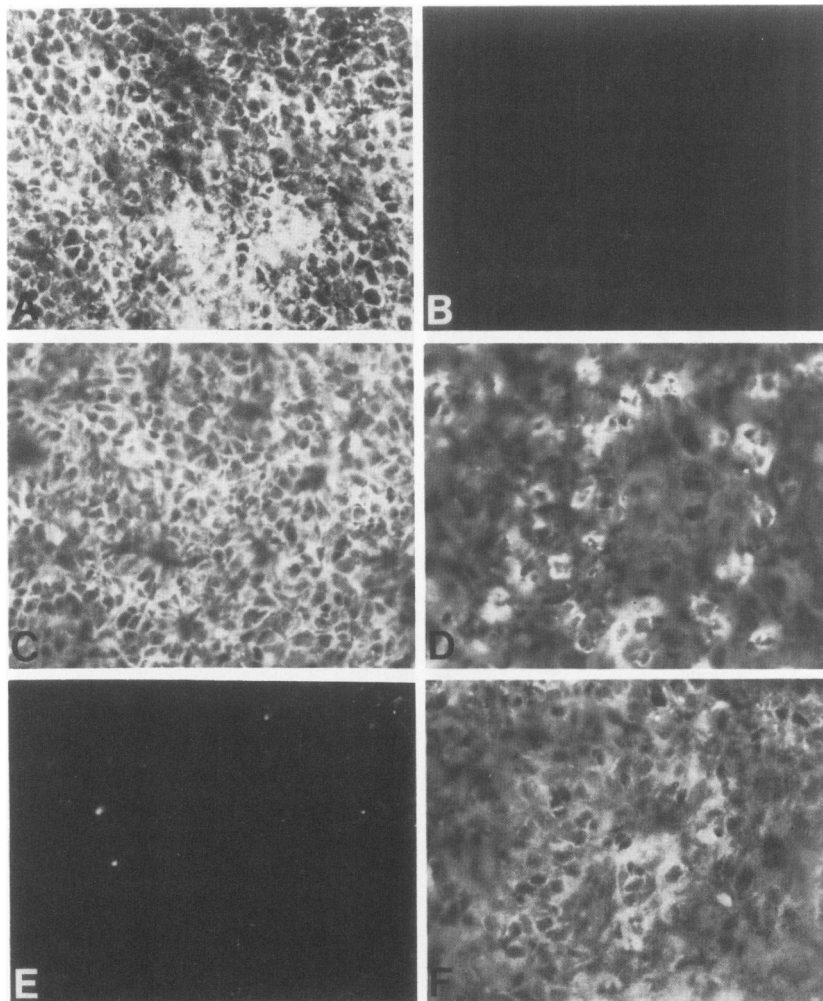


Figure 5—Phenotypic characterization of the lymphoid component of immature epithelial thymoma (patient no. 6, A, C, E) and mature epithelial thymoma (patient no. 9, B, D, F). Whereas there are NA1/34 CD1+ (T6) reactive thymocytes in thymoma of immature epithelial phenotype (A), thymocytes are CD1- (T6-) in thymoma of mature epithelial phenotype (panel B). 3A1, CD7+ reactive thymocytes in both thymoma of (C) immature and (D) mature epithelial phenotype. Panel E shows WT31 (T cell receptor α , β) nonreactive thymocytes in thymoma of immature epithelial phenotype whereas panel F shows weakly positive WT31 reactivity in thymocytes of mature epithelial phenotype thymoma. $\times 400$

Table 5—Phenotypic Characterization of Thymoma Lymphocytes in Single Cell Suspension*

Monoclonal antibody	Patient no.		
	3	5	6
	% Positive cells		
P3 (control antibody)	—	—	—
3A1 (Pan T) (CD7)	95	93	88
Leu 2a (T8) (CD8)	78	88	86
Leu 3a (T4) (CD4)	90	96	76
p80 (medullary thymocyte) (CD43)	9	31	6
35.1 (E-rosette receptor) (CD2)	100	96	73
NA1.34 (T6 cortical thymocyte) (CD1)	91	90	92
BA1 (B cell)	2	—	—
A2B5	1	—	—
12/1 - 2	2	—	—
TE4	7	—	—

* Assay for reactivity of monoclonal antibodies performed by indirect immunofluorescence as described in Methods. Reactivity of thymocyte suspensions with antibodies A2B5, 12/1 - 2, and TE4 ranged from 0 to 7% of cells positive.

fetal antigen, carcinoembryonic antigen, has been detected in thymomatous epithelial cells.³⁵ These observations suggest but do not prove that in some thymomas the thymic epithelium is either immature or dedifferentiated.

Further evidence to support the theory that thymic epithelium in thymomas is either immature or de-

differentiated comes from the phenotypic similarities between thymoma and severe cellular immunodeficiency disease (SCID). In similar studies of five thymomas, Haynes et al found SCID thymic epithelium to be TE4+, 12/1 - 2 negative or minimally reactive and TE8 and TE15 negative.²

As has been noted previously,^{2,3,28,36} the lymphoid component of thymoma was predominately that of immature cortical thymocytes (T6+, p80-). In this study, mature p80+ thymocytes were rare, suggesting that T cell maturation may be arrested in certain thymomas at the cortical thymocyte stage.

Two thymomas in the immature epithelial cell predominant group (nos. 7 and 8) contained abundant S100+, T6+ Langerhans cells among mature medullary thymocytes. S100+, lysozyme negative cells first appear in the thymic medulla by 3 months fetal gestation.³⁷ These cells are dendritic in shape and are a normal but rare component of the postnatal thymic medulla and corticomedullary junction.^{38,39} Generally referred to as interdigitating cells (IDCs) in thymus, they are thought to be closely related if not identical to the Langerhans cells in skin.⁴⁰

Histiocytosis X is a proliferative disorder of Langerhans cells.⁴¹ Four children have been reported with

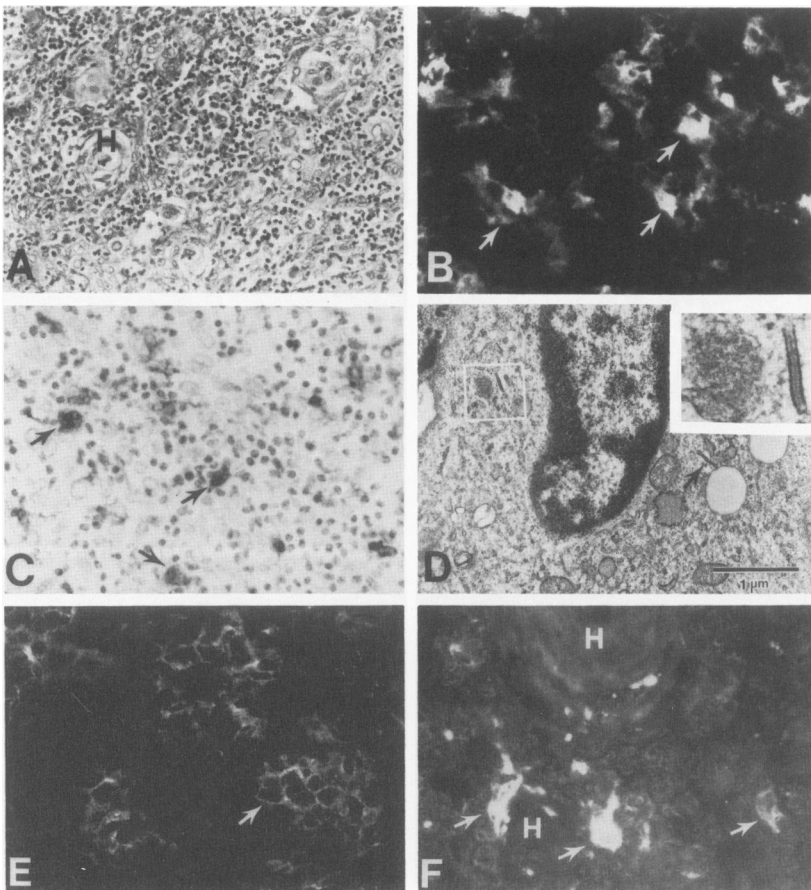


Figure 6—Phenotype of thymoma with immature epithelial cell predominance and abundant Langerhans cells. **A**—H & E-stained light micrograph showing Hassall's body (H). $\times 250$ **B**—NA1/34 (T6) reactive nonlymphoid cells in stellate pattern (arrows). $\times 400$ **C**—S100 protein immunoperoxidase stain showing numerous S100+ reactive cells (arrows). $\times 100$ **D**—Electron micrograph ($\times 17,000$) of a Langerhans cell containing two Birbeck granules at arrow and inset ($\times 70,000$). Scale bar equals 1μ . **E**—p80 reactive thymocytes in honeycomb lymphocyte pattern. $\times 400$ **F**—Normal thymic medulla with Hassall's bodies (H) reacted with NA1/34 (T6) and demonstrating positively staining stellate cells representing the normal location of Langerhans cells in thymus (arrows).

Histiocytosis X restricted to the thymus.⁴² Abundant S100+, Birbeck granules containing Langerhans cells were noted in the thymus of one adult patient with myasthenia gravis.⁴³ A spectrum of thymic abnormalities are found in Histiocytosis X ranging from thymic dysplasia with variable numbers of infiltrating Langerhans cell to thymic involution.^{44,45} Whether the presence of Langerhans cells in these two thymomas actually represented isolated Histiocytosis X of the thymus, or a reactive process secondary to the thymoma is unknown. Neither patient no. 7 nor 8 had developed evidence of systemic Histiocytosis X at 41 and 24 months follow-up respectively.

The appearance of S100+ IDCs has been noted previously in thymoma; their occurrence usually has been in areas of thymic medullary differentiation.^{31,32,46,47} In one study, S100+ IDCs were present in nine of 20 thymomas.⁴⁶ No correlation existed between the presence of IDCs in the thymomas and associated immunologic syndromes.

The epithelial component of one thymoma (patient 9, Table 3) had a phenotype (weak TE4+, strong TE8+) suggestive of more differentiated epithelium than that of other thymomas. Interestingly, the thymoma of patient 9 had a different histology than the other thymomas with mature epithelial cells predominating (Figure 4).

Thus, it has been demonstrated there are abnormalities of thymic epithelial antigen expression in thymomas. In six of nine thymomas studied, the epithelial component is either arrested or dedifferentiated with phenotypic similarities to that of 14 to 16 week fetal thymus; these data suggest a primary abnormality of epithelium in most thymomas. This panel of reagents¹⁹ should prove useful in the histologic evaluation of mediastinal masses. Limited amounts of these reagents are available on request.

Reference

1. Stutman O: Intrathymic and extrathymic T-cell maturation. *Immunol Rev* 1978, 42:138-184
2. Haynes BF: The human thymic microenvironment. *Adv Immunol* 1984, 36:87-142
3. Levine G, Bensch K: Epithelial nature of spindle-cell thymoma: An ultrastructural study. *Cancer* 1972, 30:500-511
4. Levine G, Rosai J: Thymic hyperplasia and neoplasia: A review of current concepts. *Hum Pathol* 1978, 9:495-515
5. Haynes BF, Scarce RM, Lobach DF, Hensley LL: Phenotypic characterization and ontogeny of mesodermally derived and endocrine epithelial components of the human thymic microenvironment. *J Exp Med* 1984, 159:1149-1168
6. Lobach DF, Scarce RM, Haynes BF: The human thymic microenvironment: Phenotypic characterization of Hassall's bodies with the use of monoclonal antibodies. *J Immunol* 1985, 134:250-257
7. Rosai J, Levine GD: Tumors of the thymus. *Atlas of Tumor Pathology*. Armed Forces Institute of Pathology, Washington, DC, 1976
8. Haynes BF, Metzgar RS, Minna JD, Bunn PA: Phenotypic characterization of cutaneous T-cell lymphoma. *New Engl J Med* 1981, 304:1319-1323
9. Haynes BF, Hensley LL, Jegasothy BV: Differentiation of human T lymphocytes. II. Phenotypic difference in skin and blood malignant T-cells in cutaneous T-cell lymphoma. *J Invest Dermatol* 1982, 78:323-326
10. Martin PJ, Longton G, Ledbetter JA, Newmann W, Braun MP, Beatty PA, Hansen JA: Identification and functional characterization of two distinct epitopes on the human T cell surface protein TP50. *J Immunol* 1983, 131:180-185
11. Haynes BF, Eisenbarth GS, Fauci AS: Human lymphocyte antigens: Production of a monoclonal antibody that defines functional thymus-derived lymphocyte subsets. *Proc Natl Acad Sci USA* 1979, 76:5829-5833
12. Haynes BF, Harden EA, Telen MJ, Hemler ME, Strominger JL, Palker TJ, Scarce RM, Eisenbarth GS: Differentiation of human T lymphocytes. I. Acquisition of a novel human cell surface protein (p80) during normal intrathymic T cell maturation. *J Immunol* 1983, 131:1195-1200
13. McMichael AJ, Pilch JR, Galfre G, Mason DY, Fabre JW, Milstein C: A human thymocyte antigen defined by a hybrid myeloma monoclonal antibody. *Eur J Immunol* 1979, 9:205-210
14. Ledbetter JA, Frankel AE, Herzenberg LA, Herzenberg LA: Human Leu T-cell differentiation antigens: Quantitative expression on normal lymphoid cells and cell lines, *Monoclonal Antibodies and T-Cell Hybridomas*. Edited by G Hammerling, U Hammerling, J Kearney. New York, Elsevier North-Holland, 1981, pp 16-22
15. Spits H, Borst J, Tax W, Capel PJA, Terhorst C, deVries J: Characteristics of a monoclonal antibody (WT31) that recognizes a common epitope on the human T cell receptor for antigen. *J Immunol* 1985, 135:1922-1928
16. Abramson CS, Kersey JH, LeBien TW: A monoclonal antibody (BA-1) reactive with cells of human B lymphocyte lineage. *J Immunol* 1981, 126:83-88
17. Takahashi K, Isobe T, Ohtsuki Y, Sonobe H, Takeda I, Akagi T: Immunohistochemical localization and distribution of S100 proteins in the human lymphoreticular system. *Am J Pathol* 1984, 116:497-503
18. Eisenbarth GS, Shimizu K, Conn M, Mittler R, Wells S: Monoclonal antibody F12 A2B5: reaction with a plasma membrane antigen of vertebrate neurons and peptide-secreting endocrine cells, *Monoclonal Antibodies to Neural Antigens*. Cold Spring Harbor Harbor Reports in the Neurosciences, 1981, pp 209-218
19. Haynes BF, Crummett B, Scarce RM, Wolf LS, Tuck DT, Singer KH: Summary of reactivity patterns of the thymic epithelial panel of antibodies in skin and thymus, *Leukocyte Typing III: White Cell Differentiation Antigens*. Edited by AJ McMichael, Oxford, England, Oxford Univ Press 1987, pp 252-269
20. Haynes BF, Robert-Guroff M, Metzgar RS, Franchini G, Kalyanaraman VS, Palker TJ, Gallo RC: Monoclonal antibody against human T cell leukemia virus p19 defines a human thymic epithelial antigen acquired during ontogeny. *J Exp Med* 1983, 157:907-920

21. McFarland EJ, Scearce RM, Haynes BF: The hyman thymic microenvironment: Cortical thymic epithelium is an antigenically distinct region of the thymic microenvironment. *J Immunol* 1984, 133:1241-1249
22. Laster AJ, Itoh T, Palker TJ, Haynes BF: The human thymic microenvironment: Thymic epithelium contains specific keratins associated with early and late stages of epidermal keratinocyte maturation. *Differentiation* 1986, 31:67-77
23. Lobach DF, Itoh T, Singer KH, Haynes BF: The thymic microenvironment: Characterization of *in vitro* differentiation of the IT26R21 rat thymic epithelial cell line. *Differentiation* 1987, 34:50-59
24. Haynes BF: The role of the thymic microenvironment in promotion of early stages of human T cell maturation. *Clin Res* 1986, 34:422-431
25. Woodcook-Mitchell J, Eichner R, Nelson WG, Sun T-T: Immunolocalization of keratin polypeptides in human epidermis using monoclonal antibodies. *J Cell Biol* 1982, 95:580-588
26. Goodfellow P, Solomon E: Monoclonal antibodies and human gene mapping by somatic cell genetics, *Monoclonal Antibodies in Clinical Medicine*. Edited by AJ McMichael and JW Fabre. London, Academic Press, 1982, pp 365-393
27. Harden EA, Haynes BF: Peripheral T cell circulatory kinetics and intrathymic T-cell differentiation in myasthenia gravis, *Monoclonal Antibodies, Probes for the Study of Autoimmunity and Immunodeficiency*. Edited by BF Haynes and GS Eisenbarth. Orlando, Academic Press, 1983, pp 297-313
28. Telen MJ, Shehata HM, Haynes BF: Human medullary thymocyte p80 antigen and In(Lu)-related p80 antigen reside on the same protein. *Hum Immunol* 1986, 17: 311-324
29. Chilosi M, Iannucci A, Fiore-Donati L, Tridente G, Pampanin M, Pizzolo G, Ritter M, Bofill M, Janossy G: Myasthenia gravis: Immunohistological heterogeneity in microenvironmental organization of hyperplastic and neoplastic thymuses suggesting different mechanisms of tolerance breakdown. *J Neuroimmunol* 1986, 11:191-204
30. Lobach DF, Haynes BF: Ontogeny of the human thymus during fetal development. *J Clin Immunol* 1987, 7:81-97
31. Mokhtar N, Hsu S, Lad R, Haynes BF, Jaffe E: Thymoma: Lymphoid and epithelial components mirror the phenotype of normal thymus. *Human Pathol* 1984, 15:378-384
32. Kornstein MJ, Hoxie JA, Levinson AL, Brooks JJ: Immunohistology of human thymomas. *Arch Pathol Lab Med* 1985, 109:460-463
33. Eimoto T, Teshima K, Shirakusa T, Takeshita M, Okamura H, Naito H, Mitsui T, Kikuchi M: Heterogeneity of epithelial cells and reactive components in thymomas: an ultrastructural and immunohistochemical study. *Ultrastruct Path* 1986, 10:157-173
34. Savino W, Dardenne M: Thymic hormone-containing cells. VI. Immunohistologic evidence for the simultaneous presence of thymulin, thymopoietin and thymosin α 1, in normal and pathological human thymuses. *Eur J Immunol* 1984, 14:987-991
35. Savino W, Durand D, Dardenne M: Immunohistochemical evidence for the expression of the carcinoembryonic antigen by human thymic epithelial cells *in vitro* and in neoplastic conditions. *Am J Pathol* 1985, 121:418-425
36. Takacs L, Savino W, Monostori E, Ando I, Bach J-F, Dardenne M: Cortical thymocyte differentiation in thymomas: An immunohistologic analysis of the pathologic microenvironment. *J Immunol* 1987, 138:687-698
37. Watanabe S, Nakajima T, Shimosato Y, Shimamura K, Sakuma H: T-zone histiocytes with S100 protein, development and distribution in human fetuses. *Acta Pathol Jpn* 1983, 33:15-22
38. Pelletier M, Tautu C, Landry D, Montplaisir S, Chartrand C, Perreault C: Characterization of human thymic dendritic cells in culture. *Immunology* 1986, 58:263-270
39. Chilosi M, Menestrina F, Iannucci AM, Fiore-Donati L, Pizzolo G, Janossy G: Immunohistochemical analysis of thymoma: Evidence for medullary origin of epithelial cells. *Am J Surg Pathol* 1984, 8:309-318
40. Thorbecke GJ, Silberberg-Sinakin I, Flotte TJ: Langerhans cells as macrophages in skin and lymphoid organs. *J Invest Dermatol* 1980, 75:32-43
41. Beckstead JH, Wood GS, Turner RR: Histiocytosis X cells and Langerhans cells: Enzyme histochemical and immunologic similarities. *Hum Pathol* 1984, 15:826-833
42. Siegal GP, Dehner LP, Rosai J: Histiocytosis X (Langerhans' cell granulomatosis) of the thymus. *Am J Surg Pathol* 1985, 9:117-124
43. Bramwell NH, Burns BF: Histiocytosis X of the thymus in association with myasthenia gravis. *Am J Clin Pathol* 1986, 86:224-227
44. Hamoudi AB, Newton WA, Mancier K, Penn GM: Thymic changes in Histiocytosis. *Am J Clin Pathol* 1982, 77:169-173
45. Favara BE, McCarthy RC, Mierau GW: Histiocytosis X. *Hum Pathol* 1983, 14:663-676
46. Lauriola L, Michetti F, Stolfi VM, Tallini G, Cocchia D: Detection by S100 immunolabelling of interdigitating reticulum cells in human thymomas. *Virchows Archiv B* 1984, 45:187-195
47. Muller-Hermelink HK, Marino M, Palestro G: Pathology of thymic epithelial tumors. *Curent Topics in Pathology* 1986, 75:207-268

Acknowledgment

The authors thank Ms. Kim R. McClammy and Ms. Joyce W. Lowery for their expert secretarial assistance.