



An infected prosthetic hip

Is there a role for prophylactic antibiotics?

Infection of a prosthetic joint is associated with serious morbidity, can result in prolonged admission to hospital, and is potentially life threatening. Our case illustrates these problems, and the arguments for and against the use of prophylactic antibiotics in prevention of these infections are discussed.

Case history

A 67 year old woman had congenital dislocation of the hip diagnosed at the age of 1 year. In 1976 she had a right total hip replacement and in 1980 a left total hip replacement, both for osteoarthritis. In 1985 a revision of the left hip prosthesis for aseptic loosening was performed with a good result. She remained well until July 1990 when she was seen by her orthopaedic surgeon after complaining of increasing discomfort in the right hip. Radiography of the hip showed appreciable wear of the socket, but there was no evidence of infection and her erythrocyte sedimentation rate was normal at 7 mm in the first hour. In August 1990 she had an infected wisdom tooth removed and in November she had a molar tooth stump extracted. She became unwell in December with malaise, lethargy, sore throat, and fever. Her general practitioner prescribed three separate courses of antibiotics over the next few weeks but she remained unwell with intermittent fevers and night sweats. In March 1991 she developed severe pain in her right hip. A radiograph of the right hip appeared consistent with infection of the hip prosthesis. This was supported by a raised erythrocyte sedimentation rate of 70 mm in the first hour and a fall in haemoglobin concentration to 95 g/l. An open biopsy of the right femur was performed. Bacterial cultures of both the femoral window swab and the femoral biopsy specimen grew *Streptococcus mitis*, an organism in the viridans streptococcus group. She was admitted to the Hammersmith Hospital for treatment.

On admission she complained of severe pain in her right hip but was otherwise well. She had been treated for tuberculous peritonitis at age 7 but had no other relevant medical history. On examination she was afebrile, clinically anaemic, and had no lymphadenopathy. She had a pulse rate of 80 per minute, and her blood pressure was 150/90 mm Hg. She had normal heart sounds with no cardiac murmurs. There was pitting oedema at the right ankle. Her jugular venous pressure was not raised and she had no evidence of heart failure. Neither her liver nor spleen was palpable. She had a clean sutured operation scar on the right thigh, which was swollen and non-tender. Movements of the right hip were reduced in all directions by pain, the left hip had a good range of movement, and she was able to walk with the aid of crutches.

Investigations showed a normochromic, normocytic anaemia with a haemoglobin concentration of 90 g/l. The peripheral blood leucocyte count was normal at $5.4 \times 10^9/l$. She had a raised platelet count ($533 \times 10^9/l$) and erythrocyte sedimentation rate (75 mm in the first hour). Her C reactive protein concentration was 117 mg/l (normal <10 mg/l). A biochemical profile was normal and random glucose concentration 5.2 mmol/l. Repeated blood cultures and a midstream urine culture were sterile. Radiography of her hips showed a normal

prosthesis on the left, but on the right there were areas of lucency around the hip shaft with associated new bone formation, consistent with infection (figure).

Treatment was started with intravenous benzylpenicillin 2 MU six hourly and subcutaneous heparin. She had daily physiotherapy to her hips. The pain in her hip resolved within 48 hours. Her C reactive protein concentration fell to 13 mg/l on day 12 after admission and her erythrocyte sedimentation rate to 41 mm in the first hour. Her platelet count also fell to within the normal range and the white cell count remained normal. After two weeks' intravenous benzylpenicillin treatment was changed to oral phenoxymethylpenicillin and the acute phase reactants remained stable. She was discharged to be readmitted two weeks later for removal of the infected prosthesis, followed by six weeks of traction. It was planned that she would have bone grafting of the acetabulum and proximal femoral head six months later followed by implantation of another prosthesis.

Comment

In 1988 Maderazo *et al* suggested that the annual incidence of late infection of joint prostheses was 0.6%.¹ These infections are potentially life threatening, have a high associated morbidity, and require prolonged admission to hospital. The route of infection is by haematogenous spread. An animal model has been described, in which *Staphylococcus aureus* was injected into rabbits with prosthetic knee joints and one third subsequently developed joint infections.² A review of 43 previously described cases identified the source of infection as skin in 46%, dental in 15%, urinary tract in 13%, respiratory tract in 10%, and gastrointestinal tract in 2%; in 14% the source of infection was unclear.¹ Staphylococci are the commonest infecting organisms, accounting for about 60% of the infections, with streptococci causing 20%. Numerous other organisms have been implicated, including Gram negative bacilli and anaerobes (table). There are only three previously reported cases of infection of prosthetic joints with viridans streptococci.⁴

It is important to consider the predisposing factors to these infections. These include patients who are medically compromised, such as those with rheumatoid arthritis and diabetes mellitus and immunosup-

Bacteriology of prosthetic joint infections

Organism	Incidence (%)	
	Inman <i>et al</i> ¹ (63 patients)	Maderazo <i>et al</i> ¹ (64 patients)
Staphylococci	59	55
<i>S epidermidis</i>	40	
<i>S aureus</i>	19	
Streptococci	20	15
Group A	5	
Group B	6	
<i>S faecalis</i>	8	
Gram negative bacteria	10	26
<i>Escherichia coli</i>	3	
<i>Pseudomonas sp</i>	2	
Anaerobes	10	8
<i>Peptococcus sp</i>	2	
<i>Bacteroides fragilis</i>	2	

Department of Medicine,
Hammersmith Hospital,
London W12 0NN

Case presented by:

J C Mason, *medical registrar*
Chairman: C T Dollery,
professor of medicine

Discussion group: A So,
senior lecturer, rheumatology
unit

J Cohen, *reader in infectious*
diseases

S R Bloom, *professor of*
endocrinology

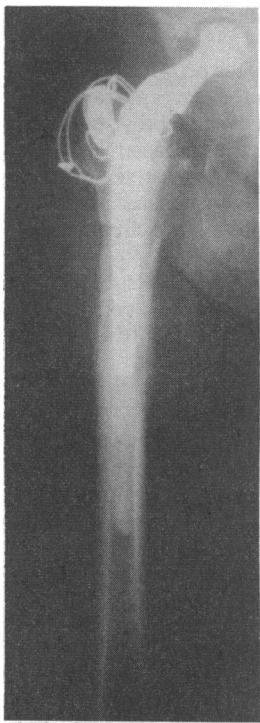
C Bulpitt, *professor of*
geriatrics

R Russell-Jones, *senior*
lecturer, dermatology unit

C M Oakley, *consultant*
cardiologist

Series edited by:
Dr Stephen Gilbey.

BMJ 1992;305:300-2



Radiograph of right femur showing local bone destruction on lateral aspect of upper femur, lucent areas around hip shaft, and periosteal new bone formation

pressed patients. The polymethylmethacrylate cement used in joint replacement surgery has been implicated in prosthetic joint infections and has been shown to inhibit macrophage function in vitro by impairing the phagocytosis of *Candida albicans*.^{5,6} In addition, certain bacteria are able to produce a fibrous exopolysaccharide material (glycocalyx), which helps to protect bacteria from the local immune response and concentrates nutrients within the matrix so predisposing to infection.⁴

TREATMENT OF INFECTED JOINT PROSTHESES

The definitive treatment of infected joint prostheses requires removal of the prosthesis. Drainage and antibiotics alone give only a 20% success rate and may compromise future surgery.⁷ Three different types of surgical approach are commonly used. In the one stage exchange arthroplasty the infected prosthesis is removed and a new prosthesis implanted with gentamicin impregnated cement. Initial results are good with a 91% success rate reported at two years in 62 patients, but in a group of 825 patients 30% had relapsed at six years and 50% at 11 years after surgery.⁷ The two stage arthroplasty requires removal of the prosthesis and cement, with debridement of infected tissue, followed by a three to six week course of intravenous antibiotics. Reimplantation is carried out 3-12 months later depending on the virulence of the infecting organism. This two stage arthroplasty gave a 97% success rate in 44 patients⁷ and a 93% success rate in 80 patients followed for two years.⁵ Recently, a three stage procedure has been developed in which removal of the prosthesis and cement followed by four weeks of intravenous antibiotics is the first stage. The second stage uses bone grafting of the acetabulum and the proximal femur 3-12 months later. Finally, once the bone graft has matured, a replacement prosthesis is inserted.

CONTROVERSY OVER PROPHYLAXIS

The role of prophylactic antibiotics in preventing prosthetic joint infections remains controversial. In a survey of 604 American orthopaedic surgeons, 93% thought that antibiotic prophylaxis was indicated.⁸ In contrast, dental authors have concluded that transient bacteraemia is unlikely to produce infection, that the risk of antibiotic prophylaxis outweighs the advantages, and there is a considerable prescribing cost.^{4,9,10} The incidence of infection from a dental source was estimated as 0.07% by Maderazo *et al*¹ and 0.04% by Little.¹⁰ In a prospective study of 1000 patients with 1112 prosthetic joints followed up for six years, 224 patients had dental or surgical procedures without prophylactic antibiotic cover and only three had subsequent joint infections due to haematogenous spread.¹¹

The risk of a fatal reaction from oral penicillin and cephalosporins is low and has been quoted as 1-2 per 100 000 patients,¹ and 4.25-9.0 per 10⁷ courses.⁹ These figures must be compared with the mortality from late infections of prosthetic joints. This has been estimated as 4-18%¹² and 18%.¹⁰ From these figures the estimated mortality from late infection of prosthetic joints from a dental source is 2-13/100 000 patients. An alternative figure of 39 deaths per million patient years at risk has recently been quoted.¹³ Conclusions from the available data regarding the relative risks of antibiotic prophylaxis and anaphylaxis vary considerably. Two recent reviews suggest that there is insufficient evidence to support the routine use of antibiotic prophylaxis for dental treatment and recommend prophylaxis for high risk groups, such as those with rheumatoid arthritis or immunocompromised patients,^{4,13} while another recommended prophylactic phenoxymethyl-

penicillin or erythromycin in all patients until conclusive data are available.¹⁴ Large multicentre prospective trials are needed to answer this question, which is becoming increasingly important as the number of patients with prosthetic joints increases.

Discussion

AS: This patient developed a very rare but well recognised complication of her hip replacement in that it became infected. When we saw her we were persuaded by the sequence of events and the bacteriology that a dental source was the likely cause of the infection. We presented the case because when we first saw her and reviewed the literature on the role of prophylactic antibiotics in patients with prosthetic joints there seemed to be a divergence of opinion between some orthopaedic surgeons and dentists. Based on the figures presented, giving routine antibiotic prophylaxis to all patients with prosthetic joints who undergo a dental procedure will result in about the same number of deaths as that caused by infection of the prosthetic joint. In immunocompromised patients, especially rheumatoid patients taking systemic steroids, and in those with multiple joint replacements, I think there is a clear role for antibiotic prophylaxis. The dilemma then is what is the appropriate antibiotic prophylaxis to use? If the patient is having a dental procedure penicillin type antibiotics would be appropriate, but these patients are also open to infection if they have catheterisation procedures and other invasive procedures. We must consider what is the most likely organism of infection given the medical procedure that is to be performed, in order to give appropriate prophylactic treatment.

CTD: I am not sure that I accept the framework of the discussion. If a patient who has a valve prosthesis or a hip prosthesis is having a procedure on infected tissues, whether it is a bladder catheterisation, skin sepsis, or a dental procedure, you should give them antibiotic prophylaxis. Jon Cohen you are the expert, do you agree with that?

JC: I think it is a very difficult problem and one which occurs with increasing frequency as more patients have prosthetic devices fitted. Firstly, there are few situations where there are hard data to guide us and to some extent we have to be pragmatic about it. Secondly, there is clearly a trade off, in that you could argue that any patient with a prosthetic device who is undergoing any one of a range of procedures, whether it is urethral catheterisation, endoscopy, or prostatic biopsy, is at risk of bacteraemia and so of colonising the prosthesis. However, it is simply not practicable or probably desirable that every one of those patients should receive prophylaxis. In many situations it is probably inappropriate to use prophylaxis because, as you have shown, the risks outweigh the benefits. I acknowledge that it is difficult to make a logical, rational, or scientific argument because we are often short of data.

COST AND EFFECTIVENESS

CTD: You seem to all be very British and very negative about it. The consequences of developing an infected hip are horrendous. This patient is going to be in bed or virtually bedridden for months. If she ever gets back on her feet again that will be a minor miracle. So if there is a reasonable prospect of preventing some of these infections prophylaxis should be given—penicillin costs only pennies and the cost of caring for this patient will be £50 000-£60 000.

JC: Cost alone is not the issue; what one must weigh in the balance first of all is whether prophylaxis is going to be effective. As I am sure Celia Oakley will attest, failure of prophylaxis given for endocarditis is well

known. So we should not start from the premise that prophylaxis is inevitably going to be successful.

CTD: I am not starting from that premise.

JC: No, but that is one premise that we may start from and can lead us in the wrong direction. Secondly, we see cases like this one on the staff round, and it is appropriate that we do, but we do not see the 2-4 patients per 100 000 who die of penicillin induced anaphylaxis. It is a difficult balance to draw.

CTD: Is it true that patients who receive antibiotic prophylaxis with oral rather than parenteral penicillin are unlikely to develop fatal anaphylaxis?

JC: It is certainly much less likely, but it can occur and there are going to be patients who have an acute hypersensitivity reaction.

SRB: The problem as I see it, is the tremendous loss of quality of life that this patient now suffers with a three stage procedure. I wondered what the justification for that was, albeit that the approach is the most likely to be 100% successful. The 90% success rate with the gentamicin impregnated cement might be worth while from that viewpoint.

JCM: The orthopaedic surgeon looking after her thought carefully about what should be done. He decided that bone grafting was required to reconstruct the hip and that the three stage procedure was therefore indicated.

CB: I have not got a feel for the size of the problem. One of the pieces of data that you mentioned was the 0.6% incidence of infection from any site. Was that per annum? In which case that is a very high incidence and after 10 years would be 6% and greater if you had two prosthetic hips, or was the incidence over 10 or 20 years?

JCM: It was an annual incidence in 1983 from Hartford Hospital, Connecticut.¹ It was also noted that the incidence had risen from 0.08% in 1978 because of the increasing numbers of patients with prosthetic joints.

RR-J: Might hyperbaric oxygen help in these patients? Does Jon Cohen have any experience of that?

JC: No, I have not.

TAKING EACH CASE ON ITS MERITS

CMO: The British Society of Antimicrobial Chemotherapy working party on antibiotic prophylaxis considered this question recently with Professor Sean Hughes from this hospital as the orthopaedic representative. They considered dental prophylaxis, and came to the same conclusion—that the incidence of infection of joint prostheses is extremely low and that there is a better case for antibiotic prophylaxis in prostatic biopsies, gastrointestinal biopsies, and so on. Incidentally, most patients with prosthetic joints are elderly, excluding some of the rheumatoid patients, and these patients have a much higher incidence of endocarditis related to such events as prostatic biopsy.

CTD: Coming back to you again Jon Cohen, I am still not sure that I understand your argument. Are you saying that because there is not conclusive proof that prophylaxis is effective we should not use it?

JC: No, not at all. What I am saying is that we must

take each case on its merits and decide whether the balance is in favour or against. As Celia Oakley says, in the case of dental prophylaxis for prosthetic joints it is probably not routinely indicated. It seems to me very worth while to use prophylaxis for a prostatic biopsy because the incidence of spontaneous bacteraemia after this procedure is high, with Gram negative organisms and enterococci. It is difficult to make these judgments without taking into account the specific circumstances and the particular risks involved.

CTD: I hesitate to disagree with experts, but when I have my hip replacement, I think I shall take prophylaxis when someone is extracting one of my teeth.

Conclusion

The use of prophylactic antibiotics before surgery in patients with joint prostheses remains controversial. The dramatic consequences of an infected prosthetic joint are well illustrated by the case described and the arguments in favour of antibiotic prophylaxis highlight this. In contrast the arguments against routine prophylaxis conclude that the incidence of secondary infection of joint prostheses, particularly after dental treatment, is very low and that the risk of antibiotic prophylaxis and the costs entailed are not justified. Routine prophylaxis before dental treatment is probably not justified whereas prophylaxis should be given before procedures with a high risk of bacteraemia such as prostatic biopsy, genitourinary surgery, and surgery on infected tissue. Routine prophylaxis is also recommended for dental and other surgery in patients who are considered at high risk, including those with rheumatoid arthritis and diabetes mellitus, immunosuppressed patients, and those with previously re-operated prostheses. Large randomised prospective studies of the use of prophylactic antibiotics in patients with joint prostheses are still required.

- 1 Maderazo EG, Judson S, Pasternak H. Late infections of total joint prostheses: a review and recommendations for prevention. *Clin Orthop* 1988;229:131-42.
- 2 Blomgren G, Lindgren U. Late haematogenous infection in total joint replacement: studies of gentamicin and bone cement in the rabbit. *Clin Orthop* 1981;155:244-8.
- 3 Inman RD, Gallegos KV, Brause BD, Redecha PB, Christian CL. Clinical and microbial features of prosthetic joint infection. *Am J Med* 1984;77:47-53.
- 4 Thyne GM, Ferguson JW. Antibiotic prophylaxis during dental treatment in patients with prosthetic joints. *J Bone Joint Surg (Br)* 1991;73:191-4.
- 5 Brause BD. Prosthetic joint infections. *Clinics in Rheumatic Diseases* 1986;12:523-36.
- 6 Gristina AG, Kolkun J. Total joint replacement and sepsis. *J Bone Joint Surg (Am)* 1983;65:128-34.
- 7 Fitzgerald RH Jr. Problems associated with the infected total hip arthroplasty. *Clinics in Rheumatic Diseases* 1986;12:537-54.
- 8 Jaspers MT, Little JW. Prophylactic antibiotic coverage in patients with total arthroplasty: current practice. *J Am Dent Assoc* 1985;111:943-8.
- 9 Jacobson JJ, Schweiter S, De Porter DJ, Lee JJ. Chemoprophylaxis of dental patients with prosthetic joints: a simulation model. *J Dent Educ* 1988;52:599-604.
- 10 Little JW. Dental treatment of patients with joint replacements. *Oral Surg* 1983;55:20-3.
- 11 Ainscow DAP, Denham RA. The risk of haematogenous infection in total joint replacement. *J Bone Joint Surg (Br)* 1984;66:580-2.
- 12 Ahlberg Å, Carlsson ÅS, Lindberg L. Haematogenous infection in total joint replacement. *Clin Orthop* 1978;137:69-75.
- 13 Blackburn WD Jr, Alarcon GS. Prosthetic joint infections: a role for prophylaxis. *Arthritis Rheum* 1991;34:110-7.
- 14 Nelson JP, Fitzgerald RH, Jaspers MT, Little JM. Prophylactic antimicrobial coverage in arthroplasty patients. *J Bone Joint Surg (Am)* 1990;72:1.