

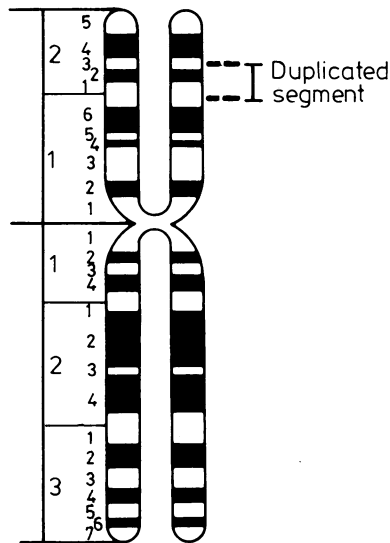FIG 2 Standard ideogram of chromosome 2, indicating the extent of the duplicated region.

### Discussion

Although about 200 cases with lung agenesis have been reported, there is no agreement on the aetiology of this malformation. Intrauterine infections, both bacterial and viral, and intrauterine injury have been proposed as possible causes of lung agenesis. It is of interest that agenesis of the lung has been induced in experimental animals by a diet deficient in vitamin A.<sup>5</sup>

Genetic factors are also thought to be responsible for some cases of pulmonary agenesis but, as mentioned above, familial cases are rare. However, many patients with this condition do not reach reproductive age, and therefore genetic aetiology may have been underestimated.

The existence of a chromosome abnormality in our patient, probably representing a duplication of a segment of chromosome 2, is of further genetic interest. It may be that this is a coincidental finding. We could find only one report in which chromosome studies had been carried out with normal results,<sup>6</sup> but no mention was made of whether or not banding was done. It is obvious that similar studies should be done in future cases.

Our patient had several of the clinical findings reported in patients with the duplication (2p) syndrome. These included facial features as well as long hyperextensible fingers and toes. The patient was the product of a term pregnancy and had a normal birthweight and length for gestation. An

excellent review of the patients with duplication (2p) syndrome has indicated the presence of skeletal abnormalities of the thorax such as extra or missing ribs and sternal malformations in a number of cases.<sup>4</sup> The relationship between these findings and possible defects in the underlying soft tissues is speculative at present.

We wish to thank Ms Sandy Quay and Ann Maltby for their technical assistance, and Drs Uta Francke and Robert W Miller for their help. This work was partially supported by a Medical Service Grant from the National Foundation—March of Dimes Tulsa Chapter.

BURHAN SAY, NANCY J CARPENTER,  
GEORGE GIACOIA, AND S JEGATHESAN  
*Genetics Unit, Children's Medical Center,  
Eastern Oklahoma Perinatal Center,  
St Francis Hospital; and Department of  
Pediatrics, University of Oklahoma,  
Tulsa Medical College, Tulsa, Oklahoma, USA*

### References

- 1 Neill CA, Ferencz C, Sabiston DC, *et al*. The familial occurrence of hypoplastic right lung with systemic arterial supply and venous drainage 'Scimitar syndrome'. *Johns Hopkins Med J* 1960;**107**:1-21.
- 2 Finkelstein H. Hypoplasie und agenesis der lunge. In: *Lehrbuch der Sauglings-kranheiten*. Berlin: Komfeld, 1908.
- 3 Yount F. Agenesis of right lung in each of identical twins. *Ariz Med* 1948;**5**:48-9.
- 4 Francke U. Clinical syndromes associated with partial duplications of chromosomes 2 and 3: dup (2p), dup (2q), dup (3p), dup (3q). *Birth Defects* 1978;**14**(6C): 191-217.
- 5 Wilson JG, Warkany J. Aortic arch and cardiac anomalies in the offspring of vitamin A deficient rats. *Am J Anat* 1949;**85**:113-55.
- 6 Dorchy H, Baran D, Richard J. Association of asymmetric crying facies, malformation of the ear and pulmonary agenesis. *Acta Paediatr Belg* 1976;**29**:255-6.

Requests for reprints to Dr Burhan Say, Genetics Unit, Children's Medical Center, PO Box 35648, 5300 E Skelly Drive, Tulsa, Oklahoma 74135, USA.

## A probable case of the homozygous condition of the aniridia gene

**SUMMARY** A non-consanguineous union between two people with congenital aniridia is described which resulted in the stillbirth of a female fetus with complete absence of eyes, nose, and adrenal glands.

Received for publication 8 January 1980

It is rare that one can observe a mating between two people affected by an autosomal trait defined as 'dominant' and see the effects of the expression of the gene in the homozygous state. Only in this situation will it become apparent whether the trait is truly dominant or intermediate to a more severe homozygous condition. The pattern of inheritance of congenital aniridia is that of a condition resulting from a dominant gene of high penetrance. The condition occurs in approximately 1 in 65 000 subjects<sup>1</sup> and involves the anterior (mesodermal), or the posterior (neuroectodermal) layer of the iris, or both. In addition, there are often associated defects including aplasia of the macula, nystagmus, and photophobia.<sup>2,3</sup> Secondary changes such as glaucoma often occur. There is considerable variation in expression of the gene from complete absence of the iris to a mild coloboma, but the manifestations tend to be symmetrical in an affected subject.<sup>4</sup>

Only three aniridia × aniridia matings have been reported, all of which were consanguineous.<sup>2,5</sup> One couple was infertile. Another had six pregnancies. These produced one daughter with aniridia, three male infants who died within 24 hours of birth with nothing documented about their eyes, one miscarriage, and one dead fetus removed at hysterectomy. No pathological examination was performed on this fetus. The report of Elsas *et al*<sup>5</sup> of a mating between two aniridics shows that three of the four living children had congenital aniridia. There was a stillborn child about which little is known.

We describe here a mating between two unrelated people with congenital aniridia, which resulted in the delivery of a stillborn fetus with total absence of eyes, nose, and adrenal glands.

### Case report

The mother (III.2, fig 1) was first seen at the age of 41, in her fourth pregnancy, for genetic counselling because of maternal age. She was a housewife but did part-time machine knitting at home. Her vision had been poor from childhood, and she had been diagnosed as having congenital aniridia with, in addition, one or two fine corneal opacities in the left eye, congenital cataracts, and nystagmus. Her visual acuity was 6/60 in both eyes 6 years before this visit. She was otherwise well. Her family tree is shown in fig 1. Her husband (III.1, fig 2) was a 42-year-old telephonist; he had met his wife at a school for the blind. He had congenital aniridia and had been poorly-sighted from childhood. At the age of 33 he had a detached retina which was treated surgically. He also had corneal opacities and dense cataracts, the latter requiring operative treatment. His family tree is shown in fig 2.

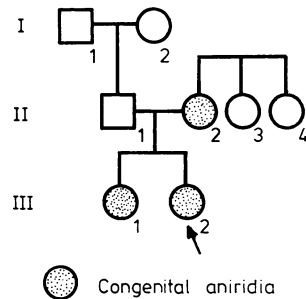


FIG 1 Pedigree of mother.

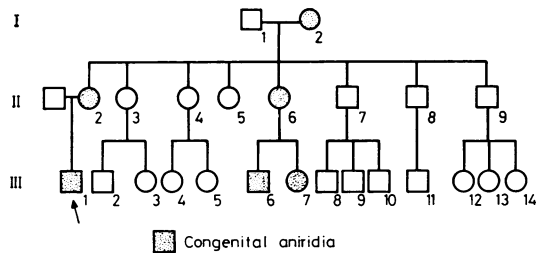


FIG 2 Pedigree of father.

The mother gave a history of relative infertility over the previous 16 years, with two miscarriages at 10 weeks' gestation. During her third pregnancy, when she was aged 39, amniocentesis was performed for raised maternal age. Culture of cells obtained at amniocentesis showed a normal female chromosome complement, and the  $\alpha$ -fetoprotein was within normal limits. She declined genetic counselling about aniridia at this time. Labour was induced at 37 weeks' gestation as fetal movements could not be detected. A macerated stillborn female infant weighing 1412 g was delivered. A full necropsy was performed, with the following findings.

Both eyes were absent. There were no palpebral fissures present, and the shallow eye sockets contained only fibrofatty tissue. The nasal bones were completely absent and the nasal cavity was small. Both parietal bones had matching elliptical defects at their posterior medial aspect and overlapped the occipital bone. The skeletal system was otherwise normal. The brain was macerated and weighed 95 g. Both adrenals were absent. Both kidneys and pelvi-ureteral systems appeared normal, as did the uterus and adnexae. Thymus and thyroid glands were normal. No abnormality was detected in the alimentary, cardiovascular, or respiratory systems. The placenta was normal.

## Discussion

The congenital anomaly described here has not, to our knowledge, been reported before, either sporadically or in kindreds with aniridia. It can be distinguished from primary anophthalmos, a rare autosomal recessive trait, by the complete absence of eyes and of palpebral fissures. In true primary anophthalmos only the ectodermal elements are missing, and the orbit is usually present with eyelids and small palpebral fissures; this condition has not been associated with adrenal and skull defects.<sup>6</sup> Cryptophthalmos, a rare autosomal recessive disorder, is characterised by an absence of palpebral apertures.<sup>7</sup> The eyes in such cases are usually present, although malformed and microphthalmic, and the nose is not usually abnormal, in contrast to our case.

While there is no proof that the defects described in our case were genetically determined, it seems highly likely that they were a consequence of the mating between two parents with aniridia. If this is so, it is possible that this dramatic defect represents the effect of the homozygous condition. Aniridia could therefore strictly be described as 'intermediate' to this severe homozygous phenotype.

It may well be relevant that pregnancies resulting from matings between aniridics have a poor outcome; of the 13 pregnancies known, including three in our patient, only five live children resulted, four with aniridia. The high pre- and perinatal death rate could be the result of fetuses with homozygous aniridia.

It is possible that the adrenal aplasia in this fetus represents the homozygous state of a recessive gene linked to aniridia, which is not apparent in the heterozygote, but this is obviously speculative. The location of the aniridia gene itself remains uncertain. The usually sporadic cases of aniridia with Wilms' tumour in which an 11p interstitial chromosome deletion has recently been found<sup>7</sup> indicate a position on chromosome 11. However, other workers using linkage studies have suggested that the hereditary type of aniridia has its locus on chromosome 1.<sup>8</sup> Perhaps the occurrence of adrenal aplasia in our case will help further in the location of the aniridia gene.

We would like to thank Professor P Polani and Dr A C Berry for their advice and help in preparing this manuscript.

S V HODGSON\* AND K E SAUNDERS†  
 \*Paediatric Research Unit,  
 The Prince Philip Research Laboratories,  
 Guy's Hospital, Guy's Tower,  
 London SE1 9RT;  
 †Consultant Pathologist,  
 Woolwich Group Hospitals

## References

- Shaw MW, Falls HF, Beel JV. Congenital aniridia. *Am J Hum Genet* 1960;12:389-415.
- Grove JH, Shaw MW, Bourque G. A family study of aniridia. *Arch Ophthalmol* 1961;65:81-94.
- Pincus MH. Aniridia congenita. *Arch Ophthalmol* 1948;39:60-6.
- Reed TE, Falls HF. A pedigree of aniridia with a discussion of germinal mosaicism in man. *Am J Hum Genet* 1955;7:28-38.
- Elsas FJ, Maumenee IH, Kenyon RK, Yoder F. Familial aniridia with preserved ocular function. *Am J Ophthalmol* 1977;83:718-24.
- Mann I. *Developmental abnormalities of the eye*. London: British Medical Association. 1957:60-6.
- Riccardi VM, Sujansky E, Smith AC, Francke U. Chromosomal imbalance in the aniridia-Wilms' tumor association: 11p interstitial deletion. *Pediatrics* 1978;61:604-10.
- Sloderbeck JD, Maumenee IH, Elsas FE, et al. Linkage assignment of aniridia to chromosome 1. *Am J Hum Genet* 1975;27:83A.

Requests for reprints to Dr S V Hodgson, Paediatric Research Unit, The Prince Philip Research Laboratories, Guy's Hospital, London SE1 9RT.

## Craniosynostosis and syndactyly: expanding the 11q- chromosomal deletion phenotype\*

**SUMMARY** A patient with a partial deletion (q23→qter) of the long arm of chromosome 11 presented with craniosynostosis and syndactyly. These characteristics, which have not been previously reported with 11q-, expand the phenotype of this syndrome and emphasise the need for chromosome analysis with banding techniques in multiple congenital anomaly syndromes, even if the patient could be classified as having a non-chromosomal syndrome.

We recently evaluated a patient with craniosynostosis of the sagittal suture and syndactyly and found an 11q23→qter deletion. Since neither of these two predominant features has been previously reported in association with this chromosomal anomaly, this case significantly expands the clinical spectrum of this 'syndrome'.

## Case report

The patient presented at 26 months of age for

\*Supported in part by grants HD-05615 and HD-04612 from the National Institute of Child Health and Human Development

Received for publication 25 February 1980