

# Image Analysis Microspectroscopy Shows that Neurons Participate in the Genesis of a Subset of Early Primitive (Diffuse) Senile Plaques

M. A. Pappolla,\* R. A. Omar,†  
and H. V. Vinters‡

From the New York Medical College, Valhalla, New York, and the F.D.R. Veterans Administration Medical Center, Montrose, New York,\* the West Virginia University, School of Medicine, Morgantown, West Virginia,† and the UCLA Medical Center, Los Angeles, California‡

*Amyloid is a component of the senile plaques that characterize one of the major neuropathologic changes in patients with Alzheimer's disease (AD). The sequence of events leading to the accumulation of amyloid precursors in senile plaques is unknown. In previous studies, the authors have shown that congophilic deposits in a subset of mature amyloid plaques are angiocentric. In this study, the authors used image analysis microspectroscopy and an antibody directed against a synthetic beta-protein ( $\beta$ ) or A4 sequence to examine the distribution patterns of this protein in serial sections from brains of patients with AD and in normal aged brains after quantitative immunohistochemistry. Image analysis of early primitive plaques disclosed two main patterns of early  $\beta$ /A4 deposition, which consisted of neurocentric and angiocentric decreasing concentration gradients. In most instances, these gradients were not recognizable by the naked eye but appeared strikingly conspicuous after image subtraction and pseudocoloring. The described neurocentric gradients suggest that deposition of this protein, in at least some early primitive plaques, is related to neurons and possibly originates from these cells. The opposite viewpoint, i.e., that peripherally synthesized  $\beta$ /A4 protein would 'sink in' toward neurons, is not supported because in very early plaques the highest immunoreactivity within the gradient was the neuronal body itself. A hypothesis is offered to reconcile the presence of both neurocentric and angiocentric depositions of these substances. (Am J Pathol 1991, 139:599-607)*

Among the most prominent histopathologic changes found in the brain tissue of patients with Alzheimer's dis-

ease (AD) are discrete foci of neuropil degeneration known as senile plaques.<sup>1</sup> The heterogeneous nature of these lesions has inspired several disparate, at times apparently conflicting, theories of plaque formation.<sup>2-11</sup> Amyloid filaments and their protein precursors are major constituents of the senile plaque.<sup>12</sup> Thus considerable efforts have focused on identifying the mechanisms that lead to the accumulation of these substances.

Initial studies on brain amyloid isolates disclosed a unique 28 amino-acid sequence termed beta-protein<sup>13</sup> or A4 peptide.<sup>14</sup> Subsequent investigations have shown that the  $\beta$ /A4-protein is part of at least four larger precursor molecules encoded by a gene in chromosome 21.<sup>15-21</sup> Two of these precursors have antiprotease activity and show a 56-amino-acid insert partially homologous with the Kunitz family of serine protease inhibitors.<sup>19,21</sup> Amyloid precursor proteins (APP) are integral membrane glycoproteins containing large extracellular domains and shorter intracytoplasmic regions.<sup>17,22</sup> It appears that initial stages of plaque formation are characterized by neuropil deposits of these substances.

Amyloid or its precursor proteins have been detected in various cell types studied, including neurons,<sup>23,24</sup> neuroglial cells,<sup>23</sup> and extracerebral tissues.<sup>25</sup> Thus the potential source of the abnormal neuropil deposits remains an important unresolved issue.

Earlier morphologic observations on plaque amyloid, using conventional amyloid staining such as Congo red or electronmicroscopy, showed the brain microvasculature as a possible primary site of amyloid deposition,<sup>26-29</sup> suggesting, perhaps, an extracerebral origin for the peptide. The availability of antibodies to the  $\beta$ /A4 protein and to various subsequences of the APP has allowed visualization of early primitive senile plaques<sup>30,31</sup> and provided a fresh reassessment of the abnormal deposition of these substances. In this study, we used image analysis microspectroscopy<sup>32</sup> and quantitative immunohistochemistry in serial sections from brains with Alzheimer's dis-

Supported in part by NIH grant NS 26312-03.

Accepted for publication April 29, 1991.

Address reprint requests to M. A. Pappolla, MD, Mt. Sinai School of Medicine, Box 1229 (Annenberg 22-72) 1450 Madison Ave. New York, NY 10029.

ease. We report microspectroscopic images obtained after three-dimensional reconstruction and topographic quantification of the  $\beta$ /A4 protein in aged brains and brains with AD. These images show a clear-cut relationship of cortical neurons to very early neuropil deposits of  $\beta$ /A4 protein in a subset of early primitive senile plaques.

## Materials and Methods

### Image Analysis Microspectroscopy and Quantitative Immunohistochemistry

The basic principles of image analysis microspectroscopy were developed in our laboratory and have been published.<sup>32</sup> Briefly, the method consists of creating images from each microscopic field using specific wavelengths (at least two) selected according to the substance(s) of interest. After composing a 'binary image,' the densities at each image plane are subtracted point by point and in precise synchronization from each other to obtain a final image containing only the substance of interest. This subtraction procedure allows specific optical isolation of compounds of interest for quantitative purposes and simultaneously corrects for uneven illumination ('shading correction'), object overlapping, and other unwanted interferences. In this study, image pairs were created from each microscopic field at 470 and 620 nm. These wavelengths were chosen because of the spectral properties of diaminobenzidine (the chromogenic substrate used in the immunostaining method) in tissue sections, as previously determined.<sup>32</sup> After image subtraction, the densities of the final image are dependent on diaminobenzidine concentration only.<sup>32</sup> Final images obtained after the subtraction steps are then subjected to a pseudocolor subroutine<sup>26</sup> in which arbitrarily chosen colors are assigned to each different density region. This allows detection of up to 255 gray density levels, far beyond the capability of the human eye.

Equipment calibration for quantitative immunohistochemistry was conducted as previously described.<sup>32</sup> Briefly, the monochromator was calibrated by spectral analysis of a holmium oxide glass against standard curves (Chemetrics, Spectrostandard) using a microspectrophotometer (Nikon, P1 model NY). The linear response of the photomultiplier was examined with linearity filters (Chemetrics, Spectrostandard) and by measuring the absorbance of the peroxidase reaction on transparent nitrocellulose filters ('blot test') as described.<sup>33</sup> The linear response of the image analysis system was examined by obtaining integrated density measurements of the same areas measured by microspectrophotometry. There was a 0.99 correlation coefficient between the two methods as calculated by linear regres-

sion analysis. Optimal antibody concentration and color development time were determined by the standard checkerboard method and from zero-order kinetic plots obtained after filming the color development step and conducting spectrophotometric measurements within discrete areas of sequential single film frames. A computerized 'frame-freezing' video recorder (Polaroid Corporation) connected to the image analyzer was used for this purpose. The optimal development time was chosen from the initial plateau phase of the velocity curve. In our experience and that of others (Sternberger, personal communication), initial plateau phase measurements correlate best with antigenic density. Reliability of the microspectroscopic measurements was confirmed by reproducibility of individual measurements and day to day reproducibility.

A minimum of 15 early primitive plaques per case were studied by image analysis. At least five early primitive plaques per case were tridimensionally reconstructed and examined by image analysis.

### Staining Procedures and Tissue Specimens

The immunostaining technique used in this study was the standard avidin-biotin peroxidase method.<sup>34</sup> Hippocampi and adjacent parahippocampal gyri from five cases of AD meeting the NIH consensus criteria<sup>35</sup> for the autopsy diagnosis of AD were studied. Serial 10- $\mu$  paraffin sections were obtained from two of the AD cases and processed as follows: section 1 was immunoreacted with anti- $\beta$ -protein antibody, section 2 was stained with Congo red,<sup>36</sup> and section 3 was impregnated with silver as per the Gros-Schultze version of the Bielschowsky method.<sup>37</sup> This cycle was repeated to 400  $\mu$  of uninterrupted serial sections. Whenever any of the sections were lost, sectioning was restarted until uninterrupted serial sections were obtained. Control material included hippocampal sections from two neurologically 'normal young' brains and five neurologically and neuropathologically 'normal' patients, which were matched with the brains with AD for age and postmortem interval. Additional sections from brains with AD were incubated with nonimmune rabbit serum and used as negative controls. Immunoreactivity was enhanced by pretreatment of tissue sections with formic acid as described.<sup>38</sup> The specificity of the antibody had been previously confirmed by absorption with the synthetic  $\beta$ /A4 peptide.<sup>39</sup>

### Anti- $\beta$ /A4-protein Antibody

This antibody was selected from among several anti-APP and anti- $\beta$ /A4 antibodies tested because it reacted with

intracytoplasmic and extracytoplasmic proteins. Antibody production and characterization has been reported.<sup>39</sup> Briefly, the 28-amino-acid sequence reported by Masters et al<sup>14</sup> was synthesized in a computerized peptide synthesizer and the sequence confirmed. After the conjugation of the peptide to thyroglobulin, New Zealand rabbits were immunized following conventional procedures. The optimal antibody dilution determined for quantification purposes was 1:1000. The antibody was reactive with the  $\beta$ /A4 peptide in Western blots experiments, but did not recognize the larger precursors in the blots (not shown).

## Results

As previously described by other investigators, immunostaining of hippocampal sections disclosed high density of senile plaques in brains from patients with Alzheimer's disease. Three of the five 'normal' aged brains included in this study showed frequent early primitive plaques present in the parahippocampal gyrus. No plaques were detected in the two young brains that were studied. There was intense intracytoplasmic immunoreactivity of hippocampal and parahippocampal neurons in all brains. Intracytoplasmic immunoreactivity was not limited to lipofuscin 'granules,' as previously described with some  $\beta$ /A4 antibodies,<sup>40</sup> but was also present as homogeneous immunolabeling of the entire neuronal perikaryon. Pyramidal cell neurons in regions H<sub>2</sub> and H<sub>3</sub> showed strong immunoreactivity, whereas neurons in region H<sub>1</sub> showed only weak immunostaining, as previously reported by others using similar antibodies.<sup>23</sup> Early primitive plaques were defined as  $\beta$ /A4 positive and argentophilic, round to irregular finely granular neuropil aggregates that were devoid of dystrophic neuritic processes and showed no congophilia. Although small amounts of amyloid fibrils (below the sensitivity of Congo red staining) are present in 'early primitive plaques,'<sup>41,42</sup> there also are amorphous  $\beta$ /A4 aggregates thought to represent putative antecedents of the amyloid fibril.<sup>41</sup> The antibody used in this study was raised against a  $\beta$ /A4 sequence; however, the immunostaining pattern obtained as described below corresponds to published reports with antibodies to other subsequences of the APP.<sup>43</sup> Thus it is likely (although not totally certain because of antibody reactivity in Western blots) that our antibody also recognizes APP *in tissue sections*. In a large number of early plaques (over 50%), neurons were frequently found at some section level (Figures 1, 2, and 3). The proportion of early primitive plaques containing neurons was highly variable from case to case, although these neuron-bearing plaques were more frequent in nondemented aged individuals than in AD (above cases and unpublished observations). Some of these plaque-associated neurons displayed morpho-

logic evidence of degeneration, such as shrinking and loss of nuclear and cytoplasmic details, but no neurofibrillary pathology. In instances, 'empty-nests,' indicative of pre-existing neurons, were clearly identified within early primitive plaques (Figure 2). 'Empty-nests' were more often found in association with early primitive plaques, but also could be observed in plaque-free areas of the neuropil. Although some of these changes could be a result of tissue artifact, matched regions from normal young brains do not show the prevalence of 'empty-nests' present in the elderly or AD population (unpublished observations). Very early immunoreactive deposits were evident as perineuronal areas of immunoreactivity (Figure 4). In more mature plaques, congophilic aggregates were associated with plaque capillaries (not always identifiable). In a small number of primitive plaques, early immunoreactive deposits (which in parallel sections showed no detectable congophilia or dystrophic neuritic processes) surrounded blood vessels.

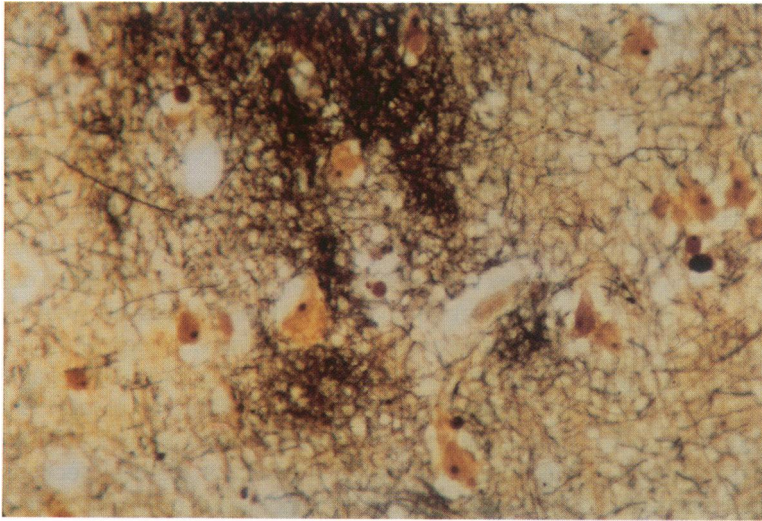
Microspectroscopic images displayed the following patterns of  $\beta$ /A4 deposition:

### Pattern 1

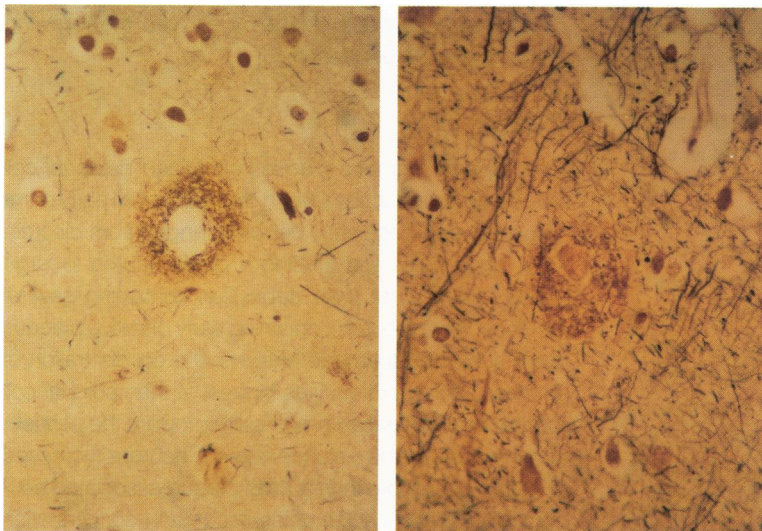
Overall, early primitive plaques contained neuronal cell bodies at some section level in over 50% of all early primitive plaques. These early deposits ranged from discrete  $\beta$ /A4 aggregates surrounding a single neuron to large areas (>400  $\mu$ ) of  $\beta$ /A4 deposition containing several neurons. When neuron-containing early primitive plaques were subjected to image analysis, the concentration of immunolabeled protein was highest at the neuronal cell bodies and decreased progressively toward the perineuronal regions as the distance from the neurons increased (Figures 4–7). More than 90% of plaque-associated neurons were present at the epicenter of  $\beta$ /A4 concentration gradients. Frequently early plaques were composed of several confluent gradients (Figure 5). Occasionally the centers of these gradients showed neurons with markedly decreased intensity of intracytoplasmic immunoreactivity. Some of the neurons with decreased intracytoplasmic immunostaining were undergoing histologic changes of degeneration such as loss of nuclear or cytoplasmic details, hydropic degeneration, karyopyknosis, or karyorrhexis. In most instances, neurocentric gradients were not recognizable by the naked eye, but appeared remarkably conspicuous after image subtraction and pseudocoloring. Only very rarely (less than 1%), neurons associated with early primitive plaques showed neurofibrillary degeneration.

### Pattern 2

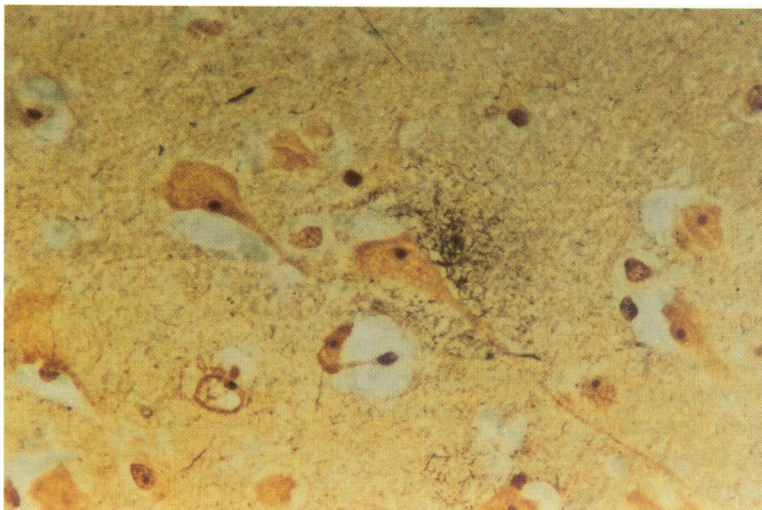
These deposits showed early angiocentric gradients of  $\beta$ /A4 deposition. The central blood vessel could not be



*Figure 1. Microphotograph depicting early primitive plaque. Neurons can be identified "embedded" within argentophilic areas. Early primitive plaques are strongly immunoreactive with anti-B/A4 antibody and are devoid of dystrophic neuritic processes and congophililia (Gros-Schultze-Bielschowsky method,  $\times 300$ ).*

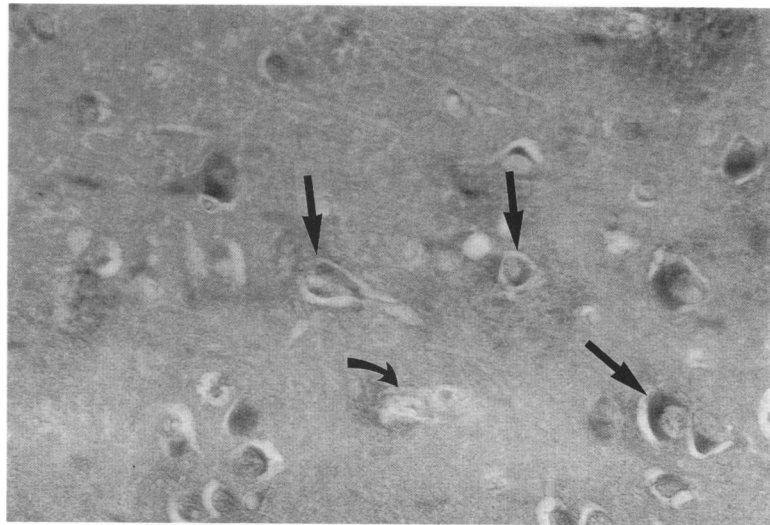


*Figure 2. Microscopic fields showing changes characteristic of early primitive plaques. These are seen as perineuronal areas of argentophilia. Changes such as those illustrated are often the most prominent ones found in the brains of some "normal" elderly individuals. Note "empty-nest" in the photograph at the right, within early primitive plaque (Gros-Schultze-Bielschowsky method,  $\times 200$ ).*



*Figure 3. Representative field illustrating early plaque characterized by perineuronal areas of argentophilia. These areas are strongly immunoreactive with B/A4 antibodies (Gros-Schultze-Bielschowsky method,  $\times 350$ ).*

**Figure 4.** Section from a patient with Alzheimer's disease immunostained with anti-B/A4 antibody. Early primitive plaques are illustrated. Straight arrows point to perineuronal deposits (pattern 1). Curved arrow indicates perivascular deposit (pattern 2). These images are black and white reproductions made along the process of quantitative immunohistochemistry whereby field illumination was manipulated to allow photographic visualization of the deposits. The contrast seen, therefore, does not correspond to the actual dye (diaminobenzidine) concentration. Neurons indicated by two straight arrows showed decreased intracytoplasmic immunostaining in comparison to "noninvolved" neurons. Intracytoplasmic pattern of immunostaining is strong and homogeneous and it is not limited to lipofuscin "granules" as previously described with some B/A4 antibodies.<sup>40</sup> Intracytoplasmic immunostaining such as this can be observed only with some (but not all) B/A4 antibodies<sup>2,3</sup> (also unpublished observations) (Avidin-Biotin-Peroxidase method,  $\times 300$ ).



directly related to neurons or to 'empty-nests,' and they were sometimes larger than capillaries (Figure 5, open curved arrow). This pattern was noted in less than 20% of nonconophilic early primitive plaques in the AD cases and was present only rarely in one of the 'normal aged' brains.

### Pattern 3

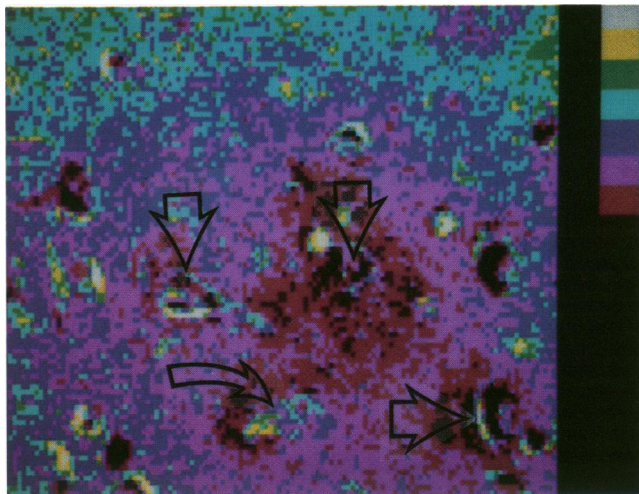
This pattern corresponds to early primitive plaques composed of concentration gradients of  $\beta$ /A4 with no neurons or vascular elements identifiable in serial sections at the epicenter of the gradients. The prevalence of this pattern was highly variable from case to case and ranged from less than 5% to over 50% of all early primitive plaques in individual cases. The presence of other cell types (such as microglial or astroglial) at the epicenter of pattern 3 gradients can not be established in this study.

### Pattern 4

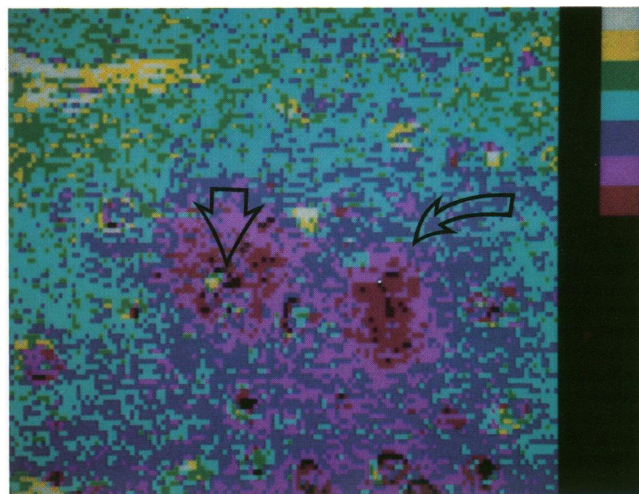
This pattern was characterized also by gradients of  $\beta$ /A4 concentration, but corresponded to that observed in more mature stages of plaque formation (plaques containing aggregates of congophilic amyloid). The concentration gradients were either angiocentric or showed no traceable cellular or vascular elements at the areas of highest amyloid concentration. Angiocentric gradients of congophilic amyloid in mature plaques correspond to our earlier published observations with Congo red staining.<sup>26</sup> Histologically normal appearing neurons were never observed at the center of congophilic gradients.

### Discussion

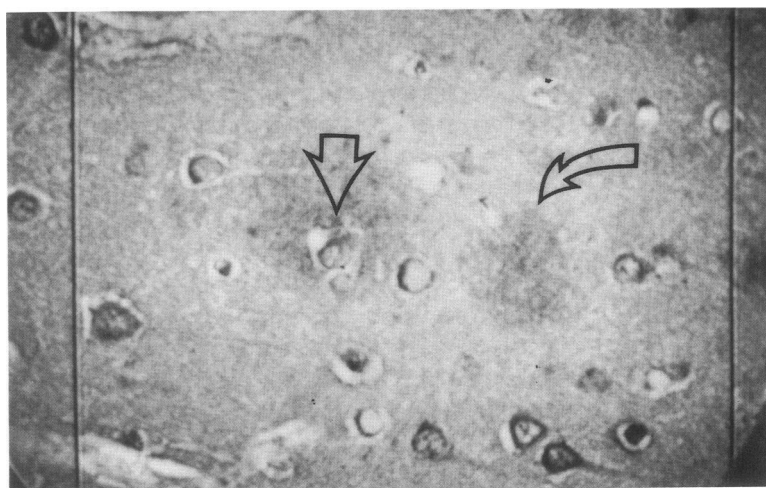
Various types of  $\beta$ /A4 deposits were described by several investigators using anti- $\beta$ -protein antibodies within brains from patients with AD.<sup>30,31,38,39,42-46</sup> Early primitive deposits are noncongophilic, lack the characteristic cores present in 'mature' senile plaques and are devoid of dystrophic neuritic processes. Although neurons could consistently be identified within these early primitive plaques [see references 30,42-46, and this study]), the significance of their presence has been questioned because of the high neuronal density at the site where early primitive plaques occur and the multiple potential sources (other than neuronal) of  $\beta$ /A4 protein. The images obtained in this study, however, showed that most neurons 'embedded' in early primitive plaques are located at the epicenter of  $\beta$ /A4 concentration gradients. This finding excludes chance as a possible explanation for encountering neurons within early primitive plaques. If the presence of neurons within early primitive plaques were incidental, the relationship between neurons and the concentration gradients would be erratic, a situation found only in rare instances. The microspectroscopic images obtained suggest that the  $\beta$ /A4 protein that accumulates in this subset of early primitive plaques either derives from neurons or that these neurons play an important role in the initial stages of plaque formation. An alternate possibility, that is, that peripherally synthesized  $\beta$ /A4 protein would 'converge' toward neurons, is extremely unlikely because the highest density of the gradients were frequently the neuronal bodies themselves. In instances, neurons at the epicenter of a gradient showed decreased intracytoplasmic concentrations of  $\beta$ /A4 protein in comparison with 'noninvolved' neurons, which suggested some relationship between  $\beta$ /A4 accumulation and neuronal disease.



**Figure 5.** Microspectroscopic image reveals that neurons indicated by arrows in Figure 4 are located at highest-concentration regions in four confluent-density gradients (indicated by "open" arrows in this figure). The open curved arrow in this figure corresponds to the solid curved arrow in Figure 4, which points to a blood vessel. Note that these gradients are confluent and involve larger areas of neuropil than those observed by unaided light microscopy. This is one of the advantages of image analysis microspectroscopy (i.e., the detection of pathologic changes beyond the capability of the human eye). The lower end of the color scale corresponds to the highest optical density, i.e., the strongest immunoreactivity.



**Figure 7.** Microspectroscopic image obtained from the microscopic field illustrated in Figure 6. In both immunoreactive areas a clear-cut "neurocentric" pseudocolor gradient (pattern 1 of B/A4 deposition) is readily apparent. Such a gradient could not have been detected without image analysis microspectroscopy. The intensity of immunostaining of the neuron indicated by the open straight arrow is decreased when compared with the intensity of "uninvolved" neurons. However the level of intracytoplasmic immunoreactivity is still the highest in the gradient. The lower end of the color scale corresponds to the highest optical density (i.e., immunoreactivity).



**Figure 6.** "Live" video image of another representative area from a quantitatively immunoreacted brain section from a patient with Alzheimer's disease. The image includes contaminating "nonspecific" gray shades that are taken into consideration by computerized image processing (shade correction). Straight arrow points to a neuronal cell body "embedded" within a B/A4 immunoreactive area. Open curved arrow points to immunoreactive area whereby a neuron was identified in a subjacent section (not shown) (Avidin-Biotin-Peroxidase method,  $\times 300$ ).

In adopting one or another theory regarding the source of  $\beta$ /A4 protein, some degree of speculation is necessary to reconcile the simultaneous presence of two main patterns of early accumulation, namely, neurocentric (pattern 1) and angiocentric (pattern 2). In a previous study, we have shown that congophilic deposits in mature plaques are angiocentric. Because it is generally assumed that the so-called 'mature' plaques (plaques with congophilic cores) represent later stages in plaque formation,<sup>44</sup> one can speculate that neuronally synthesized APP may migrate toward blood vessels, where its amyloidogenic fragment accumulates. Although it has been argued that amyloid deposits in blood vessels may reflect the accumulation of a blood-borne precursor,<sup>27,28</sup> the presence of early primitive neurocentric plaques does not support this view. In the hamster model of scrapie (biochemical differences from AD aside), it has been proposed that vascular deposits of amyloid are secondary and reflect 'bulk-flow' removal of intracerebrally produced 'prion' proteins.<sup>47</sup> Yet there are a number of observations that make the interpretation of  $\beta$ /A4 accumulation less straightforward. Early deposits of  $\beta$ /A4 protein in cortical vessels larger than capillaries (see references 31, 48, 49 and pattern 2 in this study) are obviously not directly related to neurons and would leave the question of a secondary source of the  $\beta$ /A4 protein or a concomitant vascular dysfunction open to further investigation. Relevant to the latter possibility, perhaps, is the reported presence of abnormal deposits of  $\beta$ /A4 protein in cerebrovascular malformations.<sup>50</sup>

With all these observations considered, we propose the following mechanisms of senile plaque formation. First, an initial vascular defect or lesion would trigger increased production, secretion, and/or abnormal processing of amyloid precursors by neurons and by *perivascular* neuronal processes. Current investigations favor increased levels of some amyloid precursor proteins in AD.<sup>51-55</sup> Initially, deposits of  $\beta$ /A4 would be visualized as early primitive neurocentric and angiocentric plaques. Neurons at the epicenter of gradients would degenerate and die early in the process, while a subpopulation of surviving neurons may go on to form neurofibrillary pathology. Thereafter, macrophages and microglial cells might attempt to clear these deposits employing their proteolytic enzyme systems. This proteolysis, however, may become 'impaired' because of several factors, including the antiprotease activity of some peptides derived from some amyloid precursors. This would be associated with 'incomplete' proteolysis that results in the formation of amyloidogenic fragments, which by virtue of their relatively insoluble properties can not traverse vascular structures and would accumulate at vessel walls. This stage may represent what we visualize as congophilic angiocentric gradients. The observations that an-

giocentric gradients (pattern 2) are less frequent than neurocentric gradients in 'normal' aging brains is in line with this proposed mechanism of amyloid deposition. Moreover, because mature plaques may represent later stages of plaque formation, the fact that neurocentric gradients are never observed in mature plaques also would be consistent with the above-proposed sequence of events. Finally small blood vessels are effaced and amyloid deposits then would be seen as congophilic gradients, with no traceable vascular elements at their center. Electron microscopic studies showing basement membrane fragments at the center of mature plaques<sup>29</sup> would support the latter possibility. The presence of 'neuron-free' and 'vessel-free' early  $\beta$ /A4 deposits (pattern 3) remains enigmatic to us. The role of microglial cells in the genesis of the senile plaques is not addressed in the current study, but may be relevant to the latter pattern of  $\beta$ /A4 accumulation. Microglial cells have been demonstrated at the center of a putative initial stage of senile plaque by one investigation,<sup>11</sup> but may be found in all kinds of plaques according to other studies.<sup>56</sup> Several investigators have failed to detect microglial cells in early diffuse deposits,<sup>57,58</sup> and suggested that  $\beta$ /A4 deposition precedes microglial activation. The above results, however, may be complicated by a number of technical difficulties encountered in the immunohistochemical detection of microglial cells.<sup>56</sup> Recently published studies have postulated that either microglial cells may play a role in processing neuronally derived amyloid precursors<sup>59</sup> or that microglia may induce increased APP production by neurons.<sup>56</sup>

To conclude, we report that neurons are related to a subset of early primitive senile plaques and that these neurons display (at times) evidence of disease. The hypothesis proposed herein in regard to plaque formation is speculative because it rests on assumed sequences of pathogenetic events reconstructed from morphologic observations alone. Such an exercise, however, is necessary to help shape our future research directions.

### Note Added in Proof

While this manuscript was in press, two different groups of investigators reported their findings, which support our interpretation that ABP deposition commences on the neuronal level, in transgenic mice (Wirak et al., *Science* 1991, 253:323-325 and Quon D et al., *Nature* 1991, 352:239-241).

### Acknowledgments

The authors thank D. Maldonado for preparing the manuscript, and D. Taylor for technical assistance.

## References

1. Tomlinson BE, Corsellis JAN: Aging and the dementia, Greenfields Neuropathology. Edited by JH Adams, JAN Corsellis, LW Duchon. London, Edward Arnold, 1984, pp 951-1025
2. Wisniewski HM, Terry RD: Reexamination of the pathogenesis of the senile plaque, *Progress in Neuropathology*, Vol 2. Edited by HM Zimmerman. New York, Grune & Stratton, 1973, pp 1-26
3. Terry RD, Wisniewski HM: Alzheimer's disease and related conditions. *Ciba Found Symp* 1970, 145-168
4. Dayan AD: Quantitative histological studies on the aged human brain: I. Senile plaques and neurofibrillary tangles in normal patients. *Acta Neuropathol* 1970, 16:85-94
5. Morimatsu M, Hirai S, Muramatsu A, Yoshikawa M: Senile degenerative brain lesions and dementia. *J Am Geriatr Soc* 1975, 23:390-406
6. Ulrich J: Alzheimer changes in nondemented patients younger than sixty-five: Possible early stages of Alzheimer's disease and senile dementia of Alzheimer type. *Ann Neurol* 1985, 17:273-277
7. Terry RD, Gonatas NK, Weiss M: Ultrastructural studies in Alzheimer's presenile dementia. *Am J Pathol* 1964, 44:269-297
8. Gonatas NK, Anderson W, Evangelista I: The contribution of altered synapses in the senile plaque: An electron microscopic study in Alzheimer's dementia. *J Neuropathol Exp Neurol* 1967, 26:25-39
9. Armstrong DM, Leroy S, Shields D, Terry RD: Somatostatin-like immunoreactivity within neuritic plaques. *Brain Res* 1985, 338:71-79
10. Kosik KS, Rogers J, Kowall NW: Senile plaques are located between apical dendritic clusters. *J Neuropathol Exp Neurol* 1987, 46:1-11
11. Probst A, Brunnschweiler H, Lautenschlager C, Ulrich J: A special type of senile plaque, possibly an initial stage. *Acta Neuropathol* 1987, 74:133-141
12. Selkoe DJ: Biochemistry of altered brain proteins in Alzheimer's Disease. *Annu Rev Neurosci* 1989, 12:463-490
13. Glenner GG, Wong CW: Alzheimer's disease: Initial report of the purification and characterization of a novel cerebrovascular amyloid protein. *Biochem Biophys Res Commun* 1984, 120:1131-1135
14. Masters CL, Simms G, Weinman NA, Multhaup G, McDonald BL, Beyreuther K: Amyloid plaque core protein in Alzheimer disease and Down syndrome. *Proc Natl Acad Sci USA* 1985, 82:4245-4249
15. Robakis NK, Ramakrishna N, Wolfe G, Wisniewski HM: Molecular cloning and characterization of a cDNA encoding the cerebrovascular and the neuritic plaque amyloid peptides. *Proc Natl Acad Sci USA* 1987, 84:4190-4194
16. Tanzi RE, McClatchey AI, Lamperti ED, Villa-Komaroff L, Gusella JF, Neve RL: Protease inhibitor domain encoded by an amyloid protein precursor mRNA associated with Alzheimer's disease. *Nature* 1988, 337:528-530
17. Kang J, Lemaire HG, Unterbeck A, Salbaum MJ, Masters CL, Grzeschik KH, Multhaup G, Beyreuther K, Muller-Hill B: The precursor of Alzheimer's disease amyloid A4 protein resembles a cell surface receptor. *Nature* 1987, 325:733-736
18. Tanzi RE, Gusella JF, Watkins PC, Bruns GAP, St. George-Hyslop P, VanKeuren ML, Patterson D, Pagan S, Kurnit DM, Neve RL: Amyloid beta-protein gene: cDNA, mRNA distribution, and genetic linkage near the Alzheimer locus. *Science* 1987, 235:880-884
19. Kitaguchi N, Takahashi Y, Tokushima Y, Shiojiri S, Ito H: Novel precursor of Alzheimer's disease amyloid protein shows protease inhibitory activity. *Nature* 1988, 331:530-532
20. DeSauvage F, Octave JN: A novel mRNA of the A4 amyloid precursor gene coding for a possibly secreted protein. *Science* 1989, 245:651-653
21. Ponte P, Gonzalez-DeWhitt P, Schilling J, Miller J, Hsu D, Greenberg B, Davis K, Wallace W, Lieberburg I, Fuller F: A new A4-amyloid in RNA contains a domain homologous to serine proteinase inhibitors. *Nature* 1988, 331:525-527
22. Refolo LM, Saiton SRJ, Anderson JP, Mehta P, Robakis NK: Nerve and epidermal growth factors induce the release of the Alzheimer amyloid precursor from PC 12 cell cultures. *Biochem Biophys Res Commun* 1989, 164:664-670
23. Stern RA, Otvos L Jr, Trojanowski JQ, Lee VMY: Monoclonal antibodies to a synthetic peptide homologous with the first 28 amino acids of Alzheimer's disease B-protein recognize amyloid and diverse glial and neuronal cell types in the central nervous system. *Am J Pathol* 1989, 134:973-978
24. Robakis NK, Lahiri D, Brown H, Rubenstein R, Mehta P, Wisniewski HM, Goller N: Disorders of the Developing Nervous System: Changing Views on their Origins, Diagnosis and Treatments. Edited by JW Swann. New York, Alan R. Liss, 1988
25. Joachim CL, Mori H, Selkoe DJ: Amyloid B-protein deposition in tissues other than brain in Alzheimer's disease. *Nature* 1989, 341:226-230
26. Pappolla MA: Image analysis microspectroscopy of senile plaque capillary amyloid in Alzheimer's disease. *Arch Pathol Lab Med* 1989, 113:866-871
27. Glenner GG: Congophilic microangiopathy in the pathogenesis of Alzheimer's syndrome (presenile dementia). *Med Hypotheses* 1979, 5:1231-1236
28. Glenner GG, Henry JH, Fujihara S: Congophilic angiopathy in the pathogenesis of Alzheimer's degeneration. *Ann Pathol* 1981, 1:120-129
29. Miyakawa T, Shimoji A, Kuramoto R, Higuchi Y: The relationship between senile plaques and cerebral blood vessels in Alzheimer's disease and senile dementia: Morphological mechanism of senile plaque production. *Virchows Arch [B]* 1982, 40:121-129
30. Tagliavini F, Giaccone G, Frangione B, Bugiani O: Pre-amyloid deposits in the cerebral cortex of patients with Alzheimer's disease and nondemented individuals. *Neurosci Lett* 1988, 93:191-196
31. Tagliavini F, Ghiso J, Timmers WF, Giaccone G, Bugiani O, Frangione B: Coexistence of Alzheimer amyloid precursor and amyloid protein in cerebral vessel walls. *Lab Invest* 1990, 62:761-767



32. Pappolla MA: Computerized image analysis microspectroscopy of tissue sections. *Arch Pathol Lab Med* 1988, 112:787-790
33. Nibbering PH, Leijh PCJ, Van Furth R: Quantitation of monoclonal antibody binding to individual cells by cytophotometry, Vol 3. Orlando, Academic Press, 1985, pp 97-113
34. Hsu SM, Raine L, Fanger H: The use of antiavidin and avidin-biotin-peroxidase complex in immunoperoxidase techniques. *Am J Clin Pathol* 1981, 75:816-821
35. Khachaturian ZS: Diagnosis of Alzheimer's disease: Conference report. *Arch Neurol* 1985, 42:1097-1105
36. Preece A: Staining, A Manual for Histologic Techniques. Edited by A Preece. Boston, Little Brown, 1972, p 236
37. Yamamoto T, Hirano A: A comparative study of modified Bielschowsky, Bodian and thioflavin S stains on Alzheimer's neurofibrillary tangles. *Neuropathol Appl Neurobiol* 1986, 12:3-9
38. Vinters HV, Pardridge WM, Secor DL, Ishii N: Immunohistochemical study of cerebral amyloid angiopathy. II. *Am J Pathol* 1988, 133(1):150-162
39. Vinters HV, Pardridge WM, Yang J: Immunohistochemical study of cerebral amyloid angiopathy. *Hum Pathol* 1988, 19(2):214-222
40. Wisniewski KE, Maslinska D, Kitaguchi T, Kim KS, Goebel HH, Haltia M: Topographic heterogeneity of amyloid B-protein epitopes in brains with various forms of neuronal ceroid lipofuscinoses suggesting defective processing of amyloid precursor protein. *Acta Neuropathol* 1990, 80:26-34
41. Yamaguchi H, Nakazato Y, Hirai S, Shoji M, Harigaya Y: Electron micrograph of diffuse plaques. Initial stage of senile plaque formation in the Alzheimer brain. *Am J Pathol* 1989, 135:593-597
42. Verga L, Frangione B, Tagliavini F, Giaccone G, Migheli A, Bugiani O: Alzheimer patients and Down patients: Cerebral preamyloid deposits differ ultrastructurally and histochemically from the amyloid of senile plaques. *Neurosci Lett* 1989, 105:294-299
43. Takahashi H, Kurashima C, Utsuryama M, Hirokawa K: Immunohistological study of senile brains by using a monoclonal antibody recognizing B amyloid precursor protein: Significance of granular deposits in relation with senile plaques. *Acta Neuropathol* 1990, 80:260-265
44. Yamaguchi S, Hirai M, Morimatsu M, Shoji M, Harigaya Y: Diffuse type of senile plaques in the brains of Alzheimer-type dementia. *Acta Neuropathol* 1988, 77:113-119
45. Yamaguchi H, Hirai S, Morimatsu M, Shoji M, Ihara Y: A variety of cerebral amyloid deposits in the brains of the Alzheimer-type dementia demonstrated by beta protein immunostaining. *Acta Neuropathol* 1988, 76:541-549
46. Allsop D, Haga SI, Haga C, Ikeda SI, Mann DM, Ishii T: Early senile plaques in Down's syndrome brains show a close relationship with cell bodies of neurons. *Neuropathol Appl Neurobiol* 1989, 15:531-542
47. Snow AD, Kisilevsky R, Willmer J, Prusiner SB, DeArmond SJ: Sulfated glycoaminoglycans in amyloid plaques in prion disease. *Acta Neuropathol* 1989, 77:337-342
48. Arai H, Sagi N, Noguchi I, Haga S, Ishii T, Makino Y, Kosaka K: An immunohistochemical study of B-protein in Alzheimer-type dementia brains. *J Neurol* 1989, 236:214-217
49. Delacourte A, Defossez A, Persuy P, Peers MC: Observation of morphological relationships between angiopathic blood vessels and degenerative neurites in Alzheimer's disease. *Virchows Arch [A]* 1987, 411:199-204
50. Hart MN, Merz P, Bennett-Gray J, Menezes AH, Goeken JA, Schelper RL, Wisniewski HM: Beta-amyloid protein in Alzheimer's disease is found in cerebral and spinal cord vascular malformations. *Am J Pathol* 1988, 132:167-172
51. Johnson SA, McNeill T, Cordell B, Fruch CE: Relation of neuronal APP-751/APP 695 mRNA ratio and neuritic plaque density in Alzheimer's disease. *Science* 1990, 248:854-857
52. Neve RL, Rogers J, Higgins GA: The Alzheimer amyloid precursor-related transcript lacking the  $\beta/A4$  sequence is specifically increased in Alzheimer's disease brain. *Neuron* 1990, 5:329-338
53. Higgins GA, Lewis DA, Bahmanyar S, Goldgaber D, Gajdusek DC, Young WC, Morrison JH, Wilson MC: Differential regulation of amyloid-beta-protein mRNA expression within hippocampal neuronal subpopulation in Alzheimer disease. *Proc Natl Acad Sci USA* 1988, 85:1287-1301
54. Cohen ML, Golde TE, Usiak MF, Younkin LH, Younkin SC: In situ hybridization of nucleus basalis neurons shows increased beta-amyloid mRNA in Alzheimer disease. *Proc Natl Acad Sci USA* 1988, 85:1227-1231
55. Tanaka S, Nakamura S, Ueda K, Kameyama M, Shiojiri S, Takahashi Y, Kitaguchi N, Ito H: Three types of amyloid protein precursor mRNA in human brain: their differential expression in Alzheimer's disease. *Biochem Biophys Res Commun* 1988, 157:472-479
56. Mattiace LA, Davies P, Yen SH, Dickson DW: Microglia in cerebellar plaques in Alzheimer's disease. *Acta Neuropathol* 1990, 80:493-498
57. Rozemuller JM, Eikelenboom P, Stam FC, Beyreuther K, Masters CL: A4 protein in Alzheimer's disease: Primary and secondary cellular events in extracellular amyloid deposition. *J Neuropathol Exp Neurol* 1989, 48:674-691
58. Itagaki S, McGeer PL, Akizawa H, Zhu S, Selkoe DJ: Relationship of microglia and astrocytes to amyloid deposits of Alzheimer disease. *J Neuroimmunol* 1989, 173-182
59. Cras P, Kawai M, Siedlak S, Mulvihill P, Gambetti P, Lowery D, Gonzalez-DeWhitt P, Greenberg B, Perry G: Neuronal and microglial involvement in B-amyloid protein deposition in Alzheimer's disease. *Am J Pathol* 1990, 137:214-246