

Short Communication

Altered Expression of a Structural Protein (Fodrin) Within Epithelial Proliferative Disease of the Breast

Jean F. Simpson and David L. Page

From the Department of Pathology, Vanderbilt University Medical Center, Nashville, Tennessee

Although certain histopathologic patterns of epithelial proliferative breast disease are well established as indicating an increased relative risk for the subsequent development of mammary carcinoma, the biologic characterization of these changes is not known. One evident histologic characteristic of epithelial hyperplasia is the partial or complete loss of normal cellular polarity. Nonerythroid spectrin (fodrin) is a structural protein whose function is related to maintenance of cellular polarity. By immunohistochemical analysis, normal breast luminal epithelia contain fodrin confined to a characteristic basolateral distribution. Proliferative breast disease of the common type partially loses this polarized distribution of fodrin; fodrin immunoreactivity is not limited to a basolateral location but is present around the cell membrane and is inconsistently present at luminal interfaces. Whether this change in distribution of fodrin is a permissive event in the development of proliferative disease or merely an associated finding is not known. (Am J Pathol 1992, 141:285–289)

The recognition of histopathologic patterns of epithelial proliferation that indicate an increased risk of cancer development have been well established.^{1,2} The underlying molecular structural alterations attendant with and possibly responsible for these histopathologic changes, however, have not been characterized. One evident histologic characteristic of epithelial hyperplasia is the loss of normal cellular polarity, particularly manifest as cells proliferate and often expand basement-membrane bound spaces. Fodrin (nonerythroid spectrin) is an actin-binding protein that participates in the establishment of cellular

orientation and polarity.^{3,4} The cellular localization of fodrin has been shown to vary with maturation, both in colonic epithelium⁵ and in keratinocytes.⁶ The present study evaluates the distribution of fodrin within epithelial proliferative disease of the breast. Within normal breast epithelium, fodrin was immunolocalized to the basolateral portion of luminal, epithelial cells in acini as well as intra- and interlobular ducts. Fodrin was consistently detected within epithelial hyperplasia; however, the cellular distribution was different from that of normal epithelium. In all cases, myoepithelial cells were negative for expression of fodrin.

Materials and Methods

Tissues

Forty-eight breast biopsies obtained from Vanderbilt University Medical Center and Nashville's Baptist Hospital were fixed in Omnifix Tissue Fixative (An-Con Genetics, Inc, Melville, NY) and embedded in paraffin. Hematoxylin and eosin sections were reviewed for histopathologic diagnosis. To compare methods of fixation, a specimen of normal colon and colon adenocarcinoma were each divided, with one half of each specimen fixed in acetone⁵ and the other half fixed in Omnifix, followed by paraffin embedding.

Antibody

Polyclonal rabbit anti-fodrin A antibody was provided by Drs. Alan Harris and Jon Morrow. Properties of this antibody have been described.⁷

Supported in part by NCI grant R01-CA 31698.

Accepted for publication May 26, 1992.

Address reprint requests to Dr. Jean F. Simpson, Division of Pathology, City of Hope Medical Center, Duarte, CA 91010.

Immunohistochemical Methods

Four-micrometer sections were prepared from paraffin blocks mounted on glass slides using 3-aminopropyltriethoxysilane (Sigma, St. Louis, MO) and heated to 60°C for 1 hour. The slides were deparaffinized in xylenes, rehydrated in graded alcohols, and rinsed in phosphate-buffered saline (PBS). Endogenous peroxidase activity was blocked by incubating with 0.01% H₂O₂ in methanol followed by two washes in PBS. Nonspecific staining was blocked by incubating the slides in a 1:20 dilution of normal horse serum. This and all subsequent reagents were diluted in PBS containing a 0.01% solution of bovine serum albumin (BSA). Anti-fodrin antibody diluted 1:1000 was added to the slides and allowed to incubate overnight at 4°C. The bound antibody was detected by use of the streptavidinbiotin method (Vector Laboratories, Burlingame, CA), using diaminobenzidine (DAB), (Sigma, St. Louis, MO) as chromagen. DAB was enhanced by copper-sulfate method. The sections were counterstained with hematoxylin, dehydrated in alcohol, cleared in xylenes, and coverslips were mounted with Permount (Fisher, Norcross, GA).

Results

Because formalin destroys the reactive fodrin epitope, previous studies have used acetone-fixed, paraffin-embedded tissues for immunohistochemical studies of fodrin distribution.⁵ We compared the preservation of fodrin immunoreactivity using Omnifix and acetone fixation. Normal colon and colonic adenocarcinoma gave similar immunoreactivity whether the tissue had been fixed in acetone or Omnifix. Because Omnifix has been used as an alternative to formalin for routine fixation, we were able to study 48 consecutive breast biopsy specimens from our surgical pathology files.

Patients and Histopathologic Diagnoses

The patients, all female, ranged in age from 20–91 with an average age of 50 years. Age-related involutinal and benign changes present paralleled those that have been described.^{8–10} In addition, the age distribution of epithelial

hyperplasia of the usual type was similar. Epithelial hyperplasia was evenly distributed over all age groups, and was most prevalent in the biopsies from patients aged 40–60.

Distribution of Fodrin Immunoreactivity in Normal Structures

In describing the distribution of fodrin immunoreactivity, we have employed the anatomic terminology as presented by Page and Anderson.¹¹ Acini were present in 44 of the 48 cases. Acini consistently expressed fodrin (Table 1), with immunoreactivity localized primarily to the lateral portion of the cell membrane. The basal portion of the cell membrane also was weakly positive for fodrin (Figure 1). Apical staining was only rarely seen, and was never as intense as that seen laterally between cells. Within individual cases, acini were positive throughout, although staining intensity showed some slight variation. Except for one case, acini were positive in all cases regardless of age of the patient. Intralobular ducts were also positive except for one case. These as well as interlobular ducts expressed fodrin in the luminal cells in a basolateral distribution. Myoepithelial or basalar cells were consistently negative in all cases.

Fodrin Distribution in Epithelial Proliferative Disease of the Breast

Twenty-five of 48 cases (52%) showed some degree of epithelial proliferative disease without atypia, which ranged from mild to florid hyperplasia.¹ Twenty-four of the 25 were positive for fodrin immunoreactivity (Table 1). The cellular localization of fodrin positivity was membranous and was present around the circumference of the cell (Figure 2). Some of the cells that bordered secondary lumina (Figure 2) also showed circumferential, membranous staining; the apical surface of other cells bordering the lumina were negative although lateral immunoreactivity was observed, similar to the pattern seen in cells of normal acini. Six examples of papilloma were positive for fodrin expression with membranous distribution similar to that seen in usual type hyperplasia (Table 1).

Four cases of atypical hyperplasia were evaluated for

Table 1. Fodrin Immunoreactivity in Breast Tissues

Normal acini	Hyperplasia (usual type)	Hyperplasia		Papilloma	Lobular alteration†	IMC‡
		ADH	ALH*			
42/43	24/25	2/2	0/2	6/6	4/4	3/3

* Atypical ductal, atypical lobular hyperplasia.

† Lobular alterations include: radial scar, sclerosing adenosis, lactating adenoma, expanded lobules.

‡ Invasive mammary carcinoma.

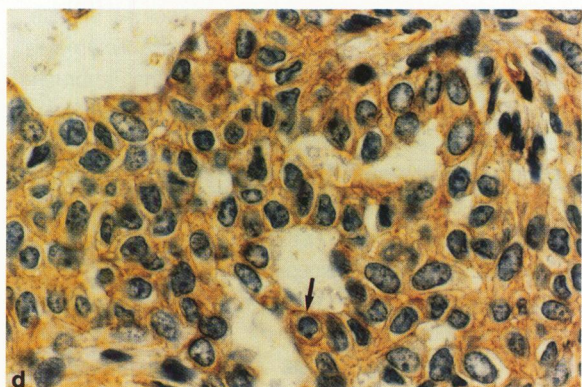
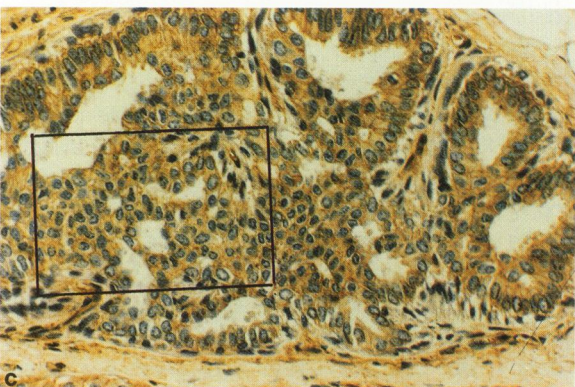
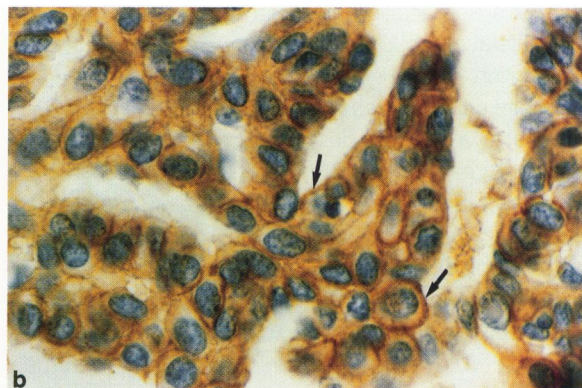

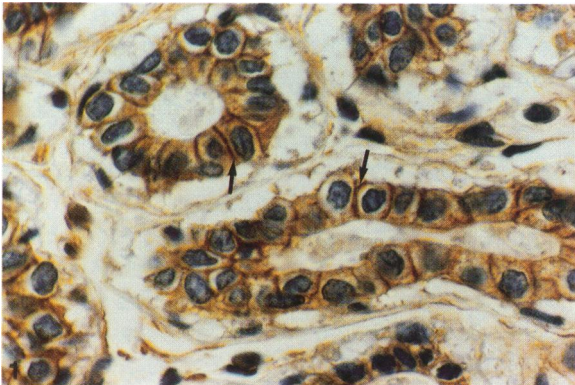


Figure 1. Distribution of fodrin in normal breast acinus as detected by immunohistochemical staining with anti-fodrin antibody. Note that immunoreactivity (arrow) is limited to the basolateral region of luminal epithelial cells with sparing of the apical region. (DAB with hematoxylin counterstain, $\times 300$).

Figure 2. Fodrin expression in epithelial hyperplasia without atypia. As cells proliferate within the basement-membrane bound space, the original lumen is obliterated. Secondary lumina are formed between proliferating cells. a, b: Moderate hyperplasia without atypia. Note that while some luminal cells express fodrin basolaterally, others show circumferential fodrin reactivity, including occasional apical staining (arrows). c: Florid hyperplasia stained with anti-fodrin antibody (DAB with hematoxylin counterstain, $\times 125$). d: Marked area of (c) showing circumferential staining, including some luminal cells (arrow) (DAB with hematoxylin counterstain, $\times 300$).

fodrin expression (Table 1). Two cases of atypical ductal hyperplasia were positive with a distribution similar to that seen in usual type hyperplasia. Two cases of atypical lobular hyperplasia were negative for fodrin expression. However, adjacent acini were positive for fodrin.

Fodrin Distribution in Other Benign Lobular Alterations

One case each of radial scar, sclerosing adenosis, lactating adenoma, and expanded lobular units (>80 acini

in cross section) showed expression of fodrin confined to lateral portion of the cellular membrane.

Fodrin Expression in Mammary Carcinoma

Three examples of invasive mammary carcinoma were evaluated for fodrin expression. All three were positive and showed cytoplasmic staining as well as an accentuation of circumferential membranous staining.

Discussion

This immunohistochemical study of the ubiquitous structural protein, fodrin, shows distinct variation in distribution within the epithelia of benign breasts unrelated to the age of the patient. Normal epithelium of terminal, intra- and interlobular ducts contains fodrin in a characteristic basolateral location, more marked laterally between luminal cells. In hyperplastic epithelia, fodrin is no longer restricted to the basolateral portion of the epithelial cell, but instead is often present around the complete periphery of the cell membrane.

Benign alterations, including radial scar, sclerosing adenosis, and lactating adenoma all contained fodrin in a basolateral distribution. This maintenance of basolateral distribution is not unexpected, considering that these lesions are characterized by distortion of, or an increase in number of, acini but not in the number of cells lining each acinus. Three examples of invasive mammary carcinoma were evaluated for the presence of fodrin; each case showed cytoplasmic positivity, thus confirming results obtained by Younes et al.⁵

Other studies have examined the distribution of fodrin within epithelium, including epidermis⁶ and colonic epithelium.⁵ Within benign colonic epithelium, fodrin is present basolaterally, and as cells mature and approach the lumen, apical positivity for fodrin becomes intense. This apical localization of fodrin in the luminal enterocyte is probably related to its development of a mature brush-border cytoskeleton.⁵ A similar transition in localization of fodrin was not seen in normal breast epithelium. This difference in localization is not surprising considering that the function of the terminally differentiated breast epithelial cell is much different from that of the absorptive colonic epithelium. Nevertheless, function surely is dependent on proper cellular orientation and polarity, as has been shown in *in vitro*.¹²

Florid epithelial hyperplasia of the breast has a characteristic growth pattern that results in cells, and nuclei having a parallel orientation of the long axes, resulting in the so-called 'streaming' pattern as described by Azzopardi.¹³ Thus it seems logical to suggest that the maintenance of strong lateral attachments keeps the cells parallel as they proliferate (due to an unknown stimulus), resulting in the characteristic streaming or swirling growth pattern. Cells that border secondary lumina (Figure 2) are not circumferentially in contact with other cells and show an inconstant expression of fodrin on the apical surface. In some examples, it appears that these apical cells attempt to maintain polarity.

The special and distinct features of the more benign patterns of hyperplasia in the breast have been defined histologically and are now correlated with the partial maintenance of normal basal-lateral expression of fodrin.

Although examples of atypical hyperplasia have not been adequately studied, the absence of fodrin expression in atypical lobular hyperplasia correlates with the characteristic discohesive growth pattern seen in this condition.

Fodrin, also known as nonerythroid spectrin, is one of several cytoskeletal proteins that have been the subject of recent investigations. The distribution of fodrin is different from that of other cytoskeletal proteins. For example, the adhesive molecule, E-cadherin, is present in reduced amounts in invasive carcinomas,¹⁴ whereas fodrin was strongly expressed in our three cases as well as the breast carcinomas evaluated by Younes et al.⁵ E-cadherin may be similar to fodrin in its distribution in normal breast, although distinction between different anatomic locations was not addressed.¹⁴ The distribution of E-cadherin in epithelial proliferative disease of the breast is not known.

Another ubiquitous structural protein, integrin, shows a pattern of tissue distribution similar to E-cadherin. However, in the breast, integrin appears largely limited to the basal layer, both in normal¹⁵ and benign lesions.¹⁶ As with E-cadherin, integrin shows a decreased expression in invasive carcinomas.¹⁷ The presence of other cytoskeletal proteins including cytokeratins,^{18,19} vimentin, and glial filament protein (GFP) have been studied in normal and hyperplastic breast tissue¹⁹ and have a different distribution from that of fodrin.

We have shown that the ubiquitous structural protein fodrin is present within normal breast structures over a wide range of patient age. Of the many proteins in the breast that have been the subject of study, the distribution of fodrin is unique. We have also shown that fodrin is consistently present within epithelial proliferative disease of the breast. Its cellular localization, however, varies between normal breast epithelia and hyperplastic lesions. In normal epithelium, there is a characteristic intense staining along the lateral cell membrane between adjacent cells; in hyperplasia, the proliferating cells show a peripheral circumferential staining of the entire cellular membrane as cells are in contact with several other cells. This peripheral, circumferential staining pattern is present inconsistently in those cells that border secondary lumina. This change in distribution in hyperplasia correlates with the histologic finding of partial loss of cellular orientation and polarity. Whether this change in distribution of fodrin is a permissive event or is merely an associated finding is not known.

Acknowledgments

The authors thank Drs. Alan Harris and Jon Morrow for their gift of antifodrin antibody, Dr. Barry Brantley for the cases, and Sandra F. Olson for expert technical assistance.

References

1. Dupont WD, Page DL: Risk factors for breast cancer in women with proliferative breast disease. *N Engl J Med* 1985, 312:146-151
2. London SJ, Connolly JL, Schnitt SJ, Colditz G: A prospective study of benign breast disease and the risk of breast cancer. *JAMA* 1992, 267:941-944
3. Nelson WJ, Hammerton RW: A membrane-cytoskeletal complex containing Na⁺, K⁺-ATPase, ankyrin, and fodrin in Madin-Darby canine kidney (MDCK) cells: Implications for the biogenesis of epithelial cell polarity. *J Cell Biol* 1989, 108:893-902
4. Molitoris BA, Nelson WJ: Alterations in the establishment and maintenance of epithelial cell polarity as a basis for disease processes. *J Clin Invest* 1990, 85:3-9
5. Younes M, Harris AS, Morrow JS: Fodrin as a differentiation marker: Redistributions in colonic neoplasia. *Am J Pathol* 1989, 135:1197-1212
6. Yoneda K, Fujimoto T, Imamura S, Ogawa K: Distribution of fodrin in the keratinocyte in vivo and in vitro. *J Invest Dermatol* 1990, 94:724-729
7. Harris AS, Green LAD, Ainger KJ, Morrow JS: Mechanisms of cytoskeletal regulation (1): Functional differences correlate with antigenic dissimilarity in human brain and erythrocyte spectrin. *Biochim Biophys Acta* 1985, 830:147-158
8. Page DL, Anderson TJ: *Diagnostic Histopathology of the Breast*, Churchill Livingstone, Edinburgh, 1987, pp 11-29
9. Holzner JH, Hubner K: *Borderline lesions and disorders of the breast. Pathology of Neoplasia and Endocrinology*. Edited by R. Bassler, Goustav Fischer Verlag, 1986, pp 20-43
10. Cowan DF, Herbert TA: Involution of the breast in women aged 50 to 104 years: a histopathological study of 102 cases. *Surg Pathol* 1989, 2: 232-333
11. Page DL, Anderson TJ: *Diagnostic Histopathology of the Breast*. Churchill Livingstone, Edinburgh, 1987, pp 4-10
12. Streuli CH, Bailey N, Bissell MJ: Control of mammary epithelial differentiation: basement membrane induces tissue-specific gene expression in the absence of cell-cell interaction and morphological polarity. *J Cell Biol* 1991, 115:1383-1395
13. Azzopardi JG: *Problems in Breast Pathology*. Philadelphia, W. B. Saunders Co, 1979, pp 114-121
14. Shiozaki H, Tahara H, Oka H, Miyata M, Kobayashi K, Tamura S, Iihara K, Doki Y, Hirano S, Takeichi M, Mori T: Expression of immunoreactive e-cadherin adhesion molecules in human cancers. *Am J Pathol* 1991, 139:17-23
15. Zutter M, Santoro S: Widespread histologic distribution of the alpha₂beta₁ integrin cell-surface collagen receptor. *Am J Pathol* 1990, 137:113-120
16. Koukoulis GK, Virtanen I, Korkkonen M, Laiten L, Quaranta V, Gould VE: Immunohistochemical localization of integrins in the normal, hyperplastic, and neoplastic breast: correlations with their functions as receptors and cell adhesion molecules. *Am J Pathol* 1991, 139:787-799
17. Zutter M, Mazoujian G, Santoro S: Decreased expression of integrin adhesive protein receptors in adenocarcinoma of the breast. *Am J Pathol* 1990, 137:863-870
18. Wetzels R, Kuijpers H, Lane E, Leigh I, Troyanovksy S, Holland R, van Haelst U, Ramaekers: Basal cell-specific and hyperproliferation-related keratins in human breast cancer. *Am J Pathol* 1991, 138:751-763
19. Gould V, Koukoulis G, Jansson D, Nagle R, Franke W, Moll R: Coexpression patterns for vimentin and glial filament protein with cytokeratins in the normal, hyperplastic, and neoplastic breast. *Am J Pathol* 1990, 137:1143-1155