

# Animal Model

## A Spontaneous Mutation Characterized by Chronic Proliferative Dermatitis in C57BL Mice

Harm HogenEsch,\* Marion J. J. Gijbels,\*  
Erik Offerman,\* Joop van Hooft,<sup>†</sup>  
Dirk W. van Bekkum,<sup>†</sup> and Chris Zurcher\*

From the Department of Pathology,\* TNO-Institute for Ageing and Vascular Research, Leiden, the Netherlands, and TNO-Institute for Applied Immunology and Radiobiology,<sup>†</sup> Rijswijk, the Netherlands

**Chronic proliferative dermatitis is a new spontaneous mutation in C57BL/Ka mice. Breeding results suggest an autosomal recessive mode of inheritance. Mutant mice develop skin lesions at the age of 5 to 6 weeks. The lesions occur in the ventral and dorsal skin of the body, whereas ears, footpads, and tail are not involved. The lesions are characterized by epidermal hyperplasia, hyper- and parakeratosis, and single cell necrosis of keratinocytes. The dermis and epidermis are infiltrated by granulocytes and macrophages, and occasionally subcorneal and intracorneal microabscesses are formed. The number of mast cells in the dermis progressively increases with age. There is dilatation and proliferation of dermal capillaries. Similar lesions develop in the mouth, esophagus, and forestomach, which, in the mouse, are all lined by orthokeratinizing stratified squamous cell epithelium. Studies with bromodeoxyuridine confirm the increased rate of epithelial cell proliferation. Most inflammatory cells in the affected skin express Mac-1, and few express the T lymphocyte marker CD3. There is increased expression of intercellular adhesion molecule-1 on keratinocytes and endothelial cells. Infiltration of neutrophils and macrophages are also seen in the liver, lung, and several joints. The disease could not be transferred by bone marrow or spleen transplants into irradiated normal syngeneic hosts. Treatment of the mice with triamcinolone, a long-acting corticosteroid, resulted in**

**nearly complete regression of the lesions over a period of 4 weeks, whereas systemic cyclosporin A treatment was ineffective. (Am J Pathol 1993, 143:972-982)**

The detection and study of hereditary disorders in animals have greatly contributed to our understanding of the complex mechanisms underlying disease processes in general as well as specific human diseases. Such defects in rodents have been particularly useful because of the relative ease of maintenance and breeding of laboratory rodents and the extensive knowledge of their biology and physiology.<sup>1</sup> Mouse models are especially useful because of rapid advances in gene mapping in this animal species.<sup>1</sup> Although nearly 100 mutations are known that affect the skin of mice, few have been investigated in detail.<sup>2</sup>

Local inflammatory reactions elicited by topical application of chemical compounds to the skin of laboratory animals have been extremely valuable in studies of mechanisms of skin inflammation and inflammation in general.<sup>3</sup> These inflammatory responses are generally acute and may be less relevant as models of chronic inflammation. Here, we describe a new spontaneous mutation, which results in the appearance of chronic inflammatory reactions in the skin and in several internal organs. The skin disease, which will be addressed as chronic proliferative dermatitis (cpd), is characterized by hyperproliferation and neutrophil infiltration of orthokeratinizing stratified squamous cell epithelia, including that of the skin and esophagus, and by a chronic persistent inflammatory reaction in the dermis. In this report, we will present data from our morphological studies of this mouse

---

Accepted for publication March 26, 1993.

Address reprint requests to Dr. Harm HogenEsch, Department of Pathology and Immunology, TNO-Institute for Ageing and Vascular Research, P.O. Box 430, 2300 AK Leiden, The Netherlands.

mutant and will discuss its similarities and dissimilarities to other murine models of hyperproliferative skin disease and to human hyperproliferative skin diseases.

## Materials and Methods

### Animals

The cpd mutation arose spontaneously in the breeding stock of inbred C57BL/KaLawRij mice in the specific pathogen-free-breeding facility of TNO in Rijswijk, the Netherlands. Mice in this breeding colony are housed in Macrolon cages and are provided autoclaved pelleted food and acidified, sterilized bottled drinking water *ad libitum*. The microbiological status is checked regularly by routine serological, bacteriological, and histological procedures. Mice were killed at various ages by ether inhalation. Control mice were C57BL/KaLawRij mice from the same colony.

### Treatment with Corticosteroids and Cyclosporin A (CsA)

Two groups ( $n = 4$ ) of 10-week-old cpd mice were treated with triamcinolone (Lederspan, Lederle, Zoeterwoude, the Netherlands), a long-acting corticosteroid, for 4 weeks. One group received two subcutaneous injections of 10 mg/kg, diluted in saline, per week for 3 weeks and one injection of 10 mg/kg in week 4. The second group was given one injection of 5 mg/kg per week. The animals of both groups were killed at the end of week 4. Four control cpd animals were injected with saline only.

Three groups of 10-week-old mice were treated with cyclosporin A (CsA; Sandimmun, kindly provided by Sandoz, Uden, the Netherlands). One group ( $n = 3$ ) received intraperitoneal injections of 15 mg/kg CsA, and a second group ( $n = 2$ ) received intraperitoneal injections of 100 mg/kg CsA, three times a week. The third group ( $n = 3$ ) was given 100  $\mu$ l diluent (olive oil) and served as control group.

### Hemopoietic Cell Transfer

Bone marrow cells and spleen cells from 5-week-old cpd mice were injected intravenously into lethally irradiated (8.7 Gy at 0.87 Gy/minute from a  $^{137}\text{Cs}$  source, type  $\gamma$  cell 20) 8- to 12-week-old syngeneic C57BL/Ka mice. They received  $1 \times 10^6$  bone marrow cells plus  $4 \times 10^6$  spleen cells ( $n = 6$ )

or  $2 \times 10^7$  spleen cells ( $n = 10$ ) only. In a second set of experiments,  $2 \times 10^7$  spleen cells from cpd mice were injected intraperitoneally into 12 neonatal nonirradiated syngeneic C57BL/Ka mice. The recipients were monitored daily for clinical signs of cpd lesions and were euthanized after 2 months, after which a complete necropsy was performed.

### Histology

Tissues were fixed in 10% neutral-buffered formalin, processed, and embedded in paraffin. Three- $\mu$  sections were routinely stained with hematoxylin-phloxine-saffron (HPS). Additional stains used were periodic acid-Schiff, Gomori's silver stain, and toluidine blue.

### Immunohistochemistry

Commercial reagents were biotinylated anti-Ia<sup>b</sup> (PharMingen, San Diego, CA), fluorescein isothiocyanate (FITC)-labeled anti-CD3 $\epsilon$  (clone 145-2C11; Boehringer Mannheim, Almere, the Netherlands), FITC-labeled F(ab')<sub>2</sub> rabbit anti-mouse immunoglobulin G (IgG, Serotec, Oxford, England), avidin-peroxidase (Serotec), and mouse anti-rat peroxidase (Jackson Immunoresearch Laboratories, West-Grove, PA). Hybridomas M7/14 (anti-lymphocyte function-associated antigen-1 [LFA-1]; TIB 217) and M1/70 (anti-Mac-1; TIB 128) were obtained from American Type Culture Collection. Hybridoma MEL-14 (anti-L-selectin) was the kind gift of Dr. L. Nagelkerken (TNO, Leiden, the Netherlands). Hybridoma YN1/1.7 (anti-intercellular adhesion molecule-1 [ICAM-1]<sup>4</sup>) was generously provided by Dr. F. Takei (Terry Fox Laboratory, Vancouver, BC). Supernatant of the YN1/1.7 cells was purified by affinity chromatography over a protein G-column. Hybridoma NLDC-145, which specifically stains dendritic cells,<sup>5</sup> was kindly made available to us by Dr. G. Kraal (Free University of Amsterdam, the Netherlands).

Skin samples were quick-frozen in liquid nitrogen for immunohistochemistry. Frozen sections were incubated overnight at 4 C with biotinylated anti-Ia<sup>b</sup> (1:100), anti-ICAM-1 (1:200), M1/70 (1:5 of supernatant), M7/14 (1:25 of supernatant), MEL-14 (1:40 of supernatant), or NLDC-145 (undiluted supernatant), followed by avidin-peroxidase or mouse anti-rat peroxidase for 60 minutes at room temperature. Negative controls consisted of omission of the primary antibody and replacement of the primary rat monoclonal antibody by an irrelevant rat IgG2a (MECA-

367). Peroxidase activity was visualized with diaminobenzidine (Sigma Chemical Co., St. Louis, MO). Alternatively, sections were incubated overnight at 4 C with FITC anti-CD3 (1:200) or FITC anti-mouse IgG (1:100) and examined using a Leitz Orthoplan epifluorescence microscope.

### *Bromodeoxyuridine (BrdU) Labeling*

To determine the rate of cell proliferation, mice received an intraperitoneal injection of 0.625 mg BrdU (Sigma) 30 minutes before being killed. Tissues were fixed for 18 hours in neutral-buffered formalin and stored in 70% alcohol until further processing. Paraffin-embedded sections were deparaffinized, rehydrated, and treated with 0.2% pepsin in 0.1 N HCl for 10 minutes at room temperature, followed by 2 N HCl for 30 minutes at 37 C, before 60-minute incubation with monoclonal anti-BrdU antibody (1:40; Dakopatts, Copenhagen, Denmark) at 37 C. Labeled nuclei were visualized by peroxidase-labeled rabbit anti-mouse Ig (Dakopatts), followed by diaminobenzidine in combination with 1% cobalt-Cl to enhance staining intensity.

### *Morphometry and Statistical Analysis*

BrdU-labeled nuclei were counted per cm basement membrane. The thickness of the combined nucleated epithelial layers of the interfollicular epidermis, ear, esophagus, and forestomach was measured at 10 sites. From these measurements, the mean thickness was calculated for each epithelium. The density of dermal mast cells was determined in toluidine blue sections as number of cells per mm<sup>2</sup> dermis. The area of the dermis was determined by subtracting the area occupied by pilosebaceous units and blood vessels from the total area of the dermis. The measurements were performed with computer-aided morphometry (Kontron-Videoplan, Zeiss, Germany). All data are expressed as mean  $\pm$  SEM. The statistical significance of observed differences between control animals and affected mice and between treated and untreated mice was determined by Student's *t*-test and one-way analysis of normal variance.

## **Results**

### *Clinical Investigations*

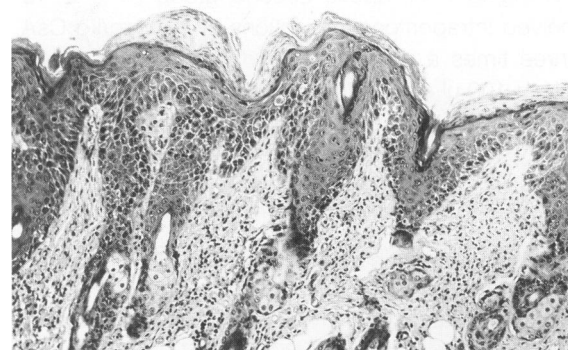
Mice that are affected by the cpd mutation were first identified at 2 weeks after weaning (5 weeks of age)

by the development of hair loss and reddening of the skin of the dorsal neck and ventral chest. The lesions gradually spread to involve most of the skin except for the feet, tail, and ear pinnae, which remained unaffected. This situation had been reached at 12 to 15 weeks of age. The lesions were characterized by erythema, severe hair loss, and mild scaling. The mice showed moderate growth retardation with aging, but otherwise remained vital. However, severe pruritus often caused self-inflicted wounds necessitating euthanasia usually before the age of 30 weeks. Hematological evaluation revealed hematocrits in the normal range and a three-fold increase of polymorphonuclear leukocytes with a regenerative left-shift.

Male and female mice were affected in equal numbers. Attempts to breed cpd mice to other cpd mice failed. Through a selective breeding program, we identified seven clinically unaffected male-female combinations that yielded cpd progeny. From these breeding pairs, a total of 760 mice was obtained, of which 123 (16%) developed cpd skin lesions. These results suggest an autosomal mode of inheritance.

### *Pathology*

The following description is based on complete necropsies of 40 mice (23 male and 17 female) of 6 to 20 weeks of age. Gross examination revealed skin changes as described above and a three- to sixfold increase in the size of the spleen. The interfollicular epidermis of affected skin was thickened (from  $8.8 \pm 0.7 \mu$  to  $55.6 \pm 17.6 \mu$ ; significant at  $P < 0.05$ ) as a result of orthokeratotic hyperkeratosis alternating with parakeratotic mounds, and epidermal hyperplasia (Figure 1). The granular cell layer was slightly thicker or of normal thickness and



**Figure 1.** Hyper- and parakeratosis and acanthosis in the epidermis and inflammatory cell infiltration in the dermis of a cpd mouse (HPS, 104 $\times$ ).

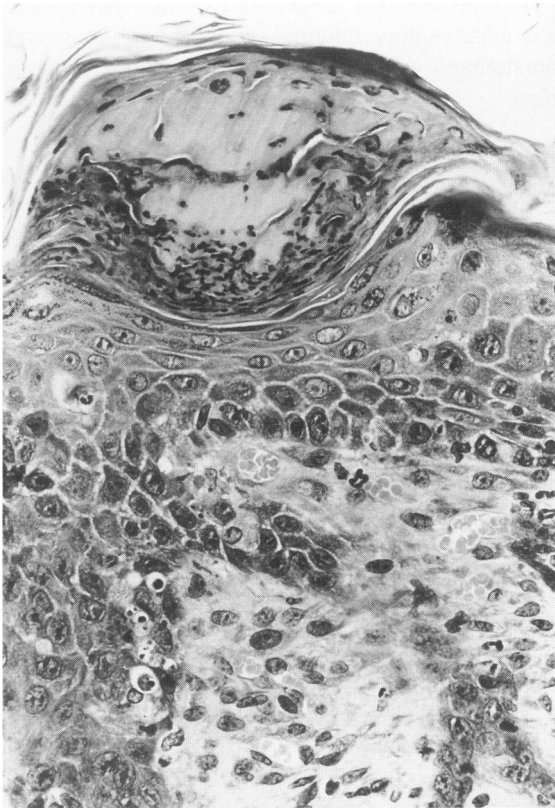


Figure 2. Intracorneal microabscess and single cell death of keratinocytes in the epidermis and blood vessel proliferation in the dermis of a cpd mouse (HPS, 365X).

was absent beneath the parakeratotic mounds. Single cell death of a variable number of keratinocytes was present in the stratum basale and spinosum (Figure 2). There was an increased number of mitotic figures in the basal cell layer. Polymorphonuclear granulocytes were present in the epidermis, and they occasionally formed small spongiform pustules just beneath the stratum corneum. Degenerated granulocytes mixed with parakeratotic mounds and formed microabscesses in the keratotic layer (Figure 2). There was occasionally mild spongiosis of the epidermis. The epidermal changes continued along the hair shafts resulting in follicular keratosis and frequent degeneration of hair shafts. The dermis was infiltrated by a mixed popu-

lation of inflammatory cells, predominantly granulocytes and macrophages. There were tortuous, dilated capillaries in the superficial dermis often associated with mild edema. Special stains for the detection of yeasts and fungi and bacterial cultures of skin samples were consistently negative. The skin of the ears, footpads, tail, and nails were all normal by light microscopy.

The oral cavity, esophagus, and forestomach of the mouse are lined by orthokeratinizing stratified squamous cell epithelium.<sup>6</sup> Similar changes as those in the epidermis were observed to various extents in these epithelia (Table 1). The thickness of the esophageal epithelium was increased from  $38.2 \pm 4.4 \mu$  in normal C57BL/Ka mice to  $75.4 \pm 8.3 \mu$  in cpd mice (significant at  $P < 0.05$ ), and the thickness of the forestomach epithelium was increased from  $34.1 \pm 8.8 \mu$  to  $62.9 \pm 5.8 \mu$  ( $P < 0.05$ ). An exception was parakeratosis, which was only found in the epidermis. The lesions were particularly prominent in the esophagus, which often contained spongiform pustules (Figure 3). The subepithelial connective tissue was infiltrated by polymorphonuclear granulocytes and macrophages.

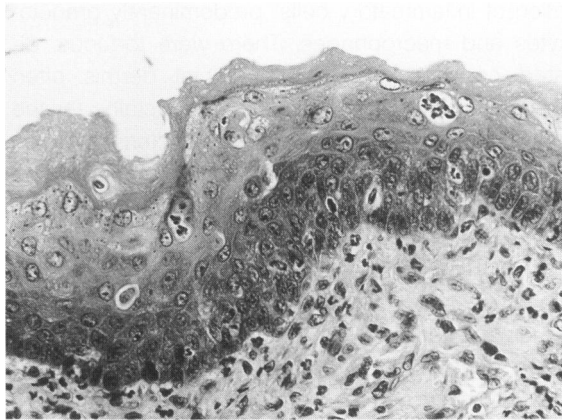
Portal and perivenous areas in the liver were infiltrated by neutrophils and macrophages (Figure 4). Similar, but less conspicuous, changes were present in the perivascular and peribronchiolar connective tissues of the lung. In addition, there was an increased number of eosinophilic alveolar macrophages. There was atrophy of the lymphoid tissues, increasing in severity with age, whereas marked extramedullary myelopoiesis accounted for the enlargement of the spleen. The bone marrow was hyperplastic with extensive myelopoiesis. Synovia and periarticular and peritendinous connective tissues of several mice (17 of 40) were infiltrated by a few or moderate number of macrophages and neutrophils (Figure 5). The synovial space was often mildly dilated and contained a few neutrophils and some proteinaceous material. The coxofemoral, tibiofemoral, and intervertebral joints and the knee tendon were most frequently involved. These lesions were more common in the female (12 of 17

Table 1. Light Microscopic Changes in Orthokeratinizing Stratified Squamous Cell Epithelia of the cpd Mouse

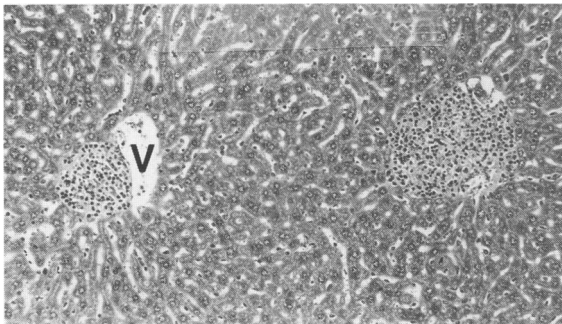
Changes	Skin	Ear	Tail	Footpads	Tongue	Gingiva	Esophagus	Forestomach
Hyperkeratosis	+++*	-	-	-	+	+	+	+
Parakeratosis	++	-	-	-	-	-	-	-
Hyperplasia	+++	-	-	-	+	+	++	++
Single cell death EC†	++	-	-	-	+	+	++	++
Granulocytes	++	-	-	-	+	+	++	+

\* Semiquantitative scoring key: - absent; + mild; ++ moderate; +++ severe.

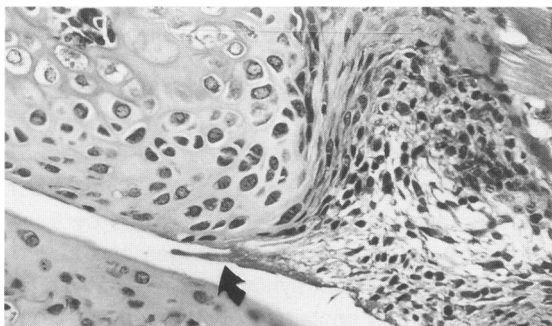
† EC-epithelial cells.



**Figure 3.** Hyperkeratosis, acanthosis, intraepithelial spongiform pustules, and mixed inflammatory cell infiltration in the esophagus of a cpd mouse (HPS, 260 $\times$ ).



**Figure 4.** Liver of a cpd mouse with mixed inflammatory cell infiltration of a portal area and adjacent to a central vein (V) (HPS, 94 $\times$ ).



**Figure 5.** Intervertebral joint of cpd mouse with mixed inflammatory cells in the synovia and perisynovial connective tissue and proteinaceous material in the synovial space (arrow) (HPS, 250 $\times$ ).

affected) than in the male mice (five of 23 affected). There was no evidence of cartilage damage in any of the examined joints. Other tissues were normal.

The lesions in five mice (two male and three female) of 28 to 30 weeks of age were essentially the same as in the younger mice. In the skin, fewer neutrophils were present in the epidermis and dermis. Dendritic cells with small melanin granules appeared in the epidermis and dermis, and heavily laden melanophages were present in the dermis

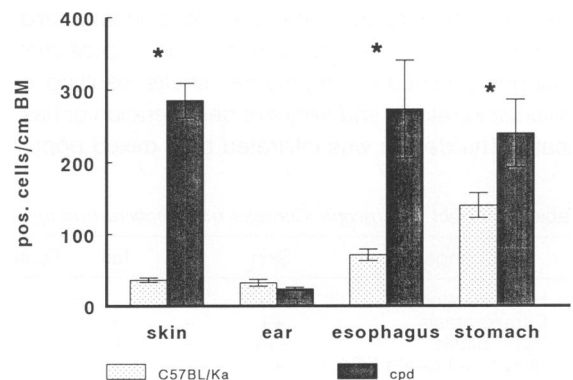
and in the draining lymph nodes. The hyperplastic and inflammatory changes in the esophagus and forestomach were less severe than in the younger mice.

### *BrdU-labeling*

In normal skin, BrdU-labeling was limited to a few basal epidermal cells and hair matrix cells. The number of labeled nuclei was higher in the esophagus and forestomach. BrdU-positive nuclei were greatly increased in number in the basal layer of the epidermis (Figure 6) and the hair follicles of cpd mice. Positive nuclei were also found in suprabasal keratinocytes. A few nuclei of dermal cells, including endothelial cells of dermal capillaries and mast cells, were BrdU-positive in cpd mice. There was also a significant increase of BrdU-positive nuclei in the esophagus and forestomach (Figure 6).

### *Immunohistochemistry*

Ia and NLDC-145 expression in normal skin was limited to Langerhans cells in the epidermis and scattered, poorly defined dendritic cells in the dermis. An increased number of Ia-positive cells was present in the epidermis of cpd mice (Figure 7). They were either round and NLDC-145-negative (macrophages) or dendritic and NLDC-145-positive (Langerhans cells). An increased number of Ia-positive cells was also present in the dermis, but there was no evidence of Ia expression on keratinocytes or endothelial cells. Most leukocytes in the dermis and epidermis were Mac-1-positive (Figure 8) and weakly LFA-1-positive. MEL-14 (L-selectin) reactivity was virtually undetectable in skin sections, although T lymphocytes reacted positively in frozen sections of lymph nodes using the same dilution



**Figure 6.** Number of BrdU-positive cells per cm basement membrane in C57BL/Ka and cpd mice. The bars represent mean  $\pm$  SEM of five mice. \*  $P < 0.05$ .

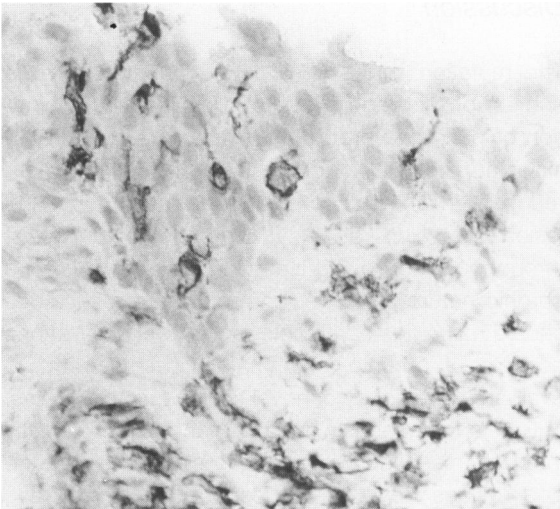


Figure 7. Ia-positive cells in the epidermis and dermis of a cpd mouse (indirect immunoperoxidase with hematoxylin counterstain, 300 $\times$ ).

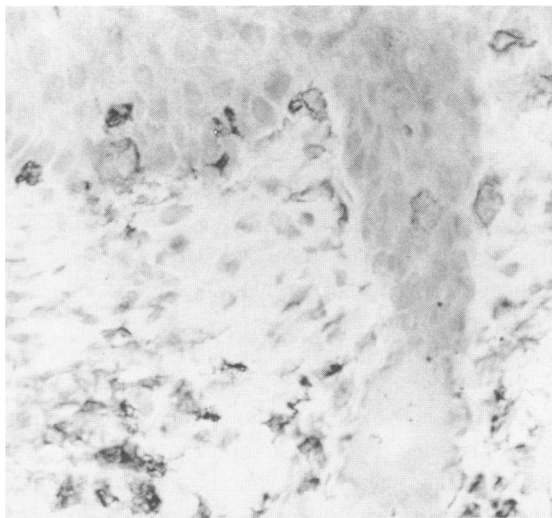


Figure 8. Mac-1-positive cells in the skin of a cpd mouse (indirect immunoperoxidase with hematoxylin counterstain, 300 $\times$ ).

(not shown). CD3-positive cells (T lymphocytes) were occasionally observed in the epidermis and were absent from the dermis of normal syngeneic control mice. Few CD3-positive cells were present in the epidermis and dermis of cpd mice.

ICAM-1 was weakly expressed on endothelial cells of blood vessels in the deep dermis of normal skin. In cpd mice, ICAM-1 was strongly expressed on basal keratinocytes and on endothelial cells of dermal blood vessels (Figure 9). The intensity of staining in the epidermis decreased rapidly toward the stratum corneum. Lack of staining with anti-mouse IgG antiserum indicated that there was no

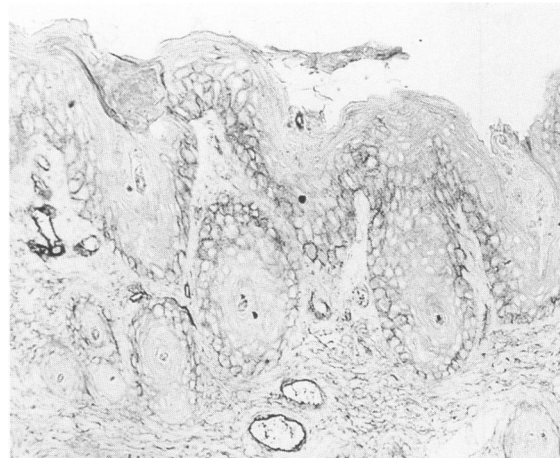


Figure 9. ICAM-1 expression on keratinocytes and endothelial cells in the skin of a cpd mouse (indirect immunoperoxidase with hematoxylin counterstain, 156 $\times$ ).

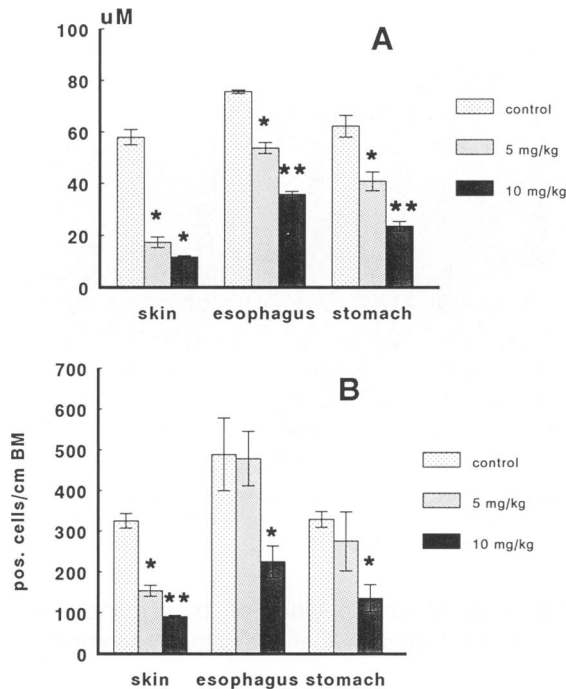
deposition of immunoglobulins or immune complexes in the epidermis and basement membrane.

### Mast Cells

In normal skin, a few mast cells ( $40.6 \pm 7.8/\text{mm}^2$ ) were present in the dermis as revealed by toluidine blue staining. Their number was significantly increased in the affected skin of 6- to 8-week-old cpd mice ( $171.3 \pm 27.1/\text{mm}^2$ ) and even further increased in the 28- to 30-week-old mice ( $594 \pm 110.4/\text{mm}^2$ ). Although the mast cells were often in close apposition to the basal membrane, they were never observed in the epidermis.

### Corticosteroid and CsA Treatment

Systemic treatment of cpd mice with 5 and 10 mg/kg triamcinolone resulted in a considerable improvement within 4 weeks. The skin became much thinner, there was no scaling, and the mice did not appear pruritic. Light microscopically, hyperkeratosis and parakeratosis were mostly absent. The thickness and BrdU incorporation of the epidermis and esophageal and forestomach epithelium were significantly reduced (Figure 10). Single cell death of keratinocytes was only rarely present. Inflammatory cells had disappeared from the epidermis, were markedly reduced in the dermis of mice treated with 5 mg/kg triamcinolone, and virtually absent from the dermis of mice treated with 10 mg/kg. This was confirmed immunohistochemically by the reduced number of cells staining for Ia-positive and Mac-1-positive cells in the 5-mg/kg group and absence of such cells in the 10-mg/kg group. ICAM-1



**Figure 10.** Effect of corticosteroid (triamcinolone) treatment on the epidermal and epithelial thickness (A) and on the number of BrdU-positive cells (B). Bars indicate mean  $\pm$  SEM of four mice. \*  $P < 0.05$  (treatment vs. control), \*\*  $P < 0.05$  (5 mg/kg vs. 10 mg/kg).

expression on keratinocytes was greatly reduced, but still high on endothelial cells in the 5-mg/kg triamcinolone group. ICAM-1 was virtually absent from endothelial cells and keratinocytes in the 10-mg/kg group. Inflammatory lesions in the internal organs (esophagus, forestomach, liver, lung, joints) of the 5-mg/kg group were diminished, and they had completely disappeared in the 10-mg/kg group.

Systemic treatment with 15 and 100 mg/kg CsA for 4 weeks did not result in any noticeable improvement of the skin condition either clinically or histologically, except for increase of hair growth over the affected skin. The latter is a well-established effect of CsA treatment<sup>7</sup> and indicates that the concentration of CsA in the skin had reached adequate levels.

### Hemopoietic Cell Transfer

Injection of a combination of bone marrow cells and spleen cells or a large number of only spleen cells from cpd mice into lethally irradiated or neonatal syngeneic C57BL/Ka mice did not result in the appearance of cpd lesions for up to 2 months after transfer. This indicates that the disease does not result from abnormal function of mature T cells or cells of the myelomonocytic lineage.

### Discussion

The mutation in the C57BL/Ka mouse that is the subject of this report results in a unique combination of proliferative and inflammatory lesions in the skin and proximal digestive tract and inflammatory reactions in a limited number of internal organs. The lesions develop at a young age and persist throughout the allowed lifespan of the animals. The chronic nature of the lesions and their persistence should make this a valuable model to study various aspects of chronic inflammatory disease and to evaluate the efficacy of novel therapeutic strategies.

Both spontaneously occurring and experimentally induced diseases with some resemblance to the cpd lesions have been described in mice. Two mouse mutants with skin lesions characterized by epidermal hyperproliferation and scaling are the asebia (*ab/ab*) and the flaky skin (*fsn/fsn*) mouse. The asebia mouse has hypoplastic sebaceous glands and develops a dermatitis with progressive alopecia and scaling.<sup>8</sup> Rupture of lipid-laden macrophages that have infiltrated the dermis is thought to be the cause of the inflammatory reaction and finally results in epidermal hyperproliferation.<sup>9</sup> The nature of the inflammatory reaction and the time-course of lesion development are clearly different from the cpd mouse. The flaky skin mouse is characterized by progressive hypochromic anemia and hyperproliferative dermatitis.<sup>2</sup> The published information on this mutant is still limited, but it seems to be different from the cpd mouse, because the infiltrating cells are mostly mononuclear and because of the absence of follicular keratosis and single cell death of keratinocytes. Various transgenic mice have been described with proliferative skin lesions.<sup>10-13</sup> The distribution and light microscopy of these lesions do not resemble the skin lesions of the cpd mouse. A diet deficient in essential fatty acids causes dermatitis characterized by hyperproliferation and scaling.<sup>14</sup> However, in contrast to the skin of cpd mice, there is marked hypergranulosis and absence of parakeratosis and single cell death of keratinocytes. Finally, a spontaneous, idiopathic dermatitis occurs in middle-aged and aged mice of the C57BL/6 and related background.<sup>15</sup> Indeed, such dermatitis also occurs in our colony of aged C57BL/Ka mice (HogenEsch and Zurcher, unpublished observations). However, this disease is different from the cpd mutation, as it only emerges in older mice, is more ulcerative in nature, and has a different distribution.

The most common chronic dermatitis in man that is characterized by hyperproliferation of keratinocytes and epidermal infiltration of neutrophils is psoriasis.<sup>16</sup> The pathogenesis of psoriasis has not been resolved and is still the subject of intense research efforts. Virtually every parameter that has been studied was found to be altered, and presumably many of them are epiphenomena.<sup>16,17</sup> Recent studies have focused on the role of T lymphocytes and keratinocytes.<sup>18,19</sup> Autoreactivity of T lymphocytes to some epidermal component may be the initiating event, and these T cells may activate keratinocytes to secrete a variety of cytokines and growth factors.<sup>18</sup> Persistent release of autocrine growth factors and insensitivity to growth-inhibitory factors of keratinocytes may cause hyperproliferation as well as infiltration of neutrophils and dermal inflammation.<sup>19</sup> Still another hypothesis locates the primary defect of psoriasis in fibroblasts.<sup>20</sup> This is based on the observations that fibroblasts from psoriatic lesions, but not from control skin, induce hyperproliferation of keratinocytes under certain experimental conditions.<sup>20,21</sup> The lesions of the cpd mouse differ from psoriatic lesions in several respects, such as the paucity of T lymphocytes in the dermal infiltrate and the presence of follicular keratosis and dyskeratosis. Furthermore, the cpd lesions did not regress upon CsA treatment in contrast to the efficacy of CsA in the treatment of psoriasis. Although the pathogenesis of cpd seems to be different from the pathogenesis of psoriasis, further studies of the cpd mouse may provide data relevant to certain aspects of psoriasis, such as the mechanism of neutrophil infiltration into the epidermis and the role of cytokines and their receptors in the inflammatory process.

Keratinocytes can be induced to secrete a variety of pro-inflammatory cytokines. In this manner, they can elicit an inflammatory reaction in the underlying dermis upon injury.<sup>22</sup> Conversely, proliferation and differentiation of epithelia is, at least in part, determined by the subepithelial mesenchymal tissue, and dermatitis is frequently associated with hyperproliferation of keratinocytes.<sup>23</sup> Thus, the primary cellular component responsible for both abnormal epithelial proliferation and subepithelial inflammation may reside either in the epithelium or in the subepithelial connective tissue. Failure to transfer the cpd lesions using hemopoietic cells from spleen or bone marrow indicates that such cells do not play a primary role in the pathogenesis. It is unlikely that the failure to transfer adoptively the disease with spleen and bone marrow cells was caused by

rejection of the grafted cells. The syngeneic donor-recipient combination obviously does not allow a verification of the chimeric status, but the dose of total body irradiation and the numbers of cells in the graft exclude the possibility of endogenous hemopoietic reconstitution in these experiments.<sup>24</sup> The absence of immunoglobulin deposition in the epidermis or basement membrane, the paucity of T lymphocytes, and the lack of response to CsA further indicate that (auto)immune phenomena are not primary mechanisms in the development of cpd lesions. Skin grafts using cross-recombinations of dermis and epidermis of cpd and syngeneic control mice may determine whether the cell that is primarily responsible for the cpd lesions resides in the dermis or epidermis. Although the skin lesions of the cpd mouse are the most striking and clinically obvious, there were also inflammatory foci in the lungs, liver, and in joint-associated tissues. These lesions could represent secondary phenomena resulting from massive cytokine release from keratinocytes, or they may point toward a generalized systemic condition.

Immunohistochemical studies of cpd mice revealed an increase of Ia-positive cells in the epidermis and lack of Ia expression on keratinocytes. The precise nature of the Ia-positive cells is not known. The round cells in the basal layer lacked the dendritic cell-specific antigen recognized by NLDC-145, suggesting that these cells are not Langerhans cells and are probably macrophages. In psoriasis, an increase of major histocompatibility class II-positive cells has been observed,<sup>25</sup> whereas the number of true Langerhans cells has been reported to be either unaltered<sup>25</sup> or decreased.<sup>26</sup>

Most inflammatory cells in the dermis and epidermis stained strongly for Mac-1 and weakly for LFA-1. This is consistent with these cells being macrophages and neutrophils. Both LFA-1 and Mac-1 are ligands of ICAM-1.<sup>27-29</sup> Increased ICAM-1 expression on keratinocytes and endothelial cells is common in many inflammatory skin diseases<sup>30,31</sup> and was also observed in the cpd lesions. ICAM-1 LFA-1 and ICAM-1 Mac-1 interactions may thus play a role in the infiltration of macrophages and neutrophils in these skin lesions. The expression of ICAM-1 is up-regulated by interferon- $\gamma$ , interleukin-1, and tumor necrosis factor- $\alpha$  (TNF- $\alpha$ ), with combinations of these cytokines often having synergistic effects.<sup>27,32</sup> The absence of Ia expression on keratinocytes and endothelial cells suggests that interferon- $\gamma$  does not play a role in this inflammatory condition, because



interferon- $\gamma$  is the major inducer of Ia expression on these cells.<sup>33,34</sup> This is consistent with the small percentage of T lymphocytes in the inflammatory infiltrate. The gp100 antigen recognized by MEL-14 is present on circulating neutrophils and plays a role in the initial adherence to endothelial cells.<sup>35</sup> Upon adhesion, the MEL-14 antigen is shed from the cell surface, thus permitting the penetration of the endothelium, and extravasated neutrophils consequently have a low expression of MEL-14 antigen.<sup>36</sup> This is consistent with our failure to find positive staining with MEL-14 on the surface of neutrophils in the dermis and epidermis. Studies to evaluate the role of these adhesion molecules in this disease by *in vivo* treatment with monoclonal antibodies are under way.

Single cell death of keratinocytes was variably present and often prominent in the lesions of cpd mice. Single cell death of keratinocytes in combination with mild epidermal hyperplasia is a prominent feature of graft-versus-host disease.<sup>37,38</sup> Similar changes can be induced by subcutaneous infusion of TNF- $\alpha$  in susceptible strains of mice,<sup>39</sup> and, indeed, TNF- $\alpha$  has been shown to be an effector mechanism in graft-versus-host disease.<sup>40</sup> Murine keratinocytes can secrete TNF- $\alpha$  under certain conditions,<sup>41</sup> but we have not been able to detect any TNF- $\alpha$  activity in supernatants of cultured keratinocytes from normal or cpd skin *in vitro* (Gijbels and HogenEsch, unpublished observations). Other possible sources of TNF- $\alpha$  in cpd skin include infiltrating macrophages and dermal mast cells.<sup>42</sup>

We observed an increased number of dermal mast cells. Increased numbers of mast cells have also been reported in idiopathic and experimentally induced chronic dermatitis in C57BL/6-related mice,<sup>43</sup> in asebia mice,<sup>9</sup> and in psoriasis in man.<sup>44</sup> Proliferation of mast cells seems to be a common feature of chronic dermatitis, and these cells may play a role in the pathogenesis of the disease when present in such large numbers. The cpd mice may provide a useful model to gain more insight into the mechanisms regulating dermal mast cell proliferation *in vivo*.

The proliferation and inflammation associated with the cpd mutation were responsive to high-dose corticosteroid treatment. Corticosteroids are strong suppressants of the function of various inflammatory cells, including neutrophils and macrophages, and of the production of several cytokines.<sup>45</sup> The decrease of epithelial thickness after corticosteroid treatment could in part be explained by a decrease of proliferation assessed by BrdU incorporation. The reduced rate of proliferation could be the result of

the attenuation of dermal inflammation, thereby removing the stimulus for epidermal proliferation. In addition, corticosteroids are known to have a direct antiproliferative effect on keratinocytes.<sup>46</sup> Corticosteroids also cause a shrinking of cellular volume of keratinocytes,<sup>47</sup> thus providing an additional explanation for the reduction of epithelial thickness.

In summary, we have described a new mouse mutant with chronic proliferative inflammation of most orthokeratinizing stratified squamous cell epithelia. The skin lesions undergo nearly complete regression upon treatment with corticosteroids for 4 weeks, but do not respond to CsA. This mouse should be a useful model to study chronic inflammatory reactions in general and chronic dermatitis with hyperproliferation of keratinocytes in particular.

### Acknowledgments

The authors thank Drs. F. Takei, G. Kraal, and L. Nagelkerken for providing monoclonal antibodies and Mr. T. Glaudemans for photographic assistance.

### References

1. Darling SM, Abbott CM: Mouse models of human single gene disorders. I: nontransgenic mice. *Bioessays* 1992, 14:359-366
2. Sundberg JP, Beamer WG, Shultz LD, Dunstan RW: Inherited mouse mutations as models of human adnexal, cornification, and papulosquamous dermatoses. *J Invest Dermatol* 1990, 95:625-635
3. Young JM, De Young LM: Cutaneous models of inflammation for the evaluation of topical and systemic pharmacological agents. *Pharmacological Methods in the Control of Inflammation*, New York, Wiley, 1989, pp 215-231
4. Horley KJ, Carpenito C, Baker B, Takei F: Molecular cloning of murine intercellular adhesion molecule (ICAM-1). *EMBO J* 1989, 8:2889-2896
5. Kraal G, Brel M, Janse M, Bruin G: Langerhans' cells, veiled cells, and interdigitating cells in the mouse recognized by a monoclonal antibody. *J Exp Med* 1986, 163:981-997
6. Hummel KP, Richardson FL, Fekete E: *Anatomy. Biology of the Laboratory Mouse*, 2nd ed. Edited by Green EL. New York, McGraw-Hill, 1966, pp 271-280
7. Paus R, Stenn KS, Link RE: The induction of anagen hair growth in telogen mouse skin by cyclosporine A administration. *Lab Invest* 1989, 60:365-369
8. Compton JG, Dunstan RW, Sundberg JP: Asebia, a mutation affecting sebaceous glands, mouse. Integument and mammary glands. *Monographs on Pathology of Laboratory Animals*. Edited by Jones TC, Mohr

- U, Hunt RD, Heidelberg, Springer Verlag, 1989, pp 218–222
9. Brown WR, Hardy MH: A hypothesis on the cause of chronic epidermal hyperproliferation in asebia mice. *Clin Exp Dermatol* 1988, 13:74–77
  10. Vassar R, Fuchs E: Transgenic mice provide new insights into the role of TGF- $\alpha$  during epidermal development and differentiation. *Genes Dev* 1991, 5:714–727
  11. Leonard JM, Abramczuk JW, Pezen DS, Rutledge R, Belcher JH, Hakim F, Shearer G, Lamperth L, Travis W, Frederickson T, Notkins AL, Martin MA: Development of disease and virus recovery in transgenic mice containing HIV proviral DNA. *Science* 1988, 242:1665–1670
  12. Bailleul B, Surani MA, White S, Barton SC, Brown K, Blessing M, Jorcano J, Balmain A: Skin hyperkeratosis and papilloma formation in transgenic mice expressing a ras oncogene from a suprabasal keratin promoter. *Cell* 1990, 62:697–708
  13. Wilson JB, Weinberg W, Johnson R, Yuspa S, Levine AJ: Expression of the BNLF-1 oncogene of Epstein-Barr virus in the skin of transgenic mice induces hyperplasia and aberrant expression of keratin 6. *Cell* 1990, 61:1315–1327
  14. Lowe NJ, Stoughton RB: Essential fatty acid deficient hairless mouse: a model of chronic epidermal hyperplasia. *Br J Dermatol* 1977, 96:155–162
  15. Stowe HD, Wagner JL, Pick JR: A debilitating fatal murine dermatitis. *Lab Anim Sci* 1971, 21:892–897
  16. Leigh IM: Hyperproliferative and immunological diseases of the skin. *The Metabolic and Molecular Basis of Acquired Disease*. Edited by Cohen RD, Lewis B, Alberti KGMM, Denman AM. London, Bailliere Tindall, 1990, pp 1939–1940
  17. Krueger GG: A perspective of psoriasis as an aberration in skin modified to expression by the inflammatory/repair system. *Immune Mechanisms in Cutaneous Disease*. Edited by Norris DA. New York, Marcel Dekker, 1989, pp 425–445
  18. Baker BS, Fry L: The immunology of psoriasis. *Br J Dermatol* 1992, 126:1–9
  19. Nickoloff BJ: The cytokine network in psoriasis. *Arch Dermatol* 1991, 127:871–884
  20. Krueger GG, Jorgensen CM: Experimental models for psoriasis. *J Invest Dermatol* 1990, 95:56S–58S
  21. Saiag P, Coulomb B, Lebreton C, Bell E, Dubertret L: Psoriatic fibroblasts induce hyperproliferation of normal keratinocytes in a skin equivalent model in vitro. *Science* 1985, 230:669–672
  22. Barker JNWN, Mitra RS, Griffiths CEM, Dixit VM, Nickoloff BJ: Keratinocytes as initiators of inflammation. *Lancet* 1991, 337:211–214
  23. Davies MG, Marks R: The dermal drive to epidermopoiesis. *The Epidermis in Disease*. Edited by Marks R, Christophers E. Lancaster, MTP Press Limited, 1981, pp 223–230
  24. Van Bakkum DW, De Vries MJ. Radiation chimeras. London, Academic Press, 1967
  25. Baadsgaard O, Gupta AK, Taylor RS, Ellis CN, Voorhees JJ, Cooper KD: Psoriatic epidermal cells demonstrate increased numbers and function of non-Langerhans antigen-presenting cells. *J Invest Dermatol* 1989, 92:190–195
  26. Bieber T, Braun-Falco O: Distribution of CD1a-positive cells in psoriatic skin during the evolution of the lesions. *Acta Derm Venereol* 1989, 69:175–178
  27. Dustin ML, Springer TA: Lymphocyte function-associated antigen-1 (LFA-1) interaction with intercellular adhesion molecule-1 (ICAM-1) is one of at least three mechanisms for lymphocyte adhesion to cultured endothelial cells. *J Cell Biol* 1988, 107:321–331
  28. Smith CW, Marlin SD, Rothlein R, Toman C, Anderson DC: Cooperative interactions of LFA-1 and Mac-1 with intercellular adhesion molecule-1 in facilitating adherence and transendothelial migration of human neutrophils in vitro. *J Clin Invest* 1989, 83:2008–2017
  29. Diamond MS, Staunton DE, de Fougères AR, Stacker SA, Garcia-Aguilar J, Hibbs ML, Springer TA: ICAM-1 (CD54): a counter-receptor for Mac-1 (CD11b/CD18). *J Cell Biol* 1990, 111:3129–3139
  30. Griffiths CEM, Nickoloff BJ: Keratinocyte intercellular adhesion molecule-1 (ICAM-1) expression precedes dermal T lymphocytic infiltration in allergic contact dermatitis (*Rhus dermatitis*). *Am J Pathol* 1989, 135:1045–1053
  31. Horrocks C, Duncan JJ, Oliver AM, Thomson AW: Adhesion molecule expression in psoriatic skin lesions and the influence of cyclosporin A. *Clin Exp Immunol* 1991, 84:157–162
  32. Barker JNWN, Sarma V, Mitra RS, Dixit VM, Nickoloff BJ: Marked synergism between tumor necrosis factor- $\alpha$  and interferon- $\gamma$  in regulation of keratinocyte-derived adhesion molecules and chemotactic factors. *J Clin Invest* 1990, 85:605–608
  33. Pober JS, Gimbrone MA Jr, Cotran RS, Reiss CS, Burakoff SJ, Fiers W, Ault KA: Ia expression by vascular endothelium is inducible by activated T cells and human  $\gamma$  interferon. *J Exp Med* 1983, 157:1339–1353
  34. Basham TY, Nickoloff BJ, Merigan TC, Morhenn VB: Recombinant gamma interferon induces HLA-DR expression on cultured human keratinocytes. *J Invest Dermatol* 1984, 83:88–90
  35. Butcher EC: Leukocyte-endothelial cell recognition: three (or more) steps to specificity and diversity. *Cell* 1991, 67:1033–1036
  36. Kishimoto TK, Jutila MA, Berg EL, Butcher EC: Neutrophil Mac-1 and MEL-14 adhesion proteins inversely regulated by chemotactic factors. *Science* 1989, 245:1238–1241
  37. Lever WF, Schaumburg-Lever G: *Histopathology of the Skin*, 6th ed. Philadelphia, JB Lippincott Co., 1983, pp 124–125
  38. Zurcher C, Van Bakkum DW: Pathology of radiation chimeras. Bone marrow transplantation. *Biological*

- Mechanisms and Clinical Practice. Edited by Van Bekkum DW, Lowenberg B. New York, Marcel Dekker, Inc., 1985, pp 213–310
39. Piguet PF, Grau GE, Vassalli P: Subcutaneous perfusion of tumor necrosis factor induces local proliferation of fibroblasts, capillaries, and epidermal cells, or massive tissue necrosis. *Am J Pathol* 1990, 136:103–110
  40. Piguet PF, Grau GE, Allet B, Vassalli P: Tumor necrosis factor/cachectin is an effector of skin and gut lesions of the acute phase of graft-versus-host disease. *J Exp Med* 1987, 166:1280–1289
  41. Enk AH, Katz SI: Early molecular events in the induction phase of contact sensitivity. *Proc Natl Acad Sci USA* 1992, 89:1398–1402
  42. Gordon JR, Galli SJ: Mast cells as a source of both preformed and immunologically inducible TNF- $\alpha$ /cachectin. *Nature* 1990, 346:274–276
  43. Galli SJ, Arizono N, Murakami T, Dvorak AM, Fox JG: Development of large numbers of mast cells at sites of idiopathic chronic dermatitis in genetically mast cell-deficient WBB6F<sub>1</sub>-W/W<sup>v</sup> mice. *Blood* 1987, 69:1661–1666
  44. Cox AJ: Mast cells in psoriasis. *Psoriasis*, Second International Symposium. Edited by Farber EM, Cox AJ. New York, Yorke Medical Books, 1977, pp 36–43
  45. Bowen DL, Fauci AS: Adrenal corticosteroids. *Inflammation: Basic Principles and Clinical Correlates*. Edited by Gallin JI, Goldstein IM, Snyderman R. New York, Raven Press, 1988, pp 877–895
  46. Marks R, Pongsehirun D, Saylan T: A method for the assay of topical corticosteroids. *Br J Dermatol* 1973, 88:69–74
  47. Holt PJA, Marks R: The modulating influence of endocrine hormones in epidermal structure and growth. *The Epidermis in Disease*. Edited by Marks R, Christophers E. Lancaster, MTP Press Limited, 1981, pp 235–242