

Detection of HLA-DR Antigens in Paraffin-Embedded Thyroid Epithelial Cells With a Monoclonal Antibody

RICARDO V. LLOYD, MD, PhD,
TERRI L. JOHNSON, MD, MILA BLAIVAS, MD, PhD,
JAMES C. SISSON, MD, and
BARRY S. WILSON, PhD

*From the Departments of Pathology and Internal Medicine,
Division of Nuclear Medicine, The University of Michigan
Medical Center, Ann Arbor, Michigan*

The human Class II major histocompatibility (MHC) antigens, or Ia antigens, which are thought to regulate immune cell interaction, can be detected in paraffin-embedded tissues by immunoperoxidase staining with a recently developed monoclonal antibody (LK8D3). HLA-DR antigens were observed in lymphoid tissues, Langerhans cells of the skin, some epithelial cells, and pulmonary alveolar macrophages. The expression of HLA-DR antigens was analyzed in formalin-paraffin sections by immunoperoxidase in 86 normal and abnormal thyroid epithelial tissues. All patients with Hashimoto's disease (8/8) and most patients with Graves' disease (6/8) expressed HLA/DR antigens in the thyroid epithelial cells and in adjacent inflammatory cells. Most papillary carcinomas (12/18), including 3 of 5 follicular variant of papillary thyroid carcinomas, had HLA-DR antigens detected in epithelial cells; whereas medullary thyroid carcinomas (0/5), follicular carcinomas (0/5), and mul-

tinodular goiters (0/4) did not have detectable HLA-DR immunoreactivity. A few other thyroid lesions had HLA-DR antigens detected in epithelial cells, including anaplastic carcinomas (2/5), Hürthle-cell tumors (1/16), and thyroid lymphomas (2/2). Monoclonal antibody LK8D3 and two other commercially available monoclonal antibodies against HLA-DR-stained tissues equally well in cryostat sections, but only antibody LK8D3 was effective in formalin-fixed paraffin-embedded tissue sections.

These results indicate that epithelial cells from thyroids of patients with autoimmune diseases commonly express HLA-DR antigens. The presence of HLA-DR antigens in most papillary thyroid carcinomas may be helpful diagnostically in cases of follicular variants of papillary carcinomas. The role of HLA-DR expression in autoimmune thyroid disease and in papillary thyroid carcinoma remains to be determined. (*Am J Pathol* 1985, 120:106-111)

THE HUMAN CLASS II major histocompatibility (MHC) antigens, or Ia antigens, are thought to regulate immunologic interaction of immune cells. In humans, Class II MHC antigens are coded for by genes located in the HLA-D region on Chromosome 6. The HLA-D region can be divided into three regions called HLA-DP (formally SB), HLA-DQ (formally DC or DS), and HLA-DR; and all of these regions code for molecules exhibiting the classic bimolecular complex of 34,000 and 28,000 molecular weight glycopolypeptides.^{1,2} Class II MHC antigens are commonly expressed on B-lymphocytes, T-lymphocytes, monocytes, macrophages, Langerhans cells of the skin, dendritic cells in lymph nodes, and endothelial cells.³ Recent studies have suggested that many human epithelial cells, including renal, bronchial, gastrointestinal, and breast cells, and epidermal keratinocytes may also express HLA-DR antigens⁴⁻⁸ The detection of HLA-DR antigens in frozen sections of human tumors has been reported by several investigators, primarily in melanomas.⁹⁻¹³ They have been detected in most cultured melanoma cell

lines^{9,10} and many other human tumors,¹¹ but not in normal skin melanocytes.^{9,10,12,13} Recently, HLA-DR antigens were detected in adenocarcinomas and squamous cell carcinomas of the lung, as well as in melanomas, with the use of paraffin-embedded tissues.¹⁴ These latter studies were made possible by the development of a monoclonal antibody to human HLA-DR antigens (LK8D3) which reacts in both frozen sections and paraffin-embedded tissues.¹⁴ Because of the excellent, morphologic preservation of tissue in paraffin sections, detailed histopathologic studies on the expression of Ia-like antigens in pathologic tissues are now possible.

Supported in part by PHS Grant IK04CA00845-02 (Career Development Award for Dr. Wilson) and a grant from the Children's Leukemia Foundation of Michigan. Address inquiries about antibody LK8D3 to Dr. B. S. Wilson.

Accepted for publication February 27, 1985.

Address reprint requests to Ricardo V. Lloyd, MD, Department of Pathology, The University of Michigan, 1315 Catherine Street, Ann Arbor, MI 48109.

Expression of HLA-DR antigens has been found on thyrocytes in patients with Graves' disease¹⁵ and in one case of Hashimoto's thyroiditis. Normal thyroid tissue which was negative for HLA DR also became positive after stimulation with phytohemagglutinin.^{14,15} These findings suggest that HLA-DR expression may be one of the earliest manifestations of autoimmune thyroid disease. However, a broad spectrum of thyroid tissues, including thyroid neoplasms, has not been previously examined for HLA-DR antigens. In this study we used a monoclonal antibody that detects HLA-DR antigens in formalin-fixed paraffin-embedded tissues to examine a large number of normal and abnormal thyroid tissues, as well as a variety of other tissues, for the expression of HLA-DR antigens. The reactivities in acetone-fixed cryostat and formalin-fixed paraffin sections with antibody LK8D3 are compared. The reactivities of two other commercially available monoclonal antibodies against HLA-DR are also compared with that of LK8D3.

Materials and Methods

Preparation of Monoclonal Antibody LK8D3

Monoclonal antibody LK8D3 was prepared and characterized as previously reported.¹⁴ This antibody has been shown to belong to the IgG class and to react with a bimolecular complex of 34,000 and 28,000 molecular weight polypeptides. Previous immunodepletion studies showed that LK8D3 can react with the HLA-DR class of the Class II MHC antigens.¹⁴ Flow cytometric analysis of the binding of antibody LK8D3 with a variety of cell lines typed for HLA-DP, HLA-DQ, and HLA-DR antigens showed that LK8D3 reacted only with HLA-DR-positive cells (personal communication, Dr. John Pesando, Fred Hutchinson Cancer Research Center, Seattle, Washington).

Immunohistochemical Staining of Tissues

The avidin-biotin complex (ABC) immunoperoxidase method was used, as previously described.¹⁴ Formalin-fixed paraffin-embedded sections cut at 4 μ were dewaxed, then treated with H₂O₂-methanol (1%) for 15 minutes. Cryostat sections were cut at 8 μ and fixed in acetone at 4 C for 10 minutes. After washing in phosphate-buffered saline (PBS), pH 7.2, and treatment with suppressor serum for 10 minutes, the tissues were incubated with 3–5 μ g/ml LK8D3 antibody for 60 minutes, monoclonal HLA-DR at 1/50 (Dako Corp., Santa Barbara, Calif), or I₂ at 1/40 (Coulter, Hialeah, Fla), and then washed in PBS and incubated with biotin-IgG (Vector Laboratories, Burlingame, Calif) for

30 minutes. After PBS washes and incubation in avidin-biotin peroxidase complex (Vector) for 30 minutes, the tissues were treated with diaminobenzidine HCl (20 mg/dl) with 0.05% H₂O₂, washed with distilled water, and counterstained with hematoxylin. Controls for immunohistochemical study consisted of 1) omission of the primary or secondary antibodies and 2) substituting another mouse monoclonal IgG antibody that reacted with lymph node tissues in frozen sections but not in formalin-fixed paraffin-embedded tissue sections in place of the primary antibody.

Tissues

Tissue sections were obtained from the files of the Pathology Department of the University of Michigan. Frozen sections of the following cases were fixed in liquid nitrogen and cut on a cryostat: papillary carcinoma (3 cases), follicular variant of papillary carcinoma, follicular carcinoma, Hürthle cell tumor, Graves' disease, Hashimoto's disease, multinodular goiter (1 case each), and two normal thyroids. Review of patients' charts was done in some cases to confirm the histologic diagnoses of Hashimoto's thyroiditis and Graves' disease. Normal thyroid tissue was obtained from the uninvolved lobes of patients who had total thyroidectomies for thyroid carcinomas (5 cases). In addition, two specimens of normal thyroid tissue were obtained from two autopsy subjects within 4 hours after death who did not have any known thyroid or autoimmune diseases.

Table 1—Distribution of HLA-DR Immunoreactivity Detected by Monoclonal Antibody LK8D3 in Epithelial Cells in Paraffin and Cryostat Sections of Thyroid Tissues

Tissues	Epithelial cell HLA-DR immunoreactivity	
	Paraffin sections	Cryostat sections*
Normal thyroid	0/7	0/2
Multinodular goiter	0/4	0/1
Hashimoto's disease	8/8†	1/1
Graves' disease	6/8§	1/1
Follicular adenoma	0/8	ND
Follicular carcinoma	0/5	0/1
Papillary carcinoma	9/13§	3/3
Follicular variant of papillary carcinoma	3/5‡	1/1
Medullary thyroid carcinoma	0/5	ND
Anaplastic carcinoma	2/5‡	ND
Hürthle cell tumors	1/16‡	1/1
Thyroid lymphomas	2/2†	ND

ND, not done.

* Sections stained with monoclonal antibodies HLA-DR (Dako) and I₂ (Coulter) gave results identical to those of LK8D3 on cryostat sections.

† Diffuse immunoreactivity in greater than 60% of epithelial cells in most cases.

‡ Focal immunoreactivity noted in less than 10% of epithelial cells.

§ Moderate immunoreactivity noted in 10–60% of epithelial cells.

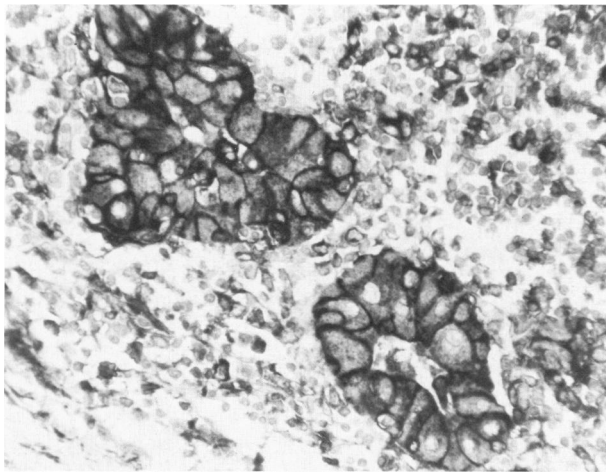


Figure 1—Thyroid tissue from a patient with Hashimoto's disease. Groups of thyroid epithelial cells with Hürthle-cell changes show strong HLA-DR immunoreactivity. Many lymphoid cells are also positive with monoclonal antibody LK8D3. (Immunoperoxidase, $\times 330$)

Definitions of Staining Intensity

The following terms and definitions are used: focal immunoreactivity, less than 10% of cells staining positively; moderate immunoreactivity, between 10% and 60% of cells staining positively; diffuse immunoreactivity, 60% or more of the cells staining positively.

Results

The results of immunostaining of normal and abnormal thyroid tissues are summarized in Table 1. A few cases were excluded because the tissues were judged as unreactive when staining was not observed in cells typically reactive with HLA-DR antibodies, such as inflammatory cells and vascular endothelial cells in

formalin-fixed paraffin-embedded tissues. These included one case of papillary carcinoma, two of follicular carcinomas, one of multinodular goiter, and sections from one specimen of normal thyroid tissue. Lymphocytes in all cryostat sections were reactive with antibody LK8D3. The immunoreactivities with antibodies HLA-DR (Dako) and I_2 (Coulter) were identical to LK8D3 in all 11 frozen sections (Table 1). However, of two formalin-paraffin sections of Hashimoto's disease and one papillary carcinoma that were examined, all gave negative staining with the two other monoclonals but were positive with LK8D3. Reactive cases in paraffin sections included all cases of Hashimoto's disease (8/8) (Figure 1) and most cases of Graves' disease (6/8) (Figure 2), in which positive staining for HLA-DR immunoreactivity was observed on follicular epithelial cells. Interestingly, most papillary thyroid carcinomas (12/18) (Figure 3), including 3 of 5 of these exhibiting the follicular variant of papillary carcinoma (Figure 4), expressed HLA-DR antigens. The staining for HLA-DR was diffuse on the cells of Hashimoto's disease. In Graves' disease and in papillary thyroid carcinomas, staining was focal to moderate. Follicular carcinomas and adenomas gave uniformly negative reactions, as did medullary thyroid carcinomas, normal thyroid tissue, and multinodular goiters. However, the epithelial cells in a few anaplastic carcinomas (2/5), two thyroid lymphomas, and one Hürthle-cell tumor showed focal immunoreactivity for HLA-DR antigens.

The relationship between HLA-DR antigens and the presence of lymphocytic infiltrates in the thyroid is summarized in Table 2. In general, there was a close relationship between the presence of many lymphocytes within the thyroid and the expression of HLA-DR an-

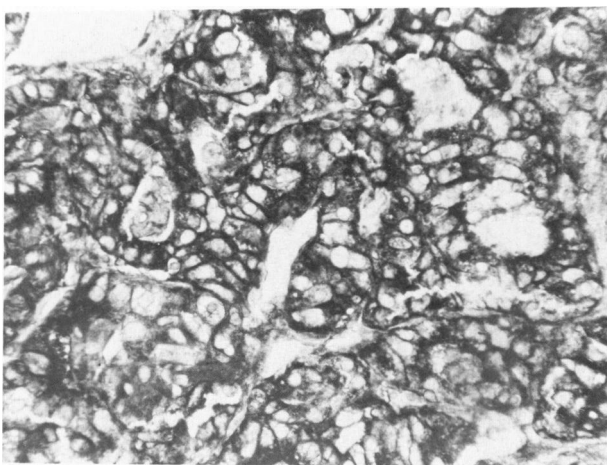


Figure 2—Thyroid tissue from a patient with Graves' disease showing positive immunoreactivity for HLA-DR antigen in most of the epithelial cells. (Immunoperoxidase, $\times 330$)

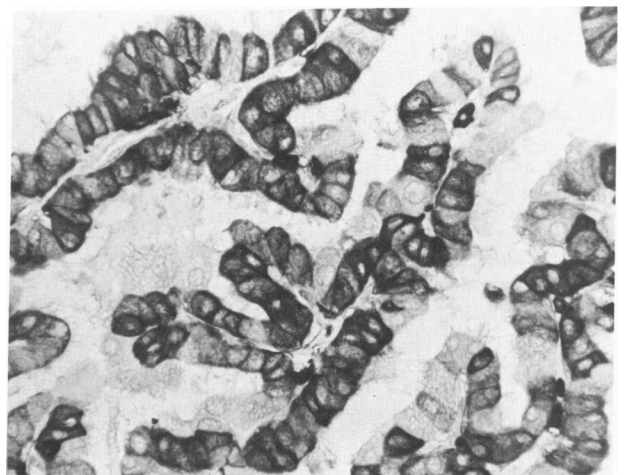

Figure 3—Papillary thyroid carcinoma showing positive immunoreactivity for HLA-DR antigens in many of the tumor cells. (Immunoperoxidase, $\times 330$)

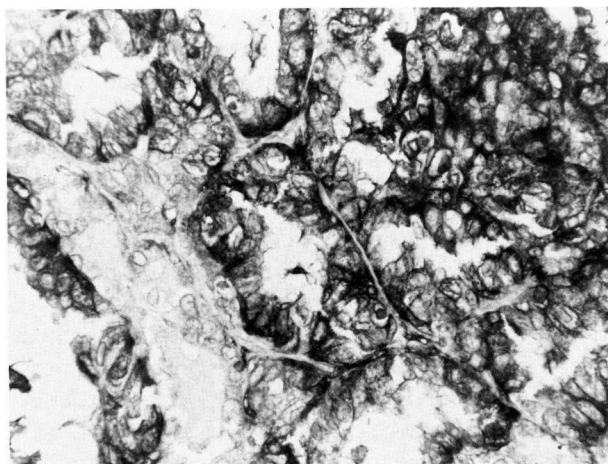


Figure 4—Follicular variant of papillary thyroid carcinoma showing variable HLA-DR immunoreactivity in tumor cells. (Immunoperoxidase, $\times 330$)




Figure 5—Malignant large-cell lymphoma from lymph node stained with monoclonal antibody LK8D3. There is distinct staining for HLA-DR antigens on the cell surface of most of the tumor cells. (Immunoperoxidase, $\times 330$)

tigens. The strongest reactions for HLA-DR antigens were usually seen where lymphocytes were in close proximity to the thyroid epithelial cells. Six follicular adenomas, four normal thyroids, and one multinodular goiter, which exhibited slight lymphocytic infiltrates, ie, less than 10% of the thyroid tissues, contained lymphoid cells without follicular destruction and were all negative for HLA-DR antigens. In addition, several cases of papillary and anaplastic carcinomas, which showed slight lymphocytic infiltrate, had no detectable HLA-DR antigens (Table 2).

The normal nonthyroid tissues, Langerhans cells of the skin, dendritic cells in lymph nodes, vascular endothelial cells, pulmonary alveolar cells, and colonic

epithelial cells, showed variable degrees of immunoreactivity for HLA-DR antigens. Most nonthyroid carcinomas and sarcomas were negative for HLA-DR antigens, but strong focal staining was noted in a vulvar squamous-cell carcinoma and in the Touton giant cells of a juvenile xanthogranuloma. Most lymphomas (4/5) (Figure 5) and all malignant Langerhans cells in eosinophilic granulomas (5/5) gave a diffuse reaction for HLA-DR antigens (Table 3). Some fibroblastic cells stained positively with LK8D3 in paraffin sections and with all three monoclonal antibodies to HLA-DR in the cryostat sections. Sections fixed in B5 stained consistently stronger than formalin-fixed sections with antibody LK8D3, whereas cryostat sections gave the strongest positive immunoreactivity with antibody LK8D3.

Table 2—Relationship Between the Presence of a Chronic Inflammatory Infiltrate and HLA-DR Antigens Detected by Monoclonal Antibody LK8D3 in Thyroid Lesions*

Diagnosis	Percent of cases with lymphocytic infiltrate in thyroid			
	HLA-DR-positive cases†		HLA-DR-negative cases	
	%	Number‡	%	Number‡
Hashimoto's disease	100	8	0	0
Graves' disease	83	5	50	1
Papillary carcinoma	89	8	100	2
Follicular variant of papillary carcinoma	67	2	100	2
Lymphoma	100	2	0	0
Anaplastic carcinoma	50	2	50	2
Hurthle cell tumor	33	1	66	2
Normal thyroid	0	0	57	4
Multinodular goiter	0	0	20	1
Medullary carcinoma	0	0	20	1
Follicular adenoma	0	0	67	6
Follicular carcinoma	0	0	22	2

Discussion

Our results show that HLA-DR antigens can be readily detected in formalin-fixed paraffin-embedded sections of tissues with monoclonal antibody LK8D3. The immunoreactivity is stronger in cryostat sections than in formalin-paraffin sections with antibody LK8D3, whereas positive immunoreactivity was seen only in cryostat sections with two other monoclonal antibodies directed against HLA-DR (Dako and Coulter). The finding of HLA-DR antigens in thyroid epithelial cells in cases of autoimmune thyroiditis such as Graves' and Hashimoto's diseases was not surprising; this has been previously observed in frozen sections of human thyroid tissues.^{16,17} However, the presence of HLA-DR antigens in papillary thyroid carcinomas, both in cryostat and paraffin sections, was unexpected. Abundant lymphocytic infiltrates were correlated with HLA-DR antigens in these neoplasms. However, in addition, other factors must be causative for HLA-DR immunoreac-

* Formalin-fixed paraffin-embedded sections.

† HLA-DR positive in thyroid epithelial cells.

‡ Number of cases with lymphoid infiltrates.

Table 3—Distribution of HLA-DR Immunoreactivity in Formalin-Fixed Paraffin-Embedded Sections of Nonthyroid Human Tissues Detected by Monoclonal Antibody LK8D3

	HLA-DR immunoreactivity
Normal tissues	
Skin—Langerhans cells	3/3*
Lymph node—dendritic cells	5/5*
Skeletal muscle	0/2
Colonic epithelium	2/2†
Pancreatic islet cells	0/2
Lung alveolar cells	5/5*
Parathyroid glands	0/2
Adrenal cortex and medulla	0/3
Pancreatic duct cells	2/2†
Epithelial neoplasms	
Hepatocellular carcinoma	0/2
Pheochromocytomas	0/2
Colon adenocarcinoma	1/3†
Carcinoid tumors	0/2
Gastrinoma	0/2
Renal cell adenocarcinoma	0/2
Vulva—squamous cell carcinoma	1/1†
Prostatic adenocarcinoma	0/2
Neuroblastoma	0/5
Choriocarcinoma	0/2
Breast adenocarcinoma	0/2
Pituitary adenoma	0/2
Malignant melanomas	3/12‡ ¹⁴
Lung carcinomas—squamous	5/8† ¹⁴
Lung adenocarcinoma	3/5* ¹⁴
Other neoplasms	
Lymphomas	4/5*
Granular cell tumor	2/3*
Juvenile xanthogranuloma	1/1†
Malignant fibrous histiocytoma	0/1
Eosinophilic granuloma	5/5‡
Fibrosarcoma	0/1

* Diffuse staining noted in greater than 60% of cells in most cases.

† Focal staining noted in less than 10% of cells in most cases.

‡ Moderate staining noted in 10–60% of cells in most cases.

tivity, because many cases with equal degrees of lymphocytic infiltration exhibited no HLA-DR immunoreactivity. It is not known whether the phenotype of T- and B-lymphocytes within the thyroid directly influences the expression of HLA-DR antigens in thyroid epithelial cells. In one recent study all patients with Graves' disease had an increased percentage and number of circulating Ia⁺ T cells.¹⁸ It has been proposed that these Ia⁺ T cells are related to acute or chronic activation of the immune system. Other investigators have reported that Riedel's thyroiditis had 47% IgA B cells, whereas Hashimoto's thyroiditis had a predominance of IgG B cells (85%) with only 15% IgA cells,¹⁹ indicating differences in the B-cell phenotypes between these two forms of thyroiditis.¹⁹ In previous studies it was also observed that many patients with Hashimoto's thyroiditis had an increase in the HLA-DRW3 antigen in peripheral-blood and bone-marrow-derived B-lymphocytes.²⁰

The autoimmune nature of various thyroid diseases

such as Graves' and Hashimoto's is well known.^{21,22} One common hypothesis is that there may be a defect in T-lymphocyte control in the pathogenesis of autoimmune thyroid disease.² Recent evidence suggests that gamma interferon, an inducer of HLA-DR expression in competent immune cells, induces the synthesis of HLA-DR on normal thyrocytes *in vitro*, and it appears to act preferentially on glands removed from HLA-DR3 individuals.²³ Other studies have shown that stimulation of normal human thyroid cells *in vitro* with the lectin/mitogen leucoagglutinin also resulted in the expression of HLA-DR antigens in these cells.²⁴ The possibility that soluble factors released by lymphocytes, such as interferon, may be the causative agent of HLA-DR expression in papillary thyroid carcinoma, as has been suggested for the HLA-DR expression of normal thyrocytes,²³ is yet to be determined. Although lymphocytic infiltration correlated with HLA-DR expression in our study, this was not always the case. Thus, other unknown factors are probably related to the expression of HLA-DR in thyroid tissues.

The distribution of HLA-DR antigens in nonthyroid tissues in this study was consistent with that in previous studies in which HLA-DR antigens were detected in lymphoreticular cells, Langerhans cells, and some endothelial cells.³ Our previous studies indicated that HLA-DR antigens could be detected by monoclonal antibody LK8D3 in formalin-fixed paraffin-embedded tissues from some melanomas and lung carcinomas.¹⁴ The present study extends the categories of abnormal thyroid lesions that express immunoreactive HLA-DR antigens, particularly in papillary neoplasms derived from thyroid epithelial cells, where HLA-DR antigens are not normally expressed. The presence of HLA-DR antigens in papillary thyroid carcinomas, but not in follicular tumors, should be helpful in distinguishing follicular variants of papillary carcinomas from follicular carcinomas in more difficult diagnostic cases. The ability of monoclonal antibody LK8D3 to react with the majority of formalin-fixed paraffin-embedded tissue sections should also prove to be a useful diagnostic tool. Finally, the presence of HLA-DR antigens in most papillary carcinomas raises many questions about the possible immunologic role of HLA-DR expression in papillary thyroid carcinoma.

References

1. Erlich H, Stetler D, Sheng-Dong R, Saik R: Analysis by molecular cloning of the human class II genes. *Fed Proc* 1984, 43:3025–3030
2. Bodmer J, Bodmer W: *Histocompatibility 1984*. Immunology Today 1984, 5:251–254
3. Winchester RJ, Kunkel HG: The human Ia system. *Adv Immunol* 1979, 28:221–292

4. Wiman, K, Curman B, Forsum, U, Klareskog U, Malnas-Tjernlund L, Tragardh L, Peterson PA: Occurrence of Ia antigens on tissues of non-lymphoid origin. *Nature* 1978, 276:711-713
5. Scott H, Solheim BG, Brandtzaeg P, Thorsby E: HLA-DR antigens in the epithelium of the human small intestine. *Scan J Immunol* 1980, 126:2109
6. Cert-Bensussan N, Quaroni A, Kurnick JT, Bhan AK: Intraepithelial lymphocytes modulate Ia expression by intestinal epithelial cells. *J Immunol* 1984, 132:2244-2252
7. Daynes, RA, Emam M, Krueger GG, Roberts, LK: Expression of Ia antigen on epidermal keratinocytes after the grafting of normal skin to nude mice. *J Immunol* 1983, 130:1536-1539
8. Klareskog L, Forsum U, Peterson PA: Hormonal regulation of the expression of Ia antigen on mammary gland epithelium. *Eur J Immunol* 1980, 10:958-963
9. Wilson BS, Indiveri, F, Pellegrino AM, Ferrone S: DR (Ia-like) antigens on human melanoma cells: Serological detection and immunochemical characterization. *J Exp Med* 1979, 149:658-668
10. Natali PG, Cordiali-Fei P, Cavaliere R, DiFilippo F, Quaranta V, Pellegrino MA, Ferrone S: Ia-like antigens on freshly implanted human melanoma. *Clin Immunol Immunother* 1981, 19:250-259
11. Thompson JJ, Herlyn M, Elder DE, Clark WH, Steplewski Z, Koprowski H: Expression of DR antigen in freshly frozen human tumors. *Hybridoma* 1982, 1:161-168
12. Winchester RJ, Wang C-Y, Gibofsky A, Kunkel HG, Lloyd RD, Old LJ: Expression of Ia-like antigens of cultured human malignant melanoma cell lines. *Proc Natl Acad Sci USA* 1978, 75:6235-6239
13. Houghton AN, Eisinger M, Albio AP, Cairncross JG, Old LJ: Surface antigens of melanocytes and melanomas: Markers of melanocyte differentiation and melanoma subsets. *J Exp Med* 1982, 156:1755-1766
14. Wilson BS, Herzig MA, Lloyd RV: Immunoperoxidase staining for Ia-like antigens in paraffin-embedded tissue from human melanoma and lung carcinoma. *Am J Pathol* 1984, 115:102-108
15. Hanafusa T, Chiovato L, Doniach D, Pujol-Borrell R, Russell RCG, Bottazzo GF: Aberrant expression of HLA-DR antigen on thyrocytes in Grave's disease: Relevance for autoimmunity. *Lancet* 1983, 2:1111-1115
16. Bottazzo GF, Pujol-Borrell R, Hanafusa T: Role of aberrant HLA-DR expression and antigen presentation in induction of endocrine autoimmunity. *Lancet* 1983, ii:1115-1118
17. Pujol-Borrell R, Hanafusa T, Chiovato L, Bottazzo GF: Lectin-induced expression of DR antigen on human cultured follicular thyroid cells. *Nature* 1983, 304:71-73
18. Jackson RA, Haynes BF, Burch WM, Shimizu K, Bowering MA, Eisenbarth GS: Ia⁺T cells in new onset Graves' disease. *S Clin Endocrin Metab* 1984, 59:187-190
19. Harrach HR, Williams ED: Fibrous thyroiditis: An immunopathological study. *Histopathology* 1983, 7:739-751
20. Moeris H, Farid NK: Hashimoto's thyroiditis is associated with HLA-DRw3. *N Engl J Med* 1978, 299:133-134
21. Volpe R: The role of autoimmunity on hypoendocrine and hyperendocrine function with special emphasis on autoimmune thyroid disease. *Ann Intern Med* 1977, 87:86-99
22. Strakosch CR, Wenzel BE, Row VV, Volpe R: Immunology of autoimmune thyroid diseases. *N Engl J Med* 1982, 307:1499-1507
23. Stridaman V, Pacini F, DeGroot LJ: Decreased suppressor T-lymphocytes in autoimmune thyroid diseases detected by monoclonal antibodies. *J Clin Endocrinol Metab* 1982, 54:316-319
24. Canonica GW, Bagnasco M, Cocco ML, Ferrini O, Giardino G: Human T-lymphocyte subpopulations in Hashimoto's disease. *J Clin Endocrinol Metab* 1981, 52:553-556
25. Bottazzo F: HLA-DR expression as a factor in endocrine autoimmune disorders (Abstr.) Seventh International Congress of Endocrinology. July 1-7, 1984 Quebec City, Quebec, Canada
26. Davies TF, Platzer M: Functional consequences of Ia antigen expression on the human thyroid cell surface (Abstr). Sixtieth meeting of the American Thyroid Association. September 19-22, 1984, New York, p T-36, No. 71