

Photochemically induced colonic ischaemic lesions: a new model of ischaemic colitis in rats

Y Yano, H Yao, K Aoyagi, K Kawakubo, S Nakamura, K Doi, S Ibayashi, M Fujishima

Abstract

Background—Recent clinical studies suggest that ischaemic colitis is caused by a microcirculatory disturbance that involves thrombosis of the colon.

Aim—To establish a new model of photochemically induced ischaemic colitis in rats.

Methods—Thirty male Wistar rats were anaesthetised with amobarbital, the femoral veins were cannulated and laparotomies were performed. The serosal surface of the proximal colon was irradiated by using a krypton laser (wavelength 568 nm, 20 mW) for four minutes. An intravenous infusion of a photosensitising dye, rose bengal (20 mg/kg body weight), was administered over 90 seconds, beginning at the start of irradiation. Rats were killed immediately (n=4), 12 hours (n=2), 24 hours (n=10), three days (n=4), seven days (n=4), 14 days (n=2), or 28 days (n=2) after irradiation. Two control rats received laser irradiation without dye infusion. Specimens of the irradiated sites were examined by using histopathology.

Results—Localised ulcers of the colon were present in rats killed at 12 hours, 24 hours, three days, and seven days after irradiation. Microscopy findings were consistent with the features of human ischaemic colitis. Reproducible ulcerative lesions were produced by photothrombosis of microvessels in the colon.

Conclusion—This model may be useful for further investigation of the pathophysiology of ischaemic colitis.

(Gut 1997; 41: 354-357)

Keywords: ischaemic colitis; photothrombosis; rose bengal

Ischaemic colitis, a disease of the large intestine caused by insufficient blood supply, was first recognised as a clinicopathological entity by Boley *et al* and Marston *et al*.¹⁻³ Subsequent clinical studies have suggested that ischaemic colitis is caused by impairment of the microcirculatory flow, at least in part, related to thrombotic occlusion of the vessels in colon, because angiography does not detect the involvement of colonic vessels in all cases. The results of experimental studies using intra-arterial injection of a foreign substance have suggested that occlusions in peripheral small arteries, but not ligations of the major arteries, induce apparent mucosal lesions in the colon.⁴⁻⁶ These studies indicate that a diffuse disturbance in the

microcirculation of the colon produces ischaemic lesions similar to those seen in humans. The infusion of foreign substances into the microcirculation, however, does not accurately reproduce the process of thrombosis. To mimic the clinicopathophysiological conditions of ischaemic colitis more closely, we attempted to induce thrombosis in the colon by using a photochemical method. Thrombus formation has been induced photochemically in microvessels according to the methods originally developed by Watson *et al*.^{7 8}

In this study, we developed a new experimental model of photochemically induced thrombosis of the colon in rats by using the interaction between krypton laser irradiation and infusion of the photosensitising dye, rose bengal.

Methods

ANIMAL PREPARATION

Thirty male Wistar rats (seven to 10 months old, weighing 250 to 400 g) were obtained from the Kyushu Animal Corporation (Tosu, Saga, Japan) and allowed free access to food pellets (CE-2 diet, Clea Japan Inc, Osaka, Japan) and tap water. Rats were anaesthetised with an intraperitoneal injection of 100 mg/kg of amobarbital, and the right femoral vein was cannulated with PE-10 tubing for infusion of a photosensitising dye, rose bengal. A 3 cm incision was made in the mid-lower abdomen, and the ileocaecal portion of the colon was carefully pulled out through the incision.

PHOTOCHEMICALLY INDUCED THROMBOSIS

The exposed colon was irradiated by using a krypton ion laser (Innova 302, Coherent Inc, Santa Clara, CA, USA) tuned to a 568 nm transition as described previously.⁹ The laser beam was positioned on the serosal surface of the colon at the anal side of the caecum using two flat mirrors. The beam was focused with an elliptical 10×2 mm cylindrical lens (CKX050AR.14, Newport Co Ltd, Irvine, CA, USA) with a 5 cm focal length. Rose bengal (disodium tetrachloro-tetraiodofluorescein, Wako Pure Chemical Co Ltd, Osaka, Japan) was injected intravenously at a dose of 20 mg/kg body weight over 90 seconds, beginning with the start of irradiation. The colon was irradiated for four minutes at a power of 20 mW. Two control rats received laser irradiation of the colon without rose bengal infusion. Respiratory movements and colonic peristalsis were negligible and did not affect the irradiation.

Laser-based methods of thrombus formation have the potential to generate local heat.

Faculty of Medicine,
Kyushu University,
Fukuoka, Japan

Y Yano
H Yao
K Aoyagi
K Kawakubo
S Nakamura
K Doi
S Ibayashi
M Fujishima

Correspondence to:
Dr Yuji Yano, Second
Department of Internal
Medicine, Faculty of
Medicine, Kyushu
University, Maidashi 3-1-1,
Higashi-ku, Fukuoka 812-82,
Japan.

Accepted for publication
28 January 1997



Figure 1: Macroscopic findings showing a colonic intraluminal lesion in a laser-irradiated rat at 24 hours. Localised shallow open ulcers with irregular margins are evident.

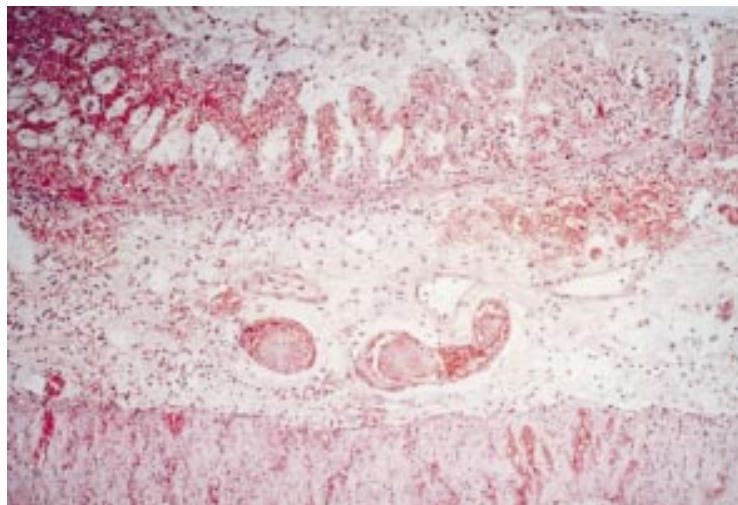


Figure 2: Histological findings of a photochemically induced ulcer of the colon. The ulcer was restricted to the mucosa or submucosa, which showed fresh mucosal haemorrhage, degeneration and necrosis of the glandular epithelium with a "ghost-like" appearance, and notable submucosal thickening caused by prominent oedema, associated with congestion and neutrophilic infiltration.

Therefore, we monitored changes in the temperature of the colonic serosal surface during irradiation in four rats by using a needle-type thermistor probe placed near the irradiated site, and a digital thermometer (PTM-100A-3, Unique Medical, Tokyo, Japan). Body temperature was determined with a rectal thermistor probe. Rectal temperature was maintained $36.0 \pm 1.0^\circ\text{C}$ with a heating lamp placed above the rat.

After the catheter was removed, the wound was closed, and the rats were returned to the housing cage.

MORPHOLOGICAL STUDY

Rats were killed immediately ($n=4$), 12 hours ($n=2$), 24 hours ($n=10$), three days ($n=4$), seven days ($n=4$), 14 days ($n=2$), or 28 days ($n=2$) after laser irradiation under amobarbital anaesthesia. The colon was removed, opened by a longitudinal incision at the non-irradiated side, and pinned on a wax block. The specimen was carefully washed with saline, and any

visible changes in the mucosal surface were recorded. Specimens were fixed in 10% formalin for three days, and then examined macroscopically for intraluminal damage. Specimens were then stained with haematoxylin and eosin, and phosphotungstic acid and haematoxylin (PTAH), and examined by using microscopy.

Results

An intense orange fluorescence, which was observed through laser eye protector glasses YL-300-DYE2 (Yamamoto-Kogaku Co Ltd, Osaka, Japan), was emitted from the irradiated site, beginning about 30 seconds after the start of the rose bengal infusion.

In rats in which the temperature of the colonic serosal surface near the irradiated site was monitored, the temperature remained constant during irradiation ($34.6 \pm 1.1^\circ\text{C}$ v $34.5 \pm 1.4^\circ\text{C}$).

MACROSCOPIC FINDINGS

Macroscopic examination of resected specimens showed localised, shallow, open ulcers with clear margins in all rats killed at 12 hours, 24 hours, three days, and seven days (fig 1). The ulcer size in the irradiated area was approximately 25×4 mm. The macroscopic features of ulcerative lesions of rats killed at seven days were the same as those killed at days 1 or 3. Ulcerative lesions were not present in rats killed immediately, 14 days, and 28 days after laser irradiation.

Two control rats killed 24 hours after irradiation showed no abnormalities in the colon, indicating that irradiation alone in the absence of rose bengal caused no mucosal damage to the colon.

LIGHT MICROSCOPY FINDINGS

Histological examination of the lesions showed that shallow ulcers were restricted to the mucosa or submucosa. Fresh mucosal haemorrhage, degeneration and necrosis of glandular epithelium with a "ghost-like" appearance, and notable submucosal thickening as a result of prominent oedema, associated with congestion and neutrophilic infiltration, were observed readily (fig 2). These findings are consistent with the features of human ischaemic colitis in the acute phase. Some microvessels of the submucosal layer were filled with smooth, pinkish thrombi (fig 3), which were not stained by PTAH, suggesting the absence of a fibrin component (fig 4). The ulcers in rats killed at seven days had regenerative mucosa in addition to the "ischaemic" lesion seen at days 1 or 3, as mentioned earlier. In rats killed at 14 days and 28 days, neither ulcerative lesions nor ulcer scars were observed.

Discussion

Photochemical treatment consistently induced ischaemic lesions in the colons of rats. Localised ulcers in association with obstruction of small arteries by platelet thrombi were present in rats killed 12 hours, 24 hours, three days, or seven days after laser irradiation and intravenous infusion of rose bengal. The pathological findings were similar to those of

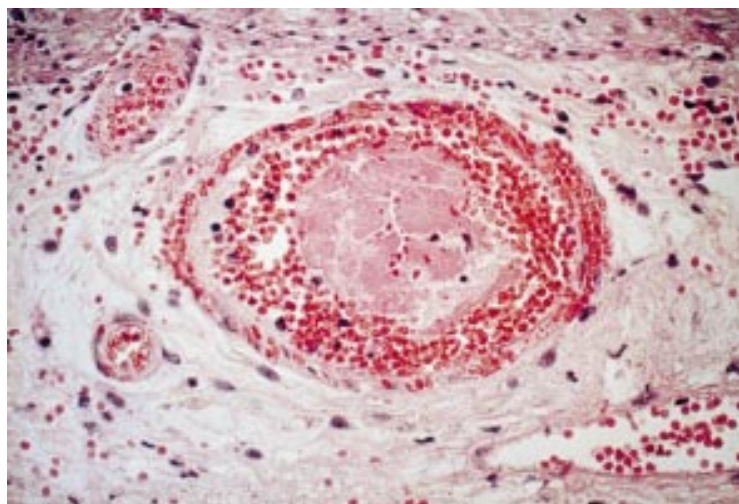


Figure 3: Microscopic findings of an ulcer in the laser-irradiated colon of a rat. The microvessel of the submucosal layer was filled with photochemically induced thrombi.

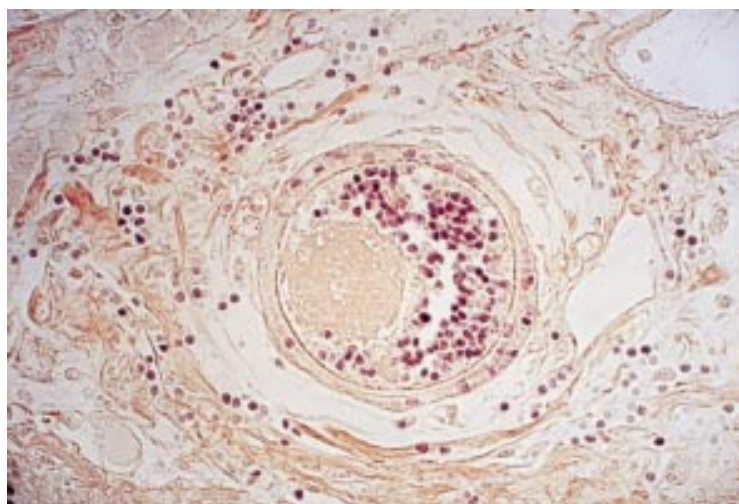


Figure 4: The photothrombi were not stained by PTAH, indicating the absence of a fibrin component.

human ischaemic colitis. Small blood vessels were obstructed with homogenous materials or platelet thrombi.

Reversible vascular occlusion affecting the colon was first described by Boley and colleagues in 1963.¹ Marston *et al* classified this vascular disease of the colon as gangrenous, stricturing, or transient.² They later defined the stricturing and transient forms as ischaemic colitis.³ The clinical features of ischaemic colitis, which is the most frequent cause of ischaemic injury to the gastrointestinal tract, have been elucidated.^{10, 11} Although ischaemic colitis is believed to be caused by ischaemia, or a decreased supply of blood flow to the colon, detectable angiographic abnormalities in the presumably occluded colonic arteries are rare,³ suggesting that ischaemic colitis may be caused by thrombotic occlusion of the microvessels, and not the large vessels of the colon.

Experimental studies in which foreign substances such as microspheres,⁴ microbarium,⁵ and Gelfoam⁶ were infused into the colonic microcirculation in animals have shown that occlusions in microarteries, but not ligation or mechanical occlusion of relatively large arter-

ies, produced mucosal lesions that imitated the clinical features of spontaneous ischaemic colitis. The lesions were enlarged by the reduction in the blood flow of the microcirculation caused by distention of the colon.¹² However, infusion of a foreign substance into the microcirculation of the colon in animals may not reflect the process of thrombosis. Although experimental models of artificial thrombosis have been developed,^{6, 13} no previous animal model of colonic thrombosis has been established because of the difficulty involved in inducing reproducible thrombosis leading to ischaemic lesions in the microcirculation of the colon.

In 1985, Watson *et al* used a photosensitising agent in combination with a selective wavelength of light to produce a thrombotic stroke model.^{7, 8} Although the wavelength of maximum absorption for protein- or membrane-bound rose bengal is 562 nm, the 568 nm krypton line effectively excites intravascular rose bengal and generates singlet oxygen, which peroxidises and damages the endothelium, resulting in notable platelet aggregation and vascular occlusion.⁸ Yao *et al* modified this method and reported a simplified animal model of krypton laser-induced thrombotic cerebral artery occlusion.⁹ This photochemical method consistently produced ischaemic lesions in the colon in the present study. Akiyoshi and Yao *et al* (unpublished observations) investigated a stroke model of cerebral cortical photothrombosis, which is similar to the colonic thrombosis in this study, induced by interaction between variable power (2–20 mW) obtained from a krypton laser and rose bengal (20 mg/kg), and demonstrated that the minimum laser power required to produce macroscopic infarct lesions was about 1.6 mW/mm². For reasons mentioned earlier, we performed this study using a power of 20 mW (about 1.3 mW/mm²) obtained from a krypton laser and rose bengal (20 mg/kg). Under these conditions, temperature changes at the colonic serosal surface at the irradiated site were stable. Histopathological examination of photochemically induced ulcers showed that microvessels of the submucosal layer were filled with platelet thrombi. Furthermore, this ulceration continued for more than seven days, and disappeared within 14 days. We believe that the reversible nature of these ulcers is also consistent with the temporal profile of a transient type of human ischaemic colitis.

In conclusion, reproducible ulcerative lesions were consistently produced by photothrombosis at the level of the microcirculation in the colon. This thrombotic model may be useful for further investigation of the pathophysiology of ischaemic colitis.

An abstract of this study was presented at the 4th United European Gastroenterology Week in Berlin in September 1995. The authors wish to thank Dr Takashi Yao (Second Department of Pathology, Faculty of Medicine, Kyushu University, Fukuoka, Japan) for valuable advice during the course of this study.

1 Boley SJ, Schwartz S, Lash J, Sternhill V. Reversible vascular occlusion of the colon. *Surg Gynecol Obstet* 1963; **116**: 53–60.

- 2 Marston A, Pheils MT, Thomas ML, Morson BC. Ischaemic colitis. *Gut* 1966; **7**: 1–15.
- 3 Marston A. *Intestinal ischaemia*. London: Edward Arnold, 1977.
- 4 Boley SJ, Krieger H, Schultz L, Robinson K, Siew FP, Allen AC, *et al*. Experimental aspects of peripheral vascular occlusion of the intestine. *Surg Gynecol Obstet* 1965; **121**: 789–94.
- 5 Mishima Y, Horie Y. Experimental studies of ischemic enterocolitis. *World J Surg* 1980; **4**: 601–8.
- 6 Mizushima K, Okamura K, Harada K, Hayashi H, Shibata Y, Matsuda T, *et al*. An experimental study of the etiology of ischemic colitis in the digestive tract. *I to Cho (Stomach Intestine)* 1979; **14**: 627–36. (In Japanese with English abstract.)
- 7 Watson BD, Dietrich WD, Busto R, Wachtel MS, Ginsberg MD. Induction of reproducible brain infarction by photochemically initiated thrombosis. *Ann Neurol* 1985; **17**: 497–504.
- 8 Watson BD, Dietrich WD, Prado R, Nakayama H, Kanemitsu H, Futrell N, *et al*. Concepts and techniques of experimental stroke induced by cerebrovascular photothrombosis. In: *Central nervous system trauma: laboratory techniques and recent advancements*. Boca Raton, FL: CRC Press, 1995: 169–94.
- 9 Yao H, Ibayashi S, Sugimori H, Fujii K, Fujishima M. Simplified model of krypton laser-induced thrombotic distal middle cerebral artery occlusion in spontaneously hypertensive rats. *Stroke* 1996; **27**: 333–6.
- 10 Iida M, Matsui T, Fuchigami T, Iwashita A, Yao T, Fujishima M. Ischemic colitis—serial changes in double-contrast barium enema examination. *Radiology* 1986; **159**: 337–41.
- 11 Iida M, Matsui T, Fuchigami T, Iwashita A, Yao T, Fujishima M. Clinical features of nongangrenous ischemic colitis—a comparison of stricturing and transient forms. *J Clin Gastroenterol* 1986; **8**: 635–9.
- 12 Ruf W, Suehiro GT, Suehiro A, Pressler V, Macnamara JJ. Intestinal blood flow at various intraluminal pressures in the piglet with closed abdomen. *Ann Surg* 1980; **191**: 157–63.
- 13 Matsumoto T, Iida M, Nakamura S, Hizawa K, Kuroki F, Fujishima M. An animal model of longitudinal ulcers in the small intestine induced by intracolonic administered indomethacin in rats. *Gastroenterol Jpn* 1993; **28**: 10–7.