

## PAPERS

## Intestinal metaplasia at the squamocolumnar junction in patients attending for diagnostic gastroscopy

N J Trudgill, S K Suvarna, K C Kapur, S A Riley

### Abstract

**Background**—The incidence of adenocarcinoma of the oesophagus and gastric cardia is increasing rapidly. Barrett's oesophagus is the major risk factor. Intestinal metaplasia at the squamocolumnar junction in the absence of Barrett's oesophagus is common but its relation to adenocarcinoma and gastro-oesophageal reflux disease is unclear.

**Aims**—To study the prevalence and clinical, endoscopic, and histological associations of intestinal metaplasia at the squamocolumnar junction.

**Methods**—Biopsy specimens were taken from 120 randomly selected patients undergoing routine diagnostic endoscopy. Eight biopsy specimens, taken from above and below the squamocolumnar junction, gastric fundus, and gastric antrum, were stained with haematoxylin/eosin, alcian blue/periodic acid-Schiff, and Gimenez, and graded independently by one pathologist.

**Results**—Intestinal metaplasia at the squamocolumnar junction was found in 21 patients (18%). Metaplasia was associated with increasing age ( $p < 0.01$ ) and antral intestinal metaplasia ( $p = 0.04$ ). Logistic regression analysis revealed that age was the only independent predictor ( $p < 0.01$ ). There was no association with symptomatic, endoscopic, or histological markers of gastro-oesophageal reflux disease.

**Conclusions**—Intestinal metaplasia at the squamocolumnar junction is a common finding. It is associated with increasing age but not gastro-oesophageal reflux disease.

(Gut 1997; 41: 585–589)

Keywords: intestinal metaplasia; Barrett's oesophagus; gastro-oesophageal reflux disease; oesophagus; gastric cardia; adenocarcinoma

The incidence of adenocarcinoma of the oesophagus and gastric cardia is rising rapidly.<sup>1 2</sup> The major recognised risk factor is Barrett's oesophagus, with 64–86% of all oesophageal adenocarcinomas originating in metaplastic

columnar epithelium.<sup>3 4</sup> Endoscopic follow up of Barrett's oesophagus suggests a cancer risk of between 1 in 48 and 1 in 175 patient years of surveillance.<sup>5</sup>

Barrett's oesophagus is recognised endoscopically by the presence of red gastric-like mucosa extending at least 3 cm above the proximal margin of the gastric folds. The diagnosis is confirmed histologically by finding columnar epithelium. Although gastric and junctional metaplasia may be present, intestinal metaplasia is both more common and more likely to be associated with malignant transformation.<sup>6</sup>

Intestinal metaplasia may also be found in biopsy specimens taken from the tubular oesophagus in patients who have less than 3 cm of red gastric-like mucosa above the proximal margin of the gastric folds. Short segments of intestinal metaplasia at the squamocolumnar junction are considerably more prevalent than conventionally defined Barrett's oesophagus.<sup>7</sup> Although its relative malignant potential is unknown, many cases of oesophageal adenocarcinoma have been reported in association with such segments.<sup>8</sup>

Barrett's oesophagus has a strong association with gastro-oesophageal reflux.<sup>9</sup> Most patients have abnormal acid exposure and many have evidence of oesophagitis or hiatus hernia.<sup>9–11</sup> The relation between short segments of intestinal metaplasia and gastro-oesophageal reflux is however unclear.<sup>7</sup> We have therefore studied patients attending for routine diagnostic endoscopy in order to assess the clinical, endoscopic, and histological associations of this condition.

### Methods

#### SUBJECTS

Patients attending the endoscopy department for routine diagnostic upper gastrointestinal endoscopy were randomly selected and invited to participate. Patients were excluded if they were known to have Barrett's oesophagus, if they had previously undergone endoscopy, or had a history of gastro-oesophageal surgery. Patients taking warfarin, those with oesophageal varices or severe comorbidity, and those requiring therapeutic intervention (for example oesophageal dilatation) were also excluded.

Departments of Gastroenterology and Histopathology, Northern General Hospital, Sheffield, UK

N J Trudgill  
S K Suvarna  
K C Kapur  
S A Riley

Correspondence to:  
Dr S A Riley, Department of Gastroenterology, Northern General Hospital, Sheffield S5 7AU, UK.

Accepted for publication  
23 June 1997

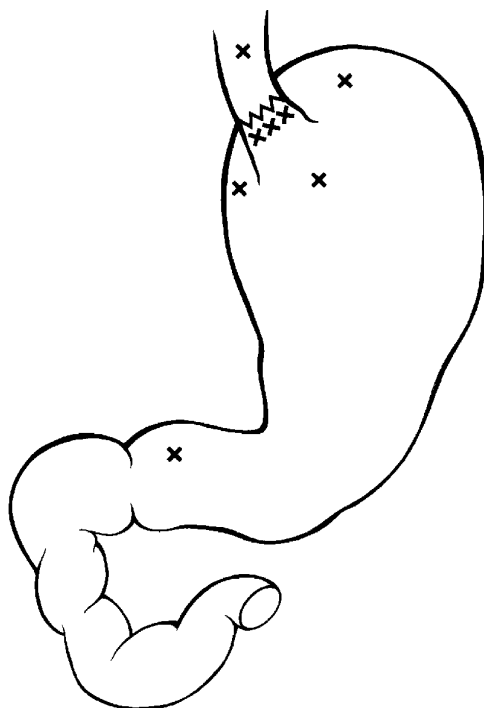


Figure 1: Mucosal biopsy sites.

The study was approved by the Northern General Hospital Ethics Committee and all patients gave written informed consent prior to inclusion.

#### PROTOCOL

Prior to endoscopy, patients were questioned concerning symptoms of gastro-oesophageal reflux and were considered to have reflux symptoms if either heartburn or acid regurgitation was the predominant symptom. Drug therapy, smoking history, and alcohol consumption were also recorded.

Patients underwent routine diagnostic endoscopy. The distances from the patient's incisor teeth to the squamocolumnar junction, proximal margin of the gastric folds, diaphrag-

matic hiatus, and gastric flare were recorded. The squamocolumnar junction was identified as the level of at least 50% of the circumference of the junction between dark red gastric-like and pale pink oesophageal mucosa. The diaphragmatic hiatus was defined as a narrowing of the oesophagus or stomach which varied in diameter and position with respiration and sniffing and the gastric flare was defined as the point where the tubular oesophagus opened out to become the sack-like stomach. A hiatus hernia was considered present when there was a distance of at least 2 cm between the proximal margin of the gastric folds and the diaphragmatic hiatus. Barrett's oesophagus was diagnosed endoscopically when there was 3 cm or more between the squamocolumnar junction and the proximal margin of the gastric folds. Endoscopic oesophagitis was graded as follows: grade 0, normal; grade 1, mucosal erythema; grade 2, non-circumferential mucosal breaks or erosions; grade 3, circumferential erosion.

Eight mucosal biopsy specimens were taken for histological analysis from each patient (fig 1): one from mucosa 2 cm above the squamocolumnar junction; three from mucosa within the tubular oesophagus immediately below the squamocolumnar junction; three, with the endoscope retroflexed, from gastric mucosa 2 cm from the gastric flare; and one from antral mucosa. A ninth biopsy specimen was taken from antral mucosa for urease testing (CLO test).

Biopsy specimens were fixed in 10% buffered formalin, processed, embedded in paraffin wax, and sectioned at 4  $\mu$ m. Each specimen was stained with haematoxylin/eosin and alcian blue/periodic acid-Schiff. All oesophageal and gastric biopsy specimens below the squamocolumnar junction were also stained by the Gimenez method to facilitate the detection of *Helicobacter pylori*.

Sections were examined by one pathologist who had no knowledge of the patients' details or endoscopic findings. Biopsy specimens were scored for the presence of acute and chronic inflammation (0/+ /++ /+++), intestinal metaplasia (+/-), dysplasia (+/-), and *H pylori* infection (+/-). Reflux oesophagitis was diagnosed histologically on finding the combination of intraepithelial neutrophils or eosinophils, basal cell hyperplasia, and spongiosis. Intestinal metaplasia was recognised as the phenotypic change from gastric type columnar epithelium to that of an intestinal morphology. Since intestinal metaplasia is a heterogeneous entity,<sup>12</sup> we chose to score the presence of intestinal metaplasia only if goblet cells containing acidic mucins were identified (fig 2).

#### STATISTICAL ANALYSIS

The  $\chi^2$  test was used to compare discontinuous data and the Mann-Whitney U test to compare continuous data. Multivariate logistic regression analysis was performed to detect independent predictors of the presence of intestinal metaplasia at the squamocolumnar junction.

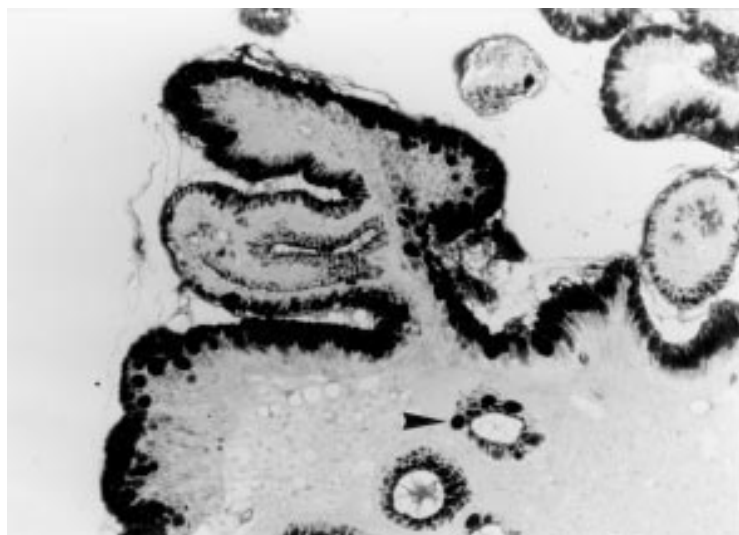


Figure 2: Columnar lined mucosa in biopsy specimens from the oesophagus immediately below the squamocolumnar junction showing goblet cells with alcian blue positive mucin (intestinal metaplasia). Alcian blue/periodic acid-Schiff; original magnification  $\times 100$ .

TABLE 1 Relation between intestinal metaplasia at the squamocolumnar junction and features of gastro-oesophageal reflux disease

	Intestinal metaplasia at squamocolumnar junction (n=21)	No intestinal metaplasia at squamocolumnar junction (n=96)	Significance
Reflux symptoms	8 (38%)	42 (44%)	NS
Endoscopic oesophagitis (grade 2 or 3)	2 (10%)	13 (14%)	NS
Hiatus hernia	3 (14%)	16 (17%)	NS
Histological features of reflux oesophagitis	0	8 (8%)	NS

TABLE 2 Clinical and histological associations of intestinal metaplasia at the squamocolumnar junction

	Intestinal metaplasia at squamocolumnar junction (n=21)	No intestinal metaplasia at squamocolumnar junction (n=96)	Significance
Age (years)	61 (29–90)	51 (22–83)	p<0.01 (95% CI 4 to 18 years)
Sex (male)	8 (38%)	41 (43%)	NS
Smokers	5 (24%)	30 (31%)	NS
Excess alcohol consumption	3 (14%)	8 (8%)	NS
Regular NSAID or aspirin consumption	5 (24%)	7 (7%)	p=0.06 (95% CI –2% to 36%)
Acute gastritis	10 (48%)	34 (35%)	NS
Chronic gastritis	20 (95%)	73 (76%)	NS
Fundal intestinal metaplasia	2 (10%)	2 (2%)	NS
Antral intestinal metaplasia	5 (24%)	6 (6%)	p=0.04 (95% CI –1% to 37%)
<i>Helicobacter pylori</i> infection	12 (57%)	39 (41%)	NS

\*Excess alcohol consumption was defined as more than 21 units per week for men and more than 14 for women.

## Results

Between 26 June 1995 and 14 August 1996, 183 patients were invited to participate in the study. Twenty four patients declined and a further 39 failed to meet the inclusion criteria. Three patients (2.5%) had endoscopic evidence of Barrett's oesophagus and biopsy specimens from below the squamocolumnar junction revealed intestinal metaplasia confirming the diagnosis. These patients were excluded from further analysis.

Of the 117 patients remaining (aged 22–90 years), 49 were men; 114 patients were white, two were black, and one was Asian. Fifty (43%) had reflux symptoms, 63 (54%) had non-reflux dyspepsia, and four (3%) were being investigated solely for anaemia or weight loss. Thirty seven (32%) had endoscopic evidence of oesophagitis, 41 (35%) gastritis, one (1%) gastric ulcer, 12 (10%) duodenal ulcer, and nine (8%) duodenitis. One patient had a squamous carcinoma of the oesophagus.

The distance between the proximal margin of the gastric folds and the squamocolumnar junction was 0 to <1 cm in 72 patients (61%), 1 to <2 cm in 35 (30%), and 2 to <3 cm in 10 (9%).

After processing, seven biopsy specimens from above the squamocolumnar junction and one antral biopsy specimen were inadequate for histological analysis. Twenty one patients (18%) had intestinal metaplasia within the tubular oesophagus below the squamocolumnar junction. In seven patients (33%) the abnormality was present in more than one of the three biopsy specimens. The prevalence of metaplasia increased from 20% to 30% as the distance from the proximal margin of the gastric folds to the squamocolumnar junction increased from less than 1 cm to between 2 and 3 cm. However, this difference was not statistically significant. One patient had low grade dysplasia.

Table 1 summarises the relation between intestinal metaplasia at the squamocolumnar junction and features of gastro-oesophageal

reflux disease. Intestinal metaplasia was not associated with symptomatic reflux, endoscopic signs of oesophagitis or hiatus hernia, or histological evidence of reflux oesophagitis.

Table 2 summarises the clinical and histological associations of patients with intestinal metaplasia at the squamocolumnar junction. Patients with intestinal metaplasia were older than those without metaplasia and were more likely to consume regularly aspirin or other non-steroidal anti-inflammatory drugs (NSAIDs). There was no difference in the prevalence of smoking or excessive alcohol intake. Intestinal metaplasia in the gastric antrum was four times more likely in patients with metaplasia at the squamocolumnar junction. However, intestinal metaplasia in the upper stomach close to the gastric flare was uncommon in both groups. In total 50 patients (43%) had a positive antral urease test and 51 (44%) had histological evidence of *H. pylori* infection (46 in the gastric antrum, 49 in the gastric fundus, and 44 below the squamocolumnar junction). There was no evidence of an association between intestinal metaplasia at the squamocolumnar junction and *H. pylori* infection.

Logistic regression analysis revealed that age was the principal predictor of intestinal metaplasia at the squamocolumnar junction (p<0.01). Allowing for age, the presence of antral intestinal metaplasia was of borderline significance (p=0.07) and regular aspirin or other NSAID consumption was not an independent predictor.

## Discussion

Although there have been no systematic studies of the anatomical site of transition from gastric to oesophageal mucosa, it is widely held that gastric columnar epithelium may extend at least 2 cm into the distal tubular oesophagus.<sup>13</sup> This has led to difficulties in diagnosing short segments of columnar metaplasia in the lower oesophagus, particularly in patients with hiatus hernia or oesophagitis, when endoscopic

landmarks may be less clear. To avoid a false positive diagnosis of Barrett's oesophagus, arbitrary criteria have been set for a minimum length of columnar lining within the tubular oesophagus, with 3 cm being popular.

The columnar lined oesophagus is composed of one or a combination of epithelial cell types: gastric fundic, junctional, or specialised intestinal metaplasia.<sup>10</sup> Gastric fundic and junctional are virtually indistinguishable from normal gastric epithelium causing further diagnostic difficulties. Intestinal metaplasia, however, with its characteristic goblet cells, is both easily recognised and pathological in the lower oesophagus and has therefore become widely accepted as a diagnostic criterion for Barrett's oesophagus.<sup>9</sup>

The prevalence of Barrett's oesophagus in unselected dyspeptic patients presenting for endoscopy is approximately 1%.<sup>14</sup> However, intestinal metaplasia at the squamocolumnar junction in patients who have less than 3 cm of red mucosa above the proximal margin of the gastric folds is far more common. In the present study, 18% of patients had intestinal metaplasia and similar prevalence rates have been reported by others.<sup>7 15</sup>

Although Barrett's oesophagus is strongly associated with gastro-oesophageal reflux,<sup>9</sup> studies of the association between intestinal metaplasia at the squamocolumnar junction and reflux have yielded conflicting data. Spechler *et al* reported an association with histological evidence of reflux, but no association with endoscopic oesophagitis or reflux symptoms.<sup>7</sup> Johnston *et al* found heartburn and regurgitation to be more common in patients with intestinal metaplasia, but found no difference in the frequency of endoscopic or histological oesophagitis.<sup>15</sup> In the present study, we found no association with reflux symptoms, hiatus hernia, endoscopic signs of oesophagitis, or histological markers of reflux disease.

It is worth noting that our study population had a lower prevalence of symptomatic, endoscopic, and histological markers of reflux disease than did those of both Spechler *et al* and Johnston *et al*.<sup>15</sup> In part this may reflect selection bias and in part differences in diagnostic criteria. We considered patients to have reflux symptoms only if acid regurgitation or heartburn was the predominant symptom. This has a high specificity for reflux disease as defined by ambulatory pH monitoring.<sup>16</sup> Furthermore, basal cell hyperplasia and increased rete pegs are difficult to interpret in pinch biopsy specimens,<sup>17</sup> with considerable intraobserver variation.<sup>18</sup> We have therefore required the presence of intraepithelial polymorph leucocytes for a histological diagnosis of reflux oesophagitis.<sup>19</sup> Thus, although we did not undertake 24 hour pH studies, it seems unlikely that acid gastro-oesophageal reflux is a predominant factor in the development of intestinal metaplasia at the squamocolumnar junction, in the absence of endoscopic evidence of Barrett's oesophagus.

The prevalence of both Barrett's oesophagus and intestinal metaplasia within the stomach

increases with age.<sup>14 20</sup> It is therefore not surprising that patients with intestinal metaplasia at the squamocolumnar junction are older than those without metaplasia. The importance of age is emphasised as it was the only independent predictor of the presence of intestinal metaplasia identified by logistic regression analysis. Others have found an association with age,<sup>21</sup> but this has not been a universal finding,<sup>7 15</sup> and may reflect selection bias.

Antral intestinal metaplasia was four times more frequent in patients with intestinal metaplasia at the squamocolumnar junction. A link with metaplasia in the upper part of the stomach was not established, but was an uncommon finding in both groups. Weston *et al* also found an association with intestinal metaplasia in the gastric body or antrum.<sup>21</sup> The reason for this association is not clear, but may represent common aetiological factors.

Aspirin and other NSAIDs often cause reactive gastritis,<sup>22</sup> and may be associated with intestinal metaplasia,<sup>23</sup> but regular ingestion of these drugs was not an independent predictor of intestinal metaplasia at the squamocolumnar junction. Similarly, *H pylori* infection, frequently associated with intestinal metaplasia within the stomach,<sup>20</sup> was not associated with metaplasia at the squamocolumnar junction. Preliminary reports from two other groups have also failed to find an association.<sup>24 25</sup> A correlation between bile reflux and the prevalence and severity of intestinal metaplasia within the stomach is well established.<sup>26</sup> Since bile reflux has also been implicated in the pathogenesis of Barrett's oesophagus,<sup>9</sup> its relation to intestinal metaplasia at the squamocolumnar junction merits further study.

This study confirms that intestinal metaplasia is common at the squamocolumnar junction, but has cast doubt on its association with gastro-oesophageal reflux. The causes of intestinal metaplasia at the squamocolumnar junction thus remain obscure and it may well represent the histological response to many different insults. Although the malignant potential of this condition is unknown, it is likely to be low, as metaplasia is common and adenocarcinoma relatively rare in patients without Barrett's oesophagus. However, there is clearly a need for long term follow up in order to quantify this risk.

Finally, the term "short segment Barrett's oesophagus" has been used by some when intestinal metaplasia is found in patients with less than 3 cm of columnar mucosa above the proximal margin of the gastric folds. However, since this implies both a common aetiology (gastro-oesophageal reflux) and an increased risk of oesophageal adenocarcinoma, we would caution against the use of this term until such links are proven.

These data have been published in abstract form and were presented to the British Society of Gastroenterology in September 1996. We gratefully acknowledge the financial support of the Astra Foundation.

- 1 Powell J, McConkey CC. Increasing incidence of adenocarcinoma of the gastric cardia and adjacent sites. *Br J Cancer* 1990; **62**: 440-3.
- 2 Blot WJ, Devesa SS, Kneller RW, Fraumeni JF. Rising incidence of adenocarcinoma of the esophagus and gastric cardia. *JAMA* 1991; **265**: 1287-9.

- 3 Haggitt RC, Tryzelaar J, Ellis FH, Colcher H. Adenocarcinoma complicating columnar epithelium-lined (Barrett's) esophagus. *Am J Clin Pathol* 1978; **70**: 1-5.
- 4 Hamilton SR, Smith RRL, Cameron JL. Prevalence and characteristics of Barrett esophagus in patients with adenocarcinoma of the esophagus or esophagogastric junction. *Hum Pathol* 1988; **19**: 942-8.
- 5 Wright TA, Gray MR, Morris AI, Gilmore IT, Ellis A, Smart HL, et al. Cost effectiveness of detecting Barrett's cancer. *Gut* 1996; **39**: 574-9.
- 6 Spechler SJ, Goyal RK. The columnar-lined esophagus, intestinal metaplasia and Norman Barrett. *Gastroenterology* 1996; **110**: 614-21.
- 7 Spechler SJ, Zeroogian JM, Antonioli DA, Wang HH, Goyal RK. Prevalence of metaplasia at the gastro-oesophageal junction. *Lancet* 1994; **344**: 1533-6.
- 8 Schnell TG, Sontag SJ, Chejfec G. Adenocarcinomas arising in tongues or short segments of Barrett's esophagus. *Dig Dis Sci* 1992; **37**: 137-43.
- 9 Champion G, Richter JE, Vaezi MF, Singh S, Alexander R. Duodenogastroesophageal reflux: relationship to pH and importance in Barrett's esophagus. *Gastroenterology* 1994; **107**: 747-54.
- 10 Paull A, Trier JS, Dalton MD, Camp RC, Loeb P, Goyal RK. The histologic spectrum of Barrett's esophagus. *N Engl J Med* 1976; **295**: 476-80.
- 11 Burgess JN, Payne WS, Andersen HA, Weiland LH, Carlson HC. Barrett esophagus: the columnar-epithelial-lined lower esophagus. *Mayo Clin Proc* 1971; **46**: 728-34.
- 12 Morson BC, Dawson IMP, Day DW, Jass JR, Price AB, Williams GT. *Morson and Dawson's gastrointestinal pathology*. Oxford: Blackwell Scientific Publications, 1990; 94-119.
- 13 Hayward J. The lower end of the oesophagus. *Thorax* 1961; **16**: 36-41.
- 14 Cameron AJ, Lomboy CT. Barrett's esophagus: age, prevalence and extent of columnar epithelium. *Gastroenterology* 1992; **103**: 1241-5.
- 15 Johnston MH, Hammond AS, Laskin W, Jones DM. The prevalence and clinical characteristics of short segments of specialised intestinal metaplasia in the distal esophagus on routine endoscopy. *Am J Gastroenterol* 1996; **91**: 1507-11.
- 16 Klausner AG, Schindlbeck NE, Muller-Lissner SA. Symptoms in gastro-oesophageal reflux disease. *Lancet* 1990; **335**: 205-8.
- 17 Kobayashi S, Kasugai T. Endoscopic and biopsy criteria for the diagnosis of esophagitis with a fiberoptic esophagoscope. *Am J Dig Dis* 1974; **19**: 345-52.
- 18 Adami B, Eckardt VF, Paulini K. Sampling error and observer variation in the interpretation of esophageal biopsies. *Digestion* 1979; **19**: 404-10.
- 19 Goldman H, Antonioli DA. Mucosal biopsy of the esophagus, stomach, and proximal duodenum. *Hum Pathol* 1982; **13**: 423-48.
- 20 Craanen ME, Dekker W, Blok P, Ferwerda J, Tytgat GNJ. Intestinal metaplasia and Helicobacter pylori: an endoscopic bioptic study of the gastric antrum. *Gut* 1992; **33**: 16-20.
- 21 Weston AP, Krmpotich P, Makdisi WF, Cherian R, Dixon A, McGregor DH, et al. Short segment Barrett's esophagus: clinical and histological features, associated endoscopic findings and association with gastric intestinal metaplasia. *Am J Gastroenterol* 1996; **91**: 981-6.
- 22 Quinn CM, Bjarnason I, Price AB. Gastritis in patients on non-steroidal anti-inflammatory drugs. *Histopathology* 1993; **23**: 341-8.
- 23 Dixon MF. Progress in gastric cancer. In: Kirkham N, Hall P, eds. *Progress in pathology volume 1*. Edinburgh: Churchill Livingstone, 1995; 13-29.
- 24 Heier SK, Seif F, Webber S, Bannan M, Khan N, Pathapati S, et al. Short segment Barrett's esophagus: clinical and histologic findings [abstract]. *Gastroenterology* 1996; **110**: A132.
- 25 Nandurkar S, Ng T, Adams S, Brooks L, Keegan A, Cox M, et al. Short segment Barrett's esophagus: prevalence, diagnosis and associations [abstract]. *Gastroenterology* 1996; **110**: A207.
- 26 Sobala GM, O'Connor HJ, Dewar EP, King RFG, Axon ATR, Dixon MF. Bile reflux and intestinal metaplasia in gastric mucosa. *J Clin Pathol* 1993; **46**: 235-40.