

CASE REPORT

Right atrial myxoma mistaken for recurrent pulmonary thromboembolism

D L Jardine, D L Lamont

Abstract

A 69 year old man was admitted for investigation of right sided pleuritic chest pain and dyspnoea, both of which began suddenly four days before admission. Acute pulmonary embolism was diagnosed. Six months after discharge while on warfarin he died. Necropsy found a 50 mm diameter myxoid tumour arising on the right atrial side of the interatrial septum. This lesion may have been discovered earlier by echocardiography although there were no clear indications for this investigation. Presentation was that of recurrent pulmonary embolism with no obvious source or cause of thrombosis. Patients who are thought to have idiopathic pulmonary embolism should undergo early echocardiography to exclude the rare but treatable diseases of the right heart that may be responsible

(Heart 1997;78:512-514)

Keywords: atrial myxoma

A 69 year old man was admitted for investigation of right sided pleuritic chest pain and dyspnoea, both of which began suddenly four days before admission. Two years earlier he had been admitted with a left pneumonitis and was treated with antibiotics. Serial chest *x* rays then documented left basal consolidation but blood and sputum cultures were negative and recovery was protracted.

The patient was a retired carpet layer, a previous smoker (15 pack-years), and maintained an alcohol intake of 400 g per week.

On examination he was peripherally cyanosed, feverish (37.5°C) with a respiratory rate of 30 per minute, blood pressure was 130/76 mm Hg, and pulse 84 beats/min. Jugular venous pressure was 4 cm above the sternal angle, heart sounds were normal, there were no murmurs or rubs, and there was dullness with inspiratory crackles at the right base. Chest radiography demonstrated mild cardiomegaly and new right lower lobe patchy changes, the ECG was normal, arterial blood gases were consistent with hypoxia (PO₂ 64, PCO₂ 31 mm Hg breathing air), liver function tests were disordered (alkaline phosphatase 213, γ

glutamyl transferase 215 U/l), and neutrophils were raised (16.4 $\times 10^9/l$). He was initially treated with intravenous antibiotics but on day 3 developed minor haemoptyses. A ventilation perfusion lung scan demonstrated multiple, moderately sized segmental and subsegmental areas of mismatch in both lungs (fig 1). Acute pulmonary thromboembolism was diagnosed, there were no signs of deep vein thrombosis. Because there were no apparent risk factors for this condition, he underwent standard testing for disorders of anticoagulation that revealed a normal platelet count (203 $\times 10^9/l$), minor prolongation of activated partial thromboplastin time (45 seconds) and prothrombin ratio (1.2), mildly raised fibrinogen (5.7 g/l), and a reduced serum plasminogen assay (58% of normal adult range). Antinuclear antibody titre was 320 (nucleolar pattern), anticardiolipin antibodies were low positive (14 GPL units), and no lupus inhibitor was detected. The possibility of an underlying coagulopathy was considered and he was treated with full dose subcutaneous low molecular weight heparin followed by long term warfarin. His fever and symptoms settled over 10 days and he was discharged. When reviewed three months later he reported a satisfactory exercise tolerance and cardiorespiratory examination was unremarkable.

Six months after his recovery, while he was still on monitored warfarin, he suffered an out of hospital cardiac arrest and was found by ambulancemen to be in electromechanical dissociation. Resuscitation attempts were unsuccessful and a subsequent necropsy found a 50 mm diameter myxoid tumour arising on the right atrial side of the interatrial septum (fig 2). The lesion was situated approximately 20 mm above and beyond the ostium of the right coronary sinus. There was extensive tumour occluding the proximal left pulmonary artery and the right lung contained multiple sinuous strands of myxoid tumour in most of the branches of the pulmonary artery. Histologically, the material blocking the vessels consisted of spindle shaped and elongated cells with round or ovoid nuclei and prominent nucleoli embedded in a loose myxomatous stroma.

This case demonstrates how recurrent emboli from a right atrial myxoma can imitate

Department of
Medicine, Timaru
Hospital, Timaru,
New Zealand
D L Jardine

Department of
Pathology
D L Lamont

Correspondence to:
Dr Jardine.

Accepted for publication
9 July 1997

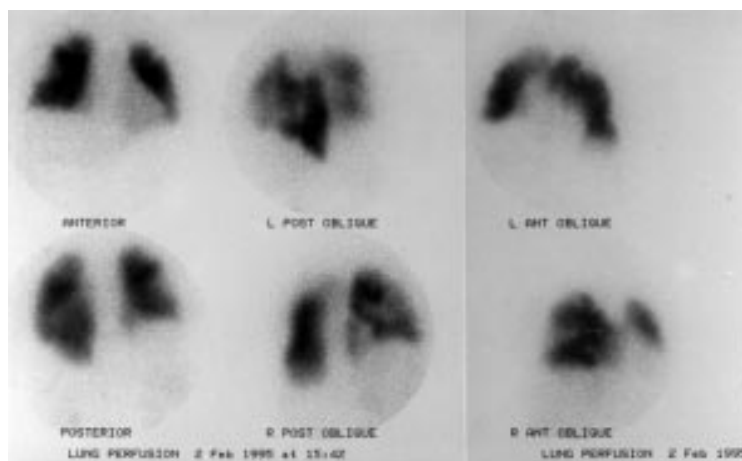


Figure 1 Anterior, posterior, and oblique views of the technetium-99m lung scan showing multiple segmental and subsegmental areas of decreased perfusion. The corresponding Xe-133 ventilation scan was normal.

episodes of thrombotic pulmonary embolism.^{1,2} The sudden death of this patient was caused by a massive tumour embolism obstructing his pulmonary vasculature, which is a recognised complication.³ Both his hospital admissions with pneumonitis were probably due to minor embolisation of tumour or associated thrombus. Patients with similar recurrent symptoms before diagnosis have been reported.^{4,5} At no stage was the diagnosis of right atrial myxoma considered because the common clinical features of this rare condition including murmur, rub, syncope, and signs of chronic right heart failure were absent.⁶⁻⁸ He was auscultated by numerous house staff and two consultants during his admissions and no auscultatory abnormality was documented. Although earlier reviews emphasised a combination of presystolic, pansystolic, and ejection systolic murmurs in nearly all cases, it was also acknowledged that murmur intensity depended on size, position, and mobility of the tumour and so varied spontaneously with respiration and body posture.⁹⁻¹¹ More recent reviews, since the advent of echocardiography, have indicated that in up to 50% of cases the auscultatory findings are normal even if performed by a cardiologist.¹² Echocardiography is considered virtually 100% sensitive for diagnosing cardiac myxoma and so has probably hastened the discovery of myxomas that have not grown large enough to cause obstruction and abnormal auscultatory findings.^{13,14} It has also been recognised that pulmonary embolism and pulmonary hypertension may complicate this condition earlier and more frequently than was first thought.^{15,16}

Therefore, echocardiography should be undertaken early in patients with unexplained pulmonary embolism or signs of pulmonary hypertension and right heart failure.^{17,18} The high probability ventilation-perfusion scan has been shown to carry a positive predictive value of up to 96% for pulmonary embolus but cannot differentiate thrombus from tumour or vegetation.¹⁹ The abnormal coagulation results were more indicative of mild liver dysfunction and an acute phase response than an underly-

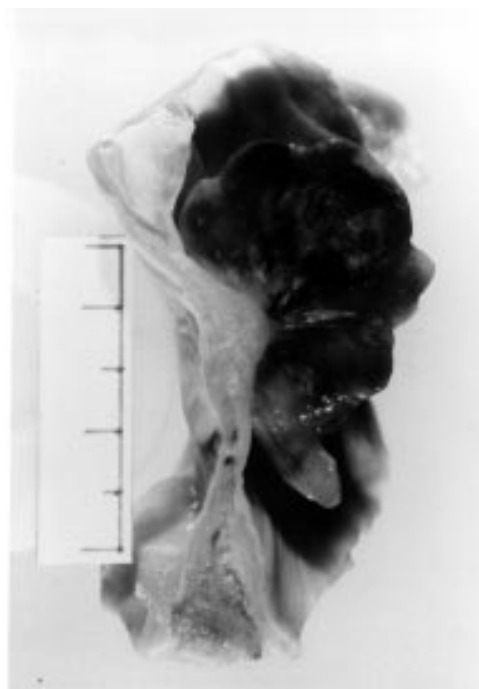


Figure 2 The 50 mm diameter myxoid tumour arising on the right atrial side of the interatrial septum.

ing coagulopathy. His initial response to anticoagulation was falsely reassuring and could be explained by the common association of thrombus with myxoma, a feature that has caused some pathologists to question the histological origin of this tumour.²⁰

In retrospect, this lesion may have been discovered earlier by echocardiography although there were no clear indications for this investigation. His presentation was that of recurrent pulmonary embolism with no obvious source or cause of thrombosis. Patients who are thought to have idiopathic pulmonary embolism should undergo early echocardiography to exclude the rare but treatable diseases of the right heart that may be responsible. It is also a useful test for assessing the haemodynamic effects of either acute or chronic pulmonary embolism.²¹

We are grateful for the technical assistance of Peter Swan who prepared the photographs and the advice of Dr J Turner, nuclear medicine department, Christchurch Hospital, New Zealand.

- Murloff LR, Johnson PM. Right atrial myxoma presenting as nonresolving pulmonary emboli: case report. *J Nucl Med* 1976;17:890-1.
- Keenan DJ, Morton P, O'Kane HO. Right atrial myxoma and pulmonary embolism. Rational basis for investigation and treatment. *Br Heart J* 1982;48:510-11.
- Heath D, Mackinnon J. Pulmonary hypertension due to myxoma of the right atrium. *Am Heart J* 1964;68:227-35.
- Miyauchi Y, Endo T, Kuroki S, Hayakawa H. Right atrial myxoma presenting with recurrent episodes of pulmonary embolism. *Cardiology* 1992;81:178-81.
- Holdswade GR, Steinberg I. Right atrial myxoma complicated by a thrombus. *JAMA* 1965;193:306-8.
- Hansen JF, Lyngborg K, Andersen M, Wennevold A. Right atrial myxoma. *Acta Med Scand* 1969;186:165-71.
- Morrissey JF, Campeti FL, Mahoney EB, Yu PN. Right atrial myxoma. Report of two cases and review of the literature. *Am Heart J* 1963;66:4-14.
- Sannerstedt R, Varnauskas E, Paulin S, Linder E, Ljunggren H, Werko L. Right atrial myxoma. Report of a case and review of the literature. *Am Heart J* 1962;64:243-54.
- Anagnostopoulos LD, Wilson WR, Ehrenhaft JL. Myxoma of the right atrium. Report of a case and review of the literature. *Arch Intern Med* 1967;120:330-6.

- 10 Goodwin JF. Symposium on cardiac tumours. *Am J Cardiol* 1968;**21**:307-14.
- 11 Waxler EB, Kawai N, Kasparian H. Right atrial myxoma: echocardiographic, phonocardiographic, and haemodynamic signs. *Am Heart J* 1972;**83**:251-7.
- 12 Burke AP, Virmani R. Cardiac myxoma. A clinicopathologic study. *Am J Clin Pathol* 1993;**100**:671-80.
- 13 DePace NL, Soulen RL, Kotler MN, Mintz GS. Two dimensional echocardiographic detection of intraatrial masses. *Am J Cardiol* 1981;**48**:954-60.
- 14 Markel ML, Waller BF, Armstrong WF. Cardiac myxoma. A review. *Medicine* 1987;**66**:114-25.
- 15 Scully RE, Mark EJ, McNeely WF, McNeely BU. Case records of the Massachusetts General hospital. *N Engl J Med* 1994;**330**:1143-9.
- 16 Reynen K. Cardiac myxomas. *N Engl J Med* 1995;**333**:1610-17.
- 17 Panidis IP, Kotler MN, Mintz GS, Ross J. Clinical and echocardiographic features of right atrial masses. *Am Heart J* 1984;**107**:745-58.
- 18 Keenan DJM, Morton P, O'Kane HO. Right atrial myxoma and pulmonary embolism. Rational basis for investigation and treatment. *Br Heart J* 1982;**48**:510-12.
- 19 Hirsh J, Hull RD, Raskob GE. Diagnosis of pulmonary embolism. *J Am Coll Cardiol* 1986;**8**:128B-36B.
- 20 Krikler DM, Davies MJ, Woolf N, Moss E. Atrial myxoma: a tumour in search of its origins. *Br Heart J* 1992;**67**:89-91.
- 21 Come PC. Echocardiographic evaluation of pulmonary embolism and its response to therapeutic interventions. *Chest* 1992;**101**:151S-62S.