

# Unrepaired Tetralogy of Fallot with Right Hemitruncus in an Adult

A Rare Case

Rajiv J. Patel, DO  
Ramzan M. Zakir, MD  
Virender Sethi, MD  
Jayant N. Patel, MD  
John Apovian, MD  
John C. Alexander, MD  
Marc Klapholz, MD  
Muhamed Saric, MD, PhD

#### Section Editor:

Raymond F. Stainback, MD,  
Department of Adult  
Cardiology, Texas Heart  
Institute and St. Luke's  
Episcopal Hospital, 6624  
Fannin Street, Suite 2480,  
Houston, TX 77030

**From:** Department of  
Medicine (Drs. Klapholz,  
R. Patel, Saric, and Zakir),  
New Jersey Medical  
School, Newark, New  
Jersey 07103; and Division  
of Cardiovascular Diseases  
(Drs. Alexander, Apovian,  
J. Patel, and Sethi), Hack-  
ensack University Medical  
Center, Hackensack, New  
Jersey 07601

**Address for reprints:**  
Muhamed Saric, MD, PhD,  
Department of Medicine,  
New Jersey Medical  
School, 185 South Orange  
Avenue I-538, University  
Heights, Newark, NJ 07103

E-mail: saricmu@umdnj.edu

© 2007 by the Texas Heart®  
Institute, Houston

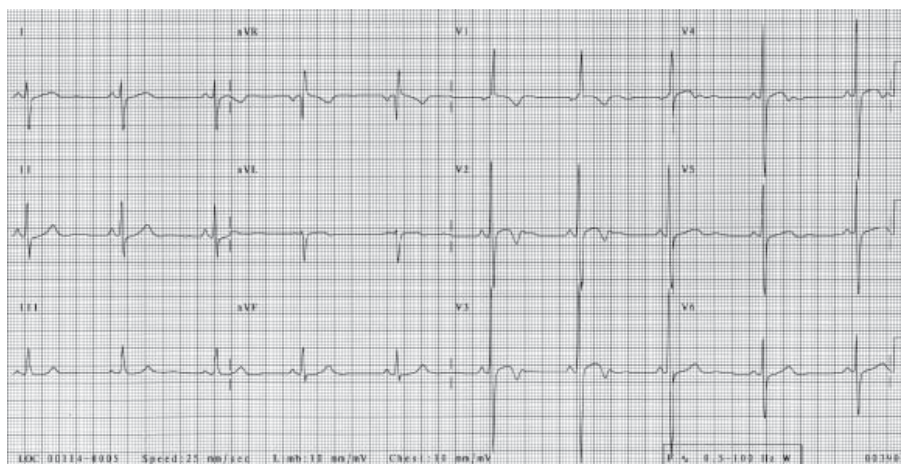
**A** 36-year-old immigrant from El Salvador, who had had a heart murmur since childhood, presented after recent-onset dyspnea on exertion and several episodes of “turning blue.” A physical examination revealed a resting oxygen saturation of 98% on room air, blood pressure of 114/70 mmHg, and a regular heart rate of 76 beats/min. There was a normal S<sub>1</sub>, an absent P<sub>2</sub>, and a grade 4/6 systolic ejection murmur with a palpable thrill along the left mid-sternal border. There was no evidence of peripheral or central cyanosis, but clubbing was present. The patient’s hemoglobin concentration was 20 g/dL (hematocrit, 58%). An electrocardiogram showed sinus rhythm, right-axis deviation, right atrial enlargement, and the Katz-Wachtel phenomenon (a large, equiphasic voltage in midprecordial leads), indicating biventricular hypertrophy (Fig. 1).

Transthoracic echocardiography was consistent with a diagnosis of tetralogy of Fallot: there was an overriding aorta, right ventricular hypertrophy, pulmonic stenosis (peak gradient of at least 72 mmHg), and a perimembranous ventricular septal defect (Fig. 2) with a minimal bidirectional shunt on color-flow Doppler. Cardiac catheterization revealed a 90-mmHg gradient in the infundibulum below the pulmonic valve. Aortography showed a right-sided aortic arch and the anomalous origin of the right pulmonary artery from the ascending aorta (right hemitruncus; Fig. 3). The left pulmonary artery was the sole branch of the main pulmonary trunk (Fig. 4).

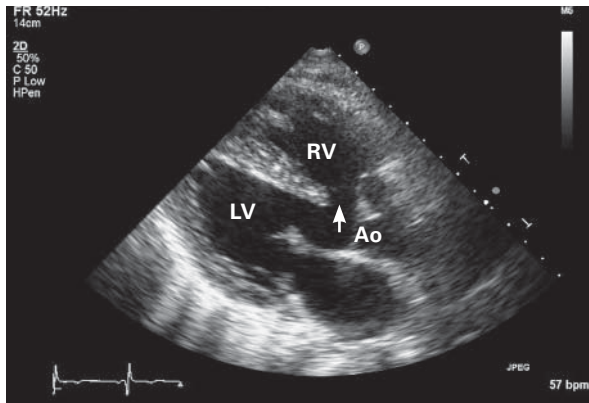
The patient underwent repair of the ventricular septal defect and resection of the infundibular obstruction; the right hemitruncus was left in place. Six months later, he was acyanotic, with normal right ventricular pressures and markedly improved overall functional capacity.

## Comment

The anomalous origin of 1 pulmonary artery from the aorta is known as hemitruncus. A combination of hemitruncus and tetralogy of Fallot is a congenital syndrome



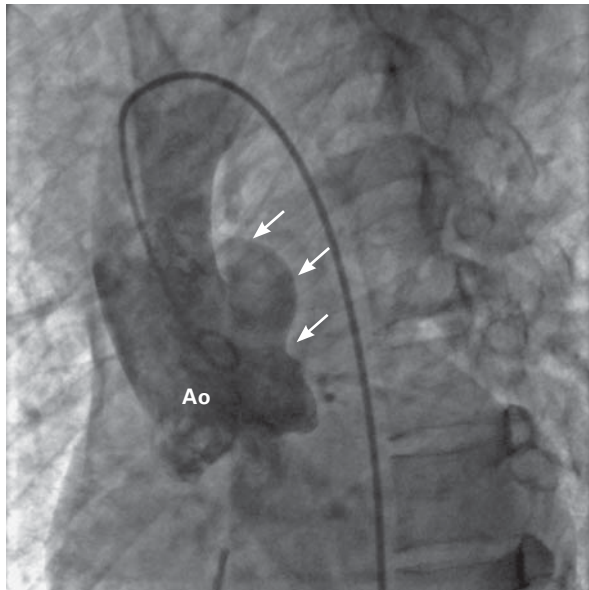
**Fig. 1** An electrocardiogram illustrates the Katz-Wachtel phenomenon (a large, equiphasic QRS voltage in midprecordial leads), indicating biventricular hypertrophy.



**Fig. 2** Transthoracic echocardiography shows tetralogy of Fallot: a perimembranous ventricular septal defect (arrow), an overriding aorta (Ao), and right ventricular (RV) hypertrophy.

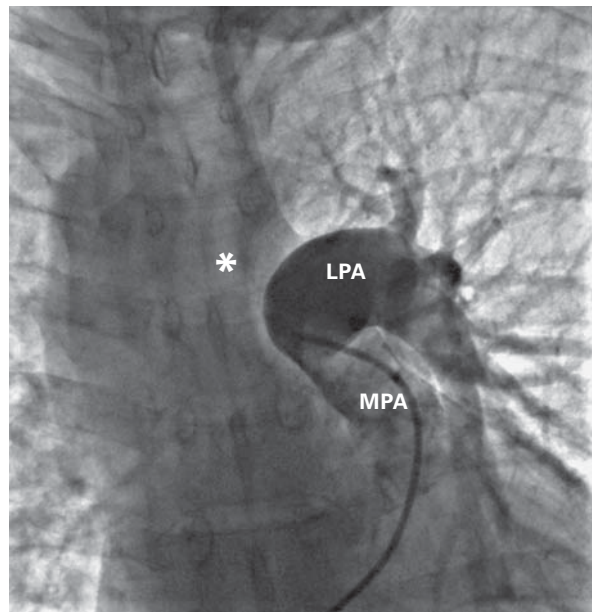
LV = left ventricle

Real-time motion image is available at [texasheart.org/journal](http://texasheart.org/journal).



**Fig. 3** Iodine contrast injection into the aortic root (Ao) reveals the anomalous origin of the right pulmonary artery (arrows) from the proximal ascending aorta.

Real-time motion image is available at [texasheart.org/journal](http://texasheart.org/journal).



**Fig. 4** Iodine contrast injection into the main pulmonary artery (MPA) shows only the left pulmonary artery (LPA) with its branches. The right pulmonary artery (asterisk) is not opacified.

Real-time motion image is available at [texasheart.org/journal](http://texasheart.org/journal).

rarely seen in adults, because most patients do not survive infancy without surgical treatment.<sup>1</sup> The incidence of hemitruncus is estimated at 0.1% of all congenital cardiac anomalies. Left hemitruncus is seen much more often with tetralogy of Fallot than is right hemitruncus (75% vs 3% of cases).<sup>2</sup> To the best of our knowledge, our patient is the oldest living person to have been diagnosed with unrepaired tetralogy of Fallot and right hemitruncus.

## References

1. Morgan JR. Left pulmonary artery from ascending aorta in tetralogy of Fallot. *Circulation* 1972;45:653-7.
2. Kutsche LM, Van Mierop LH. Anomalous origin of a pulmonary artery from the ascending aorta: associated anomalies and pathogenesis. *Am J Cardiol* 1988;61:850-6.