

patients. Diffuse, submucosal, leukæmic infiltrations produced a convoluted, brain-like appearance of the mucosal folds in 3 patients, and in 2 of these the stomach was also greatly dilated.

The intestinal lesions were of four types. Plaque-like thickenings were found in 8 patients. Raised, nodular lesions, varying in size from a few millimetres to 6 cm, were found in 21 patients. One patient had polypoid lesions extending from the cæcum to the rectum; the polyps were pedunculated, contained leukæmic tissue, and varied in size from a few millimetres to 1 cm. One patient had diffuse leukæmic infiltration of the sigmoid colon, with thickening of its wall, and a convoluted, brain-like appearance of the mucosal folds.

Nonspecific lesions were found in 49 patients. Thirteen had peptic ulcers (Cornes *et al.* 1961), 19 had gastric erosions associated with petechial hæmorrhages, 10 had nonspecific intestinal ulceration, and 4 had extensive anal ulceration. Monilial ulceration was found in 1 patient, a fibroma of the terminal ileum in another, and an adenocarcinoma of the ascending colon in another.

When these patients presented with ulcerating lesions in the gastro-intestinal tract a wide range of clinical disorders was suspected. These included peptic ulcer, gastric carcinoma, typhoid, ulcerative colitis, and carcinoma of the rectum. Of 39 patients with gross leukæmic lesions in the gastro-intestinal tract, 25 had severe and persistent symptoms referable to the gastro-intestinal tract, and 14 had minimal symptoms, the gastro-intestinal lesions being incidental findings at post-mortem. Thirty-six patients had massive hæmorrhage into the gastro-intestinal tract, 7 being due to specific leukæmic ulceration, and the rest to other causes. Lesions in the gastro-intestinal tract were the immediate cause of death in 22 patients, 20 due to massive hæmorrhage, and 2 to intestinal perforation with generalized peritonitis.

To conclude, leukæmic lesions in the gastro-intestinal tract are not rare, and in some patients these lesions are the most important feature of their illness.

*Acknowledgments:* We are grateful to Professor C V Harrison and Professor Alan Morgan for the opportunity to study post-mortem reports and autopsy material, and to Dr I M P Dawson, Dr J G Humble and Dr B C Morson for their helpful advice and criticism. The work was supported by a grant from the British Empire Cancer Campaign.

#### REFERENCES

- Cornes J S & Jones T G (1962) *J. clin. Path.* 15, 305  
 Cornes J S, Jones T G & Fisher G B  
 (1961) *Gastroenterology* 41, 337  
 Debray J & Sarakinos M (1958) *Sang* 29, 572  
 Herxheimer G (1913) *Münch. med. Wschr.* 60, 2506  
 Köhn K (1951) *Z. ges. inn. Med.* 6, 492

## The Significance of Small Mucosal Polyps of the Rectum

by J F Arthur MB

(Bland-Sutton Institute of Pathology,  
 Middlesex Hospital, London)

Adenomas are relatively common lesions in the rectum and it is generally accepted that they are liable to undergo malignant change. It seems reasonable to suppose that an adenoma starts as a small mucosal lesion and grows as it increases in age. Small mucosal nodules 1–2 mm in diameter are often seen during proctoscopy and sigmoidoscopy especially in older patients. The high incidence of small nodules compared with the incidence of larger adenomas raises the possibility that many mucosal nodules do not continue to develop into adenomas. I thought it would be interesting to study the histology of these small nodules and see if there was any way of telling which are likely to develop into adenomas and might be considered to be precancerous.

Published figures for the incidence of polyps in the large bowel derived from post-mortem studies and from clinical observations show remarkable variations. For example, Lawrence (1936), in a series of 7,000 cases found an incidence of 2.37%; Helwig (1943), with 1,460 cases, found 9.5%; Moore (1960), with 169 cases, found 27% and Atwater & Bagen (1945), with 241 cases, found 69%.

One reason for the variation seems to be a lack of agreement as to the size of the lesions included in the series. Lawrence and Helwig do not quote a minimum size. Moore gives a minimum size of  $\frac{1}{8}$  in. and Atwater & Bagen admit to the use of a hand lens.

Atwater & Bagen showed conclusively that small mucosal nodules are common in the normal colon and that the incidence increases with age.

It is difficult to obtain autopsy specimens of the rectum in a sufficiently fresh condition for adequate histological examination. Therefore, as a preliminary study, a detailed examination was made of 34 surgical resections of the rectum for carcinoma. The specimens used were prepared for examination by the normal methods used at St Mark's Hospital and the Bland-Sutton Institute. The mucosa was examined carefully and all nodules less than 2 mm diameter were recorded. Of the 34 rectums examined 32 contained nodules less than 2 mm diameter: 8 contained 25 or more; 9 contained 15–25; 15 contained 1–15; 2 contained none.

The distribution of the nodules did not follow an obvious pattern. There seemed to be no regular relationship to the position of the tumour present in any of these specimens.

Lesions between 1 and 2 mm in diameter were sectioned and were separated into four groups on their histological appearance: (1) Metaplastic polyps 87 (71%). (2) Minute adenomas 22 (18%). (3) Lymph follicles 13 (10.2%). (4) Benign connective tissue (tumour leiomyoma) 1 (0.8%).

The commonest was the metaplastic polyp. This lesion has only recently been recognized and separated from the adenomatous polyp (Morson 1962). It has a characteristic histological appearance (see Fig 1). The mucosal tubules are dilated, and the borders become serrated. In some cases the dilatation of tubules is sufficient to give a radiating frond-like appearance to the lesion. The muscle bundles of the muscularis mucosæ beneath the lesion break up into an interlacing network of fibres, some of which spread upwards into the fronds of mucosa. The cells lining the dilated mucosal tubules are different from those of the normal mucosa. They are columnar but of varying height, thus producing the serrated appearance described. The nuclei are large and vesicular. Mitoses are infrequent. A few goblet cells are present.

Minute adenomas were miniature editions of the familiar large adenoma. There is an area of overgrowth of the mucosa and a change in the type of epithelial cell. The columnar epithelial cells become taller, the nuclei larger and more darkly staining. Mitoses are frequent. The cells show active mucus secretion and there are numerous goblet cells. In the early stages of the lesion the muscularis mucosæ shows slight thickening only.

I do not propose to describe the histological appearances of the lymphoid nodules or the solitary leiomyoma.

Metaplastic nodules were found in 27 cases (80%) and 13 (40%) contained minute adenomas.

This preliminary study confirmed that small mucosal nodules are common in the rectum and showed that the commonest lesion is the metaplastic polyp. The number of adenomas found (40%) corresponds roughly with the reported figures for the incidence of adenomas in association with carcinoma of the rectum (Rosenthal & Baronofsky 1960).

The next step was to determine the incidence of small mucosal polyps and of the various histological types in the rectums of a comparable group of persons without an associated carcinoma. Numbers are not yet sufficient to quote results, but the findings suggest that metaplastic nodules are probably as common in the rectums of normal people as in those with carcinoma, whereas adenomas are seen more commonly in patients with carcinoma than in those without.

Metaplastic nodules are unlike any larger lesions seen in the rectum. I have examined

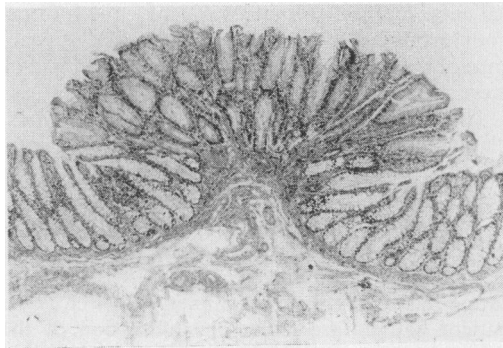


Fig 1 Cross section of metaplastic mucosal polyp from rectum.  $\times 25$

numerous other polyps derived from surgical resections and from biopsy material and I have not yet seen a true metaplastic polyp more than 1 cm in diameter. Areas of metaplastic epithelium on the surface of large adenomas are not uncommon, but larger editions of these highly characteristic mucosal malformations, if they occur, are rare.

#### REFERENCES

- Atwater J S & Bargaen J A  
(1945) *Gastroenterology* 4, 395  
Helwig E B (1943) *Surg. Gynec. Obstet.* 76, 419  
Lawrence J C (1936) *Amer. J. Surg.* 31, 459  
Moore J M (1960) *Scot. med. J.* 5, 83  
Morson B (1962) *J. Amer. med. Ass.* 179, 22  
Rosenthal I & Baronofsky I D  
(1960) *J. Amer. med. Ass.* 172, 37

## The Large Bowel Complications of Crohn's Disease of the Small Intestine

by J M Davis MChir FRCS  
(Whittington Hospital, London)

Patients with Crohn's disease of the small intestine have been reviewed to determine the incidence of the colonic complications and, in particular, the frequency of spread to the large intestine. This series has been reported elsewhere (Davis 1961); it consists of 141 patients in whom the intestinal lesion was initially limited to the small intestine; 69 patients were followed for more than five years. The large bowel complications which occurred are summarized in Table 1.

Table 1

The incidence of the large bowel complications from 141 cases of Crohn's disease of the small intestine

	Incidence
Diarrhoea as a presenting symptom	85%
Fistula-in-ano	28%
Internal fistula between the small and large intestine	15%
Extension to the caecum	15% (approx.)
Extension to the colon or rectum	4-7%