

share chronic pulmonary disease in middle-aged men already disabled by other disorders. A special feature of tuberculosis among the Irish is the development of gross calcification of lesions.

#### London-born

In the London-born extrapulmonary lesions are uncommon, though urogenital lesions and, in extreme old age, widely disseminated disease are sometimes seen. Pulmonary tuberculosis is for the most part a disease of middle-aged or elderly men who are often also suffering from other disabling diseases such as chronic peptic ulcers (with or without partial gastrectomy), diabetes, alcoholism or other mental disturbances and, the commonest of all, chronic bronchitis. It is the London-born, not the immigrant, who provides the problems of tuberculosis. It is far more difficult to diagnose the bizarre forms of disseminated tuberculosis in a senile Londoner than the florid forms in the immigrant. The acute pulmonary lesions of the immigrant usually respond to treatment rapidly and completely, whereas the chronic cavitated pulmonary disease of the middle-aged London man will show satisfactory bacteriological response, but his disability persists, aggravated by respiratory insufficiency.

#### REFERENCES

- Emerson P A, Heath G & Tomkins J G (1961) *Brit. med. J.* ii, 148  
 Hess E V & Macdonald N (1954) *Lancet* ii, 132  
 Middlemiss H (1961) *Tropical Radiology*, London  
 Springett V H, Adams T C S, Costa T B & Fleming M (1958) *Brit. J. prev. soc. Med.* 12, 135  
 Stevenson D K (1962) *Brit. med. J.* i, 1382

Dr D A Pyke

(King's College Hospital, London)

#### Electrocardiographic Changes in West Indians

Several authors have described variation in the electrocardiograms of Africans. Littman in 1946 surveyed 300 negro and 200 white subjects in America and found diphasic or inverted T waves in the precordial leads in 14 of the negroes but in only one of the whites. He described this as a persistence of the juvenile pattern of the electrocardiogram, since it is common to find inverted T waves in the precordial leads in children.

Brink (1951) in South Africa described inversion of the T waves in precordial leads in healthy Africans. Grusin (1954), also in South Africa, described two patterns. The first was inversion of T waves over the left ventricle. The second was elevation of the S-T segment, particularly over the right ventricular surface leads. Half of his patients had these 'abnormalities', the two patterns

being about equally common. Grusin found that exercise, respiration, posture, amyl nitrite and atropine had little effect in most cases, although in some the ECG changes might be diminished. The abnormalities were little correlated with body configuration, for electrical axis of his subjects was normal and the patients were clinically normal as far as the cardiovascular system was concerned.

Wasserburger (1955), Powell (1959) and Goldman (1960) have also described S-T segment and T wave changes in American and South African negro men.

The present study is based on observations of 128 West Indian men and women living in London. Sixty-seven were under 30 years old, 34 were aged 30-39, 27 were aged 40 or over. They came from a diabetic clinic, a venereal disease clinic and a general medical clinic and some were healthy students. In none was evidence of heart disease detected on clinical examination. Their electrocardiograms have been compared with those of healthy white controls of similar ages.

Two major 'abnormalities' have been detected in the electrocardiograms of the West Indians and have been found usually in the precordial leads. They are inversion of the T waves and elevation of the S-T segment. The results are given in Table 1. The mean height (in millimetres) of the

Table 1

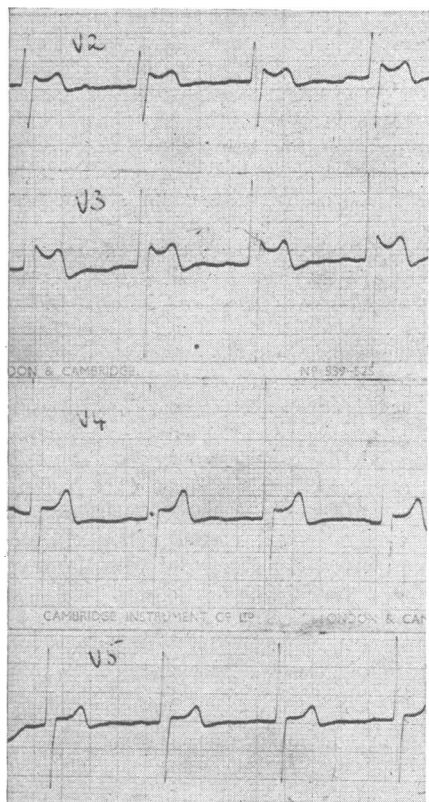
Racial differences in the electrocardiogram

	West Indian		White	
	Men	Women	Men	Women
Rv <sub>1</sub>	17.4 mm	10.4 mm	16.8 mm	10.4 mm
Sv <sub>1</sub>	10.4 mm	7.8 mm	8.0 mm	5.7 mm
Tv <sub>1</sub>	7.1 mm	2.8 mm	7.5 mm	3.3 mm
T inversion	8%	27%	0	8%
S-T elevation	44%	6%	5%	0

R wave in lead V5, the depth of the S wave in lead V1 and the height of the tallest precordial T wave in the West Indian and white men and women are shown, with the percentage of subjects showing either inversion of the precordial T wave (except in lead V1) or elevation of the precordial S-T segment of 1 mm or more (except in lead V1).

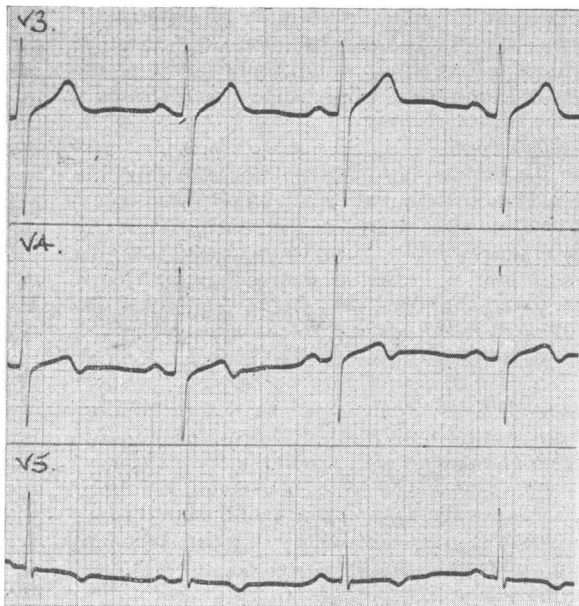
Fig 1 shows a characteristic tracing with S-T elevation, concave upwards, followed by T wave inversion. An example of T wave inversion is shown in Fig 2, which was taken from a healthy West Indian woman and might suggest ischaemia of the left ventricle.

Although these two patterns of S-T elevation and T wave inversion have been the commonest, we have occasionally seen other 'abnormalities', such as inversion of P, depression of the P-Q segment and transient bundle branch block.



**Fig 1** Characteristic pattern of S-T elevation, usually seen best in leads V2 or V3, which occurs more often in West Indian men than women

We sought an explanation of the striking differences in the electrocardiogram of West Indians and of whites. Our information is mainly negative. The tracings may vary: sometimes a second record taken a few weeks, or even a few days, later may be different from the first. Position of the patient and respiration seem to have little effect on the tracings. The effect of exercise is inconstant; in some subjects it has diminished the changes. Nutritional histories have not revealed any striking differences between those with and those without peculiar ECG patterns. Nor do they seem to be related to the time that a person has spent in this country; they have been seen as often in those who have been here for many years as in recent immigrants. That the patterns are related to some constitutional racial difference, not to some environmental factor, is suggested by the case of a 46-year-old negro who was born in this country and had never left it. His tracings showed S-T elevation and T inversion (Fig 3). He was apparently in perfect health, and he earns his living as a professional wrestler.



**Fig 2** Inversion of the T wave over the left ventricle, an appearance seen more often in healthy West Indian women than men

We have attempted a genetic study (through the courtesy of Drs Cyril Clarke and Geoffrey Harrison of Liverpool) but so far without a conclusive result. The difficulty here is that although an African community was established in Liverpool before the war and there are many marriages between negroes and whites, the offspring of these unions are mostly still young.

The excretion of 17-ketosteroids has been stated to be significantly lower in African negroes than in whites (Barnicot & Wolfson 1952). As this appeared to be another objective physiological difference between coloured and white people we thought it worth estimating twenty-four hour output of these steroids in some of our subjects, to see if there was any correlation between steroid excretion and electrocardiographic findings. None was found. Nor did we confirm the observation that ketosteroid excretion is low in coloured people. Among eleven West Indian men the mean 17-ketosteroid excretion was 11.0 mg in twenty-four hours, which is well within the normal expected range for white men in this country.

It is curious that previous studies have reported such different figures for the incidence of electrocardiographic changes. The explanation may be that the ECG changes themselves vary or that their frequency differs in American negroes, West

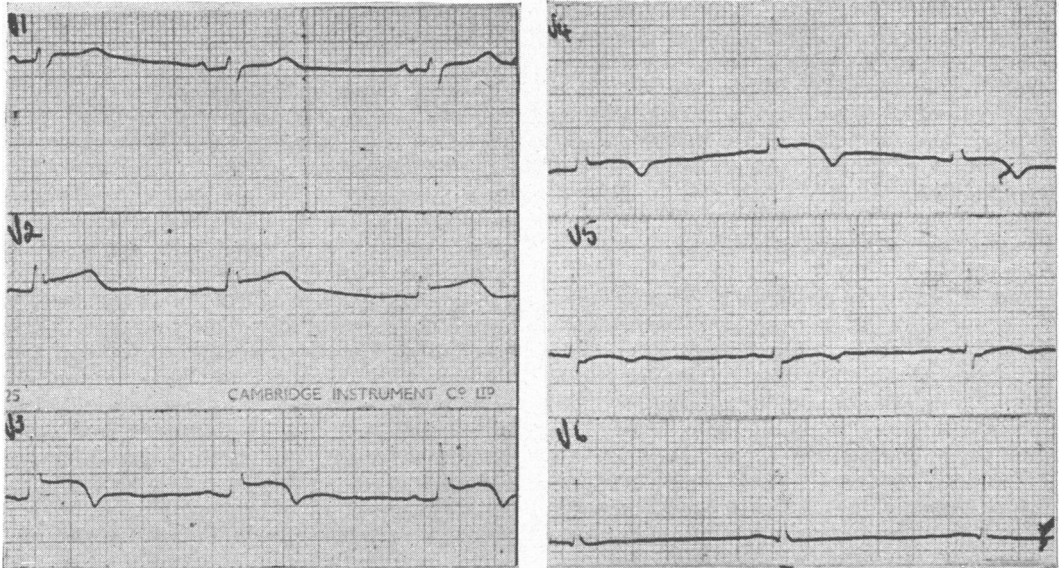


Fig 3 The V leads of a healthy negro man of 46 who had never left Britain

Africans and South African Bantu. Our group of West Indians was racially very mixed. They all had marked negroid features but probably none was pure African.

It is important to recognize that these peculiar electrocardiographic patterns occur in healthy coloured people. I know of at least three patients admitted to hospital for supposed pericarditis solely on the basis of electrocardiogram findings, in whom this diagnosis was ultimately abandoned for lack of clinical and laboratory support. The healthy coloured man or woman may have an electrocardiogram which resembles the pattern we usually associate with pericarditis or coronary disease, and it is well to be cautious in making either of these diagnoses without supporting clinical evidence.

What also emerges from this study is the difference between the sexes. The pattern of S-T elevation is common among the men, but rare among the women, whereas the T wave inversion is rare among men, but common among women. Furthermore, the magnitude of the maximum precordial T wave is very different in men and women. In 81% of the men the tallest precordial T wave is 5 mm or more, in 86% of the women it is 4 mm or less.

This striking sex difference is the same for white as for coloured people. An electrocardiogram can be sexed, merely by measuring the height of the tallest precordial T wave, in over three-quarters of cases.

#### Acknowledgments

The early observations on the 'abnormal' ECG patterns of some West Indians were made by Drs L Resnekov, B Scobie and I Weinbren.

I am grateful to the South Eastern Metropolitan Regional Hospital Board for financial support of this investigation.

#### REFERENCES

- Barnicot N A & Wolffson D (1952) *Lancet* **1**, 893  
 Brink A J (1951) *S. Afr. J. clin. Sci.* **2**, 288  
 Goldman M H (1960) *Amer. Heart J.* **59**, 71  
 Grusin H (1954) *Circulation* **9**, 860  
 Littman D (1946) *Amer. Heart J.* **32**, 370  
 Powell S J (1959) *Brit. Heart J.* **21**, 263  
 Wasserburger R H (1955) *Amer. J. med.* **18**, 428

#### Dr Hermann Lehmann

(St Bartholomew's Hospital, London)

#### Hæmoglobinopathies

##### *Hæmoglobinopathies in Immigrants*

Hæmoglobinopathies were rare 'tropical' diseases until very recently. With hundreds of thousands of immigrants from the areas of the Commonwealth where 10-20% of the inhabitants have the sickle-cell trait and where hæmoglobin C occurs in 3-10% of the people, these hæmoglobins are no longer of only theoretical interest to the physicians in this country. St Pancras, London, was mentioned by Dr Davies as having the