

## Section of Proctology

President Stanley Aylett MBE FRCS

### Ulcerative Colitis Treated by Total Colectomy and Ileorectal Anastomosis: A Ten-year Review [*Abridged*]

by Stanley Aylett MBE FRCS  
(Westminster Hospital, London)

I present for review a series of 213 cases of ulcerative colitis treated by total colectomy and ileorectal anastomosis between 1952 and 1961; Table 1 shows the cases operated upon in the relevant years. At first the numbers were small, and the procedure started as a trial. With two or three exceptions, every case has been referred by physician colleagues and the increasing numbers dealt with indicate that they are satisfied with the results following this operation. Table 2 shows the age and sex incidence. The predominance of female patients is in the ratio of 118 to 95.

Table 3 classifies the patients with each type of the disease, the fulminating, the acute and the chronic. The operative mortality of approximately 5% is less than that of many published series in which the treatment has been by panprocto-colectomy, often in one stage. In the fulminating cases the mortality rate of 12.5% is less than that recorded for similar cases treated by panprocto-colectomy. These figures are important because,

Table 1

Yearly record of number of patients

Year of operation	No. of cases
1952-53	8
1954	10
1955	13
1956	19
1957	28
1958	29
1959	34
1960	36
1961	36
Total	213

Meeting November 28 1962

### President's Address

in the assessment of any operative procedure, the immediate risks must be taken into consideration. The figures prove, I think, that the surgical methods I have advocated are a less severe tax on the patients' reduced stamina than those in general usage and so merit consideration on that account alone.

#### Operative Deaths

Errors of judgment have been responsible for several of my operative fatalities and their consideration may prevent them in the future.

There were 5 deaths in the fulminating type. I do not think that in 4 death could have been avoided; with patients desperately ill and sometimes almost moribund there are bound to be

Table 2

Age and sex incidence

Age group in years	No. of cases
10-15	13
15-20	20
20-25	24
25-30	34
30-35	25
35-40	23
40-45	17
45-50	21
50-55	21
55-60	9
60-65	3
65-70	3
Total	213

Age range: 10 to 67 years  
95 males. 118 females

Table 3

Mortality rates

	No. of cases	Operative deaths	Mortality rate (%)
Fulminating cases	40	5	12.5
Acute cases	102	5	4.9
Chronic cases	71	1	1.4

Overall operative mortality rate 5.1%

fatalities. The fifth of this group, a young sailor, recovered following the first of the two stages. Three weeks later I anastomosed the ileum to the rectum. The anastomosis broke down, he developed peritonitis and septicæmia and died. From this case I learned that the final anastomosis should not be undertaken until the patient has fully recovered from his devastating illness. This may take two or three months and the patient may be sent home or to a convalescent home. The fitter the patient the less chance there is of suture line breakdown.

Of the acute cases 5 died. One, after a smooth post-operative period with no rise of temperature or pulse or calf tenderness, collapsed suddenly from an overwhelming pulmonary embolus. A second died following multiple intraperitoneal abscesses. These deaths were probably unavoidable but three might have been prevented. In two the rectum was grossly ulcerated and ill-advisedly a one-stage operation was carried out, the anastomosis between ileum and rectum being protected by the customary safety-valve ileostomy. Because of the paper-thin rectal wall at the anastomosis the latter broke down. At the same time the safety valve receded so that the intestinal content ceased to be completely diverted. Fæces escaped into the pelvis and fatal peritonitis developed. Two errors were made in these patients: (1) A one-stage procedure should not have been attempted with a thinned rectal wall. Had a two-stage procedure been performed, the first comprising a colectomy, ileostomy and a proctostomy, the inflammation in the rectum would have subsided and it would have recovered sufficiently for a safe anastomosis later. (2) As soon as the leak through the anastomosis was recognized, a full ileostomy should have been instituted to divert completely the intestinal flow. If the rectum is thinned by ulceration a two-stage operation is essential, and when a one-stage is adopted a safety-valve ileostomy that will not recede and diverts fully the flow of intestinal content is needed.

The third possibly preventable death occurred in a child in whom considerable rectal fistula formation was present. The attempt to preserve the rectum was misguided. The rectal infection worsened and abdominoperineal excision was undertaken. She developed a sagittal sinus thrombosis from which she died. Gross perirectal infection or high fistula formation is therefore a contra-indication to ileorectal anastomosis. However, lesser fistulæ will heal if laid open at the time of or after the colectomy.

The single death among the chronic cases might have been avoided. A boy aged 14 had for many months been under a medical regime to which he had not responded, but became worse

until on admission he weighed less than 40 lb. He progressed satisfactorily until the fourth post-operative day when he suddenly died within minutes. At post-mortem both adrenal glands were atrophied, the result of prolonged steroid therapy and toxæmia, and although operated upon under cover of this drug it was possible that he had been given dosages too small to fulfil the post-operative demands.

Certain patients, although they have had no pre-operative steroids, may show signs of steroid deficiency post-operatively. A sudden collapse of blood pressure is the cardinal sign of this and it must be combated by the immediate intravenous administration of cortisone. It is life saving and I believe that without it we should have lost a further 4 patients. Presumably the toxæmia of the disease damages the adrenal cells so that the requirements following operation cannot always be met.

#### *Non-operative Deaths*

Table 4 lists the patients who have died after discharge from hospital and the cause of death. G M, male, aged 19 at operation, died of cancer arising in the residual rectal stump; had he had a panproctocolectomy he might have lived although it was apparent soon after his discharge that he had a cancer and it is possible that it was present and had already disseminated at the time of operation. He was early in the series and perhaps a mistake was made in preserving the rectum as the disease had arisen when he was aged 2 and had been present for seventeen years. The high incidence of cancer in long-standing cases is well established and it may seem preferable to advise a panproctocolectomy in these patients. I have not always followed this but if there is any rectal stenosis its adoption is probably wise.

It is convenient at this point to record that there were 2 further cases of cancer of the rectal stump: In one its development was expected, as at the time of operation the rectum was heavily strictured and in spite of advice that a total removal of the large intestine was essential the patient refused an ileostomy. The cancer was identified six years after ileorectal anastomosis. The second cancer developed seven years after the initial operation, the condition being recognized by biopsy of a suspicious area at a routine follow-up. Both patients have been subjected to abdominoperineal excision. The follow-up periods are twenty months and nine months but both patients are at present free of recurrence.

Thus, in ileorectal anastomosis, the risk of cancer developing in the rectum would appear to be minimal and not such as to condemn the procedure. The lower mortality rate of the operation compared with that of other types more than out-

**Table 4**

Non-operative deaths

Patient	Age at death (years)	Time between operation and death	Cause of death
G M	23	4 years	Cancer of rectum
M P	24	18 months	Obstruction
D J	58	6 years 2 months	Obstruction (pulmonary embolus)
F P	73	6 years	Squamous cell cancer of lung
B R	69	2 years 11 months	Coronary thrombosis
C D	61	2 years 7 months	Dissecting aortic aneurysm
D M	52	13 months	Carcinomatosis. Carcinoma present at operation

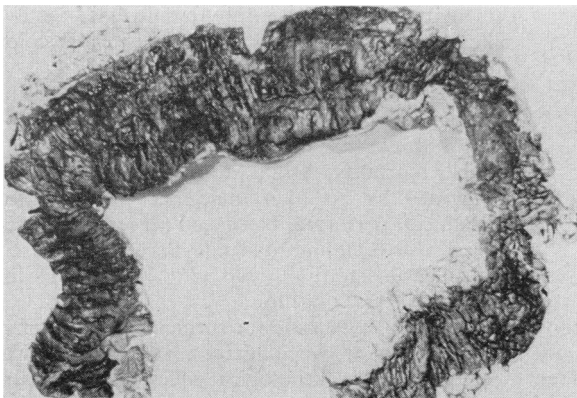
weighs this risk. Two points emerge from its consideration: (1) In adopting ileorectal anastomosis it is essential to maintain the closest follow-up. In this series 6 patients live abroad but they are communicated with regularly and seen on their visits to England. Of the rest, every case is seen at intervals of a few months and the follow-up has been complete. (2) If at a follow-up visit the rectum appears to be strictured, biopsies must be taken and its excision considered. Those converted to a permanent ileostomy are discussed below (Table 5).

Two patients, M P and D J, died of obstruction. M P was operated upon in Kenya. D J, who had been treated for one week for gastro-enteritis, was sent back to the Gordon Hospital where a gangrenous loop of gut was excised; she apparently recovered but the day before discharge collapsed from a pulmonary embolus. Of the other patients, one died of a squamous cell carcinoma of the lung (F P), one from coronary thrombosis (B R), and one from a dissecting aneurysm of the aorta (C D), their deaths occurring after varying periods of good health following their operation. The last

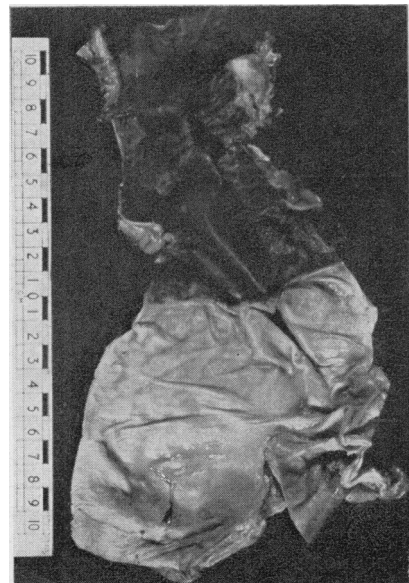patient (D M) died of cancer having had three separate primaries of the colon removed at the first operation.

Two other cases had cancer at operation. One, who had a stage 3 carcinoma of the transverse colon, is alive and well after eight years and works as an engine driver. The only modification in his case was to transect the transverse mesocolon at its reflection from the posterior abdominal wall, thus removing the lymphatic drainage. Our normal procedure is to keep close to the bowel wall during its excision. The second case was recognized at the pathological examination of the excised colon. She too remains well and free of recurrence two years after operation.

The patient who died from a dissecting aortic aneurysm (C D) was the only one from whom we have been able to recover the rectum at post-mortem. He had been operated upon 31 months earlier for fulminating colitis and had been well until one week before his death. I maintain that in the majority of cases, if the toxæmia of the disease is overcome, the inflammation in the rectum will resolve. The rectal wall will become epithelialized with a mucosa which, although attenuated or thinned and lacking the pattern of the normal structure, permits physiological function. This recovery has been seen in patients responding to medical treatment, and I have shown on various occasions pre- and post-operative biopsies demonstrating this resolution following ileorectal anastomosis (Aylett 1956, 1961). It can be claimed by



**Fig 1** The excised colon from a fulminating case of the disease (C D)



**Fig 2** Post-mortem appearance of the ileorectal anastomosis 31 months later showing complete healing of the rectum

critics who maintain that the rectal mucosa never resolves, and that on this count alone the rectum must be removed, that such biopsies do not represent the whole state of the mucosa. The post-mortem specimen from this patient refutes this suggestion. Fig 1 shows the colon removed in 1958 at the original operation; the gross ulceration extends down to the line of section through the rectum, and I think it can be accepted that the bowel below this was similarly affected. Fig 2 shows the post-mortem specimen, removed nearly three years later, of the ileum anastomosed to the rectum; although the former has some post-mortem degeneration, the rectum shows no ulceration. This surely must silence those who criticize ileorectal anastomosis on the ground that ulceration of the rectum never heals.

### *Permanent Ileostomy*

Table 5 records the 13 cases converted to permanent ileostomy. They are failures and constitute 6.4% of the survivals. They include the 3 patients who developed carcinoma of the rectum. Of the remainder, 2 were converted because of rectal stricture; 3 for fistulae and extensive ischio-rectal abscesses (one is also included in Table 3); and 3 for incontinence, two being multiparous females in whom severe tears had complicated childbirth so that the sphincters were weak, and the third was a male whose incontinence was unaccountable. One fulminating case, treated by two stages, was converted because, at the anastomosis of the ileum to the rectum, the latter wall was thinned by ulceration and split irremediably; removal was deemed to be wiser. The final patient developed a mesenteric thrombosis requiring resection and an ileostomy; he declined further operation.

*Table 5*

Patients converted to permanent ileostomy

<i>Reason for conversion</i>	<i>No. of cases</i>
Carcinoma of rectum	3
Rectal stricture (benign)	2
Perirectal suppuration	3
Incontinence	3
Rupture of rectal wall	1
Mesenteric thrombosis	1
<b>Total</b>	<b>13 (6.4% of operative survivors)</b>

### *Indications for Operation*

The success of surgery has persuaded many physicians to refer their cases which are not responding earlier than heretofore. A golden rule is to abandon medical treatment in favour of surgery if the patient's condition declines and never to continue until the patient deteriorates

to a point at which, if operation becomes imperative, its hazards are increased.

Complications such as iridocyclitis or pyoderma are unlikely to heal without operation but rapidly resolve following colectomy and local treatment. Stricture or pericolic abscesses must be treated operatively, the former because of the danger of cancerous change.

I regard multiple pseudopolyposis as an indication for operation, although when it affects the rectum the latter can be preserved, as these mucosal shreds form the nidi from which re-epithelialization takes place. In one advanced case of this complication the rectum was as involved as the colon; seven years after colectomy and ileorectal anastomosis the patient is well with no sign of pseudopolyypi in the rectum.

I believe that for the fulminating case colectomy and subsequent ileorectal anastomosis offer the best chance of recovery. The bowel is disintegrating and none can say when it will perforate or peritonitis supervene. I do not think that steroid therapy is indicated in such cases. Preliminary treatment to make the patient fit for operation, consisting of blood, electrolyte and fluid replacement, and of neomycin by mouth to reduce the intestinal flora, is in the province of the surgeon rather than that of the physician. Such treatment rarely exceeds twenty-four hours. Steroids will of course be given to those who have had them in previous episodes of the disease.

Fulminating episodes presented in 40 persons of whom 5 died from the operation. One patient developed a dissecting aneurysm of the aorta five years after operation and died. Of the remaining survivors all but 2 now enjoy normal health. Of the 2 exceptions one has a small fistula communicating with the ileorectal anastomosis which is not yet closed, but he works full time as a trades union secretary. The other has had periodic effusions into his knee-joints, resolved with phenylbutazone, but is fully employed. Figs 3-5 illustrate a fulminating case, the excised colon and his return to health.

I do not think many of these fulminating patients would have stood a panproctocolectomy and I think this operation will always carry a higher mortality. An ileostomy alone, sometimes suggested as an alternative, leaves the colon which can perforate, bleed and serve as a source of an overwhelming toxæmia. Because of these I consider ileostomy should play no part in the surgery of this condition.

A further indication for surgical intervention is the presence of liver damage revealed by clinical observation or pathological investigation. There is general recognition that such damage proceeding to cirrhosis can complicate colitis, and long-standing cases may finally present with ascites.

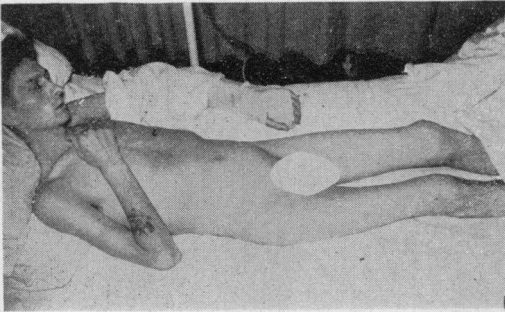


Fig 3 A patient with fulminating colitis and peritonitis




Fig 5 The same patient eighteen months later

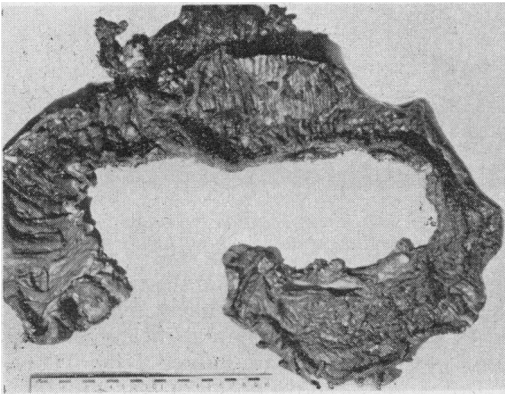


Fig 4 The colon excised from the patient in Fig 3

One such patient had had the disease for twelve years; when she was referred for surgery her serum alkaline phosphatase was 46 K.-A. units and her other liver function tests were correspondingly impaired. Following removal of her colon and ileorectal anastomosis her ascites steadily disappeared and at the end of a year the liver function tests returned to normal. After six years she is in first-class health, doing a job and running a home, and is on no dietary or salt restriction. A similar case followed the same pattern.

In a third patient with severe cirrhosis and impaired liver function the same resolution did not occur; he developed portal hypertension and devastating hæmorrhages three years after his colectomy. The bleeding occurred from large œsophageal varices and cavernous-like dilatations of the tributaries of the lower divisions of the superior mesenteric vein, particularly marked immediately above the ileorectal anastomosis. Nearly twelve months ago a porta-caval shunt was carried out by Mr G Westbury at the Westminster Hospital and the patient is again fit and working as a schoolmaster.

The experience of these three cases and of others of lesser degree to my mind makes it im-

perative that repeated liver function tests should be a part of the investigation and medical treatment of any patient suffering from ulcerative colitis; if they are impaired, excision of the colon and ileorectal anastomosis should be advised.

In cases of ulcerative colitis associated with mental illness for which institutional treatment or any therapy beyond mild suggestion is thought advisable, I would recommend that the diseased colon be first removed. We have in our series patients who have been treated unsuccessfully for schizophrenia, for manic depressive states and for other lesser mental abnormalities who have returned to normality following total colectomy and ileorectal anastomosis.

#### *Contraindications*

There are only three contraindications for this type of operation: the presence of a patulous anus, gross perirectal suppuration or a rectal stricture. I would emphasize the difference between a strictured rectum with its firm fibrosis and one in which the normal capacity has been reduced by soft œdematous and inflammatory infiltration of its walls. The majority fall into this latter category and the barium enema appearances may give the impression that the rectum is strictured. However, when healing occurs in the post-operative period, the capacity of the organ steadily increases as the inflammation resolves and only a minority become constricted.

#### *Operative Technique*

Details of the operative technique have been published elsewhere (Aylett 1960); here I will only point out aspects which I consider essential for success. After mobilizing the colon I deliberately divide the superior hæmorrhoidal artery below the origin of the last sigmoidal branch. I am sure that in ulcerative colitis the blood supply to the large intestine is more than normal and that division of this artery aids resolution in the

residual rectum. In a one-stage operation – where the ileum is anastomosed to the rectum at the time of the colectomy – one cannot be certain that the anastomosis will not leak, however perfect it appears. I consider it essential, therefore, to divert the faecal flow away from this anastomotic line until it has been proved by a barium enema that union is complete. A temporary ileostomy must be instituted. I believe that omission of these two steps is responsible for disappointments experienced by other surgeons when attempting to preserve the rectum.

One of our patients had had a total colectomy and ileorectal anastomosis carried out at another hospital, but without any protective temporary ileostomy. She developed pelvic peritonitis and ischio-rectal abscesses discharging faeces. Abdomino-perineal excision had to be undertaken and at operation the fistulous tracks were identified extending to a leaking anastomosis. I am sure that if an ileostomy had been formed at the first operation the rectum would not have required removal.

When a leak is demonstrated by the barium enema the patient is usually sent home for a month; a further X-ray will then show that the majority of leaks have closed. Rarely more time is needed before healing is complete and several barium enemas may be required. In all cases complete union has finally taken place.

The closure of the ileostomy is simple. After separation from the anterior abdominal wall, and a two-layer suture line to close the defect in the apex of the loop of small intestine, the latter is returned to the abdomen. It is separated by adhesions from the general peritoneal cavity, so that in the rare event of leakage the intestinal content discharges through the abdominal wound which has been lightly sutured. Such small fistulae have usually healed and a second closure is rarely required.

The two-stage operation, employed in the fulminating or very acute case or in those in which the rectum is excessively friable, has two merits: (1) The period of time during which the peritoneal cavity is open is reduced to a minimum. (2) The abdomen is closed before the ileum or colon is transected so that contamination from a grossly infected or ill-prepared bowel is minimized. The distal few centimetres of ileum, the colon and the upper rectum are mobilized as in the previous operation and the whole of this bowel is exteriorized. The abdomen is closed (Fig 6), the peritoneum being sutured snugly around the emerging ileum and upper end of the rectum; both these are brought through the left paramedian incision, though their points of emergence are separated by a few centimetres. The wound is sealed with Nobecutane. The colon is excised leaving the protruding ileostomy and proctostomy. Semicircles of

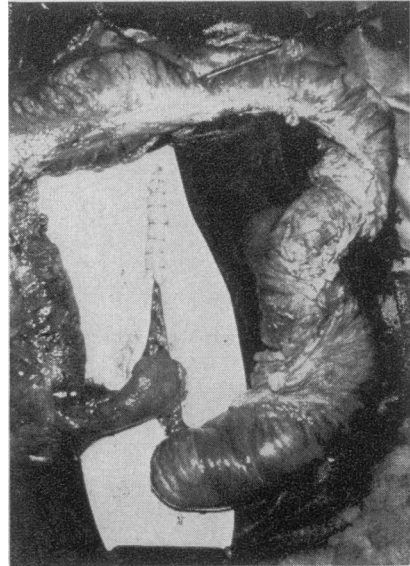


Fig 6 In the two-stage operation the colon is completely exteriorized and the abdomen closed before its excision

skin are removed from around the two stomas so that subsequent stenosis is unlikely; finally the free edges of the proctostomy and the turned back edges of the ileostomy are sutured to the skin.

This is an attractive operation, but the subsequent anastomosis between ileum and rectum is difficult and occasionally breaks down, requiring a safety-valve ileostomy before it heals. Nevertheless, used in the type of patient to whom I have referred, I believe that it will always carry a lower mortality rate than panproctocolectomy or simple ileostomy.

#### *Post-operative Care and Progress*

In the immediate post-operative period electrolyte and fluid replacement, gastric aspiration and antibiotic cover are instituted. The ileostomy works usually in three or four days and the loss of fluid and electrolytes becomes severe until the patient starts to eat fully and to take such anti-diarrhoeic drugs as codeine phosphate and I-so-gel, and at this stage replacement therapy must match every loss. Before commencing the I-so-gel and codeine phosphate we prefer to allow the ileostomy to run freely for forty-eight hours, as the too early administration of these drugs has caused what would appear to have been a temporary obstruction. Usually the evacuations from the ileostomy become semi-solid within a week or so and the intravenous therapy is discontinued. Following the closure of the safety valve or following the two-stage ileorectal anastomosis we stop all drugs, reducing bowel activity for a few days until it is certain that a fluid stool is passing.

The number of bowel actions usually settles rapidly. If frequency persists we give drugs such as poldine or propantheline, or phenoxymethylpenicillin and sulphamide in doses of 1 tablet two to four times a day. The patients are discharged on these drugs but over the ensuing months most find that they are able to cut them down and many take nothing.

#### *Complications*

The convalescent course is frequently not the smooth one I have described. Every complication that can be met in abdominal surgery may arise in the post-operative progress of these patients. Obstructions, abscesses in every site in the peritoneal cavity, hæmorrhages, wound breakdowns, small intestinal fistulæ discharging on to the abdominal wall and staphylococcal enteritis have all occurred. Medical complications such as foot-drop or a transient arthritis of feet, hands or knee-joints have also caused concern. These complications have rarely forced us to abandon the principle of retaining the rectum. They have been dealt with by general surgical and medical principles and with few exceptions have been overcome. I think persistence plays a great part in success in this operation. Figs 7 & 8 illustrate one fulminating case who suffered an immediate post-operative obstruction, then a burst abdomen with wound sepsis and numerous small intestinal fistulæ. The latter were eventually dissected out and closed. He has enjoyed full health for the last five and a half years (Fig 8).

*Obstruction* has proved our commonest and greatest worry. When it is complete the diagnosis is obvious. Nothing is passed through the ileostomy, the patient rapidly becomes nauseated and vomits and abdominal distension is soon apparent. It is often incomplete and the ileostomy continues to function though the effluent is decreased in volume. The patient may not even be nauseated and may not vomit. Moreover, because the removal of the colon allows the small intestine to dilate considerably before abdominal distension becomes apparent, such obstructions may easily be overlooked until perforation is imminent. The possibility of such a complication must ever be borne in mind. It must be considered if there is a decline in the general condition post-operatively. Slight localized tenderness on abdominal palpation, increased peristalsis, an increase in resonance on percussion and a diminution of the measured discharge from the ileostomy are significant signs. Repeated observations of the patient aided by straight X-rays of the abdomen are carried out and the slightest deterioration in his condition or a failure to improve on a conservative regime are the signals for re-opera-

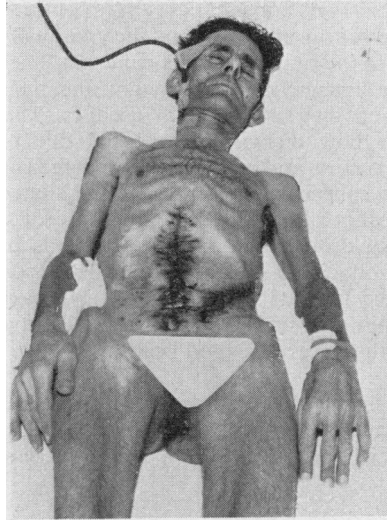


Fig 7 *Fulminating ulcerative colitis. The appearance of a patient following colectomy complicated by obstruction, burst abdomen and multiple small intestinal fistulæ*

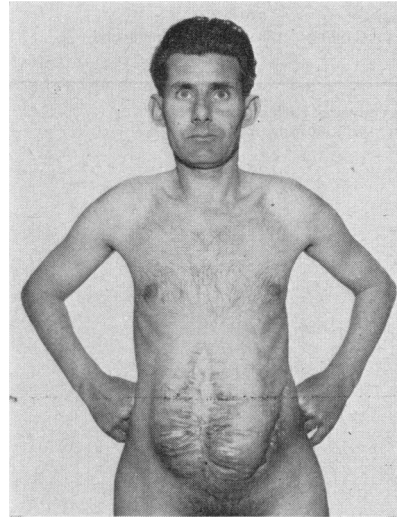


Fig 8 *Appearance of the same patient one year later*

tion, which must not be delayed until the patient's condition makes operation imperative and hazardous. We have dealt surgically with acute or subacute obstruction in 19 patients. In one, then a medical student but now a flourishing general practitioner, no less than five such episodes occurred. There was one death from pulmonary embolus amongst these patients (Table 4, D J).

*Chronic obstruction:* Some patients may continue well, perhaps for several years, and then gradually the number of their bowel actions increases. They may become anæmic and lose weight and their well-being and their good health declines. This syndrome is now recognized as being due to chronic obstruction and is always accompanied by a succussion splash over the area of the dilated loop of intestine. Its symptoms are those of a blind-loop syndrome and are due to bands or adhesions producing a state of chronic distension of an isolated loop of small intestine. We have operated upon 10 such patients and all have returned to their previous good health.

In conclusion, Table 6 summarizes the results and enumerates the patients who survived operation and in whom the operation was a success.

**Table 6**

Summary of results

	<i>No. of cases</i>
Total	213
Died following operation	11
Converted to ileostomy	13
Successful cases	190
Died of other causes	7
Successful cases still living	183 (10 with minor social limitations)

*Note:* One case converted to ileostomy is also included in 'died following operation'

Some have since died of other causes, as I have reported, but they are included in the successes as up to the time of their deaths they were well. They number 190 or 84% of the total of 213. They include soldiers, an actor, a doctor, nurses, businessmen, long-distance lorry drivers, an engine driver, artists and musicians and many housewives. They are employed in the occupation of their choice and with the exception of 10 who have some limitations they enjoy every social pursuit and pleasure of the ordinary individual. With few exceptions they have put on weight, often to a degree that has been excessive and has required dietary restriction. They have sired and borne children. They have travelled where fancy or occupation has taken them. With 3 exceptions the increase in number of bowel actions, usually to four or five a day though often less, worries them not at all. They are happy and contented patients.

The results are not my own. They are those of a team of Westminster Hospital nurses and doctors working at the Gordon Hospital whose especial interest, skill and pity have been directed to the care of patients suffering from this disease. It is with gratitude that I thank them all.

#### REFERENCES

- Aylett S O  
 (1956) *Proc. R. Soc. Med.* 49, 952  
 (1960) *Ann. R. Coll. Surg. Engl.* 27, 260  
 (1961) *Congr. int. Gastroent.* (Leyden 1960) pp 483 et seq