

Tumor Markers in the Human Ovary and Its Neoplasms

A Comparative Immunohistochemical Study

ETIENNE J. NOUWEN, PhD,
PATRICIA G. HENDRIX, MS,
SIMONNE DAUWE,
MARLÈNE W. EERDEKENS, MD, and
MARC E. DE BROE, MD, PhD

*From the Department of Nephrology and Hypertension,
University Hospital Antwerp, Edegem, Belgium*

The incidence and histologic characteristics of the expression of placental alkaline phosphatase (PLAP) in ovarian tumors was compared with that of five other tumor antigens. Three monoclonal antibodies were used for the specific localization of PLAP. PLAP was present in some sex cord cells of the 13–16-week fetal ovary, probably germ cells. In normal ovaries, all antigens except carcinoembryonic antigen (CEA) were frequently found in inclusion cysts; the germinal epithelium was positive only for cancer antigen 125 (CA 125). The frequency and extent of PLAP expression in

nonmucinous carcinomas was higher than observed for CA 19-9 and CEA, but was lower than for CA 125 and human milk fat globule antigen. Serous tumors had the highest PLAP expression, followed by endometrioid and poorly differentiated adenocarcinomas, and some other tumors. PLAP was predominantly membranous; its histologic distribution was in general heterogeneous. Different antibodies to PLAP gave different staining intensities in some tumors, but the staining patterns were always qualitatively identical. (*Am J Pathol* 1987, 126:230–242)

AN INTERESTING application of hybridoma technology as a tool in cancer research consists in the production of specific monoclonal antibodies against tumor specific substances called “tumor markers” and the use of these antibodies in tumor immunoscintigraphy and immunotherapy of metastatic disease. For this purpose, a marker substance should be expressed in sufficient amounts by malignant cells only and preferably by all malignant cells in a tumor, including its metastases, and it should be located on the cell surface. Unfortunately, several studies have revealed that malignant tumors are often very heterogeneous in the expression of tumor-associated antigens.^{1–5} This problem might be significantly reduced, however, by the combined use of monoclonal antibodies against different markers, provided that their histologic distribution is at least partially different. Immunohistology is a useful tool for investigating those features.

Using monoclonal antibodies, we have compared

on adjacent sections the histochemical distribution of six tumor-associated antigens that are more or less of interest in ovarian cancer. Different types of malignant and benign ovarian tumors and the normal adult and fetal ovary and reproductive tract were studied.

Supported by grants from the Fonds voor Kankeronderzoek van de Algemene Spaar- en Lijfrentekas, Nationale Loterij - FGWO (Grant No. 9.0005.84), the National Program for Reinforcement of the Scientific Research (PREST/UIA 04) and a research grant from the University of Antwerp.

Accepted for publication August 27, 1986.

Address reprint requests to Marc E. De Broe, MD, PhD, Department of Nephrology and Hypertension, University Hospital Antwerp, Wilrijkstraat 10, B-2520 Edegem, Belgium.

Placental alkaline phosphatase (PLAP; EC 3.1.3.1.) is frequently expressed by malignant ovarian neoplasms.^{4,6,7} It is essential to use monoclonal antibodies for its specific localization, because all other methods suffer from interference with other nontumor specific isoenzymes of alkaline phosphatase present in these tissues. HMFG 1 and HMFG 2 are monoclonal antibodies directed against human milk fat globule membrane components and have been used for tumor immunoscintigraphy and radioimmunotherapy of ovarian cancer.⁸ The other tumor-associated antigens investigated were cancer antigen 125 (CA 125),^{9,10} CA 19-9,¹¹ which is identical to sialosyl-Lewis^a,^{12,13} and carcinoembryonic antigen (CEA).

Materials and Methods

Materials

3-Amino-9-ethylcarbazole, poly-L-lysine (molecular weight >300,000), nitroblue tetrazolium, and trypsin (Type IIIs, 11,700 units/mg) were obtained from Sigma Chemical Co., St. Louis, Missouri; biotinylated horse anti-mouse immunoglobulin serum, avidin, and biotinylated horseradish peroxidase were obtained from Vector Laboratories, Inc., Burlingame, California; L-p-bromotetramisole was obtained from Janssen Chimica, Beerse, Belgium; 5-bromo-4-chloro-3-indoxylphosphate-p-toluidine salt was obtained from Serva Feinbiochemica GmbH, Heidelberg, Federal Republic of Germany; low-melting-point (49 C) paraffin was obtained from BDH Chemicals Ltd., Poole, United Kingdom.

Tissues

The study comprises 54 malignant, 6 borderline, and 31 benign ovarian tumors; 23 normal ovaries (age ranging from 17 to 74 years); 7 normal oviducts; and 2 normal endometrium samples. All tissues were surgical biopsies. Fetal tissues between 11 and 16 weeks of gestation were obtained from intact fetuses after prostaglandin-induced expulsion. They included 4 fetal ovaries, oviducts, and uteri (13, 14, 14, and 16 weeks of gestation) and 2 fetal testes (11 and 14 weeks of gestation). The samples were processed for histologic examination within 2 hours after receipt. Prior to fixation, the tissues were cut into 1.5-mm-thick slices.

Immunohistochemical Localization of PLAP, CA 125, HMFG, CA 19-9 and CEA

The immunohistochemical staining procedures for CA 125, HMFG, CA 19-9, and CEA are the same as described previously for PLAP.⁴ Briefly, the tissues were fixed for 1.5 hours in buffered 4% formaldehyde

(0.1 M sodium cacodylate buffer, pH 7.4, containing 1% CaCl₂) and were embedded in Paraplast or in low-melting-point paraffin. Adjacent 4- μ sections were mounted on poly-L-lysine-coated slides (0.1 mg/ml), treated with trypsin; and binding of the monoclonal antibodies was revealed by an indirect avidin-biotin-peroxidase method. Staining for peroxidase was performed with 3-amino-9-ethyl carbazole. For the localization of PLAP, three specific monoclonal antibodies were used: 17E3¹⁴ and E6¹⁵ culture supernatant diluted 1/50, and purified H17E2¹⁶ diluted 1/3000. The other monoclonal antibodies were OC 125 for CA 125,⁹ ascitic fluid diluted 1/3000; HMFG 1 and HMFG 2 for HMFG,¹⁷ culture supernatants diluted 1/50; 1116 NS 19-9 for CA 19-9,¹¹ culture supernatant diluted 1/20; purified antibody to CEA from Hybritech (Lot No. 360791) diluted 1/100,000. The sections were counterstained with methyl green and were mounted in glycerin-gelatin.

No difference could be found between tissues embedded in Paraplast or in low-melting-point paraffin. Treatment with trypsin yielded significantly stronger and more consistent staining with each of the eight monoclonal antibodies. Negative control staining was performed on adjacent sections with a monoclonal antibody of irrelevant specificity or normal mouse serum. Full-term placenta, a colon carcinoma, a mammary carcinoma, and an ovarian carcinoma, processed in identical ways, were used as positive controls for PLAP, CEA, HMFG, and CA 125 staining, respectively.

Conclusions on the immunohistochemical staining intensities for PLAP, obtained with the monoclonal antibodies 17E3, E6, and H17E2, are based on at least two separate staining experiments in which the three antibodies were used on adjacent sections.

Histochemical Localization of Nonspecific Alkaline Phosphatase (NSAP)

Paraffin sections adjacent to those for the immunohistochemical demonstration of PLAP were used to localize NSAP with 5-bromo-4-chloro-3-indoxylphosphate-p-toluidine salt as the substrate and nitro blue tetrazolium as the capturing agent.¹⁸ Histochemical inhibition studies were performed as described previously¹⁹ by adding 1 mM L-p-bromotetramisole²⁰ to the incubation mixture. The sections were counterstained with methyl green and mounted in glycerin-gelatin.

Routine Histology

Adjacent sections were stained either with Carazzi's hematoxylin and eosin or with Masson's trichrome.

Results

In the fetal ovaries of 13–16 weeks' gestation, the surface epithelium was negative for all antigens. In contrast, strong PLAP staining was found, irrespective of the monoclonal antibody used, in a substantial number of cells localized in the cortical sex cords. The number of positive cells decreased from the periphery to the center of the organ (Figure 1B). Staining for NSAP was stronger, and almost all sex cord cells were positive (Figure 1A). L-p-Bromotetramisole nearly abolished NSAP staining, except for a weak staining in some cells, the number and position of which was identical to that of the PLAP immunohistochemically positive cells. A few sex cord cells contained CA 19-9 staining. No staining for CA 125, HMFG 1, HMFG 2, or CEA could be observed. In comparison, Figure 2A and B illustrates the distribution of NSAP and PLAP, respectively, in a 14-week fetal testis. PLAP staining was found in a limited number of tubular cells with either of the three monoclonal antibodies. More tubular cells were positive for NSAP, and NSAP staining was also seen intracellularly in

some interstitial cells. The number of PLAP-expressing cells in the fetal testis is significantly smaller than in the ovary of comparable age.

Positive NSAP staining on the apical plasma membrane of the epithelial cells lining the 13–14-week fetal oviduct and uterus was abolished in the presence of L-p-bromotetramisole. PLAP immunostaining was absent. The oviduct was positive for CA 125 and HMFG 1 and 2; scarce staining was also found for CA 19-9. The fetal uterus was positive only for HMFG 1. PLAP was found on the apical plasma membrane of the 11–16-week chorionic trophoblast, but only a few of the villi showed positive staining. All other fetal tissues were negative for PLAP.

In 23 adult normal ovaries, relicts of the surface epithelium, present in 75% of them were sometimes (47%) positively stained for CA 125 (Figure 3A). HMFG was present only in 1 case; the other antigens were always absent. Local invaginations (Figure 3C and D) and proliferations (Figure 3B) of the germinal epithelium, present in 8 (35%) and 5 (22%) ovaries, respectively, were frequently positive for CA 125 (83% and 90%, respectively). Germinal inclusion

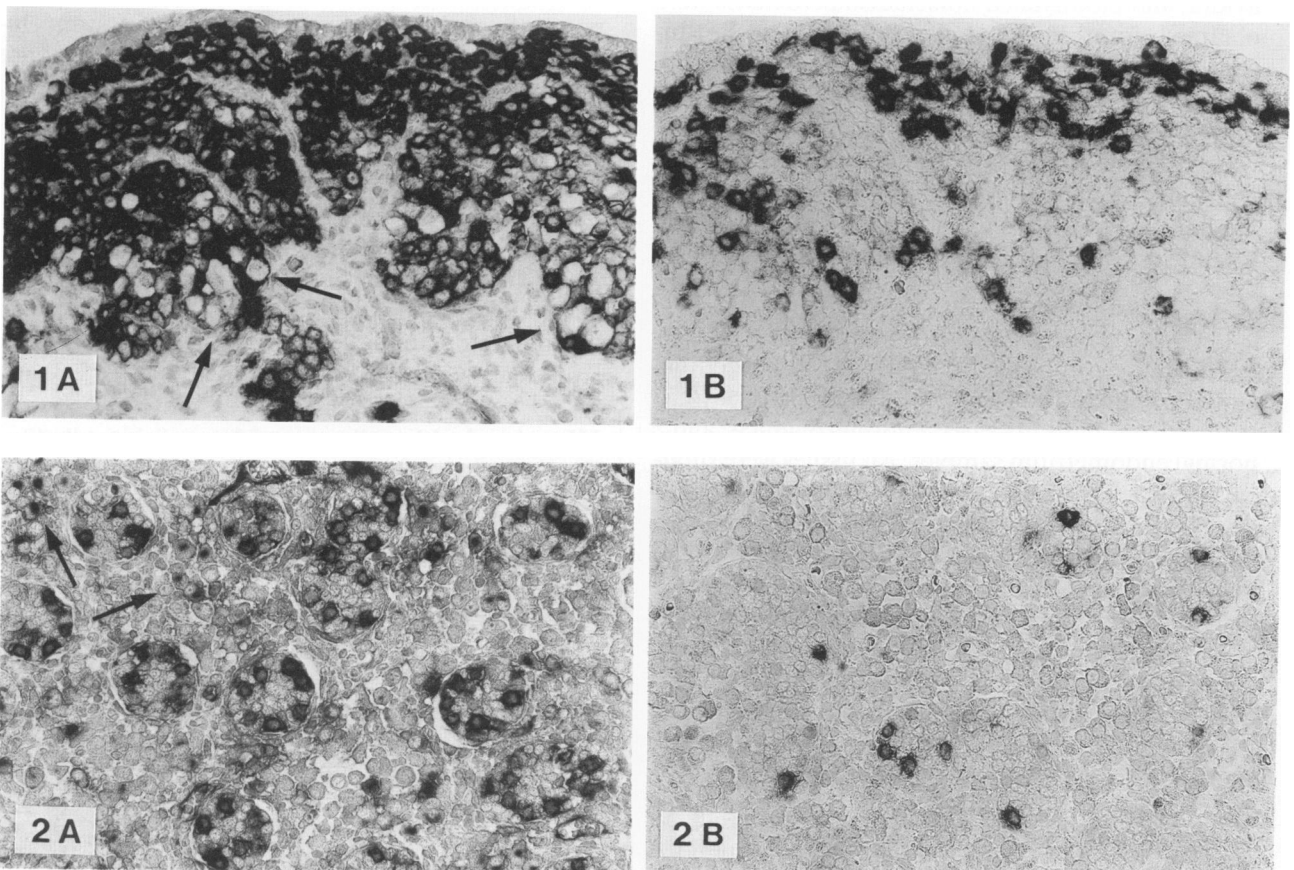


Figure 1—Fourteen-week fetal ovary. **A**—NSAP staining (arrows indicate primary oocytes). **B**—PLAP staining in some sex cord cells, probably oogonia (antibody 17E3). The surface epithelium is negative for NSAP and PLAP. (**A** and **B**, adjacent sections, $\times 210$) **Figure 2**—Fourteen-week fetal testis. **A**—NSAP staining (arrows indicate intracellular NSAP staining in some interstitial cells). **B**—PLAP staining in some tubular cells (antibody H17E2). (**A** and **B**, $\times 210$)

cysts were sometimes positive for NSAP (8/16 [50%]), PLAP (10/23 [44%], Figure 4B), HMFG 1 (7/19 [37%]), HMFG 2 (9/16 [56%]), and CA 19-9 (14/21 [67%], Figure 4C). They were nearly always positive for CA 125 (14/15 [93%], Figure 4A). In contrast, CEA was absent in all of 15 inclusion cysts. Expression of the different antigens in these cysts was independent. Some NSAP-containing inclusion cysts were negative for PLAP. Staining for PLAP, HMFG 1, CA 125, and CA 19-9 was localized on the apical plasma membrane of the epithelial cells and in the content of the inclusion cysts. Staining for HMFG 2 was also cytoplasmic. The lining epithelium was in general homogeneous in the expression of the markers (Figure 4A and B), but a pronounced cellular heterogeneity was also observed occasionally (eg, Figure 4C). Primary and growing follicles, observed in 6 premenopausal ovaries, were frequently positive only for CA 19-9 (Figure 5A and B). The zona pellucida of mature vesicular follicles found in two ovaries was also positive (Figure 5C). All other constituents of normal pre- and postmenopausal ovaries were negative for all antigens. The normal adult peritoneal mesothelium was positively stained only for CA 125.

In the normal tubal epithelium, the distribution of the different markers was roughly similar to that found in the borderline and malignant serous tumors, although CA 125 was more heterogeneously distributed (grading, 2–4). The immunohistochemical grading was 2–3 for PLAP, 2–4 for HMFG 1, 3–4 for HMFG 2, and 1–2 for CA 19-9; CEA was absent. One of 7 samples was negative for PLAP, and another lacked CA 19-9 staining. Normal endometrial glands were uniformly stained for CA 125, HMFG 1, and HMFG 2 and scarcely for CA 19-9. PLAP and CEA staining were absent.

Table 1 shows the histopathologic tumor identification and grade, the histochemical grading for NSAP, and the immunohistochemical grading for PLAP (using the antibodies 17E3, E6, and H17E2), CA 125, HMFG 1 and 2, CEA, and CA 19-9 for the malignant tumors. NSAP staining in the tumoral stroma and small blood vessels was omitted in the histochemical grading. Table 2 summarizes the results for the borderline and benign ovarian tumors.

In the group of benign tumors, PLAP and CEA had the lowest frequency of positivity (26% for both), PLAP being present in some serous tumors and cysts, CEA being present in some mucinous tumors and teratomas. CA 125, HMFG 1 and 2, and CA 19-9 positive staining occurred with a frequency of approximately 60% in all common types of benign tumors. Figure 7 illustrates the staining pattern for HMFG 2 in a dermoid cyst.

Each of the five borderline serous cystadenomas contained staining for PLAP, CA 125, HMFG 1 and 2, and CA 19-9; only one was scarcely positive for CEA. An example of the comparative distribution of the different antigens is shown in Figure 6. The scarce CEA positivity in this tumor was restricted to cells that did not stain for PLAP.

Among the malignant tumors, serous adenocarcinomas had the highest incidence of PLAP-positive staining (85%), followed by endometrioid and poorly differentiated adenocarcinomas (57%) and granulosa cell tumors. Mucinous carcinomas and some other less frequent tumor types were negative. However, in the first group, only 35% of the tumors showed PLAP staining in more than half of the cells. The overall frequency of PLAP was 60%. PLAP expression in Grade 1 and Grade 1–2 papillary serous (cyst)adenocarcinomas was comparable to that in borderline serous tumors but was slightly higher than in Grade 2–3 and Grade 3 serous adenocarcinomas. Comparison of PLAP staining patterns obtained with the three monoclonal antibodies reveals that although the patterns were always qualitatively identical, different staining intensities were found with each of these antibodies in some tumors. The histochemical staining patterns for NSAP, obtained in the presence of L-p-bromotetramisole (a specific inhibitor for liver-bone-kidney type alkaline phosphatase), were more heterogeneous than those obtained in the absence of inhibitor and were similar to the immunohistochemical patterns revealed by each of the anti-PLAP monoclonal antibodies (Figure 11). Many tumors also contained a substantial number of malignant cells lacking NSAP staining. CEA was found in all different tumor types, except in the granulosa-cell tumors, the clear-cell carcinomas, the dysgerminoma, and some other rare types. It was predominantly localized on the plasma membranes, and staining was, in general, scarce. The overall frequency of CEA-positive staining was 37%. CA 125, HMFG 1 and 2, and CA 19-9 were present in all major tumor types, with an overall frequency of 81%, 89%, 92%, and 60%, respectively. HMFG 1 had a slightly more heterogeneous expression than HMFG 2. The latter was, in general, not only membranous but also cytoplasmic. All antigens had a different histologic distribution, both within single and between different tumors. Some typical examples of the staining patterns are given in Figures 8–12.

Discussion

The use of PLAP as a serologic marker for ovarian cancer, compared with CA 125 and CEA, has been

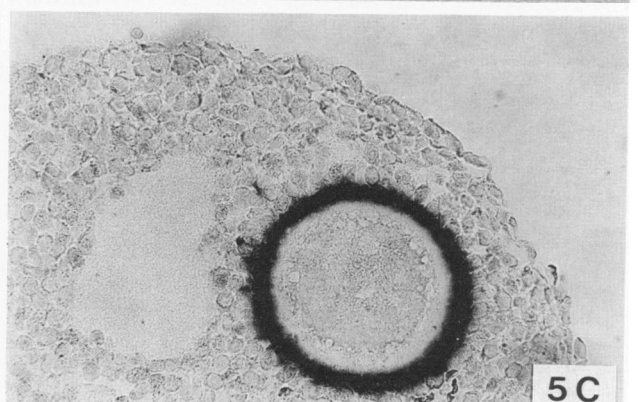
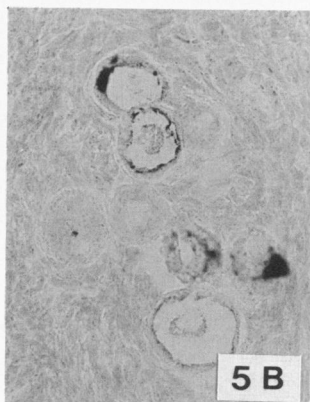
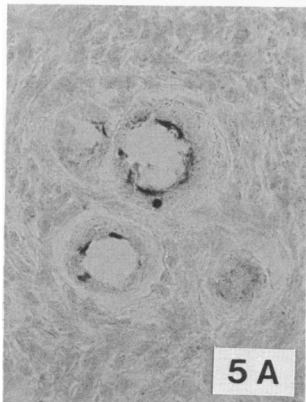
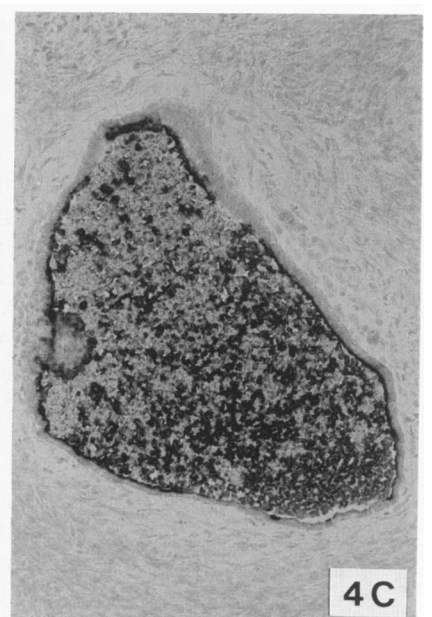
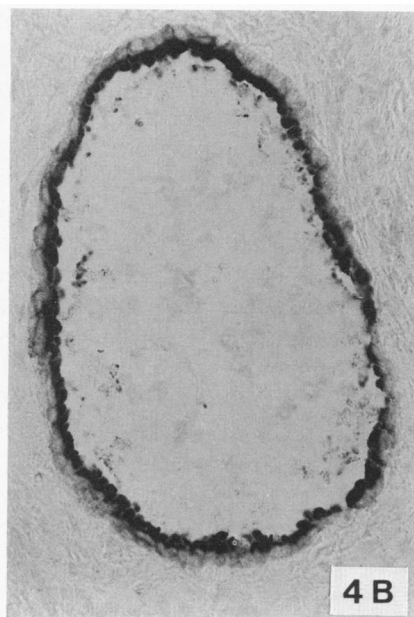
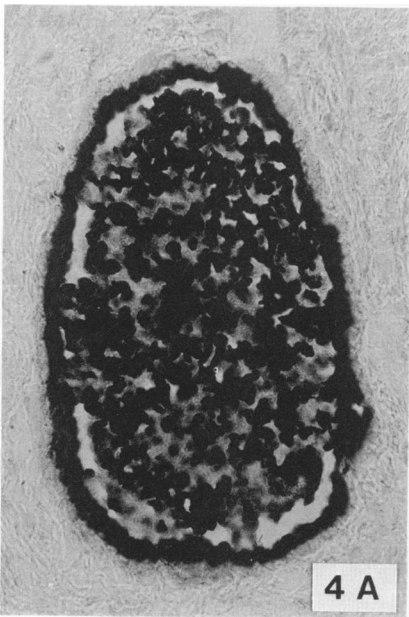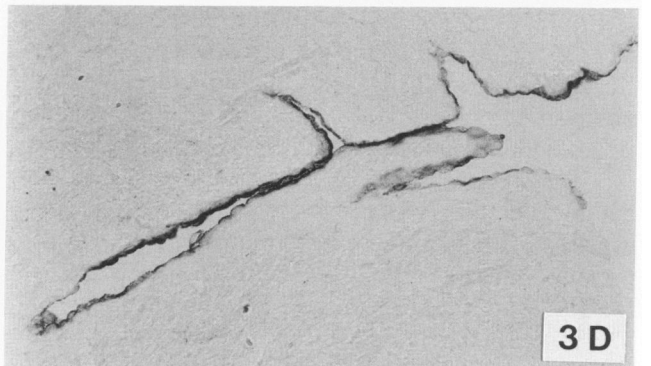
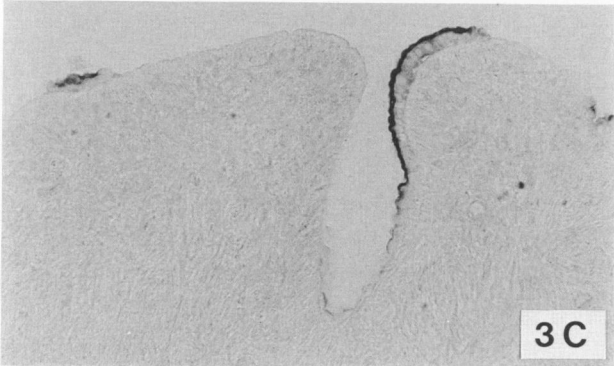
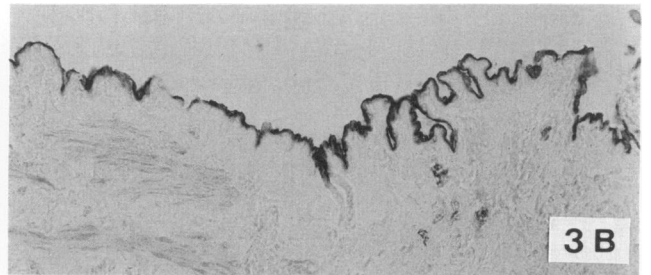
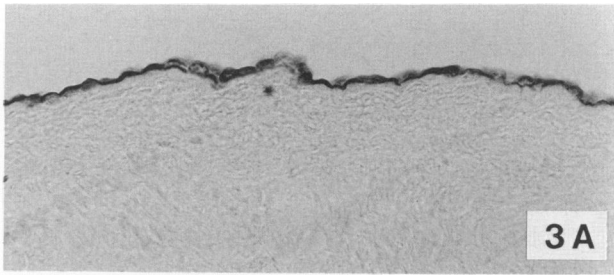


Table 1—Histochemical Grading* for NSAP and Immunohistochemical Grading for PLAP, CA 125, HMFG 1, HMFG 2, CEA, and CA 19-9 in Malignant Ovarian Tumors

No.	Grade†	Histopathology	NSAP	PLAP	CA125	HMFG 1	HMFG 2	CEA	CA 199
1	1	Papillary serous cystadenocarcinoma	4-a	4-a	3-a	3-a	4-a	2-a	3-a
2	1	Papillary serous cystadenocarcinoma	2-a	2-a	4-a	2-a	4-c	3-a	2-a
3	1	Papillary serous cystadenocarcinoma	2-a	2-a	4-a	3-am	3-a	0	0
4	1	Papillary serous cystadenocarcinoma	4-a	4-a	4-a	2-a	3-c	0	2-a
5	1	Papillary serous cystadenocarcinoma	2-a	2-ac	2-a	2-a	2-a	2-ca	3-ac
6	1	Papillary serous cystadenocarcinoma	3-ma	2-m	3-m	4-a	4-ac	0	0
7	1	Papillary serous cystadenocarcinoma	3-a	3-a	4-a	3-a	4-ac	0	1-a
8	1	Papillary serous adenocarcinoma	0	0	4-a	2-a	4-a	0	0
9	1-2	Papillary serous cystadenocarcinoma	3-ma	3-m	4-m	4-ac	4-ac	1-a	0
10	1-2	Papillary serous cystadenocarcinoma	4-ac	3-am	3-m	3-am	3-am	0	0
11	1-2	Papillary serous cystadenocarcinoma	3-a	2-a	4-m	4-a	4-mc	1-c	2-a
12	2-3	Papillary serous cystadenocarcinoma	0	0	4-am	3-a	4-ac	0	0
13	2-3	Papillary serous cystadenocarcinoma	3-cg	0	4-am	2-ag	4-m	0	1-a
14	2-3	Papillary serous cystadenocarcinoma	3-m	3-m	3-m	4-ac	4-ac	1-a	1-a
15	2-3	Papillary serous adenocarcinoma	2-m	2-m	4-mc	4-a	4-mc	0	1-am
16	3	Papillary serous adenocarcinoma	1-a	1-a	4-ac	2-a	3-m	0	0
17	3	Papillary serous cystadenocarcinoma	2-m	1-am	4-mc	4-ac	4-ca	3-a	0
18	3	Papillary serous adenocarcinoma	3-m	3-m	4-m	4-a	4-mc	1-mc	0
19	3	Papillary serous adenocarcinoma	2-ac	2-a	3-a	3-a	3-ac	0	2-a
20	3	Tubulopapillary cystadenocarcinoma	3-mc	2-a	4-mc	2-a	3-ac	3-c	1-m
21	1	Mixed serous/mucinous cystadenocarcinoma	2-a	2-a	3-a	3-a	3-ac	2-ca	0
22	1	Endometrioid carcinoma	2-am	2-a	4-a	3-ac	3-ac	0	3-a
23	1-2	Endometrioid carcinoma	3-am	3-m	4-m	3-a	3-m	0	3-ac
24	1-2	Endometrioid carcinoma	2-a	1-a	1-a	2-a	2-a	3-a	2-a
25	2	Endometrioid carcinoma	3-am	2-a	4-ac	4-ac	4-ca	0	0
26	3	Endometrioid carcinoma	4-ma	0	2-ca	3-ag	3-mc	0	0
27	3	Endometrioid carcinoma	0	0	0	2-m	3-mc	0	0
28	3	Endometrioid carcinoma	2-am	0	4-m	4-a	4-ac	0	1-m
29	3	Adenocarcinoma	1-ma	1-a	1-a	2-a	2-a	0	0
30	3	Adenocarcinoma	3-m	2-c	4-m	3-ac	4-mc	1-c	1-m
31	3	Adenocarcinoma	3-am	3-am	3-ma	3-ag	4-ac	2-ca	2-a
32	3	Adenocarcinoma	0	0	4-am	3-ag	4-ac	1-m	0
33	3	Adenocarcinoma	0	0	2-a	3-mc	4-c	0	2-a
34	3	Adenocarcinoma	3-am	2-m	3-ma	4-ac	4-mc	0	1-m
35	3	Adenocarcinoma	3-m	0	4-m	4-mc	4-mc	0	1-mg
36	1	Clear-cell carcinoma	0	0	3-a	4-a	4-m	0	2-a
37	1	Clear-cell carcinoma	0	0	1-a	3-a	2-a	0	0
38	1	Mucinous cystadenocarcinoma	0	0	1-a	2-ac	3-a	3-a	2-a
39	1-2	Mucinous cystadenocarcinoma	0	0	0	3-ac	3-ac	0	1-c
40	1-2	Mucinous cystadenocarcinoma	3-a	0	0	0	2-ca	3-a	2-ca
41	2-3	Mucinous cystadenocarcinoma	0	0	0	0	0	4-ac	4-m
42	2	Granulosa-cell tumor	2-am	1-m	3-a	4-ac	3-ac	0	2-m
43	3	Granulosa-cell tumor	2-ma	1-am	4-m	4-a	4-ac	0	1-m
44	3	Granulosa-cell tumor	0	0	0	0	0	0	0
45		Monodermal teratoma struma ovarii/carcinoid	0	0	0	2-a	2-a	0	1-a
46		Epidermoid carcinoma	3-am	2-a	4-ac	4-a	4-ac	2-c	0
47		Mixed homologous Müllerian sarcoma	3-m	3-m	4-m	4-am	4-mc	3-m	3-m
48		Mixed heterologous Müllerian sarcoma	3-m	0	2-a	4-a	3-cm	0	1-a
49		Carcinosarcoma	2-mc	0	0	4-a	2-ac	0	0
50		Sarcoma	0	0	0	0	0	0	0
51		Sarcoma	0	0	0	0	0	0	0
52		Sarcoma	0	0	0	0	1-m	0	0
53		Sarcoma	3-c	0	0	0	2-c	0	0
54	3	Dysgerminoma	3-mc	3-m	0	0	0	0	1-m

*Number indicates histologic distribution (% positive cells): 1, scarce (<5%); 2, focal (5- <50%); 3, predominant (50- <90%); 4, uniform (90-100%). Letter code indicates cellular localization: c, diffuse cytoplasmic; g, intracellular granules; a, apical plasma membrane; m, plasma membranes.
 †Grades: 1, well-differentiated; 2, moderately well differentiated; 3, poorly differentiated.

Figure 3—Normal postmenopausal ovaries. A—CA 125 staining in normal germinal epithelium. B—CA 125 staining in local proliferations of the germinal epithelium. C and D—CA 125 staining in invaginations of the germinal epithelium. (A, X262; B, X164; C, X210; D, X164) Figure 4—Normal postmenopausal ovaries. A—CA 125 staining in a germinal inclusion cyst. B—PLAP staining in the same cyst. C—CA 19-9 staining in a germinal inclusion cyst. (A and B, X210; C, X131) Figure 5—Normal premenopausal ovaries. A—CA 19-9 staining in primary follicles. B—CA 19-9 staining in zona pellucida of a mature vesicular follicle. (A, X164; B, X265)

Table 2—Histochemical Staining for NSAP and Immunohistochemical Staining for PLAP, CA 125, HMFG 1, HMFG 2, CEA, and CA 19-9 in Borderline and Benign Ovarian Tumors

Histopathology	N	No. positive for						
		NSAP	PLAP	CA125	HMFG1	HMFG2	CEA	CA 19-9
Borderline tumors								
(Papillary) serous cystadenoma	5	5	5	5	5	5	1	5
Mucinous cystadenoma	1	0	0	0	1	1	0	0
Benign tumors								
Serous cystadenofibroma	4	4	3	3	3	3	0	1
Serous/mucinous cystadenoma	1	1	1	1	1	1	1	1
Serous cyst	5	3	3	4	4	3	1	3
Endometriosis	4	2	1	3	3	2	0	3
Fibroma	1	0	0	0	0	0	0	0
Mucinous cystadenoma	5	0	0	0	4	4	3	4
Dermoid cyst	5	1	0	3	4	5	1	3
Immature teratoma	1	1	0	1	1	1	1	1
Cystic teratoma	3	1	0	2	2	2	1	3
Granulosa lutein cyst	2	0	0	0	0	0	0	0

documented previously.^{4,21-23} In this paper the expression of PLAP in the major histologic types of malignant and benign ovarian tumors and in different fetal tissues, including the male and female gonads, is described with the use of three different monoclonal antibodies and is compared with that of five other markers which are of some interest in ovarian cancer.

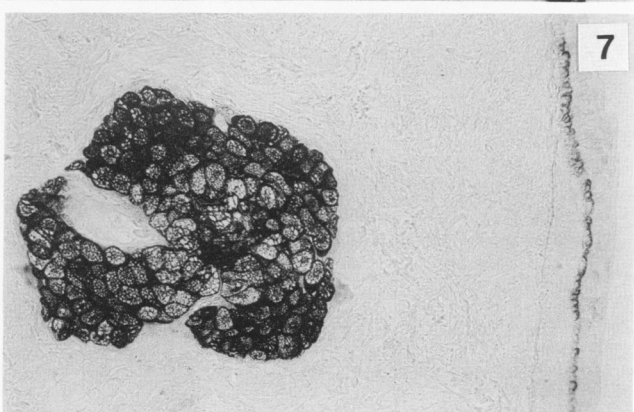
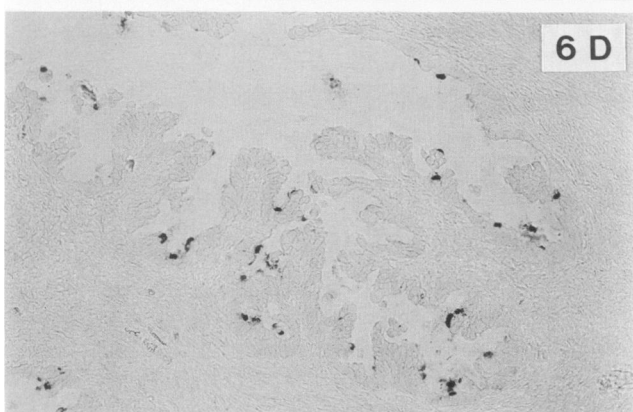
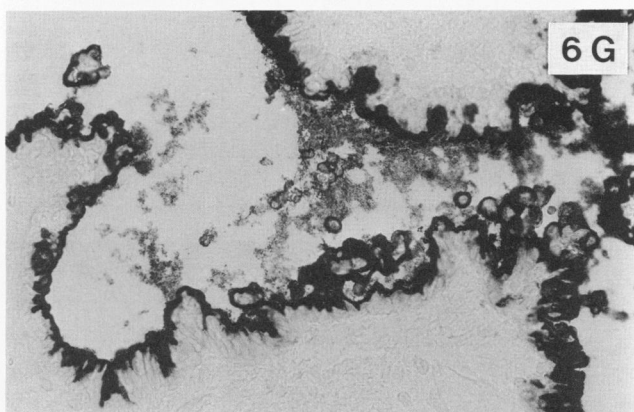
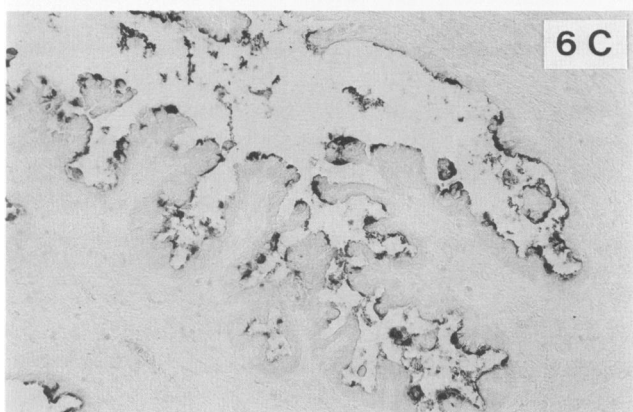
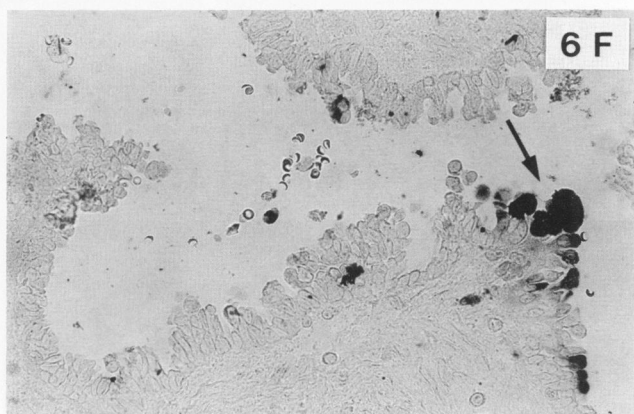
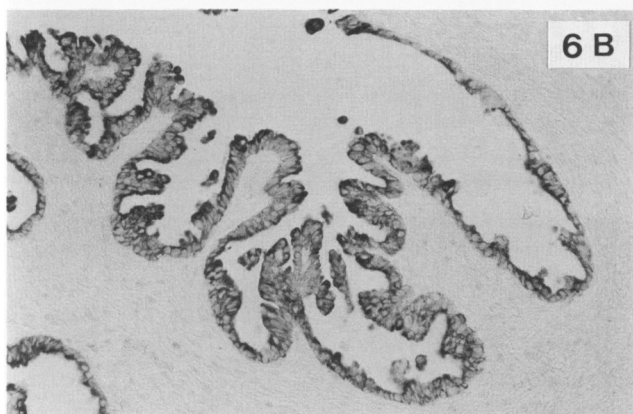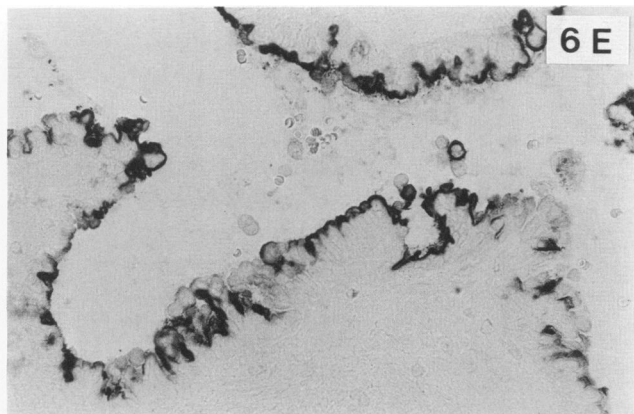
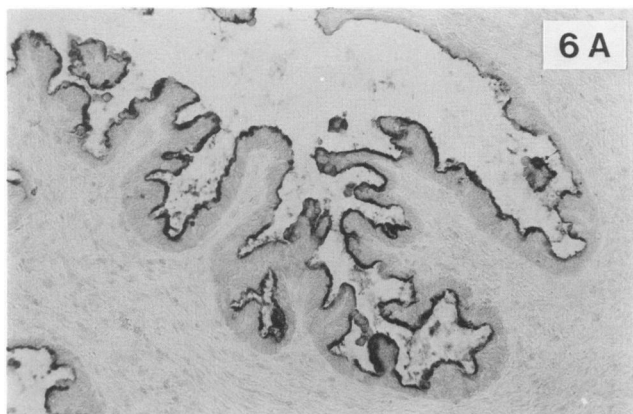
All antigens studied except CEA are more or less frequently found in normal ovaries, but their expression is always very limited, and their distribution patterns are not identical. Positive CA 125 staining in normal ovaries is in contrast to available data,^{10,24} but is probably related to the presence of this antigen in the normal peritoneal and pleural¹⁹ mesothelium.

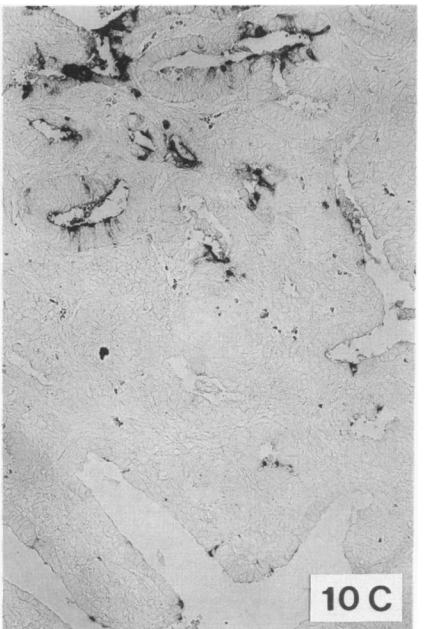
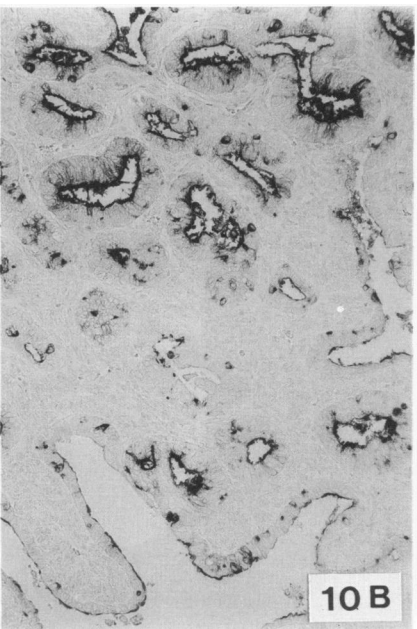
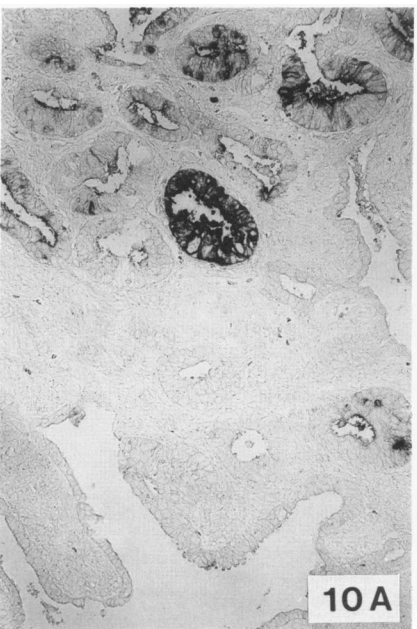
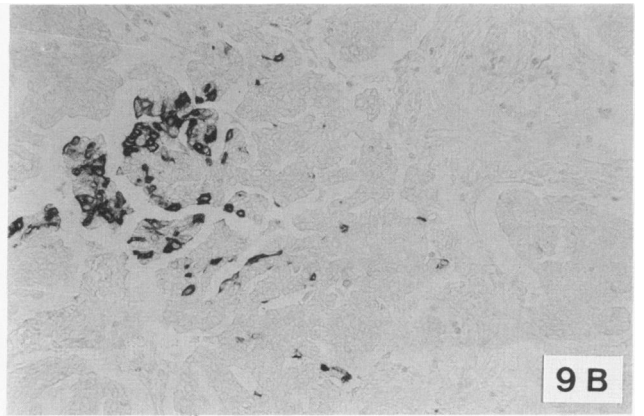
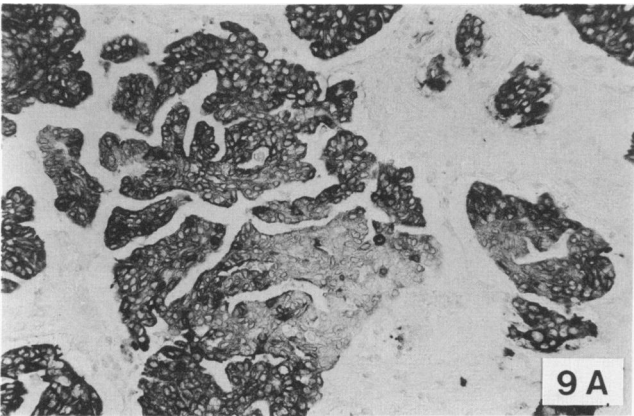
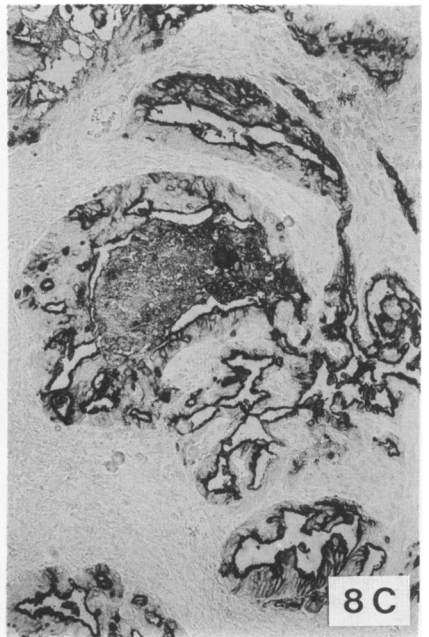
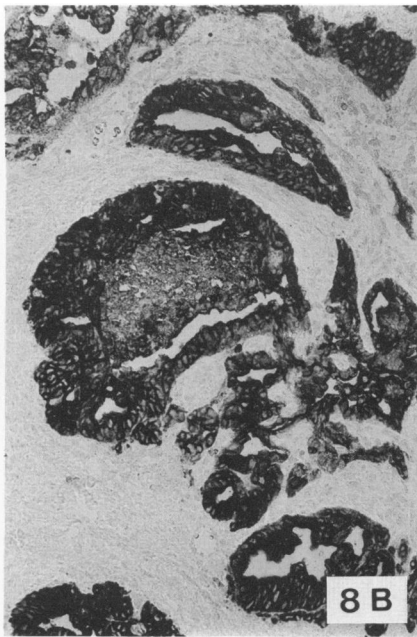
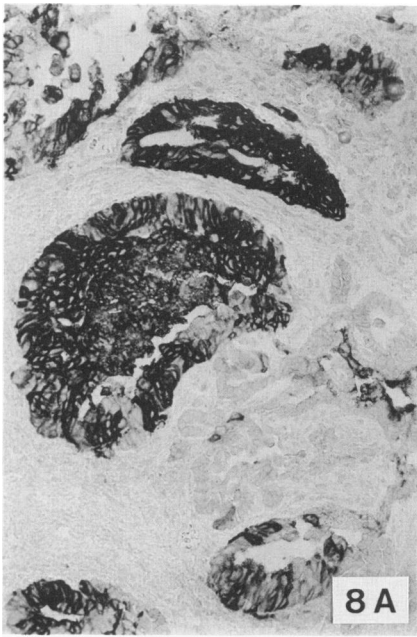
PLAP can be considered as a real oncofetal marker for the ovary because it is the only one of the six substances investigated having a significant expression in the 13-16-week fetal ovary, and the ovary is the only female fetal organ expressing PLAP, apart from the chorion. It is difficult to determine on morphologic grounds whether the PLAP-positive cells are somatic sex cord cells and/or germ cells, more in particular, oogonia. The clearly recognizable large primary oocytes and the mesenchymal cells are negative. Likewise, in the fetal testis, the PLAP-expressing tubular cells might be germ cells and/or primitive Sertoli cells. However, the expression of PLAP by the dysgerminoma and the observations that seminomas and embryonic carcinomas^{25,26} and primary intracranial germ cell tumors²⁷ also express PLAP frequently, suggest that the PLAP-expressing cells in the fetal ovary and testis are probably germ cells. Moreover, the

greater tendency of peripherally localized fetal ovarian cells to express PLAP parallels the mitotic activity of the germ cells, which decreases from the periphery toward the center of the organ, suggesting that PLAP expression is a property of the less differentiated germ cells. The absence of PLAP in primary oocytes and in the ovum of primary, growing, and mature vesicular adult follicles is also consistent with this.

On the other hand, approximately 90% of the malignant ovarian tumors that develop in adults do not originate from germ cells, but instead are thought to arise from modified peritoneal mesothelial cells covering the surface of the ovary or lining germinal inclusion cysts.^{28,29} Nevertheless, several of these tumor types express PLAP frequently, as also reported by others.^{6,7} Although neither the adult nor the fetal ovarian surface epithelium produce PLAP, its frequent expression by germinal inclusion cysts indicates that this epithelium has a strong potentiality to produce PLAP under certain conditions. The expression of the other tumor-associated antigens in germinal inclusion cysts adds further evidence in favor of the germinal epithelial origin of ovarian carcinomas. On the other hand, only a few normal epithelia produce PLAP in varying amounts, ie, the glandular endocervical epithelium,³⁰ the tubal epithelium,³¹ and the respiratory epithelium.¹⁹ The former two are embryonically related to the ovarian surface epithelium, because they develop from the müllerian duct. This relationship is also reflected by the observations that benign, borderline, and malignant ovarian tumors with a clearly recognizable serous, ie, tubal, differen-

Figure 6—Borderline papillary serous cystadenoma (Tumor 55). A—PLAP staining (antibody 17E3). B—HMFG 2 staining. C—HMFG 1 staining. D—CA 19-9 staining. E—PLAP staining (antibody E6). F—CEA staining. G—CA 125 staining. (A-D, adjacent sections, ×131; E-G, adjacent sections, ×210) Figure 7—Dermoid cyst (Tumor 81). HMFG 2 staining in sebaceous gland and stratum germinativum of epidermislike inner surface epithelium. (×105)





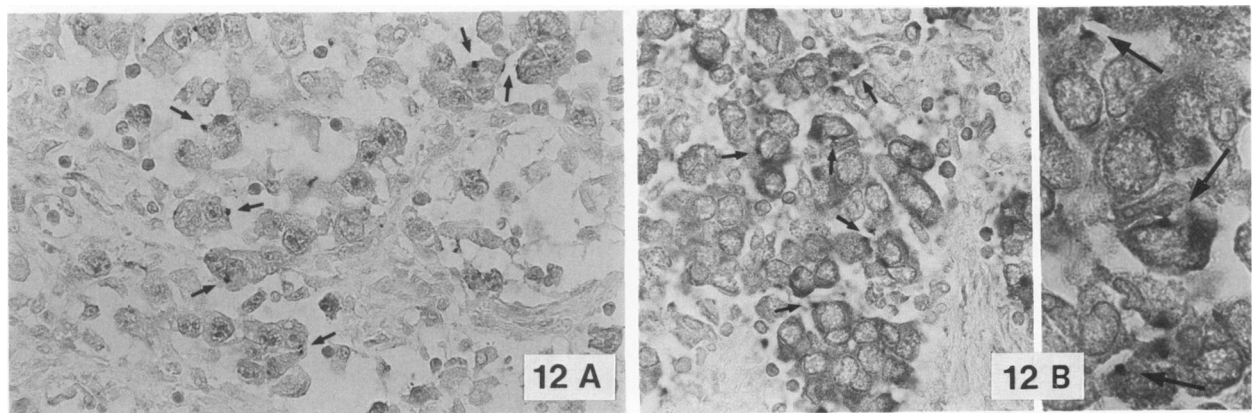
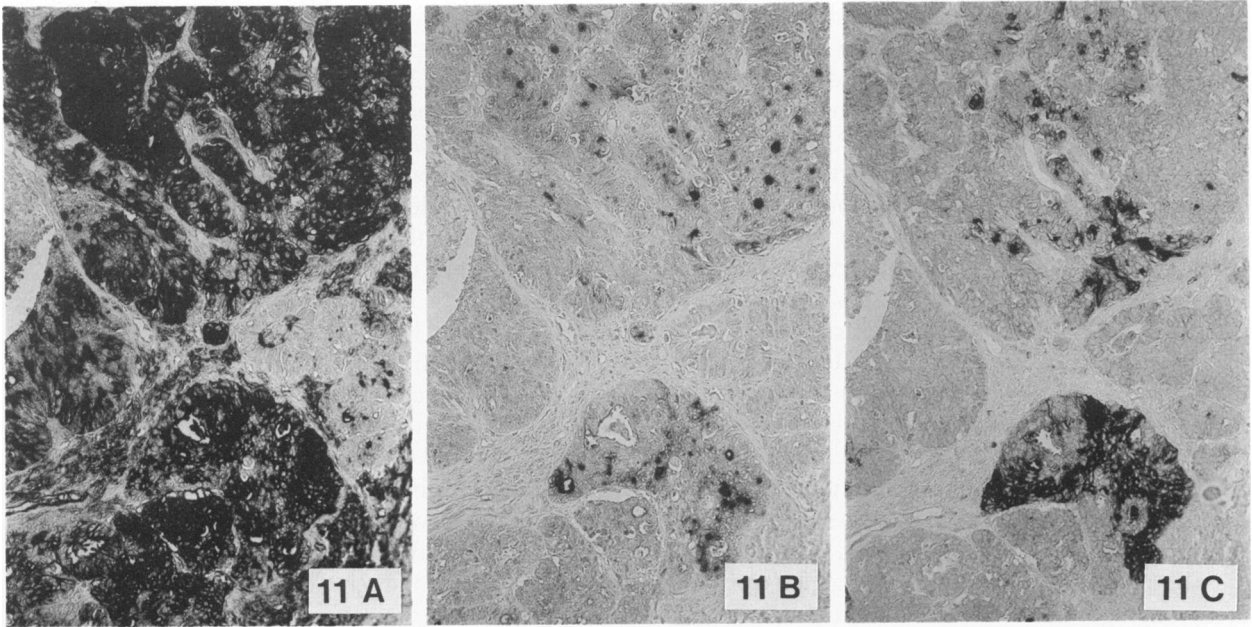


Figure 11—Moderately well differentiated granulosa cell tumor (Tumor 42). **A**—NSAP staining. **B**—NSAP staining in the presence of 1 mM L-p-bromotetramisole. **C**—PLAP staining (antibody 17E3). (A–C, adjacent sections, ×105) **Figure 12**—Dysgerminoma (Tumor 54). **A**—NSAP staining in the presence of 1 mM L-p-bromotetramisole. **B**—PLAP staining (antibody 17E3). (arrows indicate dotlike staining distribution on the cell surface). (A and B, ×265; inset, B, ×550)

tiation have the highest tendency to express PLAP, and that the distribution patterns of the six presently investigated markers in this category of tumors are similar to their patterns in the normal adult oviduct. The absence of PLAP in mucinous ovarian tumors contrasts with its expression in endocervical goblet cells.^{6,30} It supports, however, the concept that virtually all malignant mucinous ovarian tumors are of the colonic, instead of the endocervical, type.^{28,29} The absence of PLAP in the normal endometrial glandular epithelium has also been demonstrated previously

by heat-inactivation experiments,³⁰ but the fact that endometrial glandulocystic hyperplasia is frequently associated with PLAP expression (unpublished observations) again illustrates that also this müllerian epithelium possesses, like the ovarian surface epithelium, the capability to express PLAP under certain conditions. As a result, the expression of PLAP by different ovarian constituents after malignant transformation has a double embryonic basis, ie, a germinal-müllerian epithelial origin and probably also a germ cell origin.

Figure 8—Moderately well to poorly differentiated papillary serous adenocarcinoma (Tumor 15). **A**—PLAP staining (antibody 17E3). **B**—HMFG 2 staining. **C**—HMFG 1 staining. (A–C, adjacent sections, ×105) **Figure 9**—Poorly differentiated adenocarcinoma (Tumor 30). **A**—Homogeneous cytoplasmic HMFG 2 staining. **B**—CA 19-9 staining in isolated or clustered cells. (A and B, adjacent sections, ×131) **Figure 10**—Well-differentiated endometrioid carcinoma (Tumor 22). **A**—PLAP staining (antibody 17E3). **B**—HMFG 1 staining. **C**—CA 19-9 staining. (A–C, adjacent sections, ×105)

The use of three different monoclonal antibodies for the localization of PLAP in tissue sections of ovarian neoplasms results in virtually identical staining patterns, probably because they all react to some extent with different variants of PLAP, despite distinct differences in binding affinity in particular for L-leucine-sensitive PLAP. In some tumors, however, significant differences were observed in the PLAP staining intensity obtained with different antibodies, in spite of an identical histologic distribution of the staining. Some of these differences are due to the normal phenotypic diversity of PLAP, but other factors may also play a role. As demonstrated previously by heat inactivation, L-p-bromotetramisole inhibition, electrophoretic, and immunochemical evidence,⁴ the affinity of some antibodies for certain ovarian cancer associated forms of PLAP is decreased.

In all tumors PLAP staining is predominantly membranous and in general heterogeneously distributed, ranging from very scarce to uniform. The observation that the immunohistochemical patterns for PLAP for all antibodies are qualitatively similar to the patterns for NSAP in the presence of L-p-bromotetramisole, although the two methods are based on totally different biochemical principles, proves that the observed heterogeneous distribution patterns of PLAP, as also reported by others using other monoclonals and/or different histologic processing protocols (eg, cryostat sections),^{6,7} are not due to methodologic factors, but reflect the real distribution of PLAP. Therefore, although a cocktail of monoclonal antibodies may compensate to some extent for the biochemical heterogeneity of PLAP in ovarian neoplasms, it will not be able to remediate the histologic heterogeneity of the PLAP expression. This heterogeneity occurs also in the normal PLAP-producing tissues, eg, the lung¹⁹ and oviduct,³¹ confirming that antigenic heterogeneity is not just a property of tumors, but of a wide range of normal epithelia,³ and that the expression of PLAP is restricted to certain stages in the cell cycle³² and/or to certain types of cellular differentiation. The observation that well-differentiated papillary serous (cyst)adenocarcinomas have a slightly higher PLAP expression than the rather poorly differentiated tumors of this group is a further illustration of this. In comparison, CA 125 expression seems to be associated with a broader spectrum of cellular differentiation, because unlike PLAP, it is produced by undifferentiated normal adult and fetal mesothelial cells and by their more or less specialized descendants. Furthermore, all these epithelia are quite homogeneous in the expression of CA 125. The same is true for HMFG, which is expressed by many different normal epithelia.³³ It is therefore not surprising that most

ovarian tumors investigated are nearly homogeneous in the expression of CA 125 and HMFG. The non-identity of CA 125 and HMFG is indicated by occasional discordances in their occurrence, by the more cytoplasmic character of HMFG 2, and by their strongly different distribution patterns in other tumors and various normal tissues.

In our study, the frequency of CA 125 positivity in different tumor types was even higher than reported by others.^{10,34,35} The only PLAP-positive tumor lacking CA 125 and HMFG was a dysgerminoma, hereby illustrating its different embryonic origin. Although the existence of a mucinous substance containing the CA 125 as well as the CA 19-9 determinant has been described,²⁴ and although CA 125 immunoreactivity has also been observed in goblet cells of the normal respiratory airways and respiratory mucoserous glands,¹⁹ such a mucinous substance apparently is not present in the ten mucinous tumors investigated here. The presence of CA 125 in normal endocervical mucosa and its absence in mucinous tumors and normal colonic mucosa again supports the colonic type of differentiation of these tumors. This concept is also confirmed by their frequent CEA expression.

According to our results, CA 19-9 is detectable in 82% of mucinous tumors, but also in 55% of serous and other nonmucinous ovarian carcinomas. Its histochemical distribution was in nearly all cases very heterogeneous and often scarce. Differences between our results and available data indicating that CA 19-9 expression in ovarian cancer is principally a property of mucinous tumors^{34,35} may be due to differences in tissue processing methods.

Our staining results for CEA are intermediate between available data mostly obtained with polyclonal antisera.³⁶⁻³⁸ Because CEA belongs to a group of closely related substances,^{39,40} differences in CEA staining results are at least partially due to differences in the specificity of the antibodies. The low degree of CEA expression in epithelial ovarian neoplasms is consistent with its absence in germinal inclusion cysts and in normal müllerian duct-derived epithelia.

Since each of the six antigens is detectable in several types of benign and malignant ovarian tumors, immuno(histo)chemical analysis for the presence of these antigens is of no use of a differential diagnosis but may be valuable for evaluating the opportuneness of diagnostic or therapeutic immunotargeting. There is also no apparent relation between the expression and histologic distribution of the six antigens studied, which results in a partial complementarity and overlapping. Of the six presently investigated tumor-associated antigens, PLAP has the most limited expression in normal tissues.^{19,23,33,41}

In conclusion, because a substantial number of ovarian carcinomas contain an important number of PLAP-expressing malignant cells, because PLAP is predominantly localized on the surface of these cells and because most normal tissues are negative, PLAP may be useful as a tumor marker for ovarian cancer. The frequent expression of PLAP by ovarian neoplasms has a double embryonic basis, ie, a müllerian epithelial and probably a germ-cell one. Different monoclonal antibodies against PLAP are unable to overcome the histologic heterogeneity of the PLAP expression. This should be taken into account when one is planning PLAP-targeted immunotherapy of ovarian cancer; and, in view of the observation that the expression of the presently investigated markers is largely independent, combination of anti-PLAP monoclonals with antibodies against other specific markers should be considered.

References

- Hockey MS, Stokes HJ, Woodhouse CS, Macdonald F, Fielding JW, Ford CH: Carcinoembryonic antigen (CEA) expression and heterogeneity in primary and autologous metastatic gastric tumours demonstrated by a monoclonal antibody. *Br J Cancer* 1984, 49:129-133
- Hernandez E, Rosenheim NB, Bhagavan BS, Parmley TH: Tumor heterogeneity and histopathology in epithelial ovarian cancer. *Obstet Gynecol* 1984, 63:330-334
- Edwards PAW: Heterogenous expression of cell-surface antigens in normal epithelia and their tumours, revealed by monoclonal antibodies. *Br J Cancer* 1985, 51:149-160
- Nouwen EJ, Pollet DE, Schelstraete JB, Eerdekens MW, Hänsch C, Van de Voorde A, De Broe ME: Human placental alkaline phosphatase in benign and malignant ovarian neoplasia. *Cancer Res* 1985, 45:892-902
- Miller FR: Intratumor immunologic heterogeneity. *Cancer Metast Rev* 1982, 1:319-334
- Sunderland CA, Davies JO, Stirrat GM: Immunohistology of normal and ovarian cancer tissue with a monoclonal antibody to placental alkaline phosphatase. *Cancer Res* 1984, 44:4496-4502
- McDicken IW, McLaughlin PJ, Tromans PM, Luesley DM, Johnson PM: Detection of placental-type alkaline phosphatase in ovarian cancer. *Br J Cancer* 1985, 52:59-64
- Epenetos AA, Mather S, Granowska M, Nimmon CC, Hawkins LR, Britton KE, Shepherd J, Taylor-Papadimitriou J, Durbin H, Malpas JS: Targeting of iodine-123-labelled tumour-associated monoclonal antibodies to ovarian, breast, and gastrointestinal tumours. *Lancet* 1982, 2:999-1004
- Bast RC, Feeney M, Lazarus H, Nadler LM, Colvin RB, Knapp RC: Reactivity of a monoclonal antibody with human ovarian carcinoma. *Am Soc Clin Invest* 1981, 68:1331-1336
- Kabawat SE, Bast RC, Welch WR, Knapp RC, Colvin RB: Immunopathologic characterization of a monoclonal antibody that recognizes common surface antigens of human ovarian tumors of serous, endometrioid, and clear cell types. *Am J Clin Pathol* 1983, 79:98-104
- Koprowski H, Steplewski Z, Mitchell K, Herlyn M, Herlyn D, Fuhrer P: Colorectal carcinoma antigens detected by hybridoma antibodies. *Somatic Cell Genet* 1979, 5:957-972
- Magnani JL, Nilsson B, Brockhaus M, Zopf D, Steplewski Z, Koprowski H, Ginsburg V: A monoclonal antibody-defined antigen associated with gastrointestinal cancer is a ganglioside containing sialylated lacto-N-fucopentaose II. *J Biol Chem* 1982, 257:365-369
- Falk KE, Karlsson KA, Larson G, Thurin J, Blaszczyk M, Steplewski Z, Koprowski H: Mass spectrometry of a human tumor glycolipid antigen being defined by mouse monoclonal antibody NS-19-9. *Biochem Biophys Res Commun* 1983, 100:383-391
- Hendrix PG, Nouwen EJ, Briers TW, Martens E, Pollet DE, De Broe ME: Biochemical and immunochemical analysis of the molecular heterogeneity of placental alkaline phosphatase from tumor cells. (Manuscript in preparation)
- De Groote G, De Waele P, Van de Voorde A, De Broe ME, Fiers W: Use of monoclonal antibodies to detect human placental alkaline phosphatase. *Clin Chem* 1983, 29:115-119
- Travers PJ, Bodmer WF: Preparation and characterisation of monoclonal antibodies against placental alkaline phosphatase and other trophoblast associated determinants. *Int J Cancer* 1984, 33:633-641
- Taylor-Papadimitriou J, Peterson JA, Arklie J, Burchell J, Ceriani RL, Bodmer WF: Monoclonal antibodies to epithelium-specific components of the human milk fat globule membrane: Production and reaction with cells in culture. *Int J Cancer* 1981, 28:17-21
- Gossrau R: Azoindoxylverfahren zum hydrolasenachweis. IV. Zur eignung verschiedener diazolumsalze. *Histochemie* 1978, 57:323-342
- Nouwen EJ, Pollet DE, Eerdekens MW, Hendrix PG, Briers TW, De Broe ME: Immunohistochemical localization of placental alkaline phosphatase, carcinoembryonic antigen and cancer antigen 125 in normal and neoplastic human lung. *Cancer Res* 1986, 46:866-876
- Van Belle H, De Broe ME, Wieme J: L-p-bromotetramisole, a new reagent for use in measuring placental or intestinal isoenzymes of alkaline phosphatase in human serum. *Clin Chem* 1977, 23:454-459
- Eerdekens MW, Nouwen EJ, Pollet DE, Briers TW, De Broe ME: Human placental alkaline phosphatase and cancer antigen 125 in sera of patients with benign and malignant diseases. *Clin Chem* 1985, 31:687-690
- Pollet DE, Nouwen EJ, Schelstraete JB, Renard J, Van de Voorde A, DeBroe ME: Enzyme-antigen immunoassay to human placental alkaline phosphatase in serum and tissue extracts, and its application as a tumor marker. *Clin Chem* 1985, 31:41-45
- De Broe ME, Nouwen EJ, Pollet DE, Eerdekens MW, Briers TW, Hendrix PG: Human placental alkaline phosphatase as a tumour marker. *Adv Clin Enzymol* 1986, 3:39-52
- Bast RC, Knapp RC: CA 125 antigen for diagnosis and monitoring of epithelial ovarian carcinoma. Proceedings of the international meeting on Monoclonal Antibodies in Oncology: Clinical Applications. Nantes, June 1984. Edited by JF Chatal, M Douis. Nouvelles Editions Médicales Françaises, 1984, pp 35-38
- Paiva J, Damjanov I, Lange PH, Harris H: Immunohistochemical localization of placental-like alkaline phosphatase in testis and germ-cell tumors using monoclonal antibodies. *Am J Pathol* 1983, 111:156-165
- Epenetos AA, Travers P, Gatter KC, Oliver RDT, Mason DY, Bodmer WF: An immunohistological

- study of testicular germ cell tumours using two different monoclonal antibodies against placental alkaline phosphatase. *Br J Cancer* 1984, 49:11-15
27. Shinoda J, Miwa Y, Sakai N, Yamada H, Shima H, Kato K, Takahashi M, Shimokawa K: Immunohistochemical study of placental alkaline phosphatase in primary intracranial germ-cell tumors. *J Neurosurg* 1985, 63:733-739
 28. Dallenbach-Hellweg G: On the histogenesis and morphology of ovarian carcinomas. *J Cancer Res Clin Oncol* 1984, 107:71-80
 29. Russell P: Common epithelial tumours of the ovary: A new look. *Pathology* 1984, 17:555-557
 30. Goldstein DJ, Blasco L, Harris H: Placental alkaline phosphatase in nonmalignant human cervix. *Proc Natl Acad Sci USA* 1980, 77:4226-4228
 31. Van de Voorde A, Serreyn R, De Boever J, De Waele P, Vandekerckhove D, Fiers W: The occurrence of human placental alkaline phosphatase (PLAP) in extracts of normal, benign, and malign tissues of the female genital tract. *Tumour Biol* 1985, 6:545-553
 32. Fishman WH: Oncotrophoblast gene expression: Placental alkaline phosphatase. *Adv Cancer Res* (In press)
 33. Arklie J, Taylor-Papadimitriou J, Bodmer W, Egan M, Millis R: Differentiation antigens expressed by epithelial cells in the lactating breast are also detectable in breast cancers. *Int J Cancer* 1981, 28:23-29
 34. Kremer M, Chatal JF, Curtet C, Douillard JY: The immunohistochemical reactivity of monoclonal antibodies with tissue sections of human ovarian tumors, Proceedings of the Eleventh Annual Meeting of the International Society for Oncodevelopmental Biology and Medicine, Stockholm, Sweden, September 1983
 35. Kremer M: Diagnostic immunohistochimique des tumeurs ovariennes avec 1' anticorps monoclonal OC 125,²⁴ pp 39-41
 36. Van Nagell JR, Donaldson ES, Gay EC, Sharkey RM, Rayburn P, Goldenberg DM: Carcinoembryonic antigen in ovarian epithelial cystadenocarcinomas: The prognostic value of tumor and serial plasma determinations. *Cancer* 1978, 41:2335-2340
 37. Heald J, Buckley CH, Fox H: An immunohistochemical study of the distribution of carcinoembryonic antigen in epithelial tumours of the ovary. *J Clin Pathol* 1979, 32:918-926
 38. Malkin A, Kellen JA, Lickrish GM, Bush RS: Carcinoembryonic antigen (CEA) and other tumor markers in ovarian and cervical cancer. *Cancer* 1978, 42:1452-1456
 39. Kuroki M, Koga Y, Matsuoka Y: Monoclonal antibodies to carcinoembryonic antigen: a systematic analysis of antibody specificities by using related normal antigens and evidence for allotypic determinants on carcinoembryonic antigen. *J Immunol* 1984, 133:2090-2097
 40. Yachi A, Imai K, Fujita H, Moriya Y, Tanda M, Endo T, Tsujisaki M, Kawaharada M: Immunohistochemical distribution of the antigenic determinants detected by monoclonal antibodies to carcinoembryonic antigen. *J Immunol* 1984, 132:1998-2004
 41. Atkinson BF, Ernst CS, Herlyn M, Stepkowski Z, Sears HF, Koprowski H: Gastrointestinal cancer associated antigen in immunoperoxidase assay. *Cancer Res* 1982, 42:4820-4823

Acknowledgments

We wish to thank Dr. André Van de Voorde (Department of Molecular Biology, State University of Ghent, Belgium) for providing us the monoclonal antibody E6, Dr. Robert C. Bast (Department of Medicine, Duke University Medical Center, Durham, NC) for the batch of antibody OC 125, Dr. Hilary Koprowski (The Wistar Institute, Philadelphia, Pa) for the batch of monoclonal antibody 1116 NS 19-9, Dr. Joyce Taylor-Papadimitriou (Imperial Cancer Research Fund, London, UK) for the batches of antibody HMFG 1 and HMFG 2, and Drs. P. J. Den Houwdyker, J. Renard, L. Delbeke, P. Buytaert, F. Uytendroek, I. De Wever, and J. Claeys for providing some of the biopsy specimens. The technical assistance of R. Marynissen was gratefully acknowledged.