

Histopathologic Changes Induced by Vaccination in Experimental Cutaneous Leishmaniasis of BALB/c Mice

MANOEL BARRAL-NETTO,
LUIZ ANTONIO R. de FREITAS, and
ZILTON A. ANDRADE

From Gonçalo Moniz Research Centre (FIOCRUZ) and
Federal University of Bahia, Bahia, Brazil

Highly susceptible BALB/c mice became partially resistant to *Leishmania mexicana amazonensis* infection after intravenous immunization with solubilized homologous promastigote antigen. Immunized BALB/c mice exhibited mixed mononuclear cell reactions, with granulomatous inflammation, collagen deposition, and fibrinoid necrosis at the site of infection. In contrast, naive animals displayed a monomorphic picture composed of largely vacuolated and parasitized

macrophages with areas of coagulative necrosis. Electron microscopy revealed an increased number of eosinophils, sometimes in close contact with parasitized macrophages, in immunized animals. These findings illustrate that histologic changes reflect host immune status in cutaneous leishmaniasis, and that susceptibility of BALB/c mice to *L. m. amazonensis*, although dependent on genetic background, can be artificially modified. (Am J Pathol 1987, 127:271-278)

SEVERAL ATTEMPTS have been made to correlate histopathologic changes with prognosis in human cutaneous and mucocutaneous leishmaniasis.¹⁻³ The findings observed during the experimental infection of susceptible and resistant inbred strains of mice can also indicate which are the main histologic changes associated with prognosis.⁴

Despite the clearcut differences in the course of the infections with agents of cutaneous leishmaniasis observed in these strains of mice, it is difficult to discriminate factors really involved in resistance from those due to diverse genetic backgrounds, but not implicated in specific immunity.

Another way to address this question is to use animals of the same inbred strain, with identical genetic backgrounds, but differing in susceptibility to the parasite. Such is possible by immunizing susceptible animals. In the present study we took advantage of an immunization protocol which rendered BALB/c mice partially resistant to *Leishmania mexicana amazonensis*⁵ and compared the evolution of the lesions to their susceptible inbred counterparts.

Materials and Methods

Animals

Inbred BALB/c mice were obtained from the CPqGM colony (Salvador-Bahia) and were used at

10-14 weeks of age. Animals were maintained on pellet mouse ration and water *ad libitum*.

Parasites

The "Josefa" strain (MHOM/Br/76/Josefa) of *L. m. amazonensis* (as characterized by isoenzyme patterns, a panel of monoclonal antibodies, as well as kDNA restriction analysis) was used for both infection and antigen preparation.

Antigen Preparation

Stationary-phase promastigotes were obtained on liver infusion tryptose medium supplemented with 5% fetal calf serum (LIT-FCS). After washing three times in phosphate-buffered saline with 2% glucose (PBS-G), parasites were resuspended in "lysing buffer" (50 mM Tris, pH 7.7; 0.12 N NaCl; 0.5% NP-40; 0.25% sodium deoxyxholate; 5TIU/ml aprotinin; 5 mM EDTA) at a concentration of 10⁹ pro-

Supported by the Brazilian National Research Council (CNPq) Grant 40-0634/85.

Accepted for publication December 16, 1986.

Address reprint requests to Dr. Manoel Barral-Netto, Hospital Professor Edgard Santos, Rua João das Botas s/n Canela, 40000 Salvador, Bahia, Brazil.

mastigotes/ml. The material was incubated for 10 minutes at room temperature (under occasional mixing) and then submitted to dialysis against 500 volumes of PBS at 4 C. Concentration of the material is expressed as "parasite equivalent per milliliter" (pe/ml), as a function of initial number of promastigotes and final volume of the preparation.

Immunization and Infection

Mice were given intravenous injections in 3 weekly doses of solubilized antigen at 5×10^7 pe/ml in volumes of 0.2 ml (unimmunized mice received an equal volume of PBS at the same dates). One week after the last immunizing dose, mice were challenged subcutaneously in the left hind footpad with 5×10^6 viable promastigotes in 0.025 ml. Footpad thickness was measured periodically with a dial gauge micrometer caliper (C. Starret, Athol, Mass). Differences between the infected footpad and the contralateral uninfected one were expressed as "lesion size" in millimeters.

Assay for Anti-*L m amazonensis* Antibody Titers

An enzyme-linked immunosorbent assay (ELISA) was performed with homologous promastigote antigen. Microtiter plates were sensitized with 1 μ g of protein per well in a carbonate-bicarbonate buffer, pH 9.6. After washing three times with PBS containing 0.05% Tween 20 (PBS-Tween) serial dilution of sera were incubated for 1 hour at 37 C, followed by three washings with PBS-Tween. Peroxidase-conjugated rabbit anti-mouse IgG (Sigma, St. Louis, Mo) diluted 1 : 1000 in PBS + 10% newborn bovine serum was incubated for 1 hour at 37 C. After further washing the substrate solution (0.04% ortho-phenylenediamine, 0.012% hydrogen peroxide in pH 5.0 citrate phosphate buffer) was added. Reaction was stopped by adding 8N sulphuric acid (0.025 ml/well) after a 30-minute incubation at room temperature in the dark. Plates were read in a Titertek Multiskan spectrophotometer (Flow Laboratories, Ayreshire, Scotland, UK) at 495 nm.

Assay for Delayed Type Hypersensitivity (DTH)

L m amazonensis promastigotes cultured on LIT-FCS were used as the antigen source, and the footpad swelling test performed as described elsewhere.⁶ In brief, mice received 50 μ g protein os leishmanial antigen (0.025 ml into the ventral aspect of the uninfected hind footpad). Measurements were performed with a dial gauge caliper as indicated above. Results are presented as the thickness (mm $\times 10^{-2}$) measured 24

hours after antigen injection minus the thickness before injection (Δ DTH).

Histopathology

At 2, 10, and 13 weeks after infection the lesions were removed and placed in Bouin's fluid for about 1 hour. After hardening they were recut and trimmed and left in the fixative for another 12 hours. The bone-containing lesions were decalcified in EDTA. Tissues were embedded in paraffin, and the sections were stained with hematoxylin and eosin (H&E).

Electron Microscopy

Small fragments from the footpad lesions were immediately fixed in ice-cold 2% glutaraldehyde in 0.1 M cacodylate buffer for 1 hour, postfixed in OsO₄, washed in the buffer, dehydrated in graded ethanol, and embedded in Spurr's resin. Semithin sections were cut on a Reichert-Jung Ultracut E microtome with glass knives. They were mounted on glass slides and stained with methylene blue-azur II. Ultrathin sections were cut with a diamond knife, picked up on copper grids, and contrasted with uranyl acetate and lead citrate. Observations were carried out on a Zeiss EM-109 electron microscope at 50 kv.

Statistical Analysis

Group means were compared by the Student *t* test. For comparison of antibody titers log transformed data were used.

Results

Growth of Primary Lesion

Groups of 10 BALB/c mice were immunized intravenously with three doses of solubilized promastigote antigen, at weekly intervals, or maintained without immunization. After challenge infection with 5×10^6 viable promastigotes, immunized mice exhibited much smaller lesions than unimmunized animals (Figure 1A). Unimmunized animals had progressive growth of lesions, reaching huge volumes, associated with distention of the covering skin and exhibiting large necrotic areas. On the other hand, lesions in immunized mice were small and ulcerative and never appeared as large masses.

DTH Responses

Unimmunized BALB/c mice developed a transient low level DTH response at 7 weeks after infection,

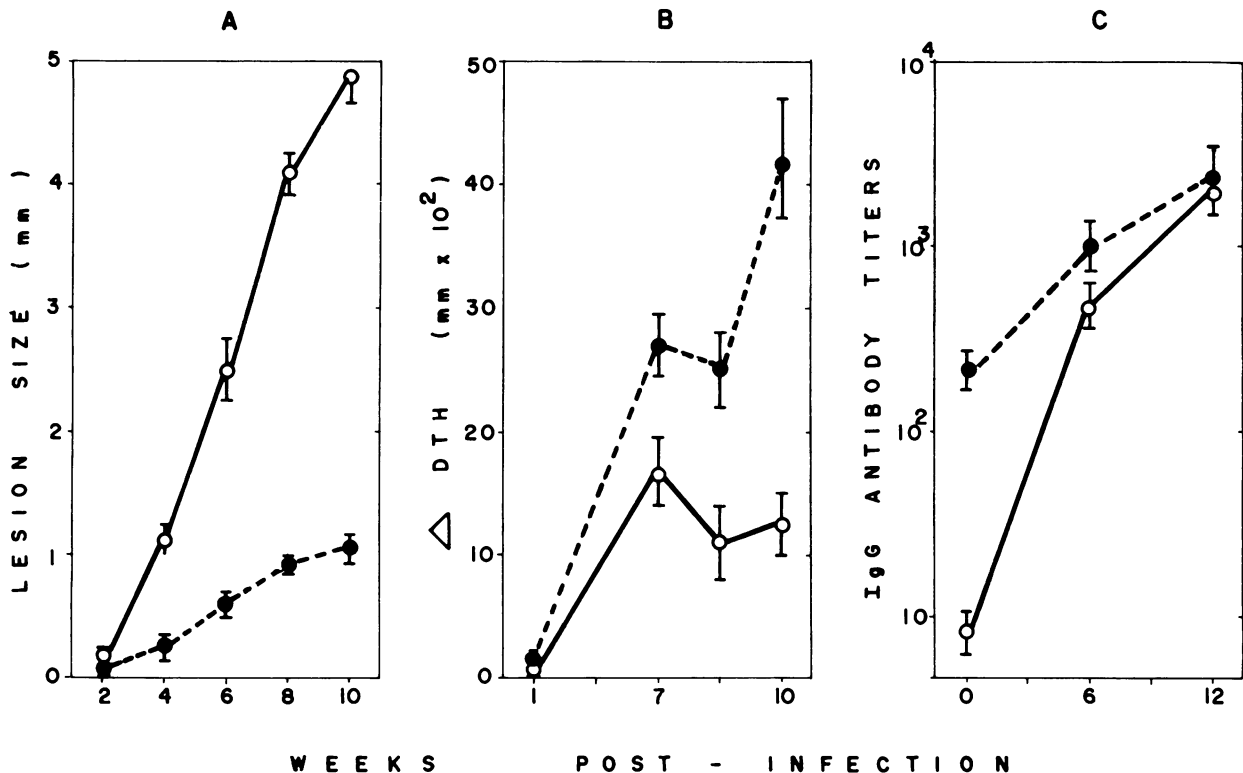


Figure 1—Demonstrative of lesion size (a), DTH reaction (b), and antibody titers (c) in immunized and unimmunized BALB/c mice infected with *L. m. amazonensis*. —, unimmunized; ----, immunized.

followed by a decreased response up to the end of the observation period. In contrast, immunized mice exhibited stronger DTH reactivity, which was persistently positive (Figure 1B). Differences were statistically significant at 10 weeks ($P < 0.05$) and 13 weeks ($P < 0.02$) after infection.

Antibody Production

Immunization by itself induced high IgG anti-leishmanial antibody titers, explaining the big difference between immunized and naive animals before the infection. After 6 weeks of infection, the difference in antibody titer was no longer significant; and titers were virtually identical 12 weeks after infection (Figure 1C).

Histopathology

The lesions observed in the footpad of immunized and naive mice 2 weeks after inoculation looked alike. They were represented by a moderate and diffuse infiltration of lymphocytes and a few plasmocytes and polymorphonuclear eosinophils, which were located at the dermis, but extended for some distance into the skeletal muscles. Among these cells there were several

small collections of parasitized macrophages. These latter cells exhibited a large, clear, and vacuolated cytoplasm containing numerous *Leishmania* organisms. However, some differences could be noted between the two groups of animals when details of the microscopic picture were comparatively analysed. In the immunized mice the clusters of parasitized macrophages were less frequently seen and contained fewer parasites as compared with naive mice. Also, in the immunized mice the diffuse mononuclear infiltration was in some cases predominantly lymphoplasmocytic, rather than lymphocytic, and a mild degree of fibroblastic proliferation and collagen deposition could be observed in focal areas, as well as a few microscopic foci of fibrinoid necrosis. On the other hand, small patchy areas of coagulative necrosis were detected in all nonimmunized mice and in only one immunized mouse.

A clear-cut difference appeared in the lesions observed 10 and 13 weeks after inoculation. At this time the changes in the naive mice were represented by an extensive and monomorphic collection of vacuolated and parasitized macrophages that resembled fatty tissue when seen with low-power microscopy (Figure 2A). This monotonous picture was only altered by the frequent appearance of areas of coagulative necrosis.

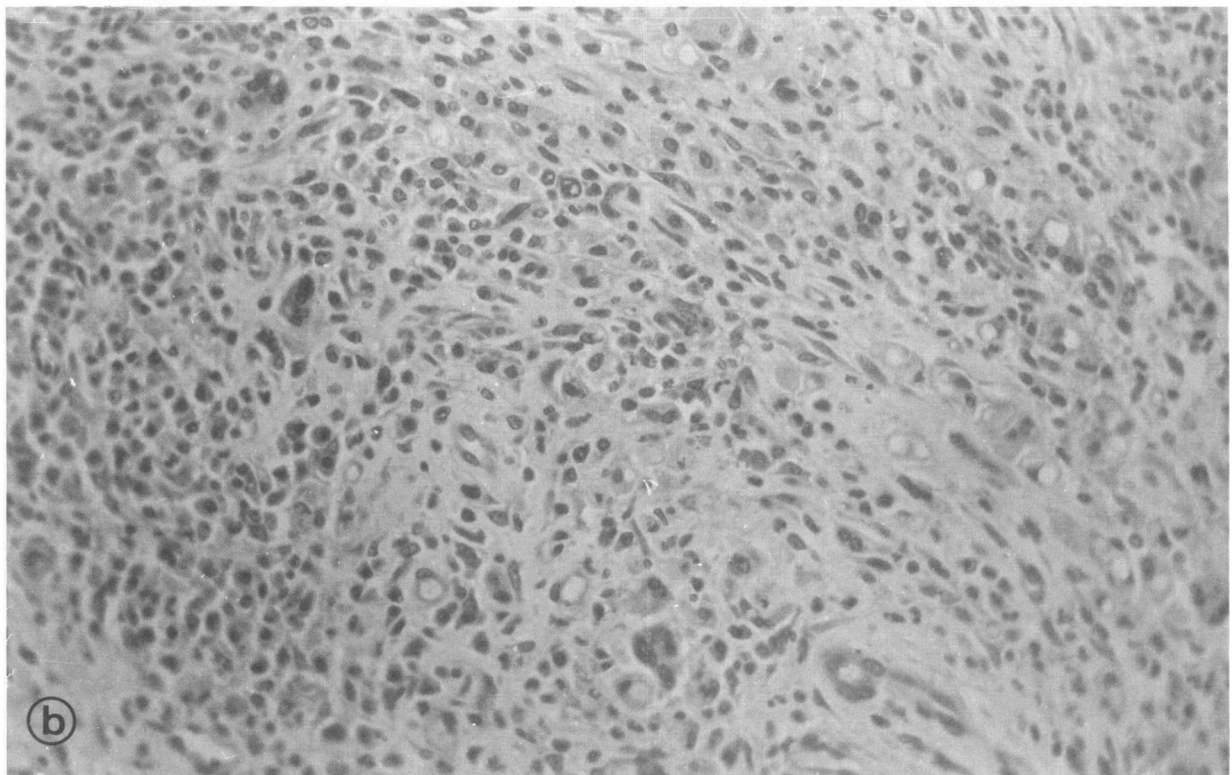
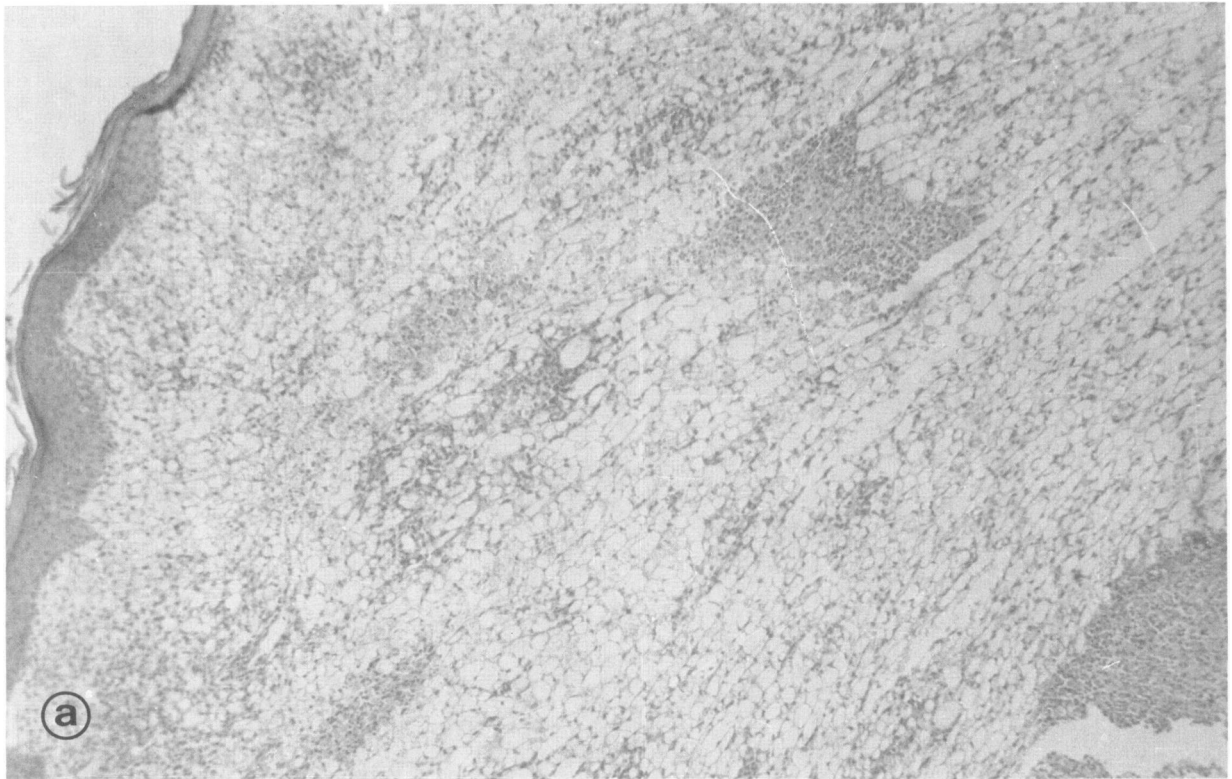


Figure 2a—Extensive collection of vacuolated and parasitized macrophages with focal areas of purulent necrosis, a typical picture of the established lesion caused by *L m amazonensis* in the naive BALB/c mouse. (H&E, $\times 100$) **b**—The most frequent histologic picture seen in BALB/c mice immunized against and challenged with *L m amazonensis*, a mixed cell reaction with diffuse fibrosis, giant cell formation, and scattered parasitized macrophages. (H&E, $\times 200$)

These focal areas, which appeared eosinophilic and poorly stained, were frequently invaded by numerous polymorphonuclear leukocytes presenting variable degrees of disintegration ("purulent necrosis"). Clusters of parasitized cells were seen dissociating the skeletal muscle fibers and sometimes invading the bone marrow more deeply situated over the footpad. At the periphery of the lesion a cuff of small lymphocytes could be noted, but there was no definite fibrous capsule. Fibrinoid necrosis was never observed in the leishmanial lesions of these naive mice.

In the vaccinated animals the lesions were represented by a mixed-cell inflammatory reaction, with only a few scattered parasitized macrophages. The small lymphocyte was the predominating cell, but many nonparasitized macrophages, plasmocytes, and eosinophils were also present. The infiltration tended to assume a focal pattern, the collection of inflammatory cells sometimes appearing separated by dense fibrous septa. Frequently a granulomatous reaction was noted, with accumulation of undifferentiated macrophages, epithelioid cells, and multinucleated giant cells (Figure 2B). The number of eosinophils was variable from case to case. Usually the eosinophils appeared in moderate numbers and with a diffuse distribution. Around and within the areas of fibrinoid necrosis they could be seen focally accumulated. Focal fibrinoid necrosis was an outstanding feature. Besides the eosinophilic fibrinoid filaments, disintegrating parasites and a few cells could also be noted within the necrotic areas. Around these areas there appeared some fibroblasts, which seemed to be involved in an organizing process in later lesions. Fibroblast proliferation and collagen formation appeared as an active process throughout the lesion, giving rise to a more or less dense stroma for the inflammatory cells, as well as forming fibrous septa and an external capsule. In one instance the footpad lesion was represented by a fibrous nodule, in the interior of which there were isolated small collections of mononuclear inflammatory cells, including a few parasitized macrophages. No involvement of neighboring skeletal muscles or bone was seen in vaccinated mice.

Electron Microscopy

The material from early lesions (2 weeks) showed more parasitized macrophages and eosinophils, as well as some necrotic macrophages, in the immunized than in unimmunized animals (Figure 3A).

Later lesions (13 weeks) disclosed large macrophages containing several well-preserved *Leishmania* organisms within parasitophorous vacuoles. Rarely,

Leishmania could be observed within the macrophages in the absence of a defined parasitophorous vacuole. A few polymorphonuclear eosinophils appeared among the macrophages, sometimes with close contact of their respective external membranes.

Lesions in the immunized animals showed many nonparasitized macrophages with many inderting cytoplasmic processes, a few primary lysosomes, residual bodies, and well-developed endoplasmic reticulum. Fibroblasts and collagen fibers were frequently observed. Some macrophages were necrotic and in their vicinity *Leishmania* appeared degenerated in the interstitial tissue or phagocytosed by polymorphonuclear, especially eosinophils (Figure 3B and C).

Discussion

Intravenous immunization of BALB/c mice with solubilized promastigotes altered immunoregulatory mechanisms in these animals, rendering them partially resistant to leishmanial infection.^{5,7} Although the precise mechanism of action is not known, there are some likely explanations for the phenomenon. First, the effect does not seem to depend solely on a reduction of the initial parasite burden. It has been shown that BALB/c mice develop the characteristic uncontrolled course of the disease even when infected with only 50 promastigotes of *Leishmania l major*.⁷ In the present case, both the gross and the histologic pictures were drastically altered. The monotonous histopathologic aspects of the lesion, composed of vacuolated macrophages, which characterized the leishmanial infection of BALB/c mice,⁴ changed to a picture that is generally described for resistant strains.^{4,8} It is interesting to note that some features taken as representative for a good prognosis in human^{3,8,11} and experimental cutaneous leishmaniasis,^{4,9} such as fibrosis, fibrinoid necrosis, and granulomatous inflammation, were outstanding findings in the immunized animals.

The present findings stand as a good example of how histopathologic features may reflect variations in the host immune status. While the lesions in the naive and susceptible BALB/c mice tended to present a homogeneous and regular appearance, as described previously both in human cutaneous diffuse leishmaniasis^{10,11} and in susceptible animals,^{4,12} in the immunized animals the lesions were characterized by their variability. Such variability from one animal to another probably represented different degrees of immunity brought about by vaccination. Confirming previous reports,^{2-4,6} the histologic features probably related to resistance were the presence of a mixed

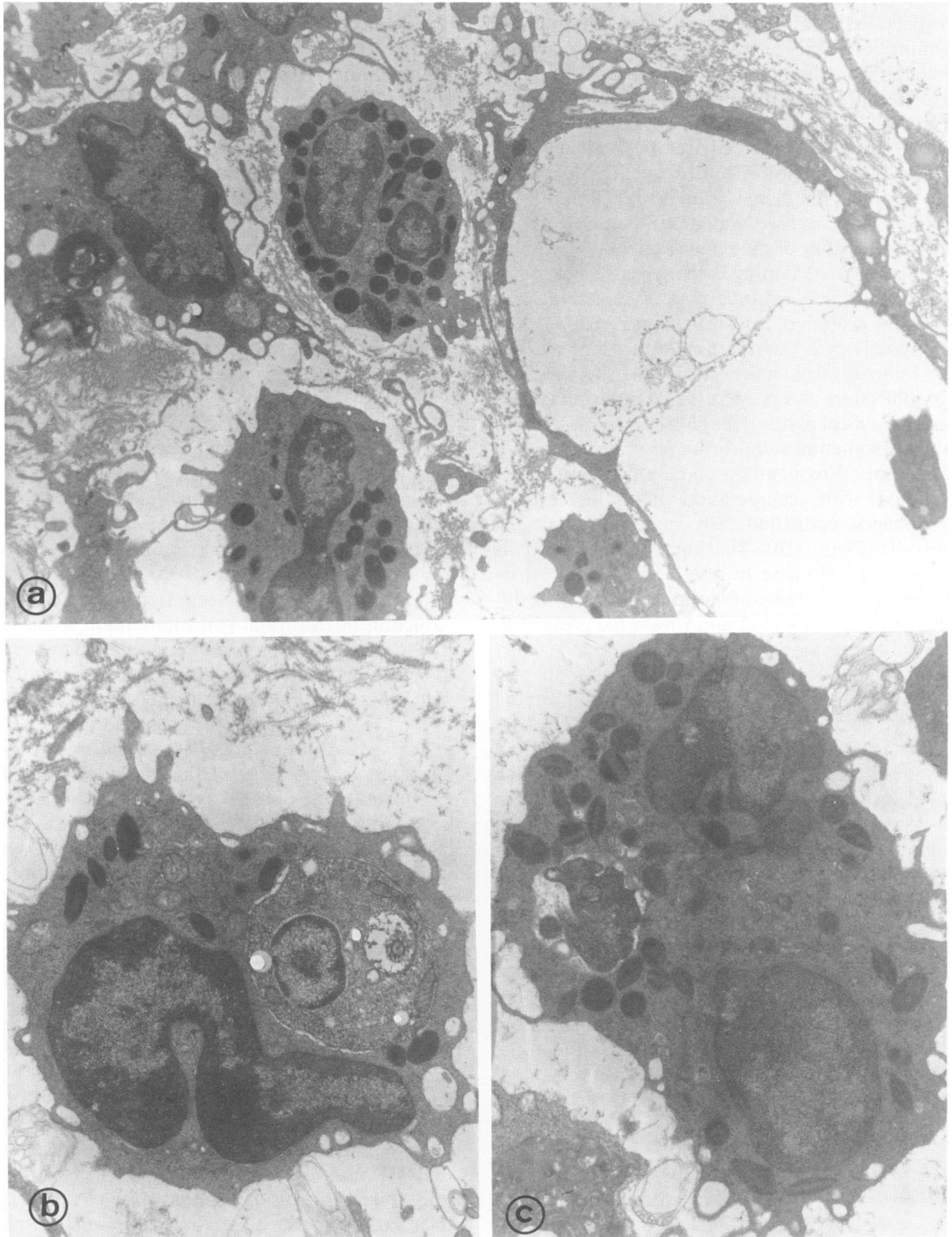


Figure 3a—Electron micrograph showing a vacuolated macrophage and eosinophils in its proximity, as frequently seen in immunized animals. (X3000) **b**
and **c**—Eosinophils phagocytosing *Leishmania* organisms which are exhibiting variable degrees of degenerative changes. (X7000)

mononuclear cell reaction, fibrinoid necrosis, granulomatous inflammation, and collagen deposition. There also were signs that the majority of *Leishmania* organisms were killed outside the macrophages, in interstitial tissue, in areas of necrosis, and phagocytosed by polymorphonuclear cells, eosinophils, and neutrophils. In fact, eosinophils were frequently observed at the ultrastructural level in the lesions of vaccinated mice. They not only appeared phagocytosing degenerating *Leishmania* organisms, but were in intimate contact with the external membrane of the parasitized macrophages. Whether some important cooperation between these cells develops after immunization is a question for future research.

Secondly, it is possible that complement activation in animals with high antibody titers is responsible for attracting larger numbers of polymorphonuclear leukocytes in the inflammatory response observed in immunized mice. The lack of a protective effect of sera from immunized animals injected into naive recipients¹³ militates against this hypothesis. If polymorphonuclear cells are important in controlling parasite growth,¹⁴ their recruitment is probably due to cellular mechanisms, through lymphokine production, for example. The latter could also account, probably, for a more efficient *Leishmania*-clearing mechanism—tissue necrosis.²⁻⁴ This refers us to the third point, that of the T-cell function. Concerning the role of the T cells, two different explanations exist related to the rather opposing views of the immunopathogenesis of leishmaniasis in BALB/c mice. If one considers the disease in such a strain of mice as a consequence of generation of a potent suppressor T cell,^{15,16} the immunization may have circumvented its generation, or, alternatively, may have stimulated a contrasuppressive mechanism. In keeping with the view of exacerbated T-helper function as a cause of the uncontrolled disease in BALB/c mice,¹⁷⁻¹⁹ the protective effect would follow the generation of a suppressor cell. If this is the case, such a suppressor cell may be able to decrease, but not abrogate, the T-helper activity, because immunized mice remain with positive DTH responses and produce high levels of anti-leishmanial antibodies. It is noteworthy that the above explanations for the disease in BALB/c mice were derived from studies using animals infected with *L major*, and different immunoregulatory mechanisms may be operative with *Leishmania* species from the New World.²⁰

Our data show that immunization can partially overcome the susceptibility of BALB/c mice to *L m amazonensis*, a putative model of human diffuse cutaneous leishmaniasis. Although intravenous immunization is hardly to be recommended for use in

humans, it can open the possibility of immunoprophylaxis in selected populations.

References

1. Bryceson ADM: Diffuse cutaneous leishmaniasis in Ethiopia: I. The clinical and histological features of the disease. *Trans R Soc Trop Med Hyg* 1969, 63:708-737
2. Ridley DS, Marsden PD, Cuba CC, Barreto A: A histological classification of mucocutaneous leishmaniasis in Brazil and its clinical evaluation. *Trans Soc Trop Med Hyg* 1980, 74:508-521
3. Destombes P: Application du concept de "systematization polaire" aux leishmanioses cutanées. *Bull Soc Pathol Exot* 1960, 53:299-301
4. Andrade ZA, Reed SG, Roters S, Sadigursky M: Immunopathology of experimental cutaneous leishmaniasis. *Am J Pathol* 1984, 114:137-148
5. Barral-Netto M, Reed SG, Sadigursky M, Sonnenfeld G: Specific immunization of mice against *Leishmania mexicana amazonensis* using solubilized promastigotes. *Clin Exp Immunol* (In press)
6. Barral A, Petersen EA, Sacks DL, Neva FA: Late metastatic leishmaniasis in the mouse. A model for mucocutaneous disease. *Am J Trop Med Hyg* 1983, 32:277-285
7. Howard JG, Nicklin S, Hale C, Liew FY: Prophylactic immunization against experimental leishmaniasis: I. Protection induced in mice genetically vulnerable to fatal *Leishmania tropica* infection. *J Immunol* 1982, 129:2206-2212
8. Ridley DS, Nicklin S, Hale C, Liew FY: The evolution of the lesion in cutaneous leishmaniasis. *J Pathol* 1983, 141:83-96
9. Andrade ZA, Reed SG, Roters S, Sadigursky M: Patogenia da leishmaniose cutânea experimental: A importância da necrose na eliminação dos parasitos das lesões. *Rev Soc Bras Med Trop* 1984, 17:187-197
10. Convit J, Pinardi E, Rondon AJ: Diffuse cutaneous leishmaniasis: A disease due to an immunological defect of the host. *Trans R Soc Trop Med Hyg* 1972, 66:603-610
11. Bittencourt AL, Andrade ZA: Aspectos imunológicos na leishmaniose cutâneo-mucosa. *Hospital (Rio de Janeiro)* 1967, 71:89-98
12. Perez H, Labrador F, Torrealba JW: Variations in the response of five strains of mice to *Leishmania mexicana*. *Int J Parasitol* 1979, 9:27-32
13. Howard JG, Liew FY, Hale C, Nicklin S: Prophylactic immunization against experimental leishmaniasis: II. Further characterization of the protective immunity against fatal *Leishmania tropica* infection induced by irradiated promastigotes. *J Immunol* 1984, 132:450-455
14. Grimaldi G Jr, Soares MJ, Moriearty PL: Tissue eosinophilia and *Leishmania mexicana mexicana* eosinophil interactions in murine cutaneous leishmaniasis. *Parasite Immunol* 1984, 6:397-408
15. Howard JG, Hale C, Liew FY: Immunological regulation of experimental cutaneous leishmaniasis: III. The nature and significance of specific suppression of cell-mediated immunity. *J Exp Med* 1980, 152:594-607
16. Howard JG, Hale C, Liew FY: Immunological regulation of experimental cutaneous leishmaniasis: IV. Prophylactic effect of sub-lethal irradiation as a result of abrogation of suppressor T cell generation in mice genetically susceptible to *Leishmania tropica*. *J Exp Med* 1981, 153:557-568
17. Liew FY: Specific suppression of responses to *Leishmania tropica* by a cloned T-cell line. *Nature* 1983, 305:630-632

18. Titus RG, Lima GC, Engers HD, Louis JA: Exacerbation of murine cutaneous leishmaniasis by adoptive transfer of parasite-specific helper T cell populations capable of mediating *Leishmania major*-specific delayed-type hypersensitivity. *J Immunol* 1984, 133:1594-1600
19. Titus RG, Ceredig R, Cerottini JC, Louis JA: Therapeutic effect of anti-L3T4 monoclonal antibody GK 1.5 on cutaneous leishmaniasis in genetically-susceptible BALB/c mice. *J Immunol* 1985, 135:2108-2114
20. Alexander J, Kaye PM: Immunoregulatory pathways

in murine leishmaniasis: Different regulatory control during *Leishmania mexicana mexicana* and *Leishmania major* infection. *Clin Exp Immunol* 1985, 61:674-682

Acknowledgments

We are indebted to Ms. Silva Cardoso for excellent technical assistance and to Mrs. Rosimari Keysselt for typing the manuscript.