

Cyclophosphamide Immunosuppression During Lymphotropic Herpesvirus Infection in the Guinea Pig Model

A Histopathologic and Virologic Study

S. McCORMICK, MD, K. DOWLER, PhD,
J. A. ARMSTRONG, BS, and G. D. HSIUNG, PhD

From the Department of Laboratory Medicine, Yale University School of Medicine, New Haven, Connecticut, and Virology Laboratory, Veterans Administration Medical Center, West Haven, Connecticut

Guinea pigs infected with lymphotropic herpesvirus (GPHLV) were given the immunosuppressive agent cyclophosphamide (Cy). All Cy-treated animals revealed the expected lymphoid depletion of spleen and lymph node B zones. Acute GPHLV infection of Cy-treated animals resulted in increased blood and spleen leukocyte viral infectivity titers and lymphoid tissue lesions containing cells positive for GPHLV antigen and intranuclear inclusions. During latent GPHLV infection, Cy treatment resulted in declining leukocyte

viral infectivity titers without pathologic lesions. Morphologic data suggest that tissue histiocytic cells may be involved in the productive viral infection observed in Cy-immunosuppressed animals during acute GPHLV infection. During latency, however, infectious virus appears restricted to a Cy-sensitive, probably lymphoid, cell. This animal model appears useful for the study of lymphotropic viral infection during immunosuppression. (Am J Pathol 1987, 127:538-548)

SUPPRESSION of the immune system, either iatrogenically or naturally, often results in the development of life-threatening herpesvirus infections of the host. These may result from reactivation of latent viral infections or increased susceptibility to primary infections. A spectrum of conditions ranging from inapparent infection to aggressive lymphoproliferative lesions and B-cell lymphomas have been associated with Epstein-Barr virus (EBV) infection of immunodeficient patients.¹ Results of DNA hybridization, tumor staining for EBV nuclear antigen, and serologic data have linked EBV etiologically with the development of lymphoma and lymphoproliferative syndromes in organ transplant patients given immunosuppressive treatment.² The pathogenetic mechanisms of EBV infection during immunosuppression remain obscure, however.

Guinea pig herpes-like virus (GPHLV) is a lymphotropic herpesvirus originally isolated from leukemia-susceptible strain 2 guinea pigs.³ Previous studies of GPHLV demonstrated tropism for blood leukocytes, lymphoid tissues, and bone marrow (reviewed by Hsiung⁴). Adherent cells (macrophages/monocytes) were also shown to be susceptible to GPHLV infection, although the importance of phagocytic uptake of virus or viral-infected cells versus intrinsic

Supported by the Medical Research Service at the West Haven Veterans Administration Medical Center.

Accepted for publication January 29, 1987.

Address reprint requests to G. D. Hsiung, PhD, Virology laboratory/151B, Veterans Administration Medical Center, West Haven, CT 06516.

genomic or episomal transmission of virus was unclear.^{5,6} Whether the inoculation route was intraperitoneal, intrathymic, intracerebral, or intranasal, virus was recovered first and in highest titer from the spleen.⁶⁻⁹ GPHLV has been compared with human EBV⁴ because each virus can induce life-long latent infection in host leukocytes. Although *in vitro* transformation potential has been described for GPHLV,^{10,11} established *in vitro* lymphoblastoid cell lines have not been reported.

A mild transient mononucleosis syndrome associated with splenic lymphoid hyperplasia was reported during acute GPHLV infection.¹² No other pathologic changes during acute or latent infection have been observed, and viral inclusions have never been seen *in vivo*. The mechanisms of progression from acute infection to the latent state are unknown. Preliminary data, however, suggest that viral persistence during latency involves B lymphocytes predominantly.

Herein we report productive viral infection and pathologic lesions in guinea pig lymphoid tissue during acute GPHLV infection in animals undergoing cyclophosphamide immunosuppression. Virologic and pathologic data during acute and latent GPHLV infection are summarized. This animal model may prove useful for understanding the pathogenesis of lymphotropic herpesvirus infection in immunodeficient patients.

Materials and Methods

Virus Stock and Cell Culture

GPHLV strain LK₄₀ (ATCC VR543) was originally isolated from the blood of a leukemic guinea pig.³ Virus stocks were prepared by passage in monolayer cultures of primary guinea pig embryo (GPE) cells. Virus infectivity titers were assayed by plaque formation and/or cytopathic effect (CPE) production in GPE cells. Preparation and maintenance of GPE cells and stock virus were described previously.^{12,13}

Animal Inoculation

Two-month-old female Hartley guinea pigs weighing 300–500 g (Camm Research, Wayne, NJ) were inoculated intraperitoneally with 1 ml GPHLV-infected cell suspension containing 10⁶ PFU GPHLV. Control animals received 1 ml of a clarified lysate of uninfected GPE cells in culture medium.

Cyclophosphamide Treatment

Cyclophosphamide (Cy) was dissolved in phosphate-buffered saline (PBS) at a concentration of 30 mg/ml and sterilized by passage through a 0.22- μ filter. All Cy treatments were administered intraperitoneally. Animals received either 30 mg/kg body wt/day (daily injection) or 300 mg/kg body wt/week (weekly injection). Control animals received equal volumes of PBS.

For acute infection studies, guinea pigs were pre-treated with Cy for 7 days, then inoculated with 10⁶ PFU GPHLV and continued on Cy for an additional 14 days. For latent infection studies, guinea pigs were inoculated with 10⁶ PFU GPHLV, infected for 60–120 days, and then treated with Cy daily for 14 days.

Hematologic Evaluation

Blood samples were taken from each animal weekly. Two to three milliliters of blood were obtained from each ether-anesthetized animal via cardiac puncture with a 25-gauge needle and collected in a 10-ml heparinized vacutainer.

Total leukocyte counts were enumerated manually by means of Unopettes with 3% acetic acid as diluent (Unopette Microcollector System, Becton-Dickinson, Rutherford, NJ). Differential leukocyte counts were determined on Wright's-stained blood smears. The absolute number of lymphocytes and polymorphonuclear cells were calculated by multiplying the total leukocyte count by percentage values obtained for each cell population from the differential.

Separation of Mononuclear Leukocytes From Peripheral Blood and Spleen Cell Suspension for Virus Isolation

Animals were sacrificed by ether or carbon dioxide asphyxiation at designated times after virus inoculation. Spleen tissues were obtained aseptically at sacrifice, and cell suspensions were prepared as previously described.¹³ Mononuclear leukocytes were separated from spleen cell suspension and peripheral blood by centrifugation in Ficoll-Hypaque. The spleen cell suspension or peripheral blood was diluted with Hanks' balanced salt solution (HBSS) 1:3, layered onto Ficoll-Hypaque 3:1 (vol/vol), and centrifuged for 40 minutes at 800g at 4 C in an IEC CRU-5000 refrigerated centrifuge. The resulting band of mononuclear leukocytes was collected with a Pasteur pipette, washed twice with HBSS, and resuspended in RPMI

1640 containing 10% newborn calf serum (NCS). The mononuclear leukocytes were then adjusted to 10^6 cells/ml with RPMI 1640 10% NCS and serial 10-fold dilutions of the adjusted cell suspension were co-cultivated on GPE monolayers for determination of viral infectivity titers. Viral infectivity data were tested for statistical significance by means of a two-tailed test of significance on the means of unpaired data between control and experimental groups.

Histopathologic Studies

Spleens at sacrifice were weighed, and the spleen/body weight ratios were calculated. Portions of tissue obtained from spleen, cervical lymph nodes, thymus, and bone marrow were fixed overnight in Bouin's fixative. Fixed tissues were embedded in paraffin, sectioned, and stained with hematoxylin and eosin (H&E).

Morphologic comparison of spleens and cervical lymph node sections from control and experimental animals was facilitated by a semiquantitative grading formula employing standard morphologic markers of lymphoid hyperplasia. The grading scheme was based on the assumption that histologic changes in lymphoid tissue have functional and immunologic relevance¹⁴ and was patterned after a proposal by Cottier et al,¹⁵ who published a standardized system for reporting human lymph node morphology in relation to immunologic function. Using this grading scheme, we previously demonstrated a specific sequence of lymphoid histologic changes in guinea pig spleens following acute infection with GPHLV.¹² Briefly, T-cell and B-cell zones of the cervical lymph nodes and splenic white pulp were evaluated separately by means of these criteria: B-zones (superficial cortex and germinal centers of lymph nodes; peripheral periarteriolar lymphoid sheath of splenic white pulp)

Frequency of blast cells
 Frequency of mitotic figures (nongerminal center)
 Overall cellularity
 Frequency of germinal centers
 Average size of germinal centers

T-zones (paracortical area of lymph nodes; central periarteriolar lymphoid sheath of splenic white pulp)

Frequency of blast cells
 Frequency of mitotic figures
 Overall T-zone cellularity

Each parameter was subjectively graded from 0 to 4+, and a total B-zone and T-zone sum was derived for each lymph node and spleen section. All sections were randomly graded by the same observer without knowledge of the experimental status of each animal. The total T- and B-zone scores obtained from control animal sections were used for establishing control ranges. Sections from the experimental animals with T- or B-zone scores above the control range were scored as positive for lymphoid hyperplasia in the respective lymphoid zone. Sections showing scores below the control range were scored as positive for lymphoid depletion.

Thymus and bone marrow sections were scored as either positive or negative for lymphoid or hematopoietic depletion or hyperplasia as compared with control slides qualitatively.

Immunohistology

Viral antigen was localized in tissue sections by means of rabbit anti-GPHLV hyperimmune sera and an avidin-biotin complex (ABC) detection system (Vector Laboratories, Burlingame, Calif).

Results

Physical Evaluation

Guinea pigs inoculated with GPHLV gained weight normally and exhibited no signs of overt disease. Animals treated with Cy for 7 days experienced weight loss but generally appeared healthy. Animals treated with Cy for a period of 14 days or longer experienced weight loss, malaise, loss of fur, and a marked drop in the spleen/body weight ratio (data not shown).

Effect of Cy on Total and Differential Leukocyte Counts of Peripheral Blood

Acute Infection

Infected animals without Cy treatment developed a relative and absolute lymphocytosis between 7 and 14 days after GPHLV inoculation, as previously reported.¹² Cy treatment resulted in severe leukopenia as a result of a marked decline in both peripheral blood lymphocytes and polymorphonuclear leuko-

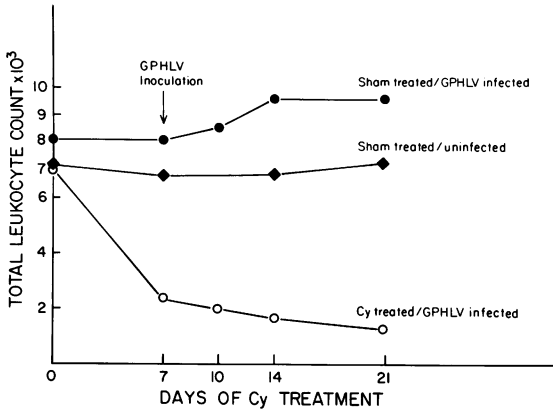


Figure 1—Peripheral blood leukocyte counts per cubic millimeter of whole blood during acute GPHLV infection. Animals received either 30 mg/kg/day cyclophosphamide (0-0) or an equal volume of diluent (●-●) and were inoculated with 10⁶ TCID₅₀ GPHLV on treatment Day 7. Sham-treated uninfected controls received diluent and uninfected cell culture lysate (◆-◆). Each point represents averaged mean counts from four experiments (63 total animals).

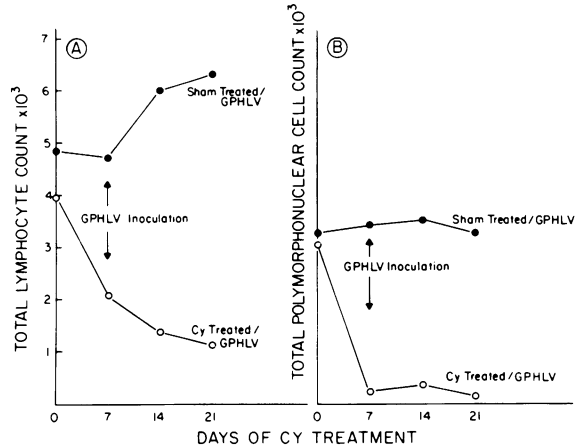


Figure 2—Total lymphocyte (A) and polymorphonuclear leukocyte (B) counts per cubic millimeter of whole blood during acute GPHLV infection. Animals received either 30 mg/kg/day cyclophosphamide (○-○) or were sham-treated with diluent (●-●). Each point represents the averaged mean counts of four experiments (63 total animals).

cytes. Leukocyte counts in sham-treated/uninfected control animals remained constant (Figures 1 and 2).

Latent Infection

Total and differential leukocyte counts showed no significant change in the latently infected animals

without Cy treatment (sham). Animals undergoing Cy suppression developed marked leukopenia as a result of declining lymphocyte and polymorphonuclear leukocyte counts. Total and differential blood counts increased to near normal values after cessation of Cy (Figures 3 and 4).

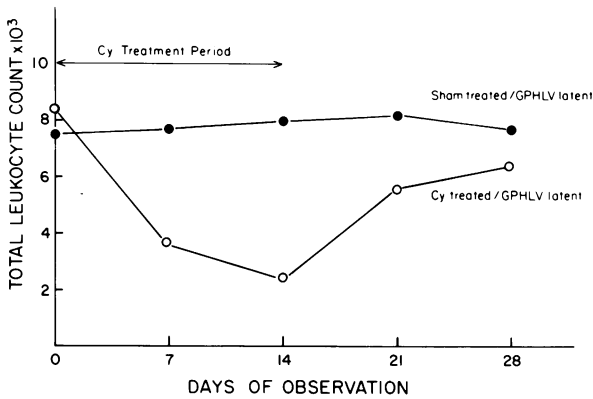


Figure 3—Total leukocyte counts per cubic millimeter of whole blood in guinea pigs during latent GPHLV infection. After 60–120 days of latent GPHLV infection, animals received either 30 mg/kg/day cyclophosphamide (○-○) or an equal volume of diluent (●-●) for 14 days. Each point represents the averaged mean counts of four experiments (66 total animals).

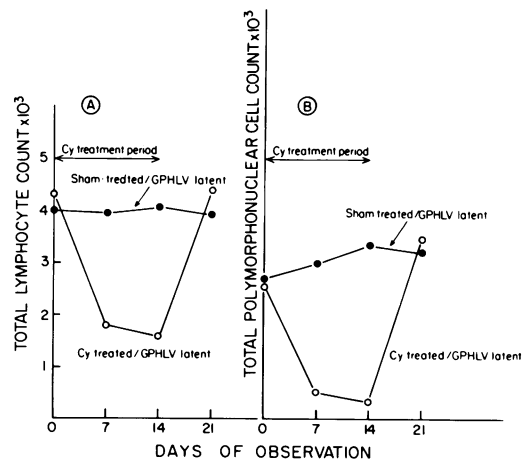


Figure 4—Total lymphocyte (A) and polymorphonuclear leukocyte (B) counts per cubic millimeter of whole blood from guinea pigs during latent GPHLV infection. After 60–120 days of latent GPHLV infection, animals received either 30 mg/kg/day of cyclophosphamide (○-○) or an equal volume of diluent (●-●) for 14 days. Each point represents the averaged mean counts of four experiments (66 total animals).

Effect of Cy on Viral Infectivity Titers of Peripheral Blood and Spleen Leukocytes During Acute and Latent GPHLV Infection

Viral infectivity titers 14 days after inoculation (acute infection) were significantly ($P < 0.01$) increased in spleen mononuclear leukocyte preparations from Cy-treated animals, compared with sham-treated controls (Table 1). Peripheral blood mononuclear leukocyte viral infectivity titers were slightly, but not significantly, increased in Cy-treated animals, compared with sham-treated controls, during acute infection.

During latent infection, viral infectivity titers were significantly ($P < 0.001$) decreased in blood and spleen mononuclear leukocytes from Cy-treated animals, compared with sham-treated controls. Infectious virus was essentially undetectable in blood and spleen mononuclear leukocytes from latently infected animals undergoing high-dosage (300 mg/kg/wk) cyclophosphamide suppression.

Histopathology

Spleens and Cervical Lymph Nodes

Acute Infection

Animals acutely infected with GPHLV developed splenic lymphoid hyperplasia. As previously described,¹² a prominent T-zone hyperplasia occurred 3–7 days after inoculation, followed by follicular hyperplasia between Day 7 and Day 14 (Figures 5A–D).

Cervical lymph nodes from GPHLV-infected animals did not show significant hyperplasia, compared with control animals.

Striking B-zone lymphoid depletion was evident in the lymph node and splenic white pulp of Cy-treated animals (Figure 6A). Significant T-zone depletion was noted only after prolonged (21 days, 30 mg/kg/day) or high-dosage (300 mg/kg/wk) treatment (Figure 6B). In this study, GPHLV-infected and uninfected control animals developed morphologically equivalent lymphoid depletion during Cy immunosuppression, as judged subjectively and by the semi-quantitative grading scheme.

Lymph node and spleen sections from 12 of 27 animals given Cy during acute GPHLV infection revealed focal lesions suggestive of viral origin (Figure 7A and B). Foci of cellular depletion were observed in the superficial cortical areas adjacent to subcapsular sinuses of affected lymph nodes and in the areas adjacent to the marginal zones and peripheral periarteriolar lymphoid sheaths of affected spleens. Cells bearing large eosinophilic intranuclear inclusions were evident in the lesions. The inclusion-positive cells demonstrated abundant cytoplasm with frequent cytophagocytic debris and were often observed within lymph node sinuses, findings suggesting a possible tissue histiocyte origin (Figures 7 and 8). Lymphoid cells with intranuclear inclusions were only rarely observed (Figure 8B). The lesions were associated with scattered degenerating cells and cytophagocytic macrophages, but little active inflammation.

Table 1—Viral Infectivity Titers of Peripheral Blood and Spleen Mononuclear Leukocyte Preparations During Acute and Latent GPHLV Infection of Guinea Pigs

GPHLV infection*	Cell population tested	Virus infectivity titers log TCID ₅₀ /10 ⁶ packed cells		
		Sham-treated	Cy-treated	
			30 mg/kg/day	300 mg/kg/wk
Acute	Blood mononuclear leukocytes	2.1 (18)†	2.3 (18)	‡
	Spleen mononuclear leukocytes	2.3 (15)	3.3 (10)	‡
Latent	Blood mononuclear leukocytes	1.8 (19)	1.0 (10)	0§ (7)
	Spleen mononuclear leukocytes	2.3 (27)	1.0 (15)	0 (6)

*Acutely infected animals were sacrificed 14 days after intraperitoneal inoculation of virus suspension. Latently infected animals were infected for 60–120 days and sacrificed after 14 days of Cy treatment. Cy-treated animals received either 30 mg/kg/day or 300 mg/kg/wk of cyclophosphamide. Sham-treated animals received diluent injections.

†Number of animals in each experiment.

‡Animals died during acute infection.

§Virus was not detectable.

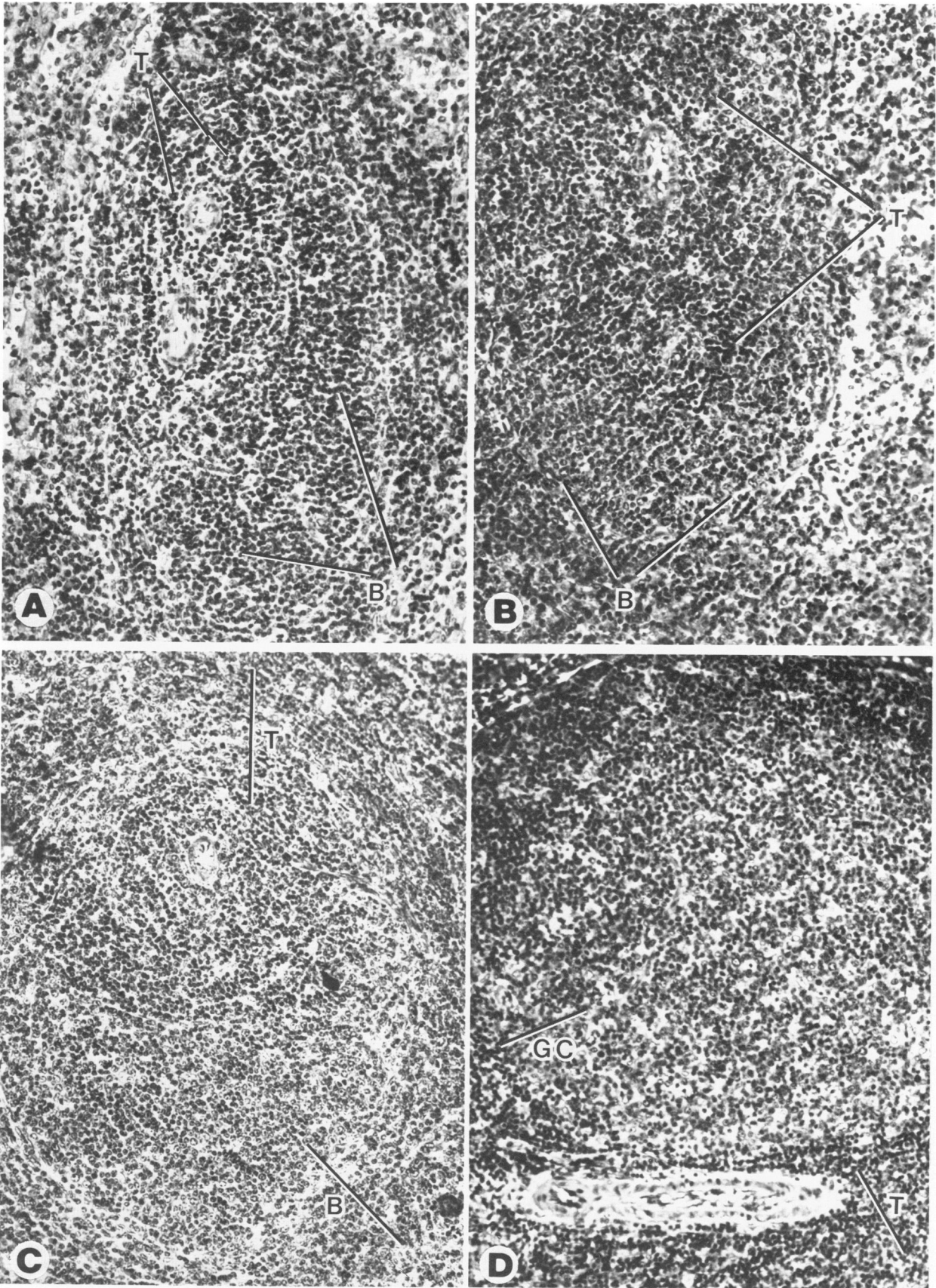


Figure 5—Spleen lymphoid tissue during acute GPLV infection. **A**—Periarteriolar lymphoid tissue from an uninfected control animal showing inconspicuous central periarteriolar lymphoid mantle (T-zone, *T*) and cap of peripheral periarteriolar lymphoid mantle (B-zone, *B*). **B**—Expanded (hyperplastic) T zone 3 days after GPLV inoculation. **C**—Mixed T- and B-zone hyperplasia 7 days following inoculation. **D**—Florid follicular hyperplasia represented by large germinal center (*GC*) and compressed T zone. (H&E, $\times 100$)

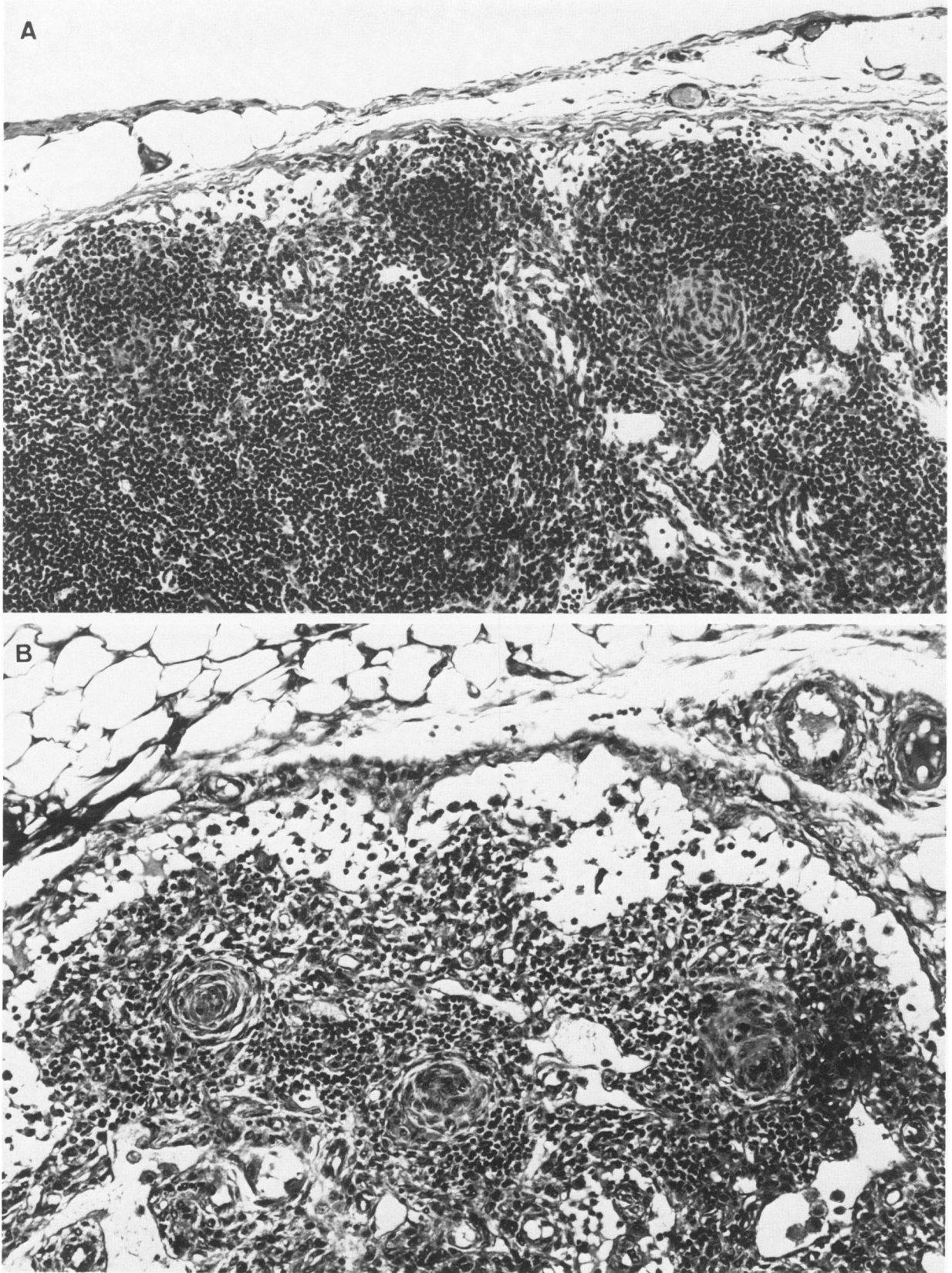


Figure 6—Cervical lymph node during Cy immunosuppression. **A**—Animal given Cy, 30 mg/kg/day for 14 days shows B-zone depletion, as indicated by atrophic germinal centers. Parafollicular T-zone area retains cellularity. **B**—High-dosage (300 mg/kg/wk) Cy results in severe combined B- and T-zone depletion. (H&E $\times 100$)

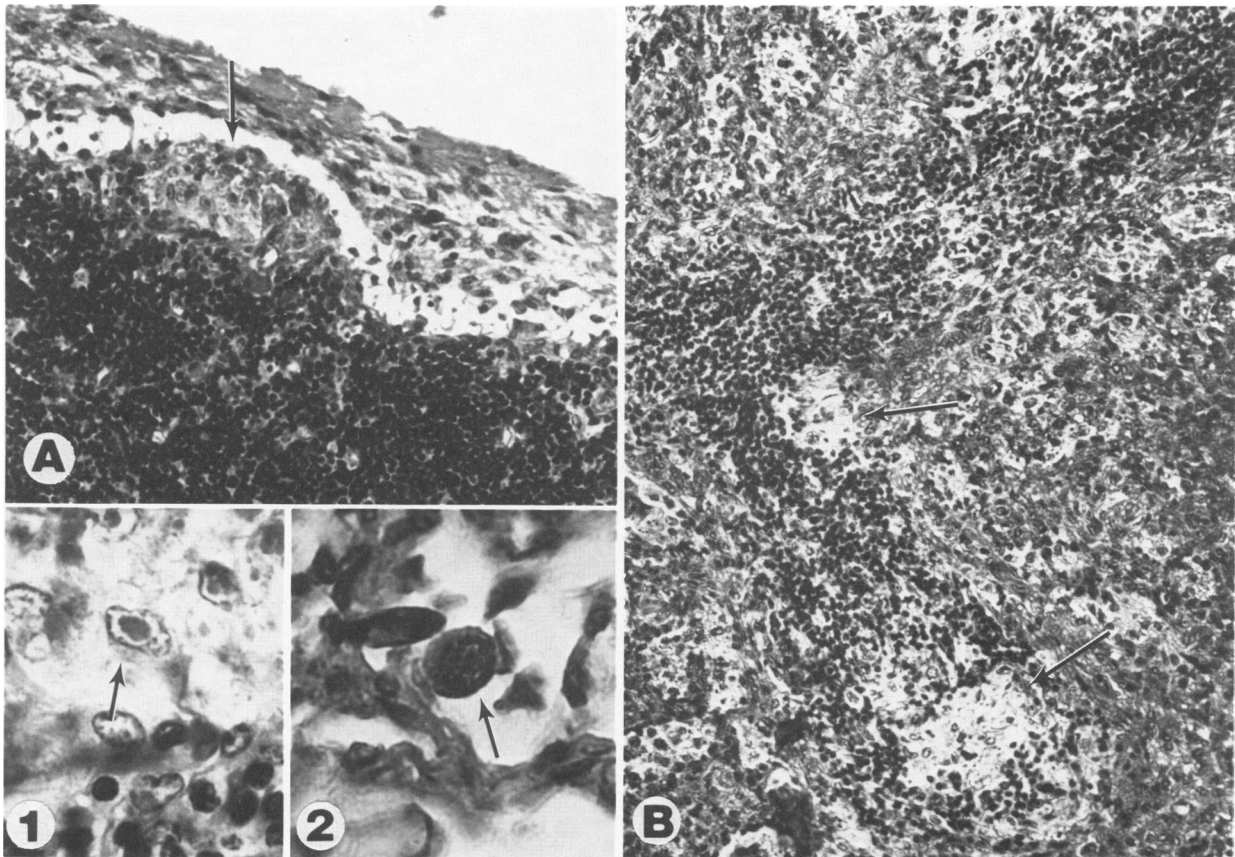


Figure 7—Viral lesions during acute GPHLV infection in animals receiving daily Cy, 30 mg/kg/day. Focal lesions (I) evident in superficial cortex of lymph node (A) and peripheral periarteriolar lymphoid sheath of spleen (B). Magnification at $\times 400$ shows degenerating cells with large intranuclear inclusions (inset 1, A). Sinus macrophage with intranuclear inclusion is strongly positive for GPHLV antigen by the ABC method with rabbit anti-GPHLV sera (inset 2, A). (A and B, H&E, $\times 100$)

The inclusions and inclusion-positive cells were positive for GPHLV antigen, as demonstrated by the ABC technique using anti-GPHLV hyperimmune rabbit sera (Figure 7A, inset 2). Inclusion-positive cells and viral-type lesions were observed only in Cy-treated/GPHLV-infected animals 14 days after viral inoculation. Preliminary data, however, suggests that antigen-positive (inclusion-negative) cells may be detectable with the ABC technique as early as 7–10 days after acute infection.

Latent Infection

No significant morphologic changes were observed in the spleens and cervical lymph nodes of latently infected animals, compared with uninfected controls. Cy treatment (30 mg/kg/day) of latently infected animals for 14 days resulted in lymphoid depletion of a magnitude similar to that observed during acute infection. High-dosage Cy treatment (300 mg/kg/wk) resulted in total (B- and T-zone) lymphoid depletion. In contrast to the acutely infected group, however,

viral lesions and intranuclear inclusions were not seen in any immunosuppressed, latently infected animals.

Thymus and Bone Marrow

Thymus and bone marrow sections revealed severe lymphoid and hematopoietic depletion in all Cy-treated animals. No morphologic differences between acutely infected, latently infected, and uninfected animals undergoing Cy treatment were observed. No viral lesions or viral inclusions were detected in any thymus or bone marrow sections.

Relationship of Spleen Viral Infectivity Titers and Lymphoid Morphology

Figure 9 summarizes the splenic lymphoid morphologic results of the semiquantitative grading scheme and compares the morphologic data with splenic leukocyte viral infectivity titer data detailed in Table 1. Viral infectivity titers of spleen mononuclear leukocyte preparations during acute and latent infection were similar among sham-treated animals (Figure 9A and C; also see Table 1). As expected, a high

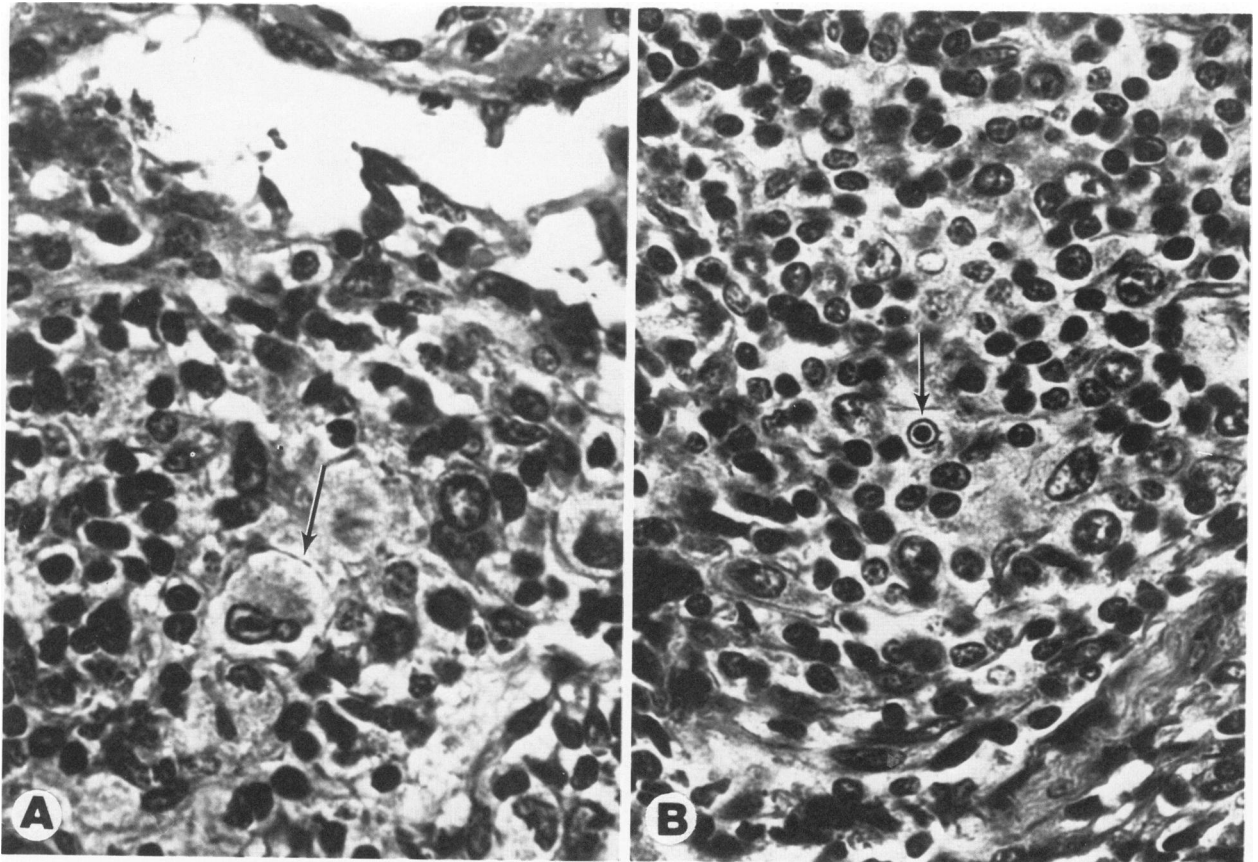


Figure 8—Morphology of inclusion-positive cells in lymph node (A) and spleen (B). Cell in (A) has abundant granular cytoplasm, distinct borders, and elongated nucleus suggestive of a tissue macrophage. Cell in (B) has small round nucleus with inapparent cytoplasm, suggestive of a small lymphocyte. Both cells contain large intranuclear inclusions. (H&E, $\times 400$)

percentage of infected but untreated (sham) animals showed T- and B-zone hyperplasia during acute infection (Figure 9A), whereas only a few showed hyperplasia during latent infection (Figure 9C). After 14 days of Cy suppression, marked T- and B-zone lymphoid depletion was evident in both the acutely and latently infected groups (Figure 9B and D). Virus infectivity titers, however, were higher in the acutely infected Cy/suppressed group (Figure 9B) and lower in the latently infected/Cy suppressed group (Figure 9D), compared with sham-treated controls. High-dosage (300 mg/kg/wk) Cy treatment during latent infection resulted in total T- and B-zone depletion and essentially no detectable infectious virus (Figure 9E). No acutely infected animals survived the high-dosage Cy regimen.

Discussion

Previous studies documented the *in vitro* growth and cytopathic characteristics of GPHLV.^{5-9,13} To date, GPHLV-specific lesions have not been observed

in vivo without modification of the host immune system. Progression from acute infection to latency was marked only by a mononucleosis syndrome and transient splenic lymphoid hyperplasia.¹² In the present study, focal lesions were found in the cervical lymph nodes and splenic white pulp of guinea pigs undergoing Cy immunosuppression during acute infection with GPHLV. The finding of large, eosinophilic intranuclear inclusions and positive immunohistochemical staining for viral antigen in these lesions suggest that the observed histopathologic changes reflect infection by GPHLV. The association of viral lesions in lymphoid tissue and increased viral infectivity titers in blood and spleen leukocyte preparations indicate that a productive viral infection occurs during acute GPHLV infection of Cy-immunosuppressed guinea pigs.

The morphologic findings in the present study suggest lymph node and spleen macrophages may be a site of lytic viral infection during immunosuppression. A previous study found bone marrow macrophages to be a potential site of infection during acute

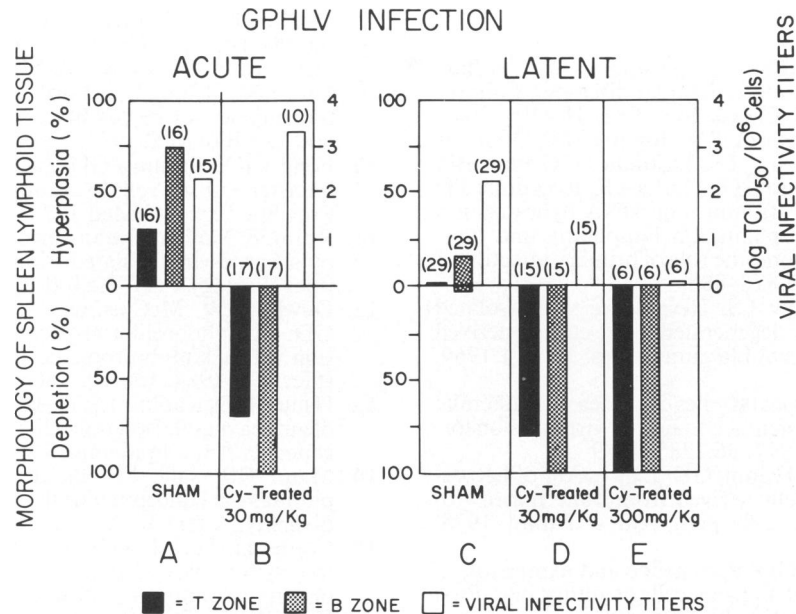


Figure 9—Relationship between spleen lymphoid tissue morphologic findings and spleen mononuclear leukocyte viral infectivity titers during acute and latent GPHLV infection. Acutely infected animals received diluent (*sham*) (A) or cyclophosphamide (B), 30 mg/kg/day, for 7 days, followed by inoculation with 10^8 TCID₅₀ of GPHLV and continued cyclophosphamide treatment for 14 more days. Latently infected animals received diluent (*sham*), 30 mg/kg/day (D), or 300 mg/kg/wk (E) cyclophosphamide for 14 days after establishment of latent GPHLV infection. Histologic sections were evaluated semiquantitatively for morphologic evidence of lymphoid hyperplasia or depletion. The number in parentheses is the number of animals examined in each group.

and latent GPHLV infection of normal, nonimmunosuppressed animals.⁵ In that study, virus was detected *in vitro* only, and phagocytic uptake of virus or virus-infected cells during co-cultivation could not be excluded. In the present study, viral inclusions were directly observed in macrophagelike cells in tissue sections, indicating *in vivo* involvement of this cell. The relative importance of phagocytic uptake versus intrinsic (genomic or episomal) viral transmission during acute and latent GPHLV infection, however, remains unclear.

In our earlier studies of acute GPHLV infection we reported recovery of virus from at least three cell types, including T- and B-lymphocytes and adherent (monocyte/macrophage) cells.^{5,6,12} On the other hand, virus was recovered predominantly from B lymphocytes during latency.^{6,12} In the present study, Cy immunosuppression during acute GPHLV infection resulted in severe morphologic lymphoid depletion; yet splenic viral infectivity titers were increased, indicating that GPHLV may induce acute infection in cells relatively less sensitive to Cy, in addition to Cy-sensitive cells such as T and B lymphocytes. On the basis of morphologic findings, we suspect a mononuclear phagocyte cell may be the nonlymphoid, relatively Cy-resistant cell infected during acute GPHLV infection of immunosuppressed animals. During la-

tent infection, however, viral infectivity titers declined during Cy suppression, the spleen and blood leukocyte titers falling to nearly zero in animals undergoing a high-dose (300 mg/kg/wk) Cy regimen. In latency, therefore, infectious virus appeared confined to a Cy-sensitive cell(s), an observation in agreement with previous studies suggesting a role for B lymphocytes in perpetuating GPHLV latent infection. It appears that progression from acute GPHLV infection to latency may involve restriction of the range of cell types harboring infectious virus.

A predominantly B-zone, dose-related depletion of spleen and lymph node tissues was evident in all Cy-treated animals. This has been described previously and reflects the predominantly anti-mitotic action of cyclophosphamide.¹⁶

Acute GPHLV infection during cyclophosphamide immunosuppression results in a productive viral infection with high virus infectivity titers in spleen and blood leukocytes and pathologic lesions in cervical lymph nodes and spleen. During latent GPHLV infection, however, viral infectivity titers decline with immunosuppression, apparently reflecting restriction of the virus to a cyclophosphamide-sensitive cell (lymphocyte). This animal model appears extremely useful for the study of lymphotropic herpesvirus infection during immunomodulation.

References

1. Klein G, Purtilo D (eds): Symposium on Epstein-Barr virus-induced lymphoproliferative diseases in immunodeficient patients. *Cancer Res* 1981, 41:4209-304
2. Ho M, Miller G, Atchison RW, Breinig MK, Dummer JS, Andiman W, Starzl TE, Eastman R, Griffith BP, Hardesty RL, Bahnson HT, Harka TR, Rosenthal JT: Epstein-Barr virus infections and DNA hybridization studies in post-transplantation lymphoma and lymphoproliferative lesions: the role of primary infection. *J Infect Dis* 1985, 152:876-886
3. Hsiung GD, Kaplow LS: Herpes-like virus isolated from spontaneously degenerated tissue culture derived from leukemia-susceptible guinea pigs. *J Virol* 1969, 3:355-357
4. Hsiung GD: Virological studies of guinea pig leukemia: An overview with reference to herpes virus and oncovirus. *Fed Proc* 1977, 36:2285-2289
5. Gonzalez-Serva A, Hsiung GD: Expression of herpesvirus in adherent cells derived from bone marrow of latently infected guinea pigs. *Am J Pathol* 1978, 91:483-492
6. Griffith B, Hsiung GD: Persistence and expression of herpesvirus in B and T spleen cells of guinea pigs. *Proc Soc Exp Biol Med* 1979, 162:202-206
7. Booss J, Hsiung GD: Herpes-like virus of the guinea pig: propagation in brain tissue of guinea pigs and mice. *J Infect Dis* 1971, 123:284-291
8. Tenser RB, Hsiung GD: Infection of thymus cells in vivo and in vitro with a guinea pig herpes-like virus and the effect of antibody on virus replication in organ culture. *J Immunol* 1973, 110:552-560
9. Lam KM, Hsiung GD: Further studies on the mode of transmission of herpes-like virus in guinea pigs. *Proc Soc Exp Biol Med* 1971, 138:422-426
10. Fong CKY, Hsiung GD: In vitro transformation of hamster embryo cells by a guinea pig herpes-like virus. *Proc Soc Exp Biol Med* 1973, 144:974-978
11. Rhim JS: Malignant transformation of rat embryo cells by a herpesvirus isolated from L₂C guinea pig leukemia. *Virology* 1977, 82:100-110
12. Dowler KW, McCormick S, Armstrong JA, Hsiung GD: Lymphoproliferative changes induced by infection with a lymphotropic herpes virus of guinea pig. *J Infect Dis* 1984, 150:105-111
13. Hsiung GD, Kaplow LS, Booss J: Herpesvirus infection of guinea pigs: I. Isolation, characterization, and pathogenicity. *Am J Epidemiol* 1971, 93:298-307
14. Mann RB, Jaffe ES, Berard CW: Malignant lymphomas—a conceptual understanding of morphologic diversity: A review. *Am J Pathol* 1979, 94:105-191
15. Cottier H, Turk J, Sobin L: A proposal for a standardized system of reporting human lymph node morphology in relation to immunological function. *J Clin Pathol* 1973, 26:317-331
16. Turk JL, Poulter LW: Selective depletion of lymphoid tissue by cyclophosphamide. *Clin Exp Immunol* 1972, 10:285-296