

### Nyhan-Lesch Syndrome and Juvenile Gout (Two Cases)

Rodney Bluestone<sup>1</sup> MB MRCP  
(for Professor E G L Bywaters FRCP  
and L P J Holt MRCP)

(Department of Medicine,  
Royal Postgraduate Medical School, London)

#### Case 1 T T, boy aged 5

*History:* Premature vertex delivery. Birth weight 4 lb 6 oz (1.98 kg). Neonatal jaundice. Obviously backward at 1 year and started tongue and lip biting and nose clawing; required splinting to control.

*On examination:* Unable to sit or feed unaided; incontinent; strong tendency to self-mutilation (Fig 1). Central nervous system normal; skull circumference 47 cm. Blood pressure 100/60.

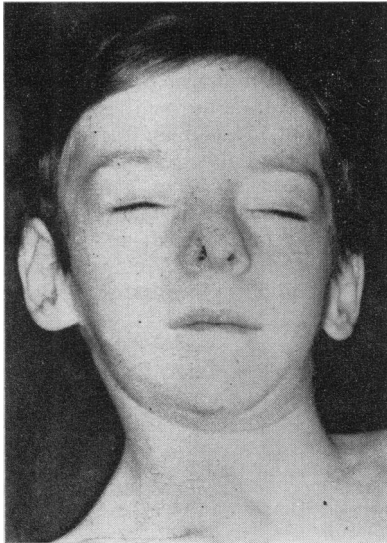

Fig 1 Case 1 Areas of self-mutilation on lower lip and nares

*Investigations:* IQ educationally subnormal. Blood urea 60 mg/100 ml. Urine sterile. Serum uric acid 9 mg/100 ml. Basal urinary uric acid 559, oxypurines 31, total 590 mg/24 h; on allopurinol, urinary uric acid 163, oxypurines 480, total 643 mg/24 h (Dr J T Scott). Enzyme studies (Dr J E Seegmiller) showed gross deficiency of hypoxanthine guanine phosphoribosyltransferase (HGPR). Family studies not possible.

*Comment:* Classical Nyhan-Lesch syndrome of mental deficiency, compulsive self-destruction, hyperuricæmia and renal failure. Subsequent studies confirm HGPR deficiency.

<sup>1</sup>Present address: School of Medicine, Center for the Health Sciences, Los Angeles, California 90024

#### Case 2 A R, man aged 24

Refuse collector

*History:* Normal school - 'a bit backward'. Aged 12: started grand mal epilepsy. Aged 16-18: confined to colony; treated with phenobarbitone and phenytoin with good control of fits. Aged 15: tophaceous gout with severe recurrent arthritis uncontrolled by probenecid and colchicine.

*On examination:* Numerous tophi ears, elbows, hands (Fig 2). Blood pressure 110/70. Central nervous system normal.

*Investigations:* IQ (full scale) 74. Blood urea 40 mg/100 ml. Creatinine clearance 23 ml/min. Urine sterile. Urinary protein 400 mg/24 h. Intravenous pyelogram showed calyceal clubbing. Hb 10.8 g/100 ml. Serum folate 3 ng/ml. Marrow megaloblastic. Serum uric acid 15.5 mg/100 ml. Basal urinary uric acid 711, oxypurines 162,

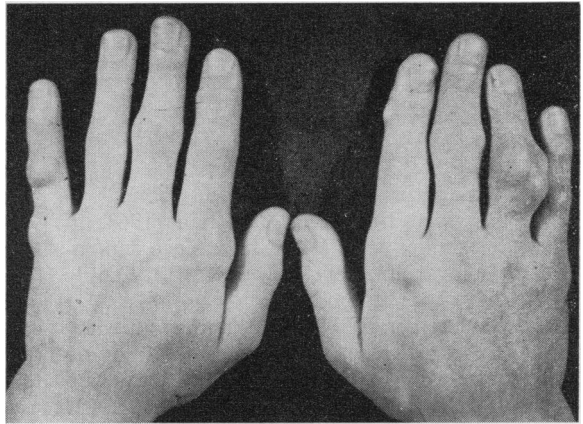


Fig 2 Case 2 Gouty tophi on hands

total 873 mg/24 h; on allopurinol, urinary uric acid 183, oxypurine 749, total 932 mg/24 h (Dr J T Scott). Enzyme studies (Dr J E Seegmiller) showed partial deficiency of HGPR to about 0.5-1.0% of normal levels.

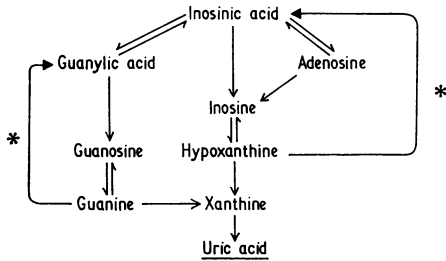
Family studies: no abnormality found in father, mother or 2 sisters.

*Treatment:* Hyperuricæmia and gout controlled by allopurinol 400 mg/day. Megaloblastic anæmia responded to oral folic acid with no increased frequency of fits.

*Comment:* Juvenile tophaceous gout in a patient with near-complete HGPR deficiency and mild cerebral disorder. Coincidental folate-deficiency anæmia.

**Discussion**

It is likely that both patients exhibit features of the same metabolic disorder. Both have a deficiency in their tissues of the enzyme hypoxanthine guanine phosphoribosyltransferase (HGPR) and, as illustrated in Fig 3, showing the final stages of the purine metabolic cycle, such a deficiency will result in overproduction of uric acid. Xanthine oxidase inhibition with allopurinol suppresses this overproduction as effectively as in primary gout, but leaves the total (i.e. uric acid + oxypurine) purine excretion about the same, in contrast to normal gout where up to one-third of normal purine excretion is abolished by allopurinol.

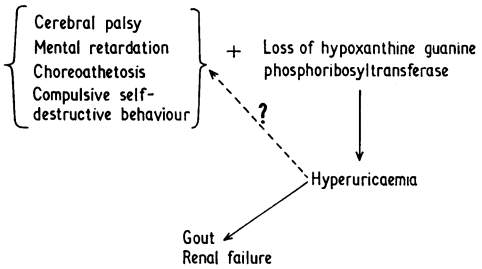


\* Site of action of hypoxanthine guanine phosphoribosyltransferase in uric acid cycle.

**Fig 3** Final stages of purine metabolic cycle. (After Seegmiller et al. 1967)

The first patient is in all respects similar to those described by Lesch & Nyhan (1964) in whom Seegmiller *et al.* (1967) have since demonstrated an invariable deficiency of HGPR. Family studies have not been possible.

Case 2 has survived to adulthood with only mild cerebral disease, tophaceous gout but no known tendency to self-mutilation. There is no hyperuricaemia, mental abnormality or HGPR



**Fig 4** Characterization of Nyhan-Lesch syndrome (sex-linked, familial disease)

deficiency in his immediate family. He has a similar metabolic abnormality to the first patient and Seegmiller (1968, personal communication) has made observations on other adults presenting in this manner.

Clearly much is still to be learned of the metabolic defects and their mode of inheritance. But it does look as if a disease pattern exists presenting in childhood in gross form (Nyhan-Lesch syndrome), and amongst populations of adult subjects with mental abnormalities, epilepsy, hyperuricaemia or gout, in its milder form.

Fig 4 summarizes the known cardinal features of our patients' disease. What relation the enzyme deficiency or hyperuricaemia has to the cerebral disorder is problematical; and whether there are other abnormalities of enzymes concerned in purine metabolism in this disorder is as yet unanswered.

*Acknowledgment:* I am grateful to Dr Jack Rubie and Dr E M Belton for permission to report Case 1.

**REFERENCES**

Lesch M & Nyhan W L (1964) *Amer. J. Med.* 36, 561  
 Seegmiller J E, Rosenbloom F M & Kelley W N (1967) *Science* 155, 1682