

Clinical Section

President R J Harrison FRCP

Meeting on February 9 1968

Cases

Pleural Mesothelioma and Hypoglycaemia

C J F Spry MB MRCP,
D H Williamson BSc DPhil
and M L James MB FFA RCS
(Radcliffe Infirmary, Oxford)

Woman aged 61

History: She had worked as a secretary for five years next door to an asbestos factory fifteen years before she became ill. She had smoked about twenty cigarettes a day for the past thirty years. In 1963 chest X-ray showed a mass in the lower part of the right chest, but she refused surgery. After four years the mass filled half the right chest. In the early part of 1967 she became unwell, and by the summer was unable to do any housework. In the autumn she was admitted to hospital and 2.7 litres of straw-coloured fluid was aspirated from the right chest. Another X-ray showed that a large mass remained. Cells were seen in the fluid suggestive of malignancy. A month later she had periods of disorientation with slurred speech. Again in hospital, she began to have attacks of unconsciousness. There was marked finger clubbing. Later an EEG showed slow wave abnormalities and carotid angiogram demonstrated cortical atrophy. Blood glucose during attacks was 45 mg/100 ml, and she responded immediately to intravenous glucose. There were no malignant cells in the pleural fluid. A diagnostic pneumoperitoneum was normal.

Pre-operative biochemical findings: Hypoglycaemia developed rapidly when food was withheld (Fig 1). The blood lactate concentration was near the upper limit for normal resting subjects, and changed in parallel with the glucose level. The rapid fall in blood glucose was not accompanied by the normal rise in nonesterified fatty acids

(NEFA) or ketone bodies (acetoacetate and β -hydroxybutyrate). Intravenous glucose during hypoglycaemia did not alter the plasma NEFA concentrations significantly.

Findings and biochemistry at operation: Surgery was required urgently as it became difficult to prevent hypoglycaemic manifestations even with continuous 10% glucose infusions. Right thoracotomy was done by Mr A J Gunning. A large hard white tumour (Fig 2) was found attached to the chest wall at four points by small vascular pedicles. It was easily removed whole. Histologically the tumour showed the features found in mesotheliomas producing hypoglycaemia. There was marked cell pleomorphism, and there were many small blood vessels. Histochemical stains showed glycogen was present.

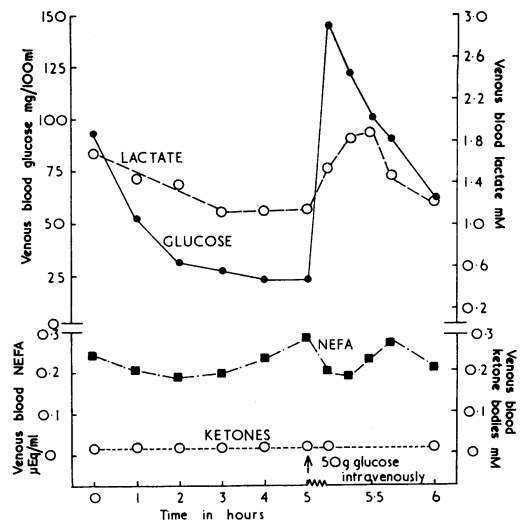


Fig 1 Concentrations of metabolites in blood during a hypoglycaemic episode

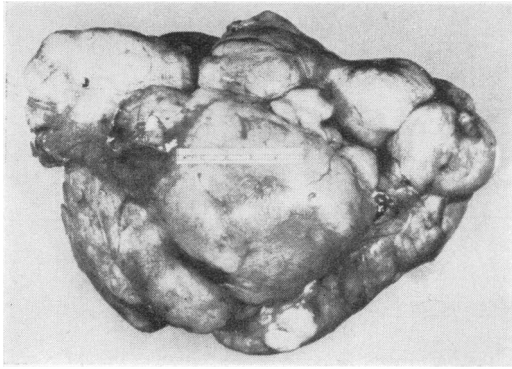


Fig 2 Photograph of pleural mesothelioma (weight 1.3 kg)

After removal of the tumour the NEFA levels rose rapidly during the next hour, even though the blood glucose was high (Fig 3). This suggested that the tumour was the cause of an inhibition of NEFA release from the adipose tissue or, as seems less likely, that it was utilizing large quantities of fatty acids.

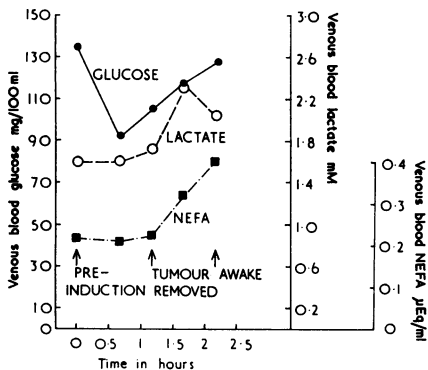


Fig 3 Concentrations of metabolites in blood during operation

Liver biopsy at operation showed a high content of glycogen: 10.8 g/100 g fresh weight liver.

An acid-alcohol extract of the tumour prepared according to Pettinga (1958) contained less than 5 micro-units immunoreactive insulin per g fresh weight.

Post-operative course: The patient recovered rapidly and has had no further attacks of hypoglycaemia. The fasting blood glucose nine days after operation was 108 mg/100 ml. The blood NEFA was 0.35 μEq/ml and ketone bodies 0.43 mM, which were considerably higher than the pre-operative levels. The pre-operative glucose

assimilation coefficient (Marks & Rose 1965) was 2.1, and fell post-operatively to a normal level of 1.4. She continued to have slurred speech. The finger clubbing diminished. Chest X-ray five months later showed no recurrence of tumour.

Discussion

The causes of tumour-induced hypoglycaemia have aroused interest and controversy since the description by Doege (1930) of a patient with a tumour in the chest and symptoms of hypoglycaemia. Suggested mechanisms have included excessive glucose utilization by the tumour, increased glucose removal due to the secretion of insulin or insulinoids by the tumour and inhibition of hepatic gluconeogenesis (Unger 1966).

In the case reported here the hypoglycaemia was associated with failure to mobilize fatty acids, to increase ketone-body production and to release glucose from the liver.

The biochemical findings in this case of hypoglycaemia, low NEFA and normal lactate values, agree with results recently reported for two patients with abdominal mesenchymal tumours (Jakob *et al.* 1967). The serum of one of their patients inhibited adipose tissue lipolysis *in vitro* more effectively than normal serum, and this inhibition was less pronounced with dialysed serum. The increase in NEFA levels shortly after removal of the tumour from our patient supports the view that an anti-lipolytic agent of short half-life may be secreted by these tumours.

Hepatic glucose release may have been depressed in our patient as indicated by the high hepatic glycogen level, a finding previously observed by Jakob *et al.* (1967), Butterfield *et al.* (1960) and Samols (1963).

The failure of NEFA and ketone-body levels to rise in response to hypoglycaemia is likely to increase the demand for glucose, because they act as alternative fuels and thus maintain 'caloric homeostasis' during periods of glucose deficiency (Cahill *et al.* 1966).

In our patient three mechanisms probably contributed to the resulting hypoglycaemia: increased glucose removal from the blood, decreased glucose release from the liver and inhibition of fatty acid mobilization.

It is clear, however, that there are several types of tumour hypoglycaemia showing different metabolic patterns. In two recently reported cases of large and diffuse abdominal mesenchymal tumours (Nissan *et al.* 1968) the hypoglycaemia was accompanied by hyperlactataemia, extremely high serum NEFA and low liver glycogen. These findings agree with the concept of excessive glucose utilization by the tumour resulting in hypoglycaemia and concomitant fatty acid mobi-

lization. The high lactate levels are probably the result of increased production by the tumour and decreased conversion of lactate to glucose in the liver due to tumour infiltration.

There are thus mesotheliomas which produce hypoglycaemia in which liver glucose release and adipose tissue lipolysis are normal, and others in which there is a failure of fatty acid mobilization and hepatic glucose release in response to hypoglycaemia.

REFERENCES

- Butterfield W J H, Kinder C H & Mahler R F (1960) *Lancet* *i*, 703
 Cahill G F jr, Herrera M G, Morgan A P, Soeldner J S, Steinke J, Levy P L, Reichard G A jr & Kipnis D M (1966) *J. clin. Invest.* **45**, 1751
 Doege K W (1930) *Ann. Surg.* **92**, 955
 Jakob A, Meyer U A, Flury R, Ziegler W H, Labhart A & Froesch E R (1967) *Diabetologia* **3**, 506
 Marks V & Rose F C (1965) Hypoglycaemia. Oxford
 Nissan S, Bar-Maor A & Shafir E (1968) *New Engl. J. Med.* **278**, 177
 Pettinga C W (1958) *Biochemical Preparations*. Ed. W M Clark *et al.* New York; **6**, 28
 Samols E (1963) *Postgrad. med. J.* **39**, 634
 Unger RH (1966) *Amer. J. Med.* **40**, 325

The following cases were also shown:

Bagassosis

Dr F E Hargreave (for Professor J G Scadding)

REFERENCE

Hargreave F E, Pepys J & Holford-Strevens V (1968) *Lancet* *i*, 619

Small Jejunal Hæmangioma Diagnosed by Selective Arteriography

Mr E C Ashby (for Mr E S Lee and Professor M D Milne)

Advanced Carcinoma of the Breast (3 cases)

Miss M S Christian (for Mr Maurice Lee)

Albers-Schönberg Disease (Osteopetrosis) with Typical X-ray Changes

Dr R Cradock Henry (for Dr D N Phear)

The following demonstrations were given:

Bronchoscopic Photography

Dr Peter Stradling

Cardiomyopathies

Professor J F Goodwin and Dr Celia Oakley

Meeting on March 8 1968

Cases

Malignant Phæochromocytoma

Simon C Latham MB MRCP
 (for S M Tucker MB MRCPed,
 Professor J P M Tizard FRCP
 and Professor R B Welbourn MD FRCS)
 (Hammersmith Hospital, London)

D S, boy aged 12

History: For six months he had suffered from headaches, but these had been of short duration and unassociated with visual disturbances. Three months after their onset he began to have paroxysmal episodes of sweating, so profuse that beads of moisture would run down his face and his shirt would become drenched. In the morning he would wake nauseated at about 5 a.m. and frequently would vomit.

In appearance he was a thin, ill boy. His blood pressure varied between 140/110 and 180/140 and he had lost 6 kg in weight. During palpation of his abdomen he became pale, sweated profusely and within ten minutes his blood pressure rose to 250/180. No family history of hypertension.

Investigations: Urea 58 mg/100 ml, sodium 135, potassium 3, chlorides 83, bicarbonate 34 mEq/l. Urine: proteinuria and on one occasion glycosuria. Hb 13.5 g/100 ml. PCV 39%. ESR 31 mm in 1 hour (Westergren).

Catecholamine metabolites (Dr M Sandler): 4-hydroxy-3-methoxymandelic acid (VMA) 31.5 (1.8–7.2), total metadrenalines 7.0 (0.25–0.8), 4-hydroxy-3-methoxyphenylglycol (HMPG) 11.1 (1.6–5.2), homovanillic acid (HVA) 3.2 (3–8) mg/24 h.

A retrograde aortogram (Fig 1) revealed a mass lying below the hilum of the left kidney and just medial to its inferior pole. At operation this mass was found to be an irregular lobulated tumour measuring 5–6 cm in diameter, adherent posteriorly to the sympathetic plexus and overlying the aorta and inferior pole of the left kidney. A separate nodule was found at the medial edge of the tumour and both were removed *en masse*. Dissection was difficult for the tumour was firmly adherent to the surrounding tissue. There was no capsule and no plane of cleavage.