

Immunocytochemical Localization of Type B Collagen

A Component of Basement Membrane in Human Liver

Luis Biempica, MD, PhD, Rachel Morecki, MD, Catherine H. Wu, PhD, Marie-Adele Giambrone, BA, and Marcos Rojkind, MD, PhD

An indirect immunofluorescent method for localizing specific types of collagen was applied to unfixed cryostat sections of autopsy and biopsy specimens of normal and fibrotic human livers. Monospecific antibodies to Types I, III, and B collagens were raised in goats by injecting collagens extracted from normal and fibrotic human livers. The antibody against B collagen stained the delicate sinusoidal meshwork within the lobule that closely paralleled in distribution the staining of reticulin fibers as seen in classical silver preparations. Antibody to Type III collagen stained at the sinusoidal aspect of the hepatocytes in a pattern similar to anti-B antibody. All three antibodies tested strongly stained the portal tracts and the fibrotic bands in specimens with cirrhosis. These observations indicate that reticulin fibers within the liver lobule contain both Type III and Type B collagen. (*Am J Pathol* 1980, 98:591-602)

TYPES I AND III COLLAGENS have been determined quantitatively in normal and fibrotic livers.¹⁻³ These collagens have been localized also by immunofluorescence in human^{4,5} and rat livers.⁶ Connective tissue within the portal tracts has been stained with antibodies to Type I and Type III collagens. Reticulin fibers bordering sinusoids have been stained with antibodies to Type III collagen.

Recently, it has been shown by biochemical analysis that normal and fibrotic livers contain other collagens in addition to Type I and Type III. They may represent close to a third of total liver collagen. Their amino acid composition is similar to that of basement membrane; that is, they contain relatively more 3-hydroxyproline and hydroxylysine and relatively less alanine than interstitial collagens.⁷⁻⁹ Two of these collagens, A and B, have been recently isolated and characterized. They are similar to the A and B chains isolated from skin¹⁰ and to the α (A) and β (B) collagens isolated from placenta.¹¹ A and B collagens appear to be genetically distinct collagens and are made of three individual α -chains.¹²

In this communication, we present evidence to suggest that the fine reticulin fibers of the liver, especially those located at the sinusoidal surface

From the Departments of Pathology, Medicine, and Biochemistry and the Liver Center, Albert Einstein College of Medicine, Yeshiva University, Bronx, New York.

Supported by Liver Research Grant AM-17702 from the US Public Health Service. A preliminary report was presented at the annual meeting of the American Association for the Study of Liver Diseases, Chicago, Illinois, November 1977.

Dr. Rojkind's present address is Departamento de Bioquímica, Centro de Estudios Avanzados, I.P.N., Mexico 14, D.F.

Accepted for publication September 10, 1979.

Address reprint requests to Luis Biempica, MD, PhD, Department of Pathology, Albert Einstein College of Medicine, 1300 Morris Park Avenue, Bronx, NY 10461.

0002-9440/80/0310-0591\$01.00

©American Association of Pathologists

of the hepatocytes, stain with anti-B collagen antibodies. Our results also suggest that there is B collagen in the kidney within basement membranes of the glomeruli and tubules.

Materials and Methods

Collagens were extracted and purified as previously described.³ The purity and homogeneity of each of the collagens to be used as antigens were determined by SDS-acrylamide gel electrophoresis, CM-cellulose, and amino acid analysis of the individual α -chains.³ The antigen (100 μ g for Type I and Type III collagens and 320 μ g for B collagen), dissolved in 100 ml of 0.25 M acetic acid, was mixed with 0.9 ml of phosphate-buffered saline (PBS), pH 7.4, and 1.5 ml of complete Freund's adjuvant. The sample was homogenized at full speed for 90 seconds in a Sorval homogenizer. Goats received multiple intradermal injections of the antigen. They were bled at 1-week intervals, and the presence of antibodies was tested by immunodiffusion in 1.2% agarose. The immunization was repeated every 2 weeks until positive results were obtained. For the B collagen two injections were needed. For Type I and Type III collagens, four injections were needed. For Type I and Type III collagens, four injections were necessary. A booster shot was given to the goats, and 1 week later they were bled and sacrificed.

Purification of IgG

Immune serums were added to an equal volume of a saturated solution of ammonium sulfate and adjusted to pH 7.4.¹³ The sample was stirred slowly overnight at 4 C, and the pellets were washed three times with 50% saturated ammonium sulfate, dissolved in one fourth the original volume, and dialyzed exhaustively against several liters of 0.04 M phosphate buffer, pH 7.4. The dialyzed solution was applied to a column of DEAE cellulose 6.5 cm in diameter and 35 cm in height, equilibrated with the same buffer.^{14,15} Each of the fractions eluted from the column with the phosphate buffer was tested for antibody activity, and the positive fractions were lyophilized and stored at -70 C until needed.

Purification of the Antibody

Approximately 10 mg of each type of collagen was dissolved in 10 ml of 0.1 M phosphate buffer, pH 7.4, and mixed with 100 mg of bovine serum albumin (Sigma, fraction V). Three milliliters of 2.5% glutaraldehyde was added slowly with constant stirring, and the sample was kept (without agitation) for 3 hours at room temperature.¹⁶ The gel that formed was homogenized in 0.1 M phosphate buffer, pH 7.4, in a loosely fitting glass Teflon homogenizer, and the particles obtained were collected after centrifugation. The pellet was washed up to 10 times, each with 100 ml of PBS. After each wash, the sample was collected by centrifugation. The pellet was resuspended in PBS, and a small column (0.5 \times 5 cm) was prepared and washed with PBS. Aliquots of the antibody, 1 ml each, containing 1-5 mg protein were added to the column, allowed to enter the column, incubated for 2 hours at room temperature, and then eluted with PBS. The unbound antibodies were dialyzed against water and lyophilized. They were dissolved in 1 ml PBS and applied to a second collagen column. The specific antibodies that bound to the second collagen column were eluted with 10 ml 0.25 M acetic acid, neutralized to pH 7.4, dialyzed against several changes of distilled water, and lyophilized. For purification of anti-Type I collagen antibodies, the IgG fraction was first passed through a Type III collagen column and the unbound antibody through a Type I collagen column.¹⁷ The inverse procedure was used for purification of anti-Type III collagen antibodies. For the B antibodies, the antiserum was first passed through a Type III collagen column.

Immunofluorescent Staining

Normal and cirrhotic livers obtained at autopsy (12 cases) and surgical liver biopsy specimens from 12 patients with various types of liver disease were rapidly frozen. Cryostat sections 5 to 7 μ thick were mounted on prewashed glass slides and were air-dried. Indirect immunofluorescence staining was carried out as follows:

Sections were incubated in a moist chamber in Petri dishes. The sections were covered with monospecific antiserums to Types I, III, and B collagens with dilutions from 1:5 to 1:20 for 30–60 minutes.

Sections were rinsed in several changes of PBS, pH 7.4, for 10 minutes each.

Incubation of sections was carried out with anti-goat IgG globulin fluorescein isothiocyanate (FITC)-conjugated rabbit-globulin (Cappel Laboratories, Cochranville, Pa), diluted 1:10 to 1:20 for 60 minutes.

Sections were again rinsed in several changes of PBS, mounted in nonfluorescent medium (Difco Laboratories, Detroit, Mich), and examined in a Zeiss fluorescence microscope provided with either transmitted or incident illumination.

Controls were run as follows:

Frozen sections were rinsed in PBS for several minutes and mounted without any incubation for the evaluation of collagen autofluorescence.

Non-immune whole goat serum was used to incubate liver sections and then treated with FITC anti-goat rabbit globulin.

Immunized goat antiserums were absorbed with the specific antigen and used for the incubation of sections proceeding afterwards in the regular way.

Sections were rinsed with PBS for several minutes and then incubated with FITC-labeled antigoat rabbit globulin.

Results

Antibodies raised against Type I and Type III human collagens were species-specific. They did not react with rat, mouse, or dog collagens. However, the anti-B antibody was not species-specific and reacted with rat, mouse, and dog collagens. Although the antigen used contained 80% B collagen and 20% A collagen, the antibody produced reacted only with B collagen. None of the antibodies was tissue-specific. They displayed a positive reaction with homologous collagens extracted from skin, pancreas, spleen, and kidney.

Frozen sections of human kidney obtained from autopsies or biopsies served for differentiating the three collagen types investigated. Staining for B collagen yielded a clear delineation of vascular basement membranes (Figure 1), comparable to the staining given by the periodic acid-Schiff (PAS) reaction. The peritubular basement membrane was also clearly delineated. In liver sections, staining for the three collagens studied varied according to the particular area of the hepatic lobule and the degree of pathologic changes.

In normal livers, the portal tracts stained strongly for the three collagens, with no difference in the intensity of stain. Intralobularly, the sinusoids were stained for Types III and B collagens. Staining was comparable in intensity for both types and resulted in clear, sharp delineation of the

sinusoidal framework (Figures 2 and 3). Staining for B collagen gave a slightly more delicate pattern than staining for Type III. Fibers extended in between hepatocytes, producing a basket-like appearance (Figure 4). When fibrotic areas were stained, the fibrous bands, which also penetrated into the periphery of the hepatic lobules, were strongly reactive for all three collagen types. Within the regenerative nodules, staining for Type I collagen was negative. Staining for Type III and Type B collagens showed a sharp delineation of sinusoids with patchy areas of thickening identical to that seen with silver stains for reticulin (Figures 5–8). There was no staining with Type I collagen antibodies.

Discussion

Morphologic identification and biochemical determination of Types I and III collagens in normal and cirrhotic livers have been previously described.^{1,2,18} Recently, Rojkind et al³ showed that an important fraction of total hepatic collagen, almost one-third of the protein-bound hydroxyproline, corresponds to a polypeptide mixture with marked similarities to basement membrane collagens. Two of the polypeptides resemble the Types A and B extracted from human skin¹⁰ and from placenta.¹¹

In this study utilizing an indirect immunofluorescent method, an antibody raised against B collagen was found to stain the sinusoidal aspect of the hepatocytes. The reaction was uniform throughout normal hepatic lobules or regenerating nodules in cirrhotic livers. The staining, in the form of a delicate network, was similar to that obtained with the silver methods for reticulin. This is the first demonstration of the localization in the liver of collagen bearing the biochemical characteristics of Type B. In fibrotic livers biochemical studies have shown that the three collagen types accumulate in approximately equal proportions.³ However, after reaching 20 mg of total collagen per gram of wet tissue (normal 5.5 ± 1.6 mg/g), there is a continued rise of primarily Types I and B collagens, and the proportion of Type III collagen decreases. This finding is reflected in the staining pattern of the intranodular collagen, where thickening at the sinusoids is seen. Most probably this staining reflects a net gain in the deposit of Type B collagen. The concentration of 20 mg/g wet tissue appears to correspond to a stage when irreversible changes in the hepatic architecture occur. Histologically, the thick bands of collagen in the portal triads and fibrous septums or cirrhotic livers, which stain dark blue or green in trichrome preparations and mahogany brown with silver impregnation, react with antibody Types I, III, and B. Sinusoidal collagen, which stains faintly in trichrome preparation and black with silver impregnation, stains with antibody Types III or B.

Staining of peritubular and glomerular basement membrane in the kidney corresponds to the electron-dense continuous structure seen in electron microscopy. A similar correspondence is not seen in the liver, where no distinct basement membrane is detectable at the sinusoid. The failure to demonstrate such a structure in normal livers does not preclude its existence and may be due to a different molecular organization. Under abnormal conditions such as cirrhosis or in fibrosis produced by hyper-*vitaminosis A*, a basement membrane became apparent.^{19,20} Our studies, coupled with the typing and quantification of collagens in advanced cirrhosis,³ suggest that an increase in Type B collagen occurs with the development of intranodular fibrosis in the cirrhotic liver and may participate in the development of portal hypertension.

References

1. Rojkind M, Martinez-Palomo A: Increase in type I and type III collagens in human alcoholic liver cirrhosis. *Proc Natl Acad Sci USA* 1976, 73:539-543
2. Seyer JM, Hutcheson ET, Kang AH: Collagen polymorphism in normal and cirrhotic human liver. *J Clin Invest* 1977, 59:241-248
3. Rojkind M, Giambrone M-A, Biempica L: Collagen types in normal and cirrhotic liver. *Gastroenterology* 1979, 76:710-719
4. Gay S, Fietzek PP, Remberger K, Eder M, Kühn K: Liver cirrhosis: Immunofluorescence and biochemical studies demonstrate two types of collagen. *Klin Wochenschr* 1975, 53:205-208
5. Remberger K, Gay S, Fietzek PP: Immunohistochemische Untersuchungen zur Kollagencharakterisierung in Liebercirrhosen. *Virchows Arch [Pathol Anat]* 1975, 367:231-240
6. Kent G, Gay S, Inouye T, Bahu R, Miniak OT, Popper H: Vitamin A-containing lipocytes and formation of type III collagen in liver injury. *Proc Natl Acad Sci USA* 1976, 73:3719-3722
7. Ohno M, Riquetti P, Hudson BG: Bovine renal glomerular basement membrane: Isolation and characterization of a glycoprotein component. *J Biol Chem* 1975, 250:7780-7787
8. Kefalides NA: Basement membranes, *Mammalian Cell Membranes. Vol II, The Diversity of Membranes*. Edited by GA Jamieson, DM Robison. London, Butterworths, 1977, pp 298-322
9. Trelstad RL, Lawley KR: Isolation and initial characterization of human basement membrane collagens. *Biochem Biophys Res Commun* 1977, 76:376-384
10. Chung E, Rhodes RK, Miller EJ: Isolation of three collagenous components of probable basement membrane origin from several tissues. *Biochem Biophys Res Commun* 1976, 71:1167-1174
11. Burgeson RE, El Adli FA, Kaitila II, Holister DW: Fetal membrane collagens: Identification of two new collagen alpha chains. *Proc Natl Acad Sci USA* 1976, 73:2579-2583
12. Rhodes RK, Miller EJ: Physicochemical characterization and molecular organization of the collagen A and B chains. *Biochemistry* 1978, 17:3442-3448
13. Peters JH, Coons AH: Fluorescent antibody as specific cytochemical reagent, *Methods in Immunology and Immunochemistry*. Edited by CA Williams, MW Chase. Vol 5. New York, Academic Press 1976, pp 426-444

14. Peterson EA, Sober HA: Chromatography of proteins: I. Cellulose ion-exchange adsorbents. *J Am Chem Soc* 1956, 78:751-755
15. Sober HA, Gutter FJ, Wyckoff MM, Peterson EA: Chromatography of Proteins: II. Fractionation of serum protein on anion-exchange cellulose. *J Am Chem Soc* 1956, 78:756-763
16. Avrameas S, Ternynck T: The cross-linking of proteins with glutaraldehyde and its use for the preparation of immunoadsorbents. *Immunochemistry* 1969, 6:53-66
17. Nowack H, Gay S, Wick G, Becker U, Timpl R: Preparation and use in immunohistology of antibodies specific for type I and type III collagen and procollagen. *J Immunol Methods* 1976, 12:117-124
18. Gay S, Miller EJ: *Collagen in the Physiology and Pathology of Connective Tissue*. Stuttgart-New York, Gustav Fischer Verlag, 1978, pp 90-94
19. Schaffner F, Popper H: Capillarization of hepatic sinusoids in man. *Gastroenterology* 1963, 44:239-242
20. Hruban Z, Russell RM, Boyer JL, Glagov S, Bagheri SA: Ultrastructural changes in livers of two patients with hypervitaminosis A. *Am J Pathol* 1974, 76:451-468

Acknowledgment

The authors wish to thank Mrs. Stella L. Biempica for technical assistance.

[Illustrations follow]

Figure 1—Normal kidney stained for collagen Type B. It shows delicate staining of the basement membranes in the glomerulus and around the tubules. (×200)

Figure 2—Normal liver, small portal triad, stained for collagen Type III. It shows heavy stain of the collagen of the portal space and the delicate sinusoidal framework of the adjacent parenchyma. (×100)

Figure 3—Normal liver centrolobular area, stained for collagen Type B. The strongly stained reticulin framework shows projections in between hepatocytes and occasional basket-like appearance (*arrow*). (×260)

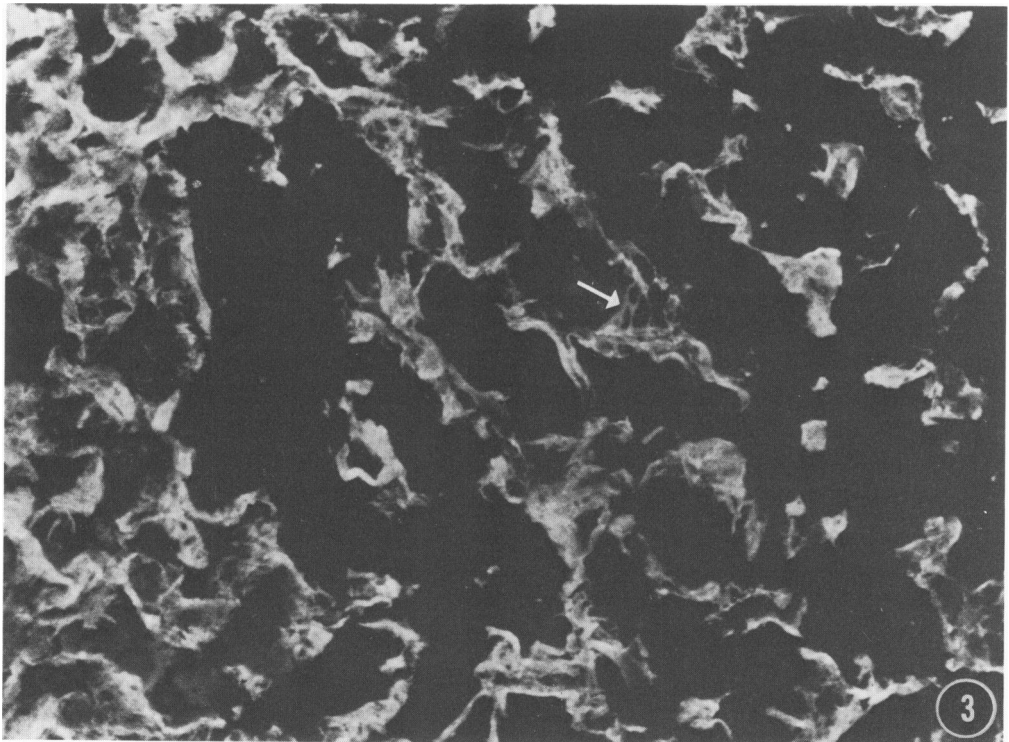
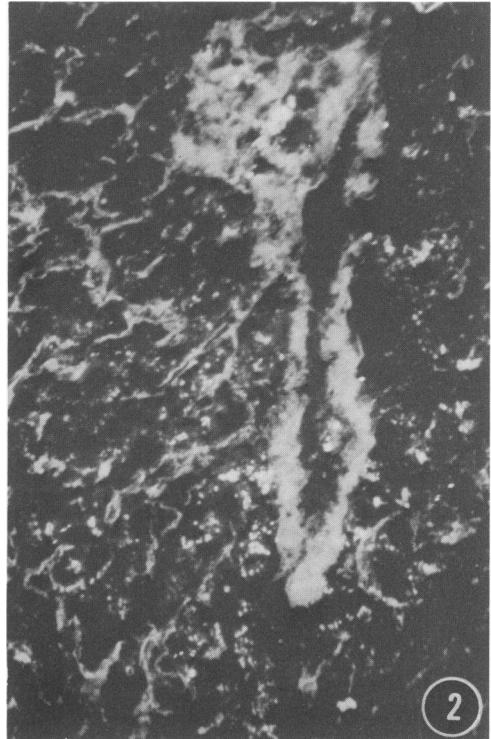
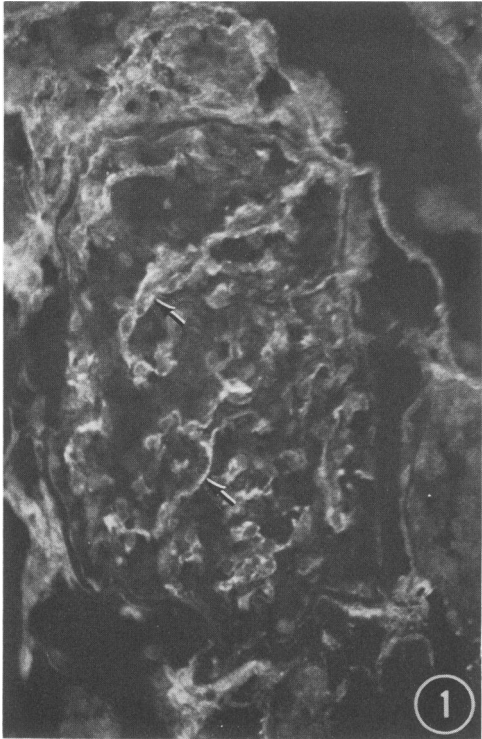
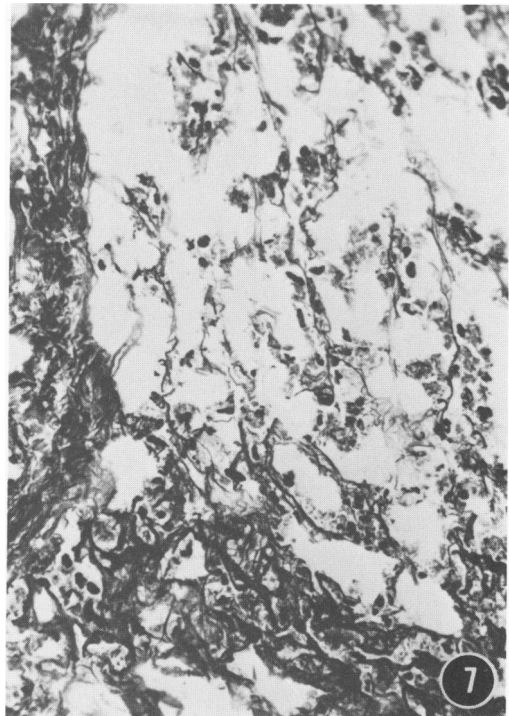
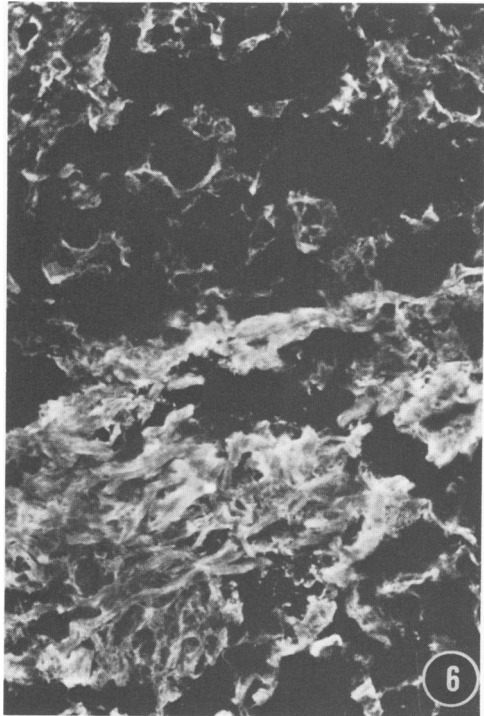
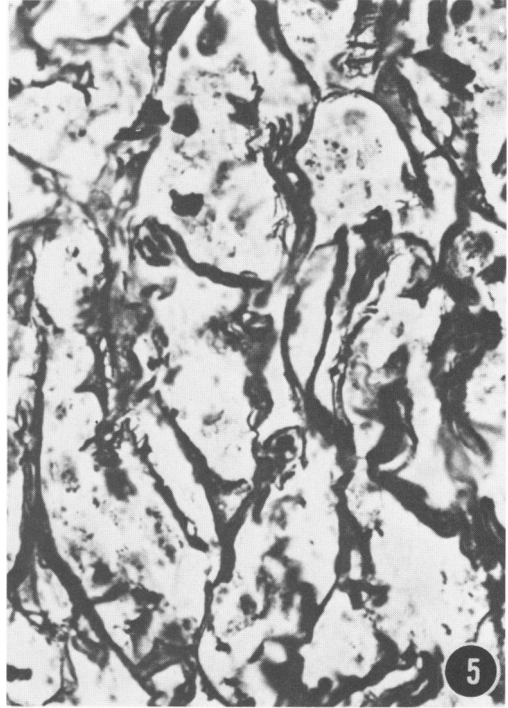
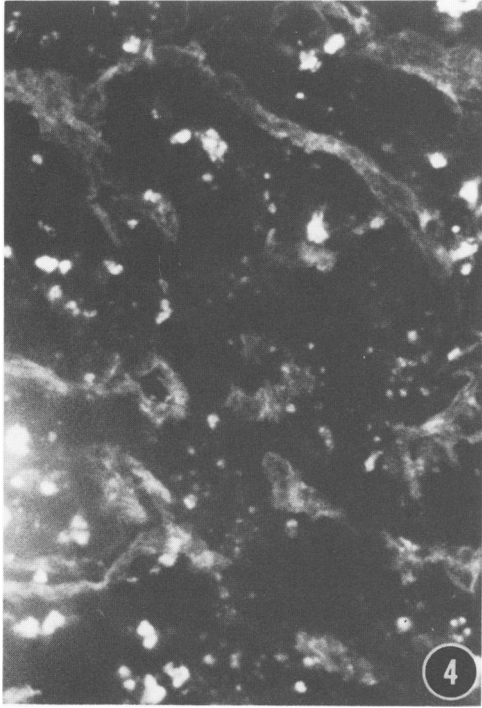


Figure 4—Normal liver, mid zone. Staining for collagen B shows delineation of sinusoidal profiles. The bright spots are given by the strongly autofluorescent lipofuscin bodies. (×260)

Figure 5—Same case as Figure 4, normal liver, unfixed cryostat section stained for reticulin. Delineation of reticulin framework along sinusoids shows a pattern comparable to the fluorescence staining of Figures 3 and 4. Silver-positive granules correspond to lysosomes (mostly lipofuscin bodies). (×260)

Figure 6—Cirrhotic liver. Staining for collagen B shows heavy fluorescence at the fibrotic bands and irregularly delineated sinusoids in the regenerative nodules. (×100)

Figure 7—Same case as Figure 6 stained for reticulin. It shows heavy stain in fibrotic bands. In the original preparation, thick collagen fibers show mahogany brown color intermingled with thin reticulin fibers stained black. The intranodular reticulum also stains black. (×100)



[End of Article]