

ANIMAL MODEL OF HUMAN DISEASE

A Model for the Study of Stroke Using the Rat

Surgical Ligation of the Middle Cerebral Artery in the Rat

ROBERT G. ROBINSON, MD

*From the Department of Psychiatry and Behavioral Sciences,
The Johns Hopkins University School of Medicine, Baltimore, Maryland*

Biologic Features

Sprague-Dawley male rats approximately 7–20 weeks of age (weight 150–450 g), have been used for study of the biochemical and behavioral consequences of cerebral cortical infarction.

Clinical features

Immediately following ligation of the middle cerebral artery, there is a decreased response to rubbing the fur or pinching the limbs on the contralateral side.^{1,15} Although the animals are able to walk, they do not move their contralateral rear limb as briskly as the ipsilateral. There is no unilateral turning behavior, and in an open field environment the animals appear to walk normally except for the slight limp on the contralateral side. These clinical features are no longer demonstrable by 24 hours after the operation. There are behavioral alterations such as spontaneous hyperactivity² and changes in shock-induced aggression¹ and intracranial self-stimulation³ which last for several weeks after the operation.

Pathologic Features

By five days after the operation there is a distinct area of infarction within the fronto-parietal cortex above the rhinal fissure and lateral to the cingulate cortex (Figure 1). The size and location of infarction varies from animal to animal, but generally the lesion is circular in shape and is about 1–2 mm in diameter. The lesion extends to a variable depth (50–100%) through the cortex but does not involve subcortical tissue. Fluorescence histochemical studies, by five days after infarction, reveal a decrease in the number of visible fluorescence varicosities in both the ipsilateral and

contralateral cortex and a decrease in the intensity of fluorescence within the cell bodies located in the locus ceruleus.⁴ However, by 40 days after the operation there is an increase in the number of visible varicosities within the cortex. This finding suggests that during the 40-day postoperative period, either collateral sprouting occurs⁵ or the concentration of norepinephrine within existing varicosities increases.

Experimental Induction of the Model

Under chloral hydrate anesthesia, rats are placed in a stereotaxic apparatus and their scalps are shaved and opened at the midline. The temporal muscle is cut along its line of insertion and reflected away from the temporal bone. With a small dental drill bit, a craniotomy is made that extends from the coronal suture to the periorbital area and from the zygomatic arch to the ridge separating the dorsal and lateral skull. Under a stereomicroscope, a semicircular ophthalmologic needle with 6-0 suture is passed through the dura, behind the middle cerebral artery, and out again through the dura. The artery and overlying dura are ligated, and a small hole is made in the dura with a 25-gauge needle just distal to the ligature so that the

Publication sponsored by the Registry of Comparative Pathology of the Armed Forces Institute of Pathology and supported by Public Health Service Grant RR-00301 from the Division of Research Resources, National Institutes of Health, under the auspices of Universities Associated for Research and Education in Pathology, Inc.

Address reprint requests to Dr. Robert G. Robinson, Department of Psychiatry, Johns Hopkins University School of Medicine, Traylor Bldg., Rm. 623, Baltimore, MD 21205.

Supported in part by NIH grants RCDA MH00163 and NS15178.

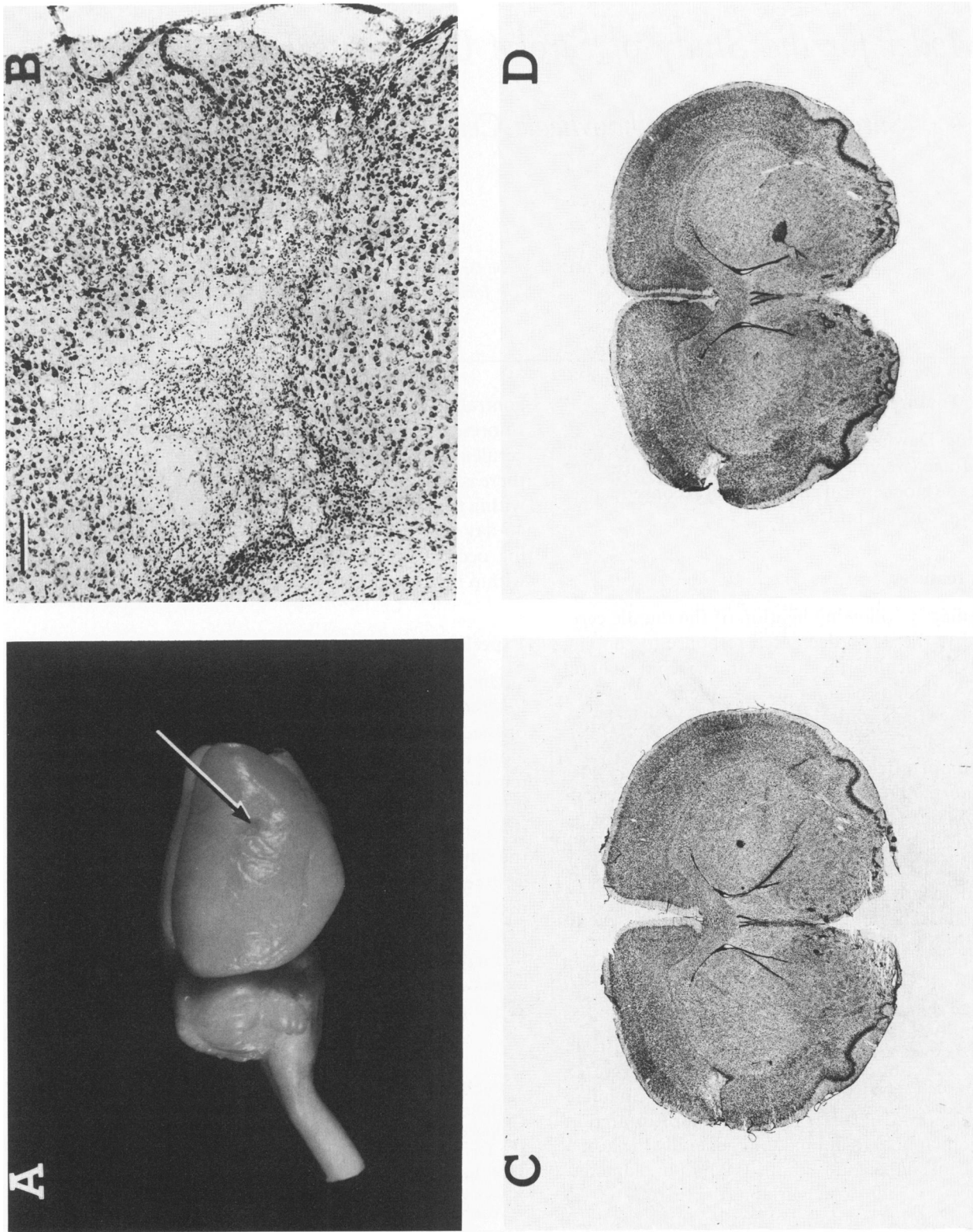


Figure 1A—Whole brain 30 days after right middle cerebral artery ligation. The lesion site is indicated by the arrow. **B**—Microscopic appearance of a right hemispheric infarction 30 days after surgery. The cellular infiltrate is still visible throughout the lesion. The lesion extends through the entire depth of the cortex in this case. The marker (upper left) indicates 200 μ . **C and D**—Toluidine-blue-stained coronal brain section 25 μ thick through the lesion site. The lesions extend through the cortex but do not involve subcortical tissue.

artery can be severed with dural scissors. The temporal muscle is then sutured to subcutaneous fascia on the dorsal skull, and the incision is closed.

Comparison With Human Disease

Ligation of the middle cerebral artery in the rat produces a focal infarct of variable size within the frontal parietal cortex. The variable size and location of the infarct may also occur in man. The major difference between the human disease and the rat model is that occlusion of the major trunk of the middle cerebral artery in the rat does not produce a sustained hemiparesis and hemisensory deficit, as would be seen in humans. Presumably, the reason for this difference is that the motor-sensory cortex in the rat is more medial than in man,⁶ and the hemiparesis in the rat results from transient ischemia rather than direct infarction.

Usefulness of the Model

The major advantage of this model is that it produces a nonlethal, discrete focal lesion. The small size and discrete nature of this lesion contrasts with other animal models of stroke which produce global ischemic lesions,⁹ diffuse hemispheric anoxic lesions,¹⁰ massive hemispheric infarctions,^{11,12} or diffuse hemispheric microinfarctions.^{13,14} The discrete lesions produced by ligation of the middle cerebral artery allow long-term behavioral and biochemical studies to be carried out in which the lesion is localized to one area of the cerebral cortex. However, because of the variability in lesion size, comparisons of the biochemical and behavioral effects of lesions in one location with those of other locations must be carefully controlled for lesion size.

We have developed two methods for the quantitation of lesion size. One utilizes independent raters,⁷ while the other uses vernier scales mounted on the stereomicroscope.⁸ As an example of the utility of this model of stroke, we have demonstrated that a unilateral fronto-parietal right hemispheric infarct produces a 20-day period of spontaneous hyperactivity and a 60–70% decrease in norepinephrine and dopamine concentrations in the ipsilateral and contralateral cerebral cortex, locus ceruleus, and substantia nigra by 12 hours after the operation, with a slow recovery throughout the remainder of the 40-day post-operative period.¹⁵ Middle cerebral artery ligation in the left hemisphere, which produces a comparably

sized lesion, does not cause any of these biochemical or behavioral changes.⁵ The neural asymmetries responsible for this phenomenon have not yet been elucidated.

References

1. Robinson RG, Shoemaker WJ, Schlumpf M, Valk T, Bloom FE: Effect of experimental cerebral infarction in rat brain on catecholamines and behaviour. *Nature* 1975, 255:332–334
2. Robinson RG, Bloom FE: Pharmacological treatment following experimental cerebral infarction: Implications for understanding psychological symptoms of human stroke. *Biol Psychiatr* 1977, 12:669–680
3. Robinson RG, Bloom FE: Changes in posterior hypothalamic selfstimulation following experimental cerebral infarction in the rat. *J Comp Physiol Psychol* 1978, 92:969–976
4. Robinson RG, Bloom FE, Battenberg ELF: A fluorescent histochemical study of changes in noradrenergic neurons following experimental cerebral infarction in the rat. *Brain Res* 1977, 132:259–272
5. Bowen FP, Karpiak SE Jr, Demirjian C, Katzman R: Sprouting of noradrenergic nerve terminals subsequent to freeze lesions of rabbit cerebral cortex. *Brain Res* 1975, 83:1–14
6. Hall RD, Lindholm EP: Organization of motor and somatosensory neocortex in the albino rat. *Brain Res* 1974, 66:23–38
7. Robinson RG: Differential behavioral and biochemical effects of right and left hemispheric cerebral infarction in the rat. *Science* 1979, 205:707–710
8. Pearlson GD, Robinson RG: Suction lesions of the frontal cerebral cortex in the rat induce asymmetrical behavioral and catecholaminergic responses. *Brain Res* (In press)
9. Brown RM, Carlson A, Ljunggren B, Siesjo BK, Snider SR: Effect of ischemia on monoamine metabolism in the brain. *Acta Physiol Scand* 1976, 90:789–794
10. Levy DE, Brierley JB, Silverman DG, Plum F: Brief hypoxia-ischemia initially damages cerebral neurons. *Arch Neurol* 1975, 32:450–456
11. Welch KMA, Chabi E, Buckingham J, Bergin B, Anchar VS, Meyer JS: Catecholamine and 5-hydroxytryptamine levels in ischemic brain, influence of *p*-chlorophenylalanine. *Stroke* 1977, 8:341–346
12. Zervas NT, Hori H, Negora M, Wurtman RJ, Larin F, Lavyne MH: Reduction of brain dopamine following experimental cerebral ischemia. *Nature* 1974, 247:283–284
13. Kogure K, Scheinberg P, Matsumoto A, Busto R, Reinmuth OM: Catecholamines in experimental brain ischemia. *Arch Neurol* 1975, 32:21–24
14. Furlow TW Jr, Bass NH: Stroke in rats produced by carotid injection of sodium arachidonate. *Science* 1975, 187:658–660
15. Robinson RG, Coyle JT: The differential effect of right versus left hemispheric cerebral infarction on catecholamines and behavior in the rat. *Brain Res* 1980, 188:63–78