

Chemical Bursectomy of Chickens With Colchicine Applied to the Anal Lips

Timo Romppanen, MD, and Tapani E. Sorvari, MD

To induce chemical bursectomy, 30 μ l colchicine dissolved in saline solution (1 mg/ml) was applied on the anal lips of White Leghorn chickens once daily for four consecutive days after hatching. Histologic characteristics of the bursa of Fabricius, spleen, thymus, cecal tonsils, and rectal wall were studied 1-7 days after hatching. Total necrosis of the lymphoid cells and the follicle-associated epithelium in the bursa was observed during the four days of colchicine application. The bursal stroma remained unchanged, and only minor changes were found in the interfollicular surface epithelium. After colchicine application ceased, some regeneration of the epithelium, as evidenced by small epithelial buds, was found. At the end of the observation period the epithelial buds were often covered by the follicle-associated epithelium, which was capable of phagocytizing carbon. However, practically no lymphoid repopulation was seen in the buds. Since this method of colchicine application had no direct effect on other lymphoid organs or on the survival or weight of the chickens, this bursectomy model seems to be a new tool for use in studies of bursal function. (*Am J Pathol* 1980, 100:193-208)

THE IMPORTANCE of the microenvironment of the bursa of Fabricius for development of the B-cell line and humoral immunity in chickens has been shown by the use of several experimental methods. These include surgical bursectomy,^{1,2} treatment with testosterone,³⁻⁶ cyclophosphamide,⁷⁻⁹ or antiserum against the μ chain,^{10,11} X-ray irradiation,¹² and combinations of these.^{12,13}

The follicular epithelium seems to be an important microenvironment for development of the B-cell line. Transplantation of bursal lymphocytes from chick embryos or newly hatched chickens into chick embryos and 4-day-old chickens that were immunodeficient due to treatment with cyclophosphamide resulted in maturation of donor lymphocytes in the originally alymphoid epithelial buds of the recipients and restoration of immunologic functions.¹⁴⁻¹⁶

The microenvironment of the follicular medulla seems to be modified by the follicle-associated epithelium, which has the unique capacity of very active phagocytosis and is important in transporting various materials from the bursal lumen to the medulla of the bursal follicles.^{17,18} Because environmental antigens can be transported to the bursal lumen by anal sucking movements, the microenvironment of the medulla of bursal

From the Department of Pathology, University of Kuopio, Kuopio, Finland.

Accepted for publication February 14, 1980.

Address reprint requests to Timo Romppanen, MD, Department of Pathology, University of Kuopio, P.O. Box 138, 70101 Kuopio 10, Finland.

lymphoid follicles is in contact with environmental antigens via the follicle-associated epithelium.¹⁹⁻²¹

With the experimental bursectomy methods described above there is an extensive influence either on all bursal tissues (surgical bursectomy, X-ray irradiation)^{1,2,12} or also on other lymphoid tissues, such as thymus and spleen (testosterone treatment *in ovo*, cyclophosphamide, antiserum against μ -chain).^{3-5,7-11} An experimental approach where bursal lymphoid cells could be selectively destroyed without significant systemic effects should be a welcome help in investigating the microenvironment of the bursa. Neonatal testosterone treatment fulfills these requirements only partially, because it causes some systemic effects on other organs, such as the comb.⁶

In this paper we describe a new model for chemical bursectomy where, by applying colchicine solution to the anal lips, the bursal lymphoid tissues can be totally destroyed without any apparent direct effect on other organs or lymphoid tissues.

Materials and Methods

Laboratory Animals

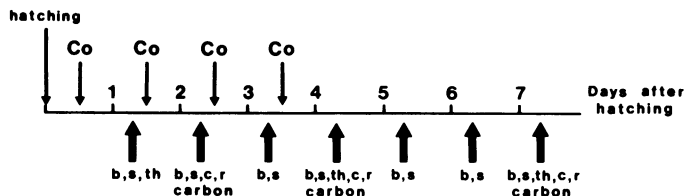
Newly hatched White Leghorn chickens were received from a local hatchery. They were given commercial chicken food and water *ad libitum*.

Colchicine Application

Once daily for 4 consecutive days, beginning on the day of hatching, 30 μ l colchicine (E. Merck, Darmstadt, Germany) dissolved at a concentration of 1 mg/ml in saline solution was applied to the anal lips of the chickens (Text-figure 1). With this dosage, the mortality of these chickens was not significantly higher than that of the controls. In preliminary experiments a concentration of 0.5 mg/ml was found to be ineffective for destroying the bursal lymphoid tissues. Higher concentrations (2 mg/ml and higher) increased mortality significantly.

Autopsies and Tissue Sampling

The schedule for autopsies and tissue sampling is presented in Text-figure 1. One to seven days after hatching the chickens were killed with an overdose of ether. The chick-



TEXT-FIGURE 1—Schedule for colchicine application and tissue sampling. Co = time of colchicine application to the anal lips of chickens. Large arrows = time of tissue sampling, b = bursa, s = spleen, th = thymus, c = cecal tonsil, r = rectal wall, carbon = application of India ink to test the phagocytic capacity of the follicle-associated epithelium.

ens, their bursae, and their spleens were weighed. A histologic specimen from the transverse midline of the bursa and the spleen was taken from each animal, fixed overnight in 4% neutral buffered formaldehyde, and embedded in paraffin. In addition, one cecal tonsil and a piece of the rectal wall from chickens aged 2 (5 chickens), 4 (15 chickens), and 7 (15 chickens) days, as well as the thymus of chickens aged 1 (3 chickens), 4 (5 chickens), and 7 days old (5 chickens) were removed for morphologic studies. Tissue sections 6 μ thick were cut and stained by the van Gieson-hematoxylin and hematoxylin-eosin methods. In addition, the spleens were stained with methyl-green-pyronin applied for formalin-fixed material.²²

Functional Tests

Interfollicular Epithelium and Mucin Secretion

Since the interfollicular epithelium is known to secrete mucin,²¹ all bursae were stained with alcian blue, pH 2.5, and periodic acid-Schiff²³ for examination of the mucosubstances.

Follicle-Associated Epithelium and Endocytosis

In order to study the known phagocytizing capability of the follicle-associated epithelium,^{17,18} 50 μ l India ink (Pelikan, 17 noir, Gunther Wagner, Germany) was applied to the anal lips of 10 chickens aged 2, 4, and 7 days five times at 30-minute intervals before they were killed. Histologic preparations were made as described above.

Results

Chicken, Spleen, Thymus, and Bursal Weights

In no age group was the mean body weight significantly smaller than that of the control animals. On the contrary, by Day 5 the mean body weight for the experimental animals was higher than that of the controls (Table 1). The mean weight of the spleen (mg/100 g body weight) on Days 1-6 did not differ significantly from that of the controls, whereas on Day 7 the difference was significant (Table 1). Despite a slight decrease in the mean weight of the thymus (mg/100 g body weight) after the application of colchicine, the difference was not significant when compared with that of the controls (Table 2). The mean weight of the bursa in the control group increased from 59 mg to 139 mg during the experimental period (Text-figure 2). In contrast, the bursae in the colchicine group decreased in weight from 46 mg to 29 mg (Text-figure 2).

Histologic Features of the Bursa

After one colchicine application, signs of serious tissue injury were already evident. The histopathologic changes are summarized in Table 3. In detail, the following changes were observed.

On Day 1, the follicle-associated epithelium, the center of the follicular epithelium, and practically all lymphoid cells were necrotic (Figures 1 and 2). In the interfollicular surface epithelium some cytoplasmic vacu-

Table 1—Body and Spleen Weights for Control Chickens and for Chickens Treated With Colchicine

Days after hatching	Treatment with colchicine	Number of chickens	Body weight (g)	SD	Spleen weight (mg/100 g body weight)	SD
1	—	3	33.6	3.2	55.3	10.7
1	+	5	39.5	5.7	54.2	13.2
2	—	8	43.8	6.3	76.4	16.9
2	+	10	40.2	5.9	85.0	18.9
3	—	3	42.0	5.6	59.7	4.0
3	+	5	39.5	4.9	59.0	11.6
4	—	13	46.8	4.9	105.1	24.8
4	+	20	47.9	4.8	92.8*	36.6
5	—	3	39.7	3.1	99.0	8.5
5	+	5	51.2†	5.0	82.9	28.7
6	—	3	44.2	7.2	83.7	29.3
6	+	5	53.7	5.7	81.7	21.3
7	—	20	54.4	5.3	112.1	37.7
7	+	25	57.7*	5.7	89.0‡	19.8

* No significant difference (when compared with control chickens; Student *t* test).

† Significant difference ($P < 0.02$).

‡ Significant difference ($P < 0.025$).

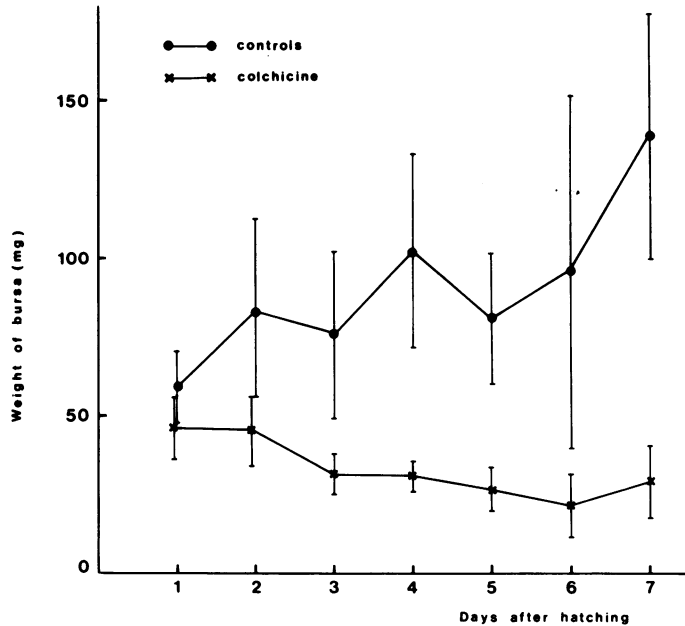
olization and an increased number of mitoses were found. In the interfollicular connective tissue no microscopic changes were observed. On Day 2, the follicle-associated epithelium was completely absent. The necrotic center of the follicular epithelium was demarcated (Figures 3 and 4). Of the lymphoid cells only necrotic remains were seen as "nuclear dust." In the interfollicular surface epithelium a pseudostratification was often observed. Due to the depletion of lymphoid tissue, the relative amount of interfollicular connective tissue seemed to have increased (Figure 3).

On Day 3, the changes in the follicle-associated epithelium, the interfollicular surface epithelium, and the interfollicular connective tissue were the same as on Day 2. The necrotic material in the center of the fol-

Table 2—Thymus Weight for Control Chickens and for Chickens Treated With Colchicine

Days after hatching	Treatment with colchicine	Number of chickens	Thymus weight (mg/100 g body weight)	SD
1	—	3	289.5	30.7
1	+	3	337.8	56.9
4	—	5	351.6	58.0
4	+	5	318.9*	63.6
7	—	5	348.1	42.0
7	+	5	302.4*	18.9

* No significant difference when compared with the untreated control chickens.



TEXT-FIGURE 2—Mean weight of the bursa (mg) in untreated control chickens (●—●) and in chickens treated with colchicine (X—X). The bars represent SD values.

lices began to discharge into the bursal lumen. Almost no lymphoid cells were seen.

One to three days after the last application of colchicine (Days 4–6), some small primitive epithelial buds without follicle-associated epithelium were found (Figure 5). On Day 4 the number of these primitive buds in a transverse midline section of the bursa was, in most cases, less than 21 (Table 4). This was a striking morphologic difference, compared with the control bursae (Figure 6), which on Day 4 contained a mean of 444 lymphoid follicles (determined from 4 bursae) in corresponding cross-sections. In 17 of 20 chickens in the colchicine group no lymphoid cells were found in the developing buds. Only in 3 cases were 1, 4, and 101 follicles populated with lymphoid cells found in cross-sections of the bursa.

On Days 4–6 the morphologic character of the interfollicular surface epithelium was unchanged. Occasionally some lymphoid cells were seen in the stroma, near the buds.

At the end of the observation period (Day 7), discharge of necrotic materials into the bursal lumen was almost completed. In the area of a previously necrotic follicle there was either a crypt lined by tall columnar epithelium, similar to the interfollicular surface epithelium, or a regenerating bud, on which follicle-associated epithelium often was seen (Figure

Table 3—Morphologic Changes in the Bursa After Colchicine Application

Days after hatching	Follicle-associated epithelium	Follicular epithelium	Interfollicular epithelium	Lymphoid cells	Interfollicular stroma
1	Necrotic or absent	Necrotic in center	Cytoplasmic vacuolization, mitoses	Necrotic	No light-microscopic changes
2	Absent	Demarcation of necrotic center	Cytoplasmic vacuolization, mitoses, pseudostratification	Absent	Relative amount increased
3	Absent	Discharging of necrotic material into bursal lumen	Cytoplasmic vacuolization, mitoses, pseudostratification	Mostly absent	Relative amount increased
4-6	Absent, no phagocytosis of carbon	Discharging of necrotic material into bursal lumen, beginning of the regeneration	Cytoplasmic vacuolization, cysts	Mostly absent	Relative amount increased
7	Present in bursae with buds, phagocytosis of carbon	Partly regenerated buds	Cytoplasmic vacuolization, cysts	Mostly absent	Relative amount increased, contains some lymphoid cells

• Table 4—Number of Buds in Cross Midline Section of Bursae in Chickens Treated With Colchicine

Number of buds in cross midline section of bursa	Number of cases	
	4 days after hatching	7 days after hatching
0	5	11
1-20	10	10
21-40	4	2
Over 41	1	2

7). The number of buds in a transverse midline section (Table 4) was the same as 3 days previously, and only in 2 cases were more than 40 (78 and 122) buds seen. In only 3 of 25 cases were some of the buds populated with lymphoid cells. The appearance of these lymphoid follicles did not differ from that of those of the untreated control chickens. In the interfollicular surface epithelium were seen cysts of various sizes. In the stroma were observed a few lymphoid cells around the buds and the epithelial crypts.

Functional Tests

Interfollicular Epithelium and Mucin Secretion

In control chickens, most cells of the interfollicular surface epithelium contained acid mucosubstances as small apical intracytoplasmic vacuoles (Figure 8). Among cells that stained positive with alcian blue (pH 2.5), few were observed to contain only neutral mucin. On the surface of the whole interfollicular surface epithelium was seen a thin layer of acid mucin (Figure 8). In the follicle-associated epithelium and the follicular epithelium practically no mucin was found, so the secretion of mucin in the bursal epithelial tissues seems to be exclusively a function of the interfollicular surface epithelium.

In chickens treated with colchicine the staining pattern of the interfollicular surface epithelium was essentially the same as in the controls (Figure 9). The contents of vacuoles and cysts in the interfollicular surface epithelium seemed to take up alcian blue. In cases where no bud regeneration had occurred, the tall columnar epithelium of the crypts had the same staining pattern as the interfollicular surface epithelium, indicating that regeneration apparently had taken place from interfollicular surface epithelium. Regenerated buds did not contain any mucosubstances.

Follicle-Associated Epithelium and Endocytosis

The anal sucking movements following the application of India ink to the anal lips were similar to those of the colchicine-treated and the con-

trol chickens, and in both groups carbon was taken up from the anal lips into the bursal lumen.

On Days 2 and 4, no carbon was taken up by bursal epithelium in the colchicine-treated group, whereas an intensive accumulation of carbon particles was seen in the follicle-associated epithelium of the control group. Seven days after hatching, however, the follicle-associated epithelium in 7 out of 10 cases in the colchicine-treated group took up carbon, but to a lesser extent than did the control group (Figure 7).

Histologic Features of Other Organs

No major differences between the control chickens and the colchicine-treated chickens were observed in the microscopic appearance of the spleen, thymus, and cecal tonsils. The same qualitative pattern of lymphoid cells was seen in both groups. In no case were germinal centers observed. No pathologic alterations occurred in the rectal mucosa.

Discussion

When applied to the anal lips, the mitosis-arresting agent colchicine caused necrosis of all lymphoid cells, follicle-associated epithelium, and the center of the follicular epithelium in the chicken bursa. No significant signs of injury were seen in peripheral parts of the follicular epithelium, where so-called secretory cells had been demonstrated recently.^{24,25} The bursal stroma and the interfollicular surface epithelium also resisted the effects of colchicine well. The layer of acid mucins on the surface of the interfollicular surface epithelium may have a protective function, which prevents significant injuries by chemical agents. Apparently, transport of colchicine by the bursa is similar to that described for various other foreign materials¹⁷⁻¹⁹: uptake by the follicle-associated epithelium and transport further into the follicular medulla. Foreign material presumably reaches the follicular cortex and the stroma later and in smaller amounts. However, enough colchicine is transported to the cortical areas of lymphoid follicles to cause necrosis of lymphoid cells, which seemed to be far more susceptible to colchicine than the cells of connective tissue type in the follicular cortex and the stroma.

Corresponding changes have been observed in tissue culture of bursae by Eerola.²⁶ In a culture medium the bursal follicles lost their lymphocytes; the follicle-associated epithelium and medullary contents were discharged at the surface of the mucosa.

Schaffner et al applied colloidal particles of radioactive plutonium (²³⁹Pu) via the cloaca to newly hatched chickens.²⁷ Initially they found damage to the lymphoid cells and the follicle-associated epithelium. Some

weeks later reparative processes were evident, and the bursal follicles were separated from the bursal surface epithelium by connective tissue. No regeneration of the follicle-associated epithelium was evident, and no uptake of carbon by the bursal tissue was observed, findings that are different from those of the present study.

Colchicine, when applied to the anal lips in the concentrations used in this study, seems to have no apparent systemic effects if body weight and survival are used as indicators. The greater body weight for chickens of the colchicine group on Day 5, compared with that of the control chickens, can be explained by the small number of chickens examined at this time. Nor were there any apparent direct effects on other lymphoid organs, such as the spleen, the thymus, or the cecal tonsils, or on the rectal wall. The difference in the spleen weight on Day 7 can be interpreted as a secondary effect due to depletion of lymphoid cells of bursal origin, which could home in the spleen. The thymic weight in the colchicine group was a little smaller than in the control group. This difference was not significant. Also, histologically, the thymus glands in both groups were similar.

After the application of colchicine to the anal lips, only the bursal microenvironment is drastically changed. The only components that resist this chemical agent are the bursal stroma and the interfollicular surface epithelium. A few epithelial cells, however, proliferate to form epithelial buds in the bursal stroma. The surface epithelium associated with these buds often is capable of phagocytizing and thus resembles normal follicle-associated epithelium functionally. This process can be interpreted as partial regeneration.

This method differs in many respects from those which have been used previously. Bursectomy caused by cyclophosphamide, given systemically *in ovo* or after hatching,^{7-9, 14} causes severe depletion of the lymphoid cells of the B-cell line in the whole chicken, together with severe hypogammaglobulinemia. The same result occurs with another method, where chickens that have undergone surgical bursectomy are exposed to whole body X-ray irradiation,¹² or with the use of antiserum against the μ -chain, which destroys lymphoid cells of the B-cell line of the chickens.^{10,11} Surgical bursectomy alone eliminates the bursal microenvironment *in toto* but saves other lymphatic organs.^{1,2} On the other hand, *in ovo* hormonal bursectomy caused with testosterone between the 5th and 12th days of incubation totally prevents development of the bursa or results in a rudimentary sack lined by pseudostratified epithelium.³⁻⁵ With this method the change in the bursal microenvironment may be due to a lack of alkaline phosphatase in cells of the bursal stroma,^{28, 29} which may render the bursal stroma "hostile" to B cells and prevent transplanted B cells from

homing in the bursa.²⁹ When testosterone is given later, either embryonally or during the neonatal period, it causes bursal changes resembling the results presented in this study.³ The effects of testosterone on other lymphatic organs, such as the thymus and the spleen, seem to be slight, whereas some systemic effects occur in other organs, such as the comb. Other steroids, like cortisone, given during the newly hatched period to the chickens also modify the bursal development, but concomitant effects occur in other lymphatic organs, such as the thymus.⁶

We conclude that lymphoid cells in the chicken bursa can be destroyed selectively by applying colchicine solution to the anal lips as reported in this paper. This bursectomy method differs in many respects from surgical and chemical bursectomy methods used previously and provides a new tool for studying the bursal microenvironment during development of the B-cell line.

References

1. Chang TS, Glick B, Winter AR: The significance of the bursa of Fabricius of chickens in antibody production. *Poult Sci* 1955, 34:1187
2. Glick B, Chang TS, Jaap RG: The bursa of Fabricius and antibody production. *Poult Sci* 1956, 35:224-225
3. Meyer RK, Rao MA, Aspinall RL: Inhibition of the development of the bursa of Fabricius in the embryos of the common fowl by 19-nortestosterone. *Endocrinology* 1959, 64:890-897
4. Warner NL, Burnet FM: The influence of testosterone treatment on the development of the bursa of Fabricius in the chick embryo. *Aust J Biol Sci* 1961, 14:580-587
5. Warner NL, Szenberg A, Burnet FM: The immunological role of different lymphoid organs in the chickens: I. Dissociation of immunological responsiveness. *Aust J Exp Biol Med Sci* 1962, 40:373-388
6. Glick B: Immunity studies in testosterone propionate injected chicks. *Int Arch Allergy Appl Immunol* 1970, 38:93-103
7. Lerman SP, Weidanz WP: The effect of cyclophosphamide on the ontogeny of the humoral immune response in chickens. *J Immunol* 1970, 105:614-619
8. Linna TJ, Frommel D, Good RA: Effects of early cyclophosphamide treatment on the development of lymphoid organs and immunological functions in the chickens. *Int Arch Allergy Appl Immunol* 1972, 42:20-39
9. Eskola J, Toivanen P: Effect of *in ovo* treatment with cyclophosphamide on lymphoid system in chicken. *Cell Immunol* 1974, 13:459-471
10. Kincade PW, Lawton AR, Bockman DE, Cooper MD: Suppression of immunoglobulin G synthesis as a result of antibody-mediated suppression of immunoglobulin M synthesis in chickens. *Proc Natl Acad Sci USA* 1970, 67:1918-1925
11. Kincade PW, Cooper MD: Development and distribution of immunoglobulin-containing cells in the chicken: An immunofluorescent analysis using purified antibodies to μ , γ and light chains. *J Immunol* 1971, 106:371-382
12. Cooper MD, Peterson RDA, South MA, Good RA: The functions of the thymus system and the bursa system in the chickens. *J Exp Med* 1966, 123:75-102
13. Weidanz WP, Konietzko D, Lerman SP: The effect of combined chemical bursectomy on antibody formation at the cellular level. *J Reticuloendothel Soc* 1971, 9:635

14. Toivanen P, Toivanen A: Bursal and postbursal stem cells in chicken: Functional characteristics. *Eur J Immunol* 1973, 3:585-595
15. Sorvari T, Toivanen A, Toivanen P: Transplantation of bursal stem cell into cyclophosphamide-treated chicks. *Transplantation* 1974, 17:584-592
16. Eskola J, Toivanen P: Cell transplantation into immunodeficient chicken embryos: Reconstituting capacity of cells from the bursa of Fabricius, spleen, bone marrow, thymus and liver of 18-day-old embryos. *Cell Immunol* 1976, 26:68-77
17. Schaffner T, Mueller J, Hess MW, Cottier H, Sordat B, Ropke C: The bursa of Fabricius: A central organ providing for contact between the lymphoid system and intestinal content. *Cell Immunol* 1974, 13:304-312
18. Sorvari T, Sorvari R, Ruotsalainen P, Toivanen A, Toivanen P: Uptake of environmental antigens by the bursa of Fabricius. *Nature* 1975, 253:217-219
19. Sorvari R, Naukkarinen A, Sorvari TE: Anal sucking-like movements in the chicken and chick embryo followed by the transportation of environmental material to the bursa of Fabricius, caeca and caecal tonsils. *Poult Sci* 1977, 56:1426-1429
20. Sorvari R, Sorvari TE: Bursa Fabricii as a peripheral lymphoid organ: Transport of various materials from the anal lips to the bursal lymphoid follicles with reference to its immunological importance. *Immunology* 1977, 32:499-505
21. Naukkarinen A, Arstila AU, Sorvari TE: Morphological and functional differentiation of the surface epithelium of the bursa Fabricii in chicken. *Anat Rec* 1978, 161:415-432
22. Ahlquist J, Andersson L: Methyl-green-pyronin staining: Effects of fixation; use in routine pathology. *Stain Technol* 1972, 47:17-22
23. Mowry RW: The special value of methods that color both acid and vicinal hydroxyl groups in the histochemical study of mucins: With revised directions for the colloidal iron stain, the use of alcian blue G8 and their combinations with the periodic acid-Schiff reaction. *Ann NY Acad Sci* 1963, 106:402-423
24. Olah I, Glick B: Secretory cell in the medulla of the bursa of Fabricius. *Experientia* 1978, 34:1642-1643
25. Olah I, Glick B, McCorkle F, Stinson R: Light and electron microscope structure of secretory cells in the medulla of bursal follicles, of normal and cyclophosphamide treated chickens. *Dev Comp Immunol* 1979, 3:101-115
26. Eerola E: *In vitro* culture of chicken bursal epithelium. *Cell Immunol* (In press)
27. Schaffner T, Herring J, Gerber H, Cottier H: Bursa of the Fabricius: Uptake of radioactive particles and radiotoxic "sealing" of bursal follicles, Immune Reactivity of Lymphocytes: Development, Expression and Control. Edited by M Feldman, A Globerson. New York and London, Plenum Press, 1976, pp 33-39
28. Ackerman GA, Knouff RA: Testosterone suppression of mesenchymal alkaline phosphatase activity and lymphoepithelial nodule formation in the bursa of Fabricius in the embryonic chick. *Anat Rec* 1963, 146:23-27
29. Eskola JT, Ruuskanen OJ, Fräki JE, Viljanen MK, Toivanen A: Alkaline phosphatase in the developing bursa of Fabricius: A comparative study of the cyclophosphamide-and testosterone-induced immunodeficiencies in the chick embryo. *Scand J Immunol* 1977, 6:185-194

Acknowledgments

We acknowledge gratefully the technical assistance of Mrs. Pirjo Kortevuori, Mrs. Irma Väänänen, and Mrs. Raija Pitkänen.

Figure 1—Day 1, bursa after the first colchicine application. The lymphoid follicles are necrotic (*arrows*). (H&E, ×100)

Figure 2—Detail from Figure 1. The follicle-associated epithelium (*arrow*) and the center of the follicle are necrotic. The periphery of the follicle medulla is preserved. (H&E, ×400)

Figure 3—Day 2, bursa after the second colchicine application. The necrotic centers of the follicles are demarcated and are seen as dark masses. (H&E, ×100)

Figure 4—Detail from Figure 3. No follicle-associated epithelium is seen. *P* = preserved peripheral regions of the follicular epithelium, *IFE* = pseudostratified interfollicular surface epithelium. (H&E, ×400)

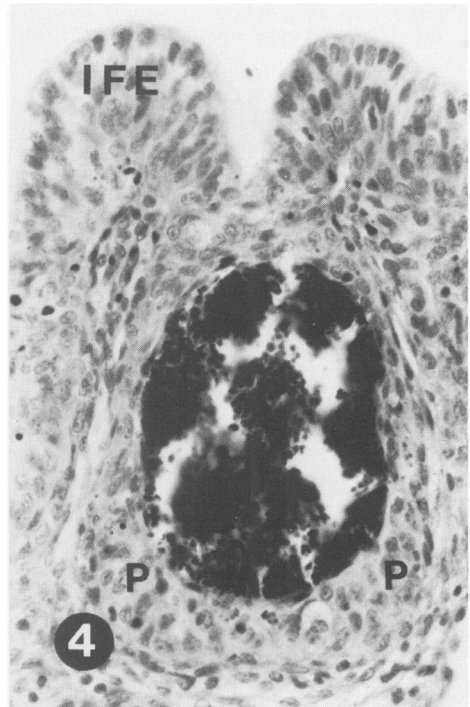
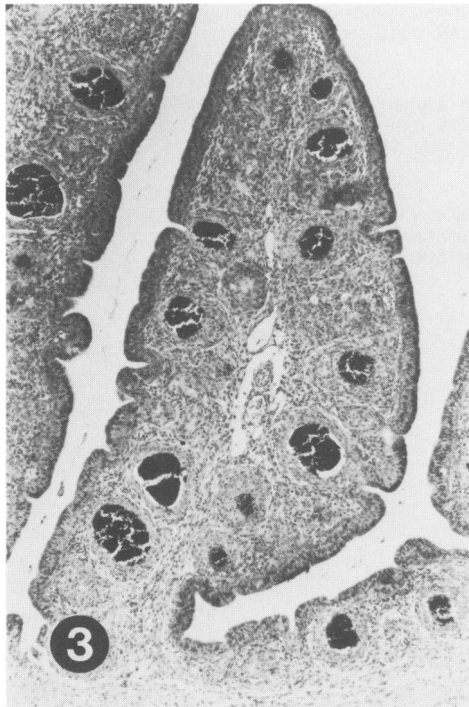
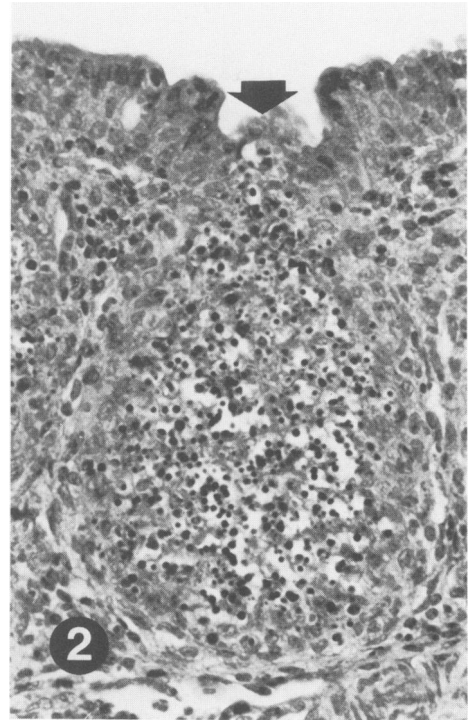
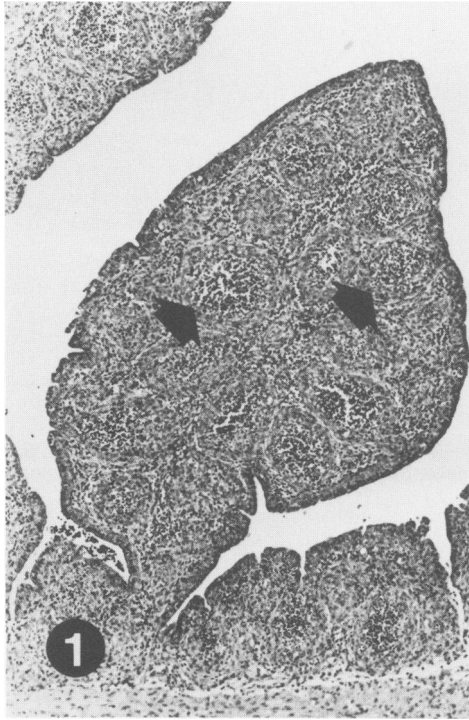

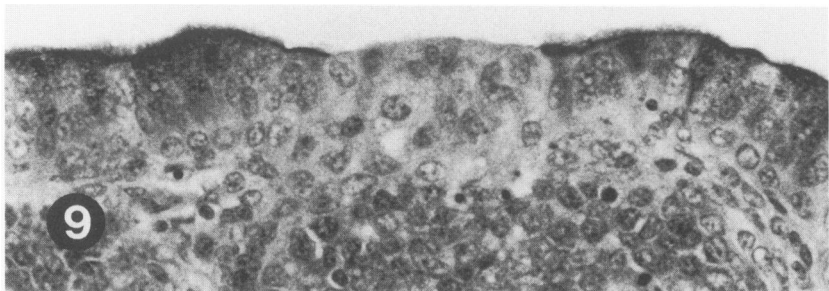
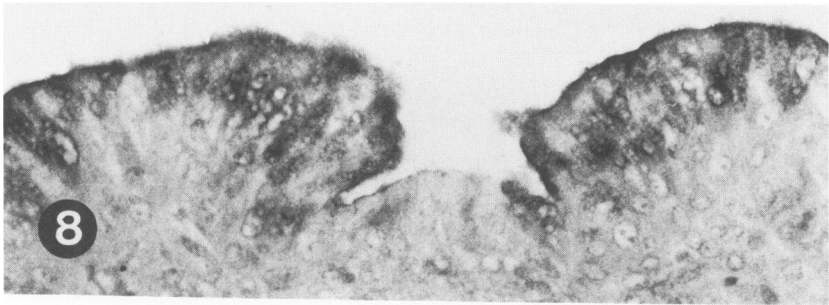
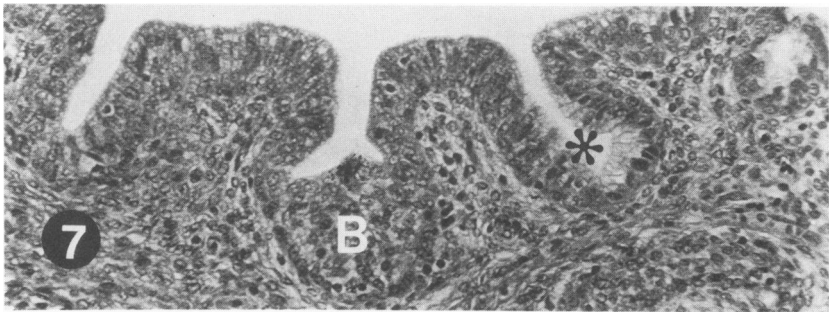
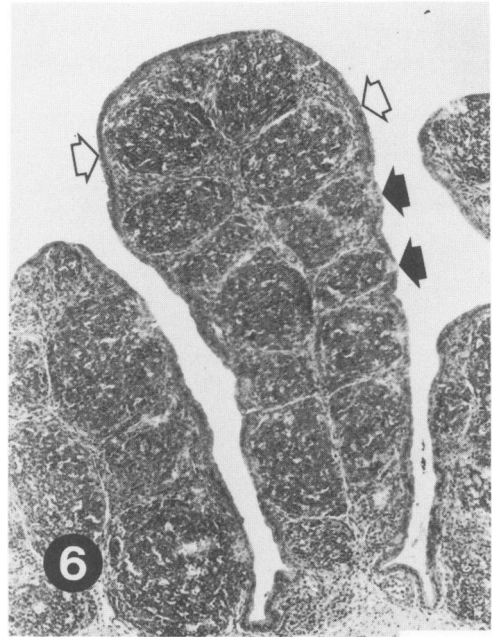
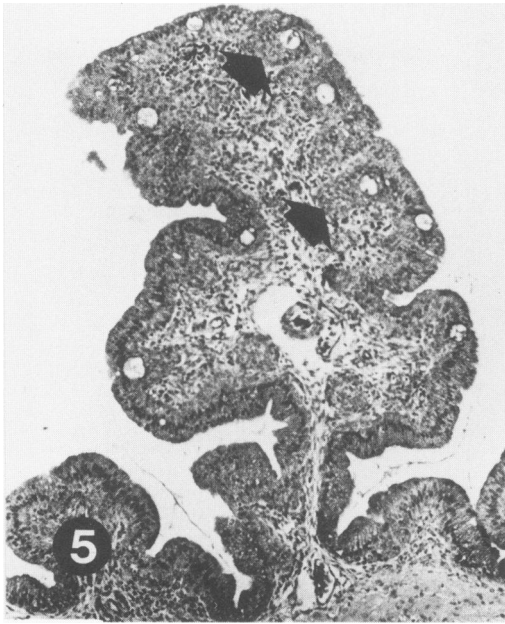
Figure 5—Day 4, bursa 1 day after the last colchicine application. Discharge of the necrotic materials into the lumen is completed. Small primitive buds are seen (*arrows*), often containing a cyst. (H&E, ×100)

Figure 6—Day 4, bursa of an untreated control chicken. Numerous lymphoid follicles in the bursal plica are seen. The follicle-associated epithelium is seen as pale-staining tufts (*closed arrows*) covering the lymphoid follicles. *Open arrows* indicate the interfollicular surface epithelium. (H&E, ×100)

Figure 7—Day 7, bursa of a chicken treated with colchicine and India ink, applied before tissue preparation. No lymphoid follicles are seen. In place of the previous follicles a crypt covered by tall columnar epithelium is often visible (*asterisk*). A small regenerated bud can be observed (*B*). On its luminal border the follicle-associated epithelium is indicated by carbon particles. Few lymphoid cells are visible in the bursal stroma. (H&E, ×250)

Figure 8—Day 7, bursa of an untreated control chicken. The apical part of the interfollicular surface epithelium stains positive for alcian blue. The follicle-associated epithelium in the middle does not contain mucosubstances and is pale. (Alcian blue and PAS, ×500)

Figure 9—Day 7, bursa of a colchicine-treated chicken. The staining pattern of the interfollicular surface epithelium, as well as the follicle-associated epithelium is similar to that of the controls (see Figure 8). (Alcian blue and PAS, × 500)



[End of Article]