

## ANIMAL MODEL OF HUMAN DISEASE

# *Chimpanzee Carriers of Hepatitis B Virus*

## *Chimpanzee Hepatitis B Carriers*

SWAN N. THUNG, MD,  
MICHAEL A. GERBER, MD,  
ROBERT H. PURCELL, MD,  
WILLIAM T. LONDON, DVM,  
KATHLEEN B. MIHALIK, MLT,  
and HANS POPPER, MD, PhD

*From the Lillian and Henry M. Stratton-Hans Popper Department of Pathology, the Mount Sinai School of Medicine of the City University of New York, New York, New York, and the Laboratory of Infectious Diseases, National Institute of Allergy and Infectious Diseases, and National Institute of Neurological and Communicative Disorders and Stroke, National Institutes of Health, Bethesda, Maryland*

HEPATITIS B virus (HBV) infection in man has a variety of manifestations. One of these, the HBV carrier, is a person with hepatitis B surface antigen (HBsAg) in the blood for at least 6 months, without clinical manifestations and no, or minor, abnormalities of laboratory tests referable to the liver.<sup>1</sup> This definition sometimes is extended to HBsAg-negative individuals with antibody to hepatitis B core antigen (HBcAg, anti-HBc), including IgM type anti-HBc in the serum<sup>2,3</sup> or HBV markers in the liver. Many carriers have HBsAg in the cytoplasm of hepatocytes, resulting in positive orcein reaction of Shikata<sup>4</sup> and ground-glass appearance.<sup>5</sup> The large number of HBsAg carriers throughout the world, approaching 200 million, represents a significant health problem.<sup>6</sup> One obvious significance of this state is the potential infectivity of HBV carriers for others.

Many questions concerning the carrier state are not resolved. These include the relative number of individuals who acquire this state by perinatal ("vertical") transmission from the mother or horizontal transmission from others in early childhood, in contrast to those who develop it following symptomatic or asymptomatic acute hepatitis later in life; the degree of persistence of viral replication; variations in the degree of infectivity; the spontaneous termination of the carrier state; the histologic manifestations, which are reported to vary from normal liver to nonspecific changes to various types of chronic hepatitis and cirrhosis; the evolution of the hepatic lesions; the risk of development of hepatocellular

carcinoma; the reason for the male predominance of chronic HBV infection; and, finally, the pathogenesis, about which contradictory reports have been published.

All three major forms of acute viral hepatitis (hepatitis A, B, and non-A/non-B) have been reproduced in chimpanzees and are associated with different histologic changes.<sup>7,8</sup> Chronic persistent hepatitis B<sup>9,10</sup> and non-A/non-B<sup>8</sup> have been described. The availability of chimpanzees with known long duration of the HBsAg carrier state, fulfilling the criteria mentioned above, prompted the description of this model.

### **Biologic Features**

The HBV carrier chimpanzees, 5 males and 4 females, varied in age from 3 to 14 years, with a mean of 8.6 years. They had been positive for HBsAg

---

Supported in part by National Institute of Environmental Health Sciences Grant 2P30 E500928 06 and AM 30689. Dr. Gerber is the recipient of a Research Career Development Award (AI 00035) from the United States Public Health Service.

Address reprint requests to S. N. Thung, MD, Department of Pathology, The Mount Sinai School of Medicine, One Gustave L. Levy Place, New York, NY 10029.

Publication sponsored by the Registry of Comparative Pathology of the Armed Forces Institute of Pathology and supported by Public Health Service Grant RR-00301 from the Division of Research Resources, National Institutes of Health, under the auspices of Universities Associated for Research and Education in Pathology, Inc.

Table 1—Morphologic and Serologic Findings in Chimpanzee Carriers of HBV and Control Chimpanzees

Chimpanzee			Minimum interval of HBsAg carriage (months)	Serum					Tissue			Inflammation	
No.	Age (years)	Sex		HBs Ag	HBe Ag	DNA polymerase	Anti-HBc	SGPT/ICD elevation	Orcein stain	HBV markers*		Lobular	Portal
										HBsAg	HBcAg		
28	12	M	45	+	+	+	+	+/+	-	+++	+++	±	+
29	9.5	F	40	+	+	+	+	-/+	+	+++	+++	+	±
39	14	F	23	+	+	+	+	-/+	++	+++	+++	-	+
40	11	M	23	+	+	±	+	+/-	-	+++	+++	-	++
56	8	M	16	+	+	+	+	+/+	+++	+++	+++	-	-
57	7.5	M	16	+	+	+	+	+/+	+++	+++	+++	+	+
800	7	F	60	+	+	+	+	+/+	-	+/+	-/-	++	+
904	5	M	22	+	+	+	+	+/+	-	++/-	-/+	±	±
A-20	3	F	15	+	+	+	+	-/-	+	+++	+++	+	++
A-19	3	M	(control)	-	-	-	-	-/-	-	-/-	-/-	±	-
A-20	1.5	F	(control)	-	-	-	-	-/-	-	-/-	-/-	±	-
A-39	2.5	F	(control)	-	-	-	-	-/-	-	-/-	-/-	±	-

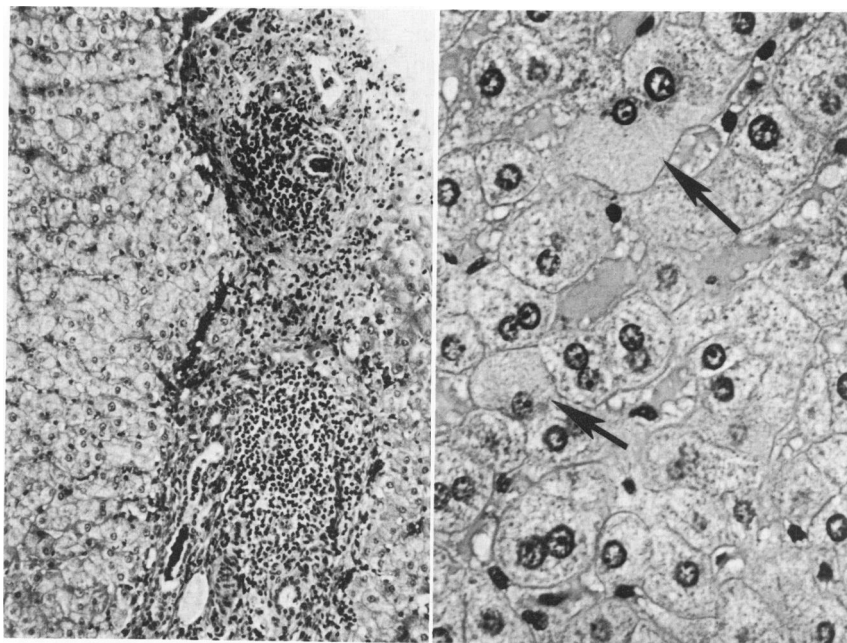
\* Immunoperoxidase/immunofluorescence: -, none; + + +, most.

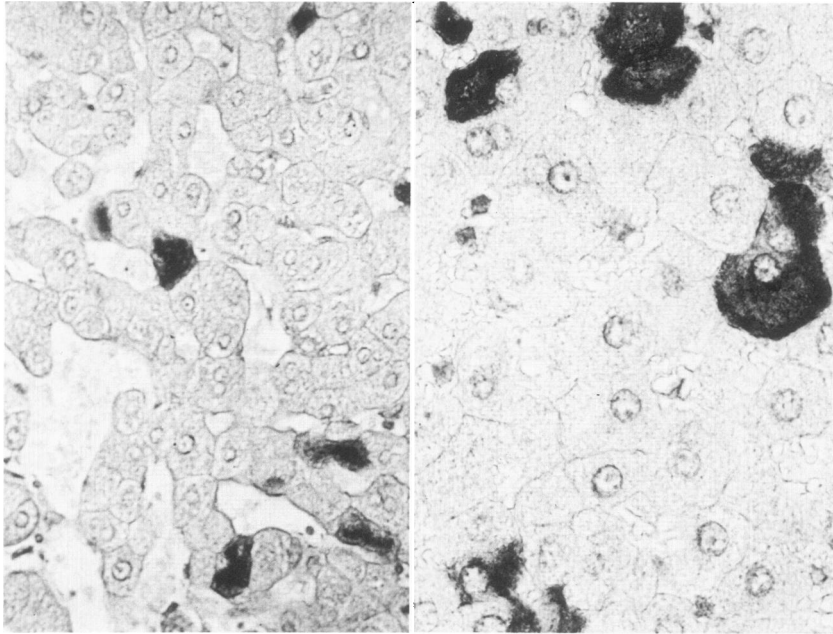
for a minimum of 15 months prior to study (average 29 months). Only one (A-20) was experimentally infected with HBV; the others were HBsAg-positive when first tested or contracted HBV from HBsAg carrier mothers. The 3 control chimpanzees, 2 females and 1 male, 1.5, 2.5, and 3 years old, showed no significant histologic changes, and all serologic studies revealed normal results. One of the control animals (A-20) subsequently became an HBsAg carrier that was included in this study. Serum alanine aminotransferase (SGPT) activity of the carrier chimpanzees was slightly elevated in all but two instances. In 3 chimpanzees, the levels were slightly

above 1.5 times the normal value, and in only 1 serum 4 times the normal value. Isocitric dehydrogenase (ICD) activities were regularly elevated. HBsAg, HBeAg, and anti-HBc were found in all carriers by radioimmunoassay. Antibody to HBeAg was found in 1 chimpanzee, and antibody to delta antigen<sup>11</sup> in 3 chimpanzees. DNA polymerase activity<sup>12</sup> was significantly elevated in 8 HBV carriers and slightly elevated in 1 (Table 1). There was no correlation between the level of DNA polymerase activity and the other findings.

Menghini needle liver biopsy specimens were available from all 9 HBV carrier chimpanzees and

**Figure 1**—Liver biopsy specimen from a chimpanzee carrier of hepatitis B virus, showing dense infiltration of portal tract by mononuclear cells, mainly lymphocytes. The limiting plate of the lobules is intact, as seen in chronic persistent hepatitis. (H&E, ×100) **Figure 2**—Liver biopsy specimen from a chimpanzee HBV carrier showing ground-glass hepatocytes containing HBsAg (arrows). (H&E, ×400)





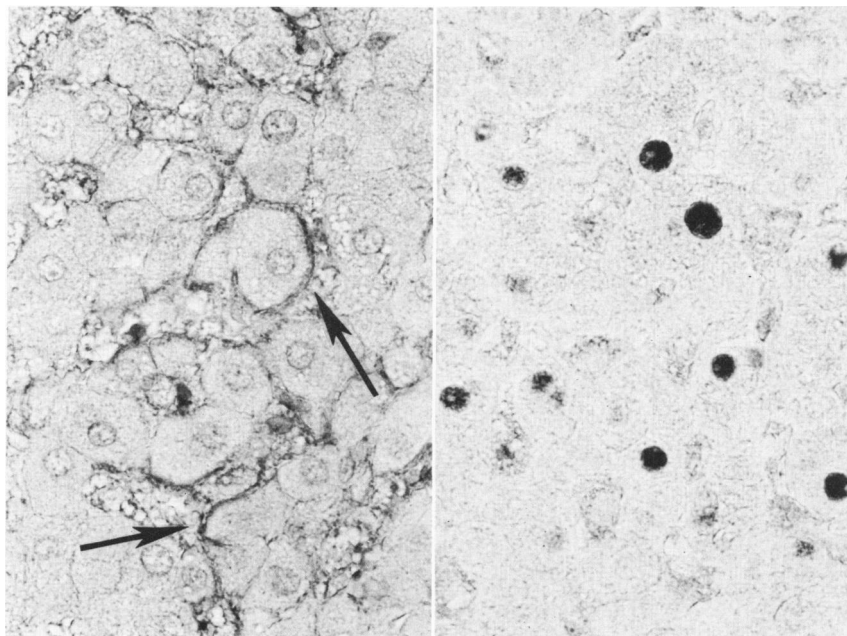
**Figure 3**—Liver biopsy specimen from a chimpanzee HBV carrier, showing orcein-positive material in the cytoplasm of scattered hepatocytes. (Shikata's orcein,  $\times 250$ ) **Figure 4**—Immunohistochemical demonstration of HBsAg in a liver biopsy specimen from a chimpanzee HBV carrier by the peroxidase-antiperoxidase technique. HBsAg is identified as dark brown reaction product in the cytoplasm of some hepatocytes. (Anti-HBs,  $\times 400$ )

were compared with 3 controls, some of the latter with multiple biopsies. Histologically, 1 HBV carrier chimpanzee had an essentially normal liver, while the rest had lobular alterations, reflected in focal necrosis and sinusoidal cell activation, significant in only 1 case. The portal tracts were infiltrated by lymphocytes and macrophages, few of them positive for the periodic acid-Schiff (PAS) reaction. The bile ducts were not altered. The inflammation extended focally into the periportal parenchyma, without significant hepatocellular necrosis. The portal tracts were not uniformly involved, and the degree of inflammation was not related to their size. In two specimens, the inflammation of the portal tracts was rather extensive and resembled chronic persistent hepatitis in man (Figure 1). There was no correlation between the intensity of lobular and portal changes. Four chimpanzees showed scattered hepatocytes with ground-glass appearance of the cytoplasm (Figure 2). The relation of ground-glass hepatocytes to HBsAg was confirmed by orcein stain (Figure 3). The number of orcein-positive cells was greater than the number of ground-glass hepatocytes in all 4 cases. In one instance, orcein-positive hepatocytes were seen without ground-glass hepatocytes. Demonstration of HBsAg in the hepatocyte cytoplasm by the peroxidase-antiperoxidase method on paraffin sections<sup>13</sup> corresponded to the positive results by orcein staining. However, immunoperoxidase staining for HBsAg was more sensitive than the orcein stain, since the former demonstrated more positive cells than the latter (Figure 4). In addition, the presence of cytoplas-

mic HBsAg was detected by immunohistochemical reaction in hepatocytes of the 4 HBV carrier chimpanzees with negative orcein reaction. Moreover, the presence of HBsAg along the plasma membrane was demonstrated by immunoperoxidase staining in 8 HBV carriers (Figure 5), but not by orcein stain. There were fewer cells with membranous expression of HBsAg than with cytoplasmic HBsAg by immunoperoxidase staining. Immunofluorescence studies were carried out on frozen liver tissue from all 9 carrier chimpanzees and revealed HBsAg (along the hepatocellular membrane) in 8 of these. HBcAg was found by immunofluorescence in the hepatocyte nuclei of eight of the nine carrier chimpanzees, but by immunoperoxidase staining in only 3 (Figure 6). There was no discernible quantitative relationship between expression of HBcAg and expression of HBsAg. Furthermore, there was no correlation between the pattern of HBV markers in the liver and the histologic type of liver disease.

In summary, the 9 HBV carrier chimpanzees (in contrast to the controls) revealed a spectrum of histologic findings ranging from normal liver to features of human chronic persistent hepatitis. Comparison of the techniques for demonstration of intrahepatic HBV markers indicated greater sensitivity of immunoperoxidase staining for HBsAg in paraffin sections over immunofluorescence on frozen sections and orcein staining of paraffin sections. In contrast, immunofluorescence was far more sensitive than the immunoperoxidase technique for the detection of HBcAg.

**Figure 5**—Immunohistochemical identification of HBsAg in a liver biopsy specimen from a chimpanzee HBV carrier by the peroxidase-antiperoxidase technique. HBsAg is expressed along the plasma membrane of hepatocytes as brown reaction product (arrows). (Anti-HBs,  $\times 400$ ) **Figure 6**—Immunohistochemical identification of HBcAg in a liver biopsy specimen from a chimpanzee HBV carrier by the peroxidase-antiperoxidase technique. HBcAg is seen as dark brown reaction product in the nuclei of hepatocytes (Anti-HBc,  $\times 400$ )



### Comparison With Human Disease

In this limited sample, HBV carrier chimpanzees, in contrast to man, showed no male predominance<sup>14</sup> and were characterized by persistent viral replication, as indicated by HBeAg and DNA polymerase activity in the serum.<sup>15</sup> There was no correlation between the biochemical abnormalities and the histologic findings, which ranged from normal liver to chronic persistent hepatitis. In these aspects, the animal model corresponds well with the disease in human carriers. Orcein-positive ground-glass hepatocytes represent a characteristic finding in human carriers and are described here in chimpanzees. Both in human and chimpanzee carriers, abundant HBsAg is present in the hepatocyte cytoplasm, but membranous expression of HBsAg and intranuclear HBcAg is not commonly seen in healthy human carriers.<sup>16</sup> Similar to most, but not all, human carriers, the hepatocyte nuclei in the carrier chimpanzees showed no significant histologic variations. Progression to chronic active hepatitis has not been noted to date in carrier chimpanzees.

### Usefulness of the Model

The availability of HBV carrier chimpanzees may facilitate studies of the role of various parameters, particularly immunologic factors, in the development of the carrier state. The pathogenesis of chronic viral hepatitis may be explored under well-defined circumstances. Long-term observations of the natural history of the carrier state and evolution of chronic viral

liver disease, perhaps including cirrhosis and hepatocellular carcinoma, may be carried out. The effect of environmental agents such as alcohol and other hepatotoxins on the chronically infected liver may be studied. Therapeutic trials may be undertaken with the goal of terminating the carrier state or preventing progressive liver disease. Some of these uses of the chimpanzee model have already been explored; others are currently being examined.

### References

1. Simon JB, Patel SK: Liver disease in asymptomatic carriers of hepatitis B antigen. *Gastroenterology* 1974, 66:1020-1028
2. Gerlich WH, Luer W, Thomssen R: Diagnosis of acute and inapparent hepatitis B virus infections by measurement of IgM antibody to hepatitis B core antigen. *J Infect Dis* 1980, 142:95-101
3. Deinhardt F: Predictive value of markers of hepatitis virus infection. *J Infect Dis* 1980, 141:299-305
4. Shikata T, Uzawa T, Yoshiwara N, Akatsuka T, Yamazaki S: Staining methods of Australia antigen in paraffin section. *Jpn J Exp Med* 1974, 44:25-36
5. Hadziyannis S, Gerber MA, Vissoulis C, Popper H: Cytoplasmic hepatitis B antigen in "ground glass" hepatocytes of carriers. *Arch Pathol* 1973, 96:327-330
6. Sobelavsky O: HBV as a global problem, *Viral Hepatitis*. Edited by GN Vyas, SN Cohen, R Schmid. Philadelphia, The Franklin Institute Press, 1978, pp 347-356
7. Dienstag JL, Popper H: The pathology of viral hepatitis types A and B in chimpanzees. *Am J Pathol* 1976, 85:131-148
8. Popper H, Dienstag JL, Feinstone SM, Alter HJ, Purcell RH: The pathology of viral hepatitis in chimpanzees. *Virchows Arch [Pathol Anat]* 1980, 387:91-106

9. Shikata T, Karasawa T, Abe K: Two distinct types of hepatitis in experimental hepatitis B virus infection. *Am J Pathol* 1980, 99:353-368
10. Shouval D, Chakraborty PR, Ruiz-Opazo N, Baum S, Spigland I, Muchmore E, Gerber MA, Thung SN, Popper H, Schafritz D: Chronic hepatitis in chimpanzee carriers of hepatitis B virus: Morphologic, immunologic and viral DNA studies. *Proc Natl Acad Sci USA* 1980, 77:6147-6151
11. Rizzetto M, Hoyer B, Canese MG, Shih JWK, Purcell RH, Gerin JL: Delta agent: Association of delta antigen with hepatitis B surface antigen and RNA in serum of delta-infected chimpanzees. *Proc Natl Acad Sci USA* 1980, 77:6124-6128
12. Kaplan PM, Greenman RL, Gerin JL, Purcell RH, Robinson WS: DNA polymerase associated with human hepatitis B antigen. *J Virol* 1973, 12:995-1005
13. Thung SN, Gerber MA, Sarno E, Popper H: Distribution of five antigens in hepatocellular carcinoma. *Lab Invest* 1979, 41:101-105
14. Blumberg BS: Sex differences in response to hepatitis B virus. *Arthritis Rheum* 1979, 22:1261-1266
15. De Francis R, D'Arminio A, Vecchi M, Ronchi G, Del Ninno E, Parravicini A, Ferroni P, Zanetti AR: Chronic asymptomatic HBsAg carriers: Histologic abnormalities and diagnostic and prognostic value of serologic markers of the HBV. *Gastroenterology* 1980, 79:521-527
16. Gerber MA, Thung SN: The localization of hepatitis viruses in tissues. *Int Rev Exp Pathol* 1979, 20:49-76