

# Radiation-Induced Cardiomyopathy

## *I. An Electron Microscopic Study of Cardiac Muscle Cells*

M. Yusuf Khan, MD

This investigation demonstrates sequential ultrastructural lesions of cardiac myocytes in rabbits exposed locally to a single dose (1008 and 1300 rads) of x-irradiation. A wide spectrum of lesions were observed as early as 24 hours postirradiation and were followed for as long as 4 months after x-irradiation. Myofibrillar degeneration and dissociation of intercalated discs seen at 24 and 48 hours postirradiation were followed by gradual progression of myofibrilolysis and myofiber degeneration to myofiber atrophy, myofiber collapse and eventual progressive pericellular interstitial myocardial fibrosis. The possible role of dissociation of intercalated discs in the pathogenesis of well-known postirradiation electrocardiographic changes is suggested. Myofibrillar degeneration appears to be the characteristic (although non-specific) lesion of radiation having a multifactorial etiology: direct radiation effect, vascular compromise and endogenous (cardiac) catecholamine liberation (*Am J Pathol* 73:131-146, 1973).

EFFECTS OF RADIATION on the heart have been well documented at the light microscopic level, both in humans subjected to therapeutic irradiation of malignancies adjacent to the heart (such as carcinoma of breast, esophagus and mediastinal lymphoma<sup>1-5</sup>) and in different species of experimental animals.<sup>6-10</sup> The ultrastructural study of the myocardium of a patient dying of heart disease following therapeutic x-irradiation for carcinoma of the thyroid has also been reported.<sup>11</sup> Besides these morphologic changes, electrocardiographic alterations and hemodynamic disturbances from x-irradiation are also well known.<sup>12-15</sup> The pathogenesis of these changes has, however, remained speculative, and the reported doses of x-irradiation claimed to be effective have been variable and contradictory. Part of the contradiction in experimental studies may lie in the variable modalities of radiation and the animal species used.<sup>6,7,15</sup>

---

From the Department of Pathology, College of Medicine and Dentistry of New Jersey, New Jersey Medical School, Newark, NJ.

Supported by Grant GR 70-20 from the New Jersey Heart Association, Institutional Grant IN-92A from the American Cancer Society and by Institutional General Research Support Grant GR 5 S 01-RR05393-11 from the National Institutes of Health.

Abstract presented at the Nineteenth Annual Meeting of the Radiation Research Society, Boston, Mass., May 1971.

Accepted for publication June 5, 1973.

Address reprint requests to Dr. M. Yusuf Khan, Department of Pathology, New Jersey Medical School, 100 Bergen St, Newark, NJ 07103.

Traditionally, the sensitivity of the heart to radiation has been regarded as very low. More recently, however, Fajardo and Stewart<sup>6</sup> have demonstrated lesions in rabbit myocardium following 2000 rads of x-irradiation. No systematic ultrastructural study of radiation-induced myocardial changes in experimental animals has been reported to date. This time-sequence, ultrastructural study was undertaken to explore the pathogenesis of radiation-induced cardiomyopathy and the nature of cardiac tissue reactions and the relative sensitivity of its various tissue components to small doses of x-irradiation. This report concerns the lesions of myocardial cells.

### Materials and Methods

Forty male New Zealand white rabbits weighing 1.5 to 2 kg were placed under intravenous pentobarbital sodium (Nembutal®) anesthesia (30 mg/kg) and were subjected to a single cardiac dose of 1008 (10 animals) and 1300 rads (30 animals) of x-irradiation, calculated at a depth of 1.5 cm from the surface of the skin. Using a precordial approach, radiation was delivered from a source of 250 keV (MA 15, HVL 2.2 cu mm, TSD 15 cm, air dose 66 rad/min) through an x-ray cone 4 × 5 cm. Before irradiation, cardiac localization was verified by a chest x-ray, and precordial skin was either shaved or depilated with depilatory paste, Nair (Carter Products). An additional 12 animals subjected to sham irradiation procedure served as controls. Animals were housed in air conditioned facilities and served usual laboratory food and water *ad libitum*.

Following irradiation, animals were selected at random in batches of 3 or 4 along with a control. Under intravenous pentobarbital sodium anesthesia, they were killed at 24 hours, 48 hours, 72 hours, 7 days and at predetermined weekly or biweekly intervals thereafter for 4 months. The thoracic cavity was opened by splitting the sternum, and the pericardial cavity was incised. A block of muscle approximately 3 mm thick was quickly excised from the left ventricular wall and minced with a razor blade into approximately 1 mm cubes and placed in ice cold 2.5% phosphate-buffered glutaraldehyde at 4 C for 2 hours. The sampling site was kept constant in all the animals.

Glutaraldehyde-fixed tissue was washed thoroughly in 1 M phosphate buffer (pH 7.3) and postfixed in 1% phosphate-buffered osmium tetroxide for 1 hour at 4 C. Tissue was dehydrated and embedded in Epon 812 according to Luft's method.<sup>17</sup> One micron thick sections were cut with a glass knife on an LKB ultramicrotome III and stained with toluidine blue. Thin sections, cut with a diamond knife and supported on 250 mesh copper grids, were stained with uranyl acetate followed by lead citrate stains.<sup>18</sup> Sections were examined and photographed in RCA EMU-3 electron microscope.

### Results

Ultrastructural changes in cardiac muscle cells were present as early as 24 hours postirradiation. A continuing and overlapping spectrum of lesions was seen over different observation periods. For convenience, the description of the lesions will be arbitrarily discussed under broad periods of observation and special mention made of lesions considered significant from a sequential point of view. One of the 40 x-irradiated

animals was excluded from this study because, on light microscopic examination, it fulfilled the criteria of Fajardo and Stewart<sup>6</sup> for idiopathic Millers' myocarditis. No significant difference was observed between the lesions in animals receiving 1008 rads and those receiving 1300 rads of x-irradiation.

At 24 hours following irradiation the myocardial cells showed prominent and frequent contraction bands, disruption of intercalated discs, myofibrillar disorganization with myofibrillolysis and presence of lipid bodies. Z-lines and mitochondria were relatively well preserved (Figure 1).

At 48 hours postirradiation, myofibrillar degeneration was much more advanced, with loss of whole sarcomeres in groups of myofibrils. Z-bands within many of these areas were relatively intact, with double membranous structure and focal areas of increased electron density, while other myofibers showed marked mitochondrial alteration and partial loss of cristae, with total Z-band destruction (Figures 2 and 3). Many other relatively intact fibers showed disruption and dissociation of the intercalated discs (Figure 4).

By day 8 postirradiation, additional degenerative changes were evident, which were characterized by architectural disorganization of myofibrils, focal cytoplasmic degeneration and subplasmalemmal vacuolation with many myelin-like figures and electron-dense granular debris, within the injured myofibers (Figure 5).

By day 22 postirradiation, myofibrillolysis had become less and less prominent, but other degenerative changes persisted. Many fibers showed thicker Z-lines, dilated sarcoplasmic reticulum and mineralization of mitochondria (Figure 6). Fine pericellular fibrosis was noted for the first time on day 22.

By day 49 postirradiation, many muscle fibers were collapsed, with complete disorganization of myofibrils and collapse of intercalated discs. The sarcolemmal membrane, however, remained intact. Mitochondria in these fibers tended to be small with indistinct cristal architecture (Figure 7). Other relatively intact fibers showed dilated sarcoplasmic reticulum and many small mitochondria. Still many other fibers showed varying degrees of atrophy, some with marked reduction in the number of myofibrils and the presence of many membranous tubular and vesicular structures within their central core. These atrophic fibers were surrounded by undifferentiated proliferating mesenchymal cells and increased collagen fibrils, and some of these also showed inclusions of prominent myelin-like figures (Figures 8-10).

By 4 months following x-irradiation there was a progressive and marked increase in interstitial fibrosis surrounding individual and groups of myofibers. Many of the muscle fibers exhibited varying degrees of degenerative changes in myofibrils, with many myelin-like figures and small dense mitochondria (Figures 11 and 12).

### Discussion

The present investigation has demonstrated a spectrum of ultrastructural lesions of myocardial cells from a relatively small dose of x-irradiation. Lesions seen as early as 24 hours and followed up to 4 months following irradiation showed an overlapping continuum with relentless progression to myocardial fibrosis. Thus, in contrast to light microscopic studies of Fajardo and Stewart,<sup>6</sup> there was no "latent phase" free of lesions. Understandably, without the aid of electron microscopy, many of these changes could not have been observed. Even in our retrospective study, it was difficult to positively identify many of these lesions by light microscopy; if recognized, they were difficult to differentiate from artifacts. This, however, does not in any way reflect on the latency phase with respect to reported electrocardiographic disturbances following radiation.<sup>12,13</sup>

Pathogenesis of radiation-induced cardiomyopathy has remained speculative and controversial. Various factors have been implicated: a) direct effect of radiation on muscle cell possibly through degradation of DNA and disturbance of RNA transcription;<sup>19-21</sup> b) vascular compromise;<sup>22-24</sup> c) interstitial cell damage;<sup>22-25</sup> d) neural damage (David and Gabriel as quoted by Warren).<sup>10</sup>

In the earlier phases of injury following x-irradiation, myofibrillar degeneration (characterized by contraction bands and myofibrillar disorganization with myofibrillolysis) and dissociation of intercalated discs were the most prominent and significant findings. Burch *et al*<sup>11</sup> also described myofibrillolysis as a late effect of x-irradiation. That myofibrillolysis does occur is also supported by the observations of Caster *et al*,<sup>21</sup> who demonstrated a 20% loss of actinomyosin in rat heart 10 days after radiation. Myofibrillar degeneration may result from direct radiation injury and altered membrane permeability affecting intracellular concentration of potassium,<sup>26,27</sup> or it may be secondary to microvascular compromise or release of endogenous catecholamines from adrenergic nerve endings of myocardium.<sup>28,29</sup> Our own observations have shown marked associated changes in microvasculature and interstitial tissue, including degranulation and degeneration of adrenergic nerve endings.<sup>30</sup> Sottocasa *et al*<sup>31</sup> have

shown an increase in lysosomal enzymes in heart muscle slices irradiated *in vitro*, and Bacq and Alexander<sup>32</sup> have shown increased enzyme levels following irradiation. One can only speculate about the occurrence of *in vivo* lysosomal enzyme induction and its role in the myofibrillar degeneration, if any. It is more likely that radiation-induced myofibrillar degeneration is a much more complex phenomena resulting from a combination of some or all of these factors. Myofibrillar degeneration has more recently been shown to be a significant and common reaction pattern of myocardium to various types of insults such as hypoxia, hypokalemia and exogenous administration of catecholamines.<sup>28</sup> Although some investigators<sup>33</sup> have not shown any dynamic alteration in catecholamine stores of myocardium following x-irradiation, our preliminary ultrastructural observations show marked degenerative changes in adrenergic nerve endings (work in progress). Therefore, we believe that endogenous catecholamines may be playing some part in myofibrillar degeneration. The ultimate fate of myofibers showing myofibrillolysis is not clear. In view of our lack of evidence regarding the cardiac muscle regeneration, it is conceivable that it may lead to atrophy, collapse and, finally, complete loss of muscle cells. At present there is no evidence that there is any kind of reconstitution of myofibrils by synthesis of new myofilaments.

The structure of the intercalated disc is well known, but its physiologic significance is still a matter of controversy.<sup>34,35</sup> Barr *et al*<sup>36</sup> have suggested that the nexus or tight junction of the disc is the site of propagation of the excitation impulse. In the present study, the dissociation of intercalated discs observed following x-irradiation could have resulted from vigorous contraction of muscle fiber or direct radiation injury. Acute and late electrocardiographic disturbances following x-irradiation in experimental animals<sup>12,14,15</sup> and humans<sup>13</sup> are well documented. The role that the dissociation or rupture of intercalated discs may play in the causation of these acute electrocardiographic changes following irradiation needs further elucidation. Dissociation of intercalated discs has also been described in many other pathologic states of animals and humans,<sup>34,35</sup> but again its pathophysiologic significance is not clear.

Atrophy and collapse of myocardial fibers may result from myofibrillolysis, disruption of intercalated discs or radiation-induced biochemical injury and resultant metabolic deprivation of the cell.<sup>37</sup> We are presently pursuing the nature and extent of biochemical injury to the myocardium following irradiation, and our preliminary results do indicate some disturbance of carbohydrate metabolism.

Interstitial myocardial fibrosis represents the end result of radiation-induced myocardial damage and our observations suggest that it results from stromal collapse and increased mesenchymal cell activity. The onset of mesenchymal cell activity is somewhat delayed following radiation, in comparison to muscle cell and microvascular changes.<sup>30</sup> Myocardial fibrosis characteristically tends to encompass individual myocardial cells and groups of myocardial cells and correlates well with our own light microscopic observations and those of others.<sup>6</sup>

In conclusion, this sequential ultrastructural study of cardiac myocytes in radiation-induced cardiomyopathy demonstrates a spectrum of lesions, many of which have thus far eluded investigators working at the light microscopic level. The most significant lesions included dissociation of intercalated discs and myofibrillar degeneration, followed by myofiber atrophy, myofiber collapse and eventual interstitial pericellular fibrosis.

### References

1. Cohn K, Stewart JR, Fajardo LF, Hancock EW: Heart disease following radiation. *Medicine (Baltimore)* 46:281-298, 1967
2. Rubin E, Camara J, Grayzel DM, Zak FG: Radiation-induced cardiac fibrosis. *Am J Med* 34:71-75, 1963
3. Catterall M, Evans W: Myocardial injury from the therapeutic irradiation. *Br Heart J* 22:168-174, 1960
4. Dollinger MR, Lavine DM, Foye LV: Myocardial infarction due to post-irradiation fibrosis of the coronary arteries. *JAMA* 195:316-319, 1966
5. Efskin D: The Effect of Massive x-Ray Doses to the Mediastinum, Especially the Heart. Oslo, Norsk Hydro's Institute for Cancer Research, 1954-1956, pp 13-14
6. Fajardo LF, Stewart JR: Experimental radiation-induced heart disease. I. Light microscopic study. *Am J Pathol* 59:299-315, 1970
7. Phillips SJ, Macken DL, Rugh R: Pathologic sequelae of acute cardiac irradiation in monkeys. *Am Heart J* 81:528-542, 1971
8. Senderoff E, Kaneko M, Beck AR, Baronofsky ID: Effects of irradiation on normal canine heart. *Am J Roentgenol Radium Ther Nucl Med* 86:740-751, 1961
9. Warthin AS, Pohle EA: The effects of roentgen rays on the heart. III. The tolerance dose for the myocardium of rats. *Am J Roentgenol* 25:635, 1931
10. Warren S: Effects of radiation on normal tissues. VI. Effects of radiation on the cardiovascular system. *Arch Pathol* 34:1070-1079, 1942
11. Burch GE, Sohal RS, Sun SC, Miller GC, Colcolough HL: Effects of radiation on the human heart: an electron microscopic study. *Arch Int Med* 121:230-234, 1968
12. Takaoka A: Electrocardiographic study of cardiac damage following irradiation of canine hearts. *Radiol Clin Biol* 38:182-196, 1969
13. Takaoka A, Kaneda H, Urano M, Kikkawa S: An electrocardiographic

- study of cardiac damage secondary to radiotherapy of malignant intrathoracic tumors. *Radiol Clin Biol* 37:1-12, 1968
14. Badran AM, El-Naggar AM, Mahmoud KA: Electrocardiographic changes following x-irradiation of the canine heart. *Am Heart J* 79:648-652, 1970
  15. Jones A, Wedgwood T: Effects of radiation on the heart. *Br J Radiol* 33:138-158, 1960
  16. Bishop VS, Stone HL, Yates J, Simek J, Davis JA: Effects of external irradiation of the heart on cardiac output, venous pressure and arterial pressure. *J Nucl Med* 6:645-650, 1965
  17. Luft TH: Improvement in epoxy resin embedding methods. *J Biophys Biochem Cytol* 9:409-414, 1961
  18. Reynolds E: The use of lead citrate at high pH as an electron-opaque stain in electronmicroscopy. *J Cell Biol* 17:208-212, 1963
  19. Pollard EC: The biological action of ionizing radiation. *Am Scientist* 57, 2:206-236, 1969
  20. Kosmider S, Szczurek Z, Petelenz T: The pathomorphology of the heart muscle in experimental radiation disease in rabbits. *Arch Immunol Ther Exp* 10:416, 1962
  21. Caster WO, Armstrong WD, Simonson E: Changes in the cardiovascular system following total body x-irradiation. *Am J Physiol* 188:169-177, 1957
  22. Rhoades RP: The vascular system, *Histopathology of Irradiation from External and Internal Sources*. Edited by W Bloom. New York, McGraw-Hill Book Co., 1948
  23. Shtern LS, Rapoport CL, Gromakovakiaia MM, Zubkova SR: Effect of x-rays on the permeabilities of blood-organ barriers. *Biophysics* 2:188, 1957
  24. Khan MY, Ohanian M: Ultrastructural study of radiation induced cardiac vasculopathy. *Circulation (Suppl 2)* 44:377, 1971
  25. DeBoer WGRM: Experimentele en therapeutische Roentgenbestraling als oorzaak van arteriele en cardiale beschadiging. Doctoral dissertation, University of Groningen, Groningen, The Netherlands, 1963
  26. Dowben RM, Zuckerman L: Alteration in skeletal muscle after x-irradiation and their similarity to changes in muscular dystrophy. *Nature* 197:400-401, 1963
  27. Emberson JW, Muir AR: Changes in the ultrastructure of rat myocardium induced by hypokalemia. *Q J Exp Physiol* 54:36-40, 1969
  28. Reichenbach DD, Benditt EP: The pathogenesis and potential importance of myofibrillar degeneration. *Human Pathol* 1:125-150, 1970
  29. Bloom S, Cancilla PA: Myocytolysis and mitochondrial calcification in rat myocardium after low doses of isoproterenol. *Am J Pathol* 54:373-392, 1969
  30. Khan MY: Radiation-induced cardiomyopathy in rabbits: an ultrastructural study. *Radiat Res* 47:268-269, 1971
  31. Sottocasa GL, Glass G, Benard B: The effects of x-irradiation on the activities of some lysosomal hydrolases of heart tissue. *Radiat Res* 24:32-42, 1965
  32. Bacq AM, Alexander P: *Fundamentals of Radiobiology*. New York, Pergamon Press, Inc, 1961
  33. Cession-Fossion A, Beaumariage ML: Teneuren catecholamines du myocarde et des glandes surrenales du rat apres irradiation aux rayons x. *Int J Radiat Biol* 10:277-282, 1965

34. Burch GE, Sohal RS: Morphologic and pathologic aspects of intercalated disc of the heart. *Am Heart J* 78:358-368, 1969
35. Kawamura K, Konishi T: Ultrastructure of the cell junction of the heart muscle with special reference to its functional significance in excitation conduction and to the concept of "disease of intercalated disc." *Jap Circ J* 31:1533-1543, 1967
36. Barr L, Dewey MM, Berger W: Propagation of action potentials and the structure of the nexus in cardiac muscle. *J Gen Physiol* 48:797-823, 1965
37. Kelly LS: Radiosensitivity of biochemical processes, *Fundamental Aspects of Radiosensitivity*. Upton, NY, Biology Department, Brookhaven National Laboratory, p 32, 1961 (Publication No. 14)

### **Acknowledgments**

The author gratefully acknowledges the use of the electron microscope of the Department of Pathology, St. Vincent's Hospital, New York, NY, and wishes to thank Dr. A. Madrazo for his help, Dr. A. H. Wazir and Miss G. Mackenzie for irradiating the animals and Dr. Hugh G. Grady for his help and encouragement, without which this work would not have been possible.



*[Illustrations follow]*

### Legends for Figures

**Fig 1**—Myocardium 24 hours postirradiation (1300 rads). Myofiber shows marked architectural disorganization, with myofibrillolysis (*FL*), relatively intact Z-band and (*Z*) and mitochondria (*M*), lipid bodies (*L*), contraction band (*CB*) and dissociated intercalated disc (*arrow*) (Uranyl acetate–lead citrate,  $\times 12,000$ ).

**Fig 2**—Myocardium 48 hours postirradiation (1300 rads). Injured myofiber showing extensive myofibrillolysis (*FL*) involving full sarcomere length (*S*). Intact Z-band (*Z*) shows double membrane structure and at places condensation of Z-band material (*arrow*). Lipid body (*L*) and intact mitochondria (*M*) are also seen (Uranyl acetate–lead citrate,  $\times 18,500$ ).

**Fig 3**—Myocardium 48 hours postirradiation (1008 rads). Myofiber showing myofibrillolysis (*FL*) with fine, electron-dense granular material and vacuolated mitochondria (*arrows*). Nucleus (*N*) of an endothelial cell and RBC (*R*) are seen (Uranyl acetate–lead citrate,  $\times 21,000$ ).

**Fig 4**—Myocardium 48 hours postirradiation (1300 rads). A myofiber with an intact segment (*ICD*) of an intercalated disc and a completely disrupted segment (*arrows*) is seen. Note also normal appearing mitochondria (*M*) and Z-band (*Z*) (Uranyl acetate–lead citrate,  $\times 19,000$ ).

**Fig 5**—Myocardium 8 days postirradiation (1300 rads). An area of focal cytoplasmic degeneration containing membranous profiles and dense granular material (*FCD*) is seen within a myofiber. Note also many contraction bands (*CB*) and subsarcolemmal myofibrillolysis (*FL*) with many myelin-like figures and electron-dense granular debris (Uranyl acetate–lead citrate,  $\times 14,500$ ).

**Fig 6**—Myocardium 14 days postirradiation (1300 rads). Myocyte with focal myofibrillar degenerative changes, thick and dense Z-bands, dilated sarcoplasmic reticulum (*SR*) and mineralized mitochondria (*arrows*) is seen (Uranyl acetate–lead citrate,  $\times 15,000$ ).

**Fig 7**—Myocardium 48 days postirradiation (1300 rads). Note a collapsed myofiber (*MC2*) with disorganized contractile elements (*MF*) and convoluted, crumpled intercalated disc (*arrow*) but intact sarcolemma. Mitochondria (*M*) show indistinct cristae. Also note part of an adjacent myofiber (*MC1*) showing normal structure (Uranyl acetate–lead citrate,  $\times 16,200$ ).

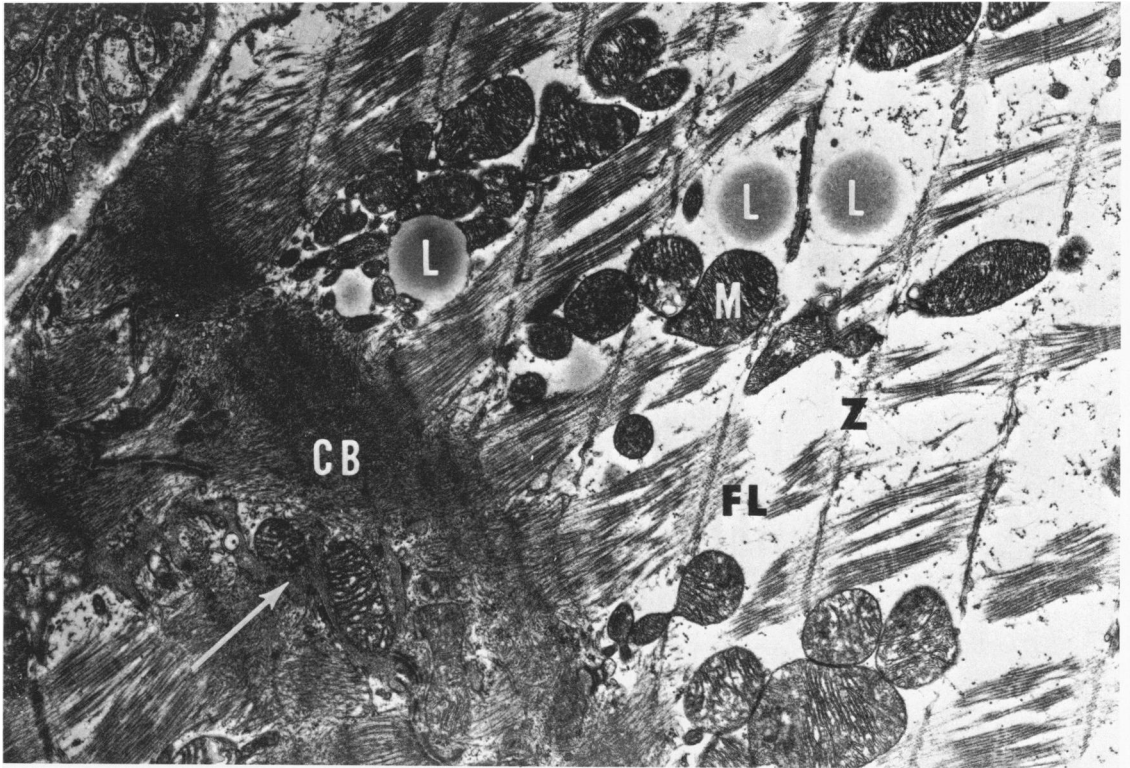
**Fig 8**—Myocardium 43 days postirradiation (1300 rads). Note an intact myofiber (*F1*) with attenuated myofibrils (*arrows*), dilated sarcoplasmic reticulum (*X*) and a markedly atrophic myofiber (*F2*) with complete loss of architecture. Z-line can still be made out within the atrophic myofiber (*arrow head*). Note also many mesenchymal cells with collagen (*CL*) fibrils surrounding the atrophic myofiber (Uranyl acetate–lead citrate,  $\times 8000$ ).

**Fig 9**—Myocardium 43 days postirradiation. Higher magnification of another atrophic myofiber (*MC*) and an undifferentiated mesenchymal cell with nucleus (*N*). Atrophic myofiber shows peripherally arranged attenuated myofibrils with thick Z-bands (*arrows*) but indistinct H-band. Central core of the fiber contains small mitochondria and many membranous vesicular and tubular profiles (*star*) (Uranyl acetate–lead citrate,  $\times 30,000$ ).


**Fig 10**—Myocardium 44 days postirradiation (1300 rads). An atrophic muscle fiber with loss of myofibrillar architecture and loss of mitochondria. Note large number of whorled myelin-like figures (*X*) and altered Z-lines. Relatively intact adjacent myofiber shows mitochondrial alteration (Uranyl acetate–lead citrate,  $\times 24,500$ ).

**Fig 11**—Myocardium 3 months postirradiation (1300 rads). Myofibers show marked degenerative changes, with loss of myofibrils (*FL*), altered mitochondria (*M*), dense bodies (*arrow*) and membrane-bound vesicles (*V*). A broad band (*CL*) of structureless myofibers (Uranyl acetate–lead citrate,  $\times 19,000$ ).

**Fig 12**—Myocardium 3½ months postirradiation (1300 rads). Three muscle fibers with densely collagenous pericellular fibrosis (*CL*) with degenerated and fragmented nuclei (*N1* and *N2*). Muscle fibers show varying degrees of myofibrillar degeneration with small dense mitochondria (*M*). One fiber contains many myelin-like figures (*X*) (Uranyl acetate–lead citrate,  $\times 19,000$ ).

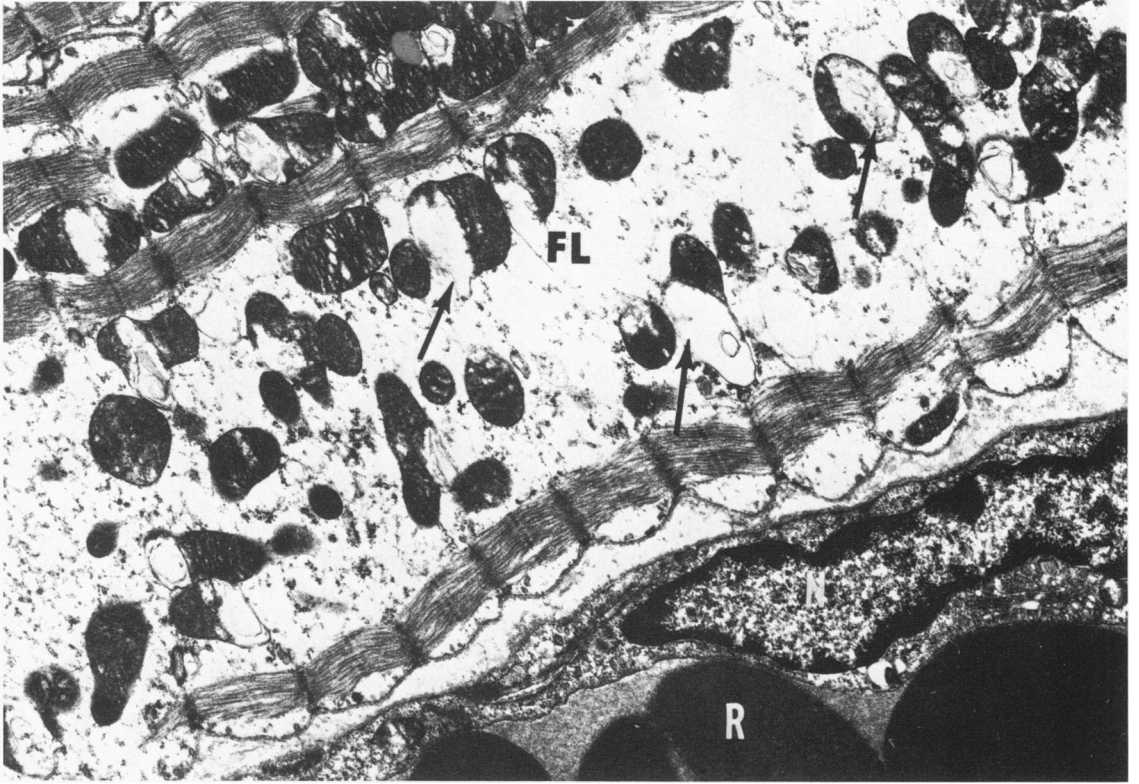

1

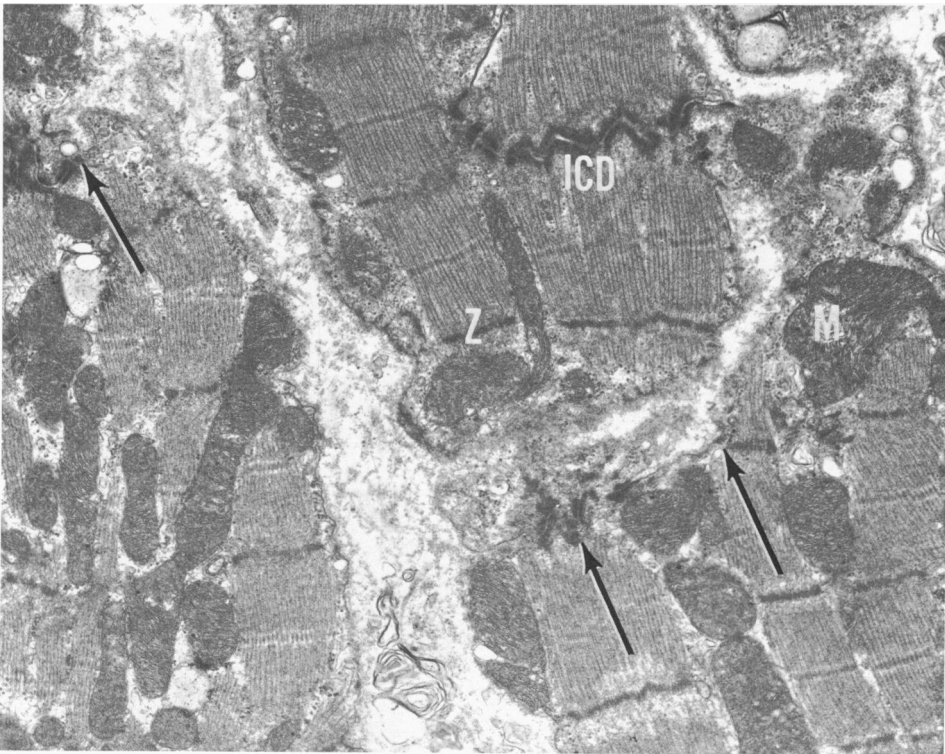


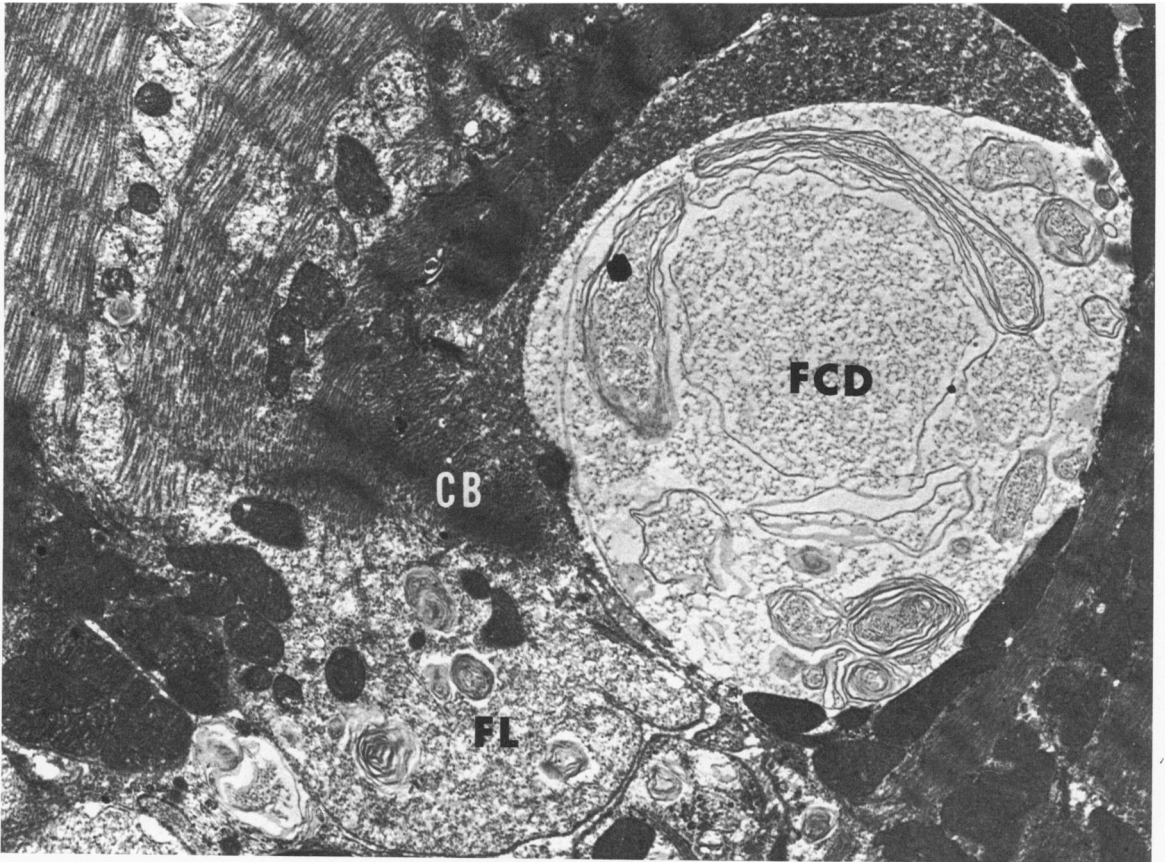
2

3

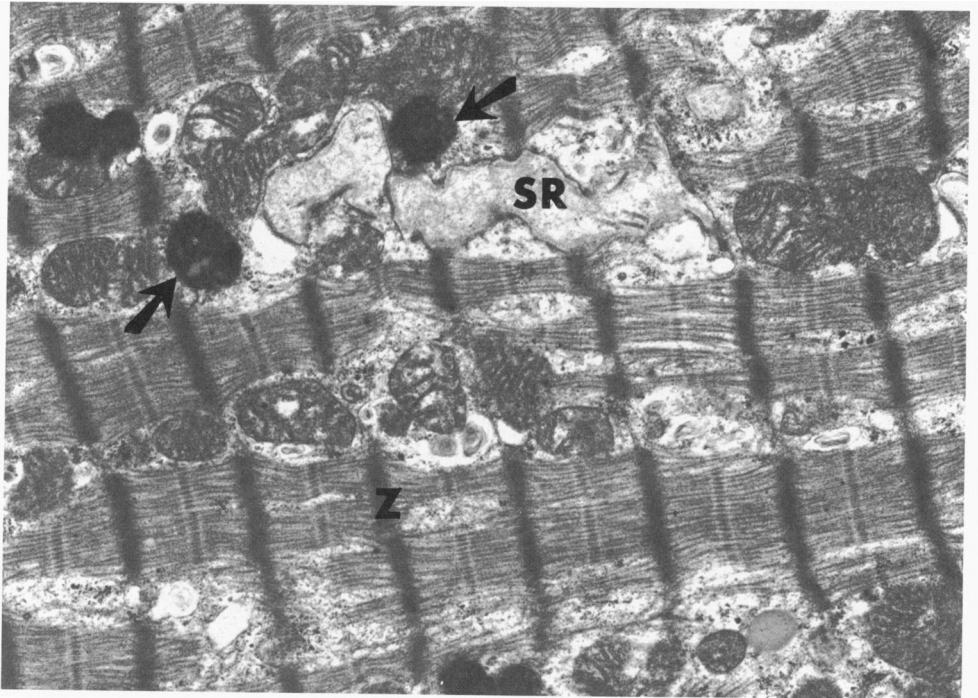


4



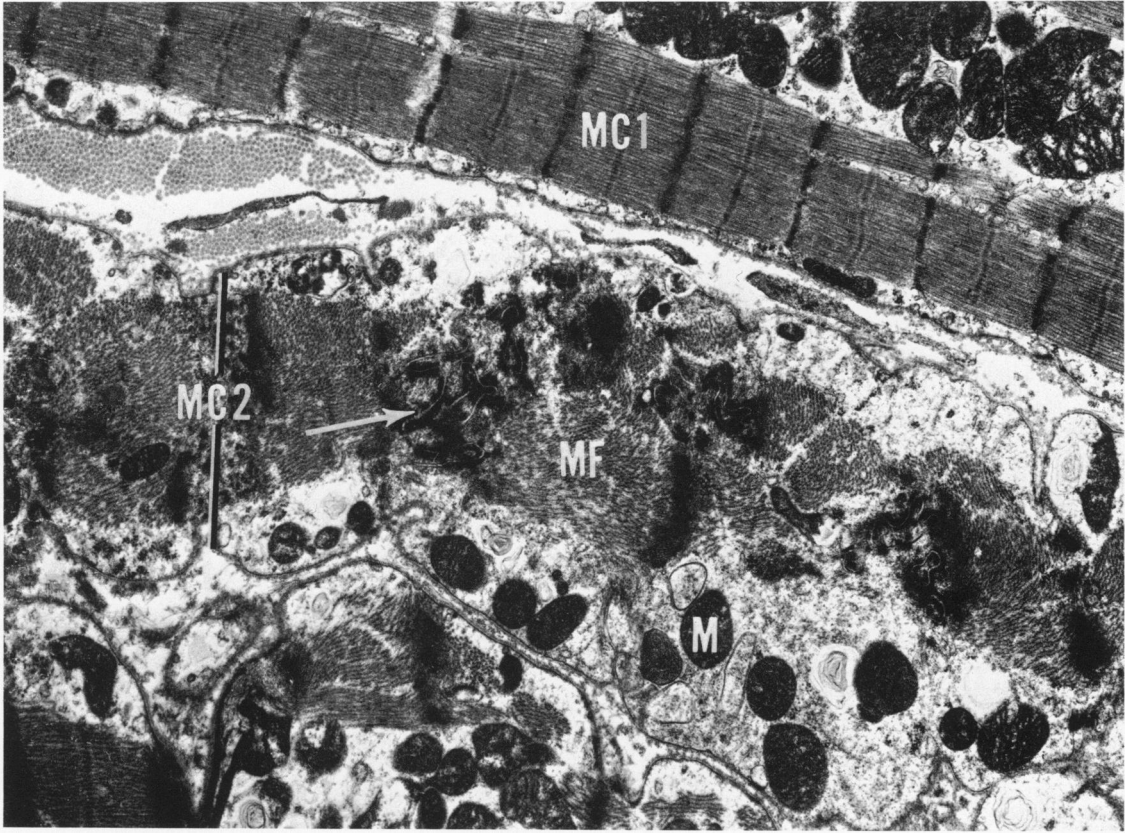


5

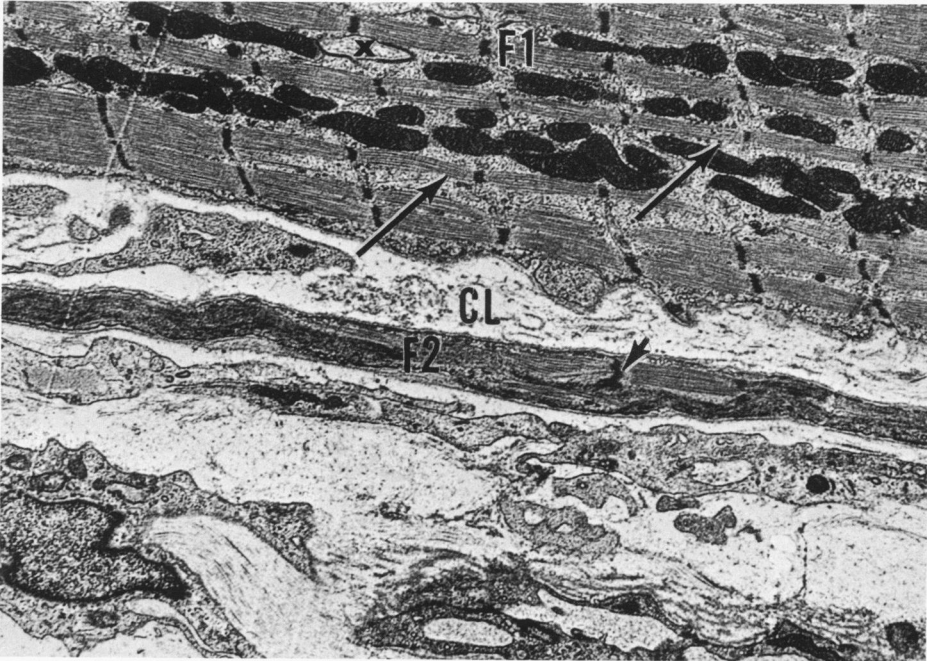


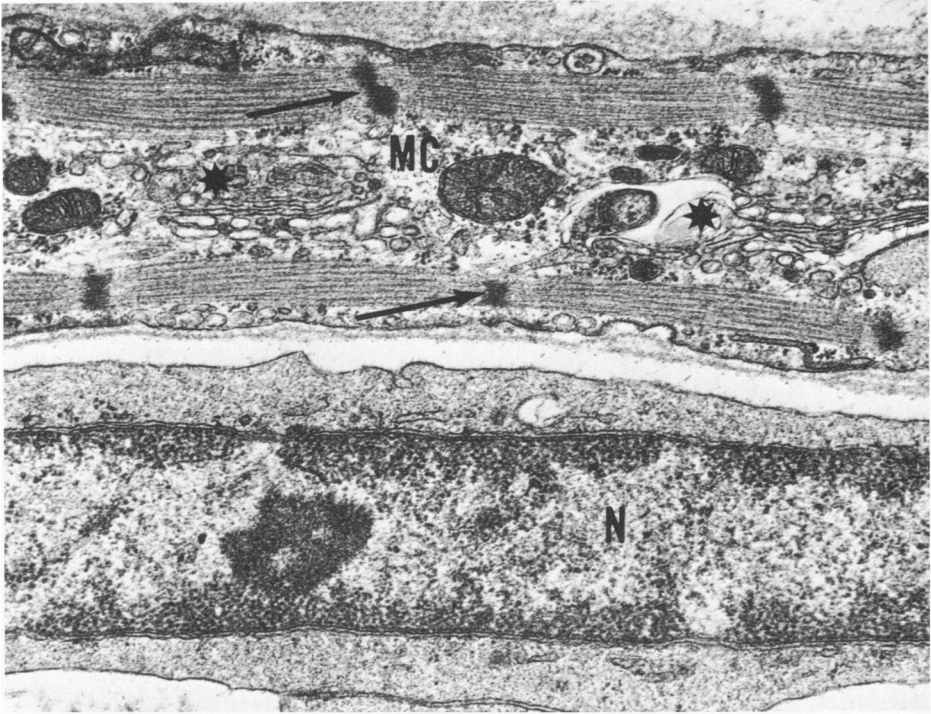
6

7

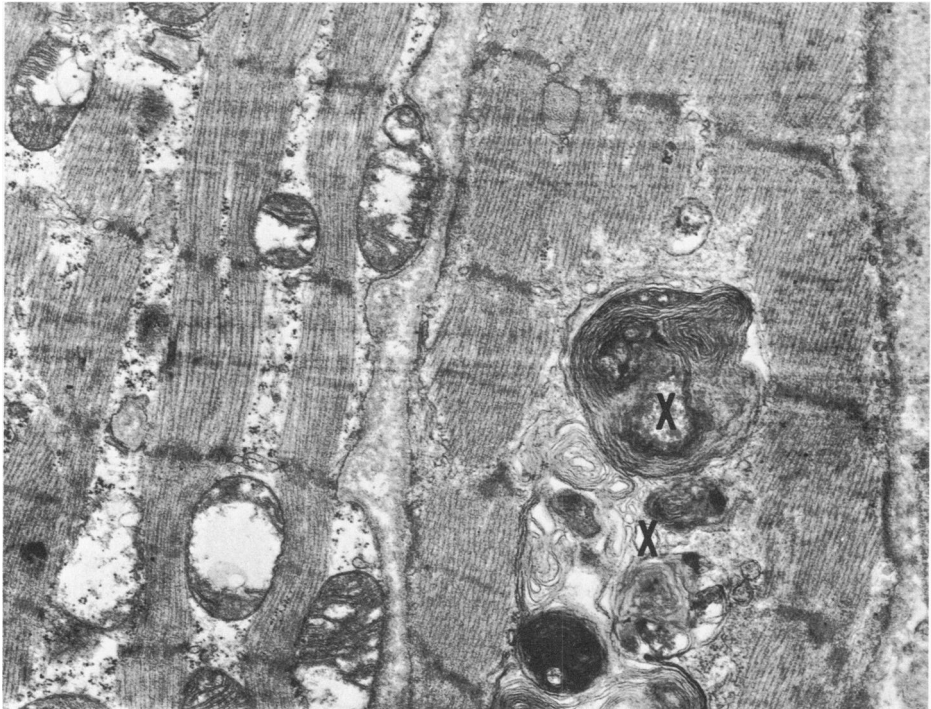


8



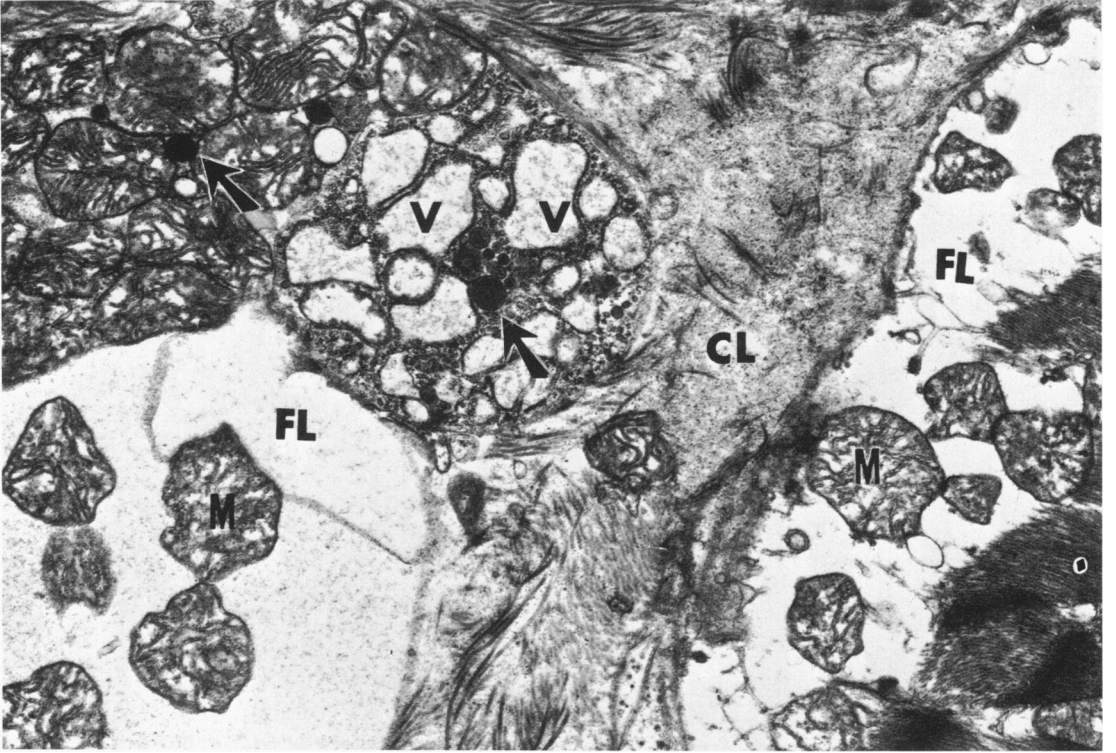


9



10

11



12

