

## STUDIES ON THE EXOCRINE PANCREAS

### I. NONSPECIFIC PANCREATIC DUCTULAR ECTASIA

M. N-I. WALTERS, M.B., B.S., M.R.A.C.P., M.C. PATH.

*From the Department of Pathology, University of Western Australia,  
Perth, Australia*

Although it has long been asserted that retention of pancreatic secretion may result in such histologic changes as dilatation of ducts and end chambers, flattening of cells in the glands and even subsequent necrosis and lipomatosis of the pancreas,<sup>1</sup> it was not realized until relatively recently that dilatation of acini and small ducts was an early and frequent degenerative lesion.<sup>2</sup> In their review of 200 necropsies Wallace and Ashworth<sup>2</sup> found the change in 45.5 per cent of cases, either focally or more diffusely throughout the parenchyma. The acinar lumen was dilated and usually contained an eosinophilic, granular or homogeneous material which appeared to be retained secretion. Flattening of the lining epithelium was also present and their nuclei were smaller and more deeply stained. Because of the over-all increase in the acinar diameter it was felt that the process was a true dilatation and not a result of epithelial atrophy. They also believed the change to be caused only rarely by obstruction of the major pancreatic ducts.

The association of acinar dilatation and renal failure (uremia) was stressed by Baggenstoss in 1947, who also denied its pathogenesis as a consequence of ductal obstruction.<sup>3</sup> Neither age, sex nor the duration and degree of uremia figured significantly in its production. He pointed out that the cells of involved acini lost their zymogenic granules and that the intraluminal material was amorphous, stringy or laminated and reacted like protein to a variety of stains. As the lesion was also present in 20 per cent of controls, it was postulated that dehydration and some as yet undetermined metabolic disturbance resulted in inspissation of secretion and intrinsic obstruction of pancreatic ductules and acini.

A similar reaction was produced in rats by dietary means, and comparable changes were also found in patients with pancreatic fibrosis induced by severe malnutrition.<sup>4</sup> In animals the lesion progressed to pancreatic lipomatosis, but without fibrosis, the islands of Langerhans

This work is a portion of that submitted for a doctorate in the University of Western Australia. The investigation was supported by grant No. MSRG53.45 from the Medical Research Grants Committee of that University.

Accepted for publication, January 16, 1964.

remaining unaffected. In the following year the syndrome was observed in the pancreas of patients not only succumbing in uremia (regardless of its cause), but also in patients with gastric carcinoma, upper intestinal obstruction, sepsis and chronic ulcerative colitis.<sup>5</sup> The lesion was ascribed to a number of factors including inhibition (through vomiting as well as gastric distention) of pancreatic secretion normally stimulated by secretin, abnormal vagal or parasympathetic stimulation causing depletion of zymogenic granules and the formation of a viscid pancreatic juice, and dehydration resulting in inspissation of juice. Protein deficiency, it was thought, might augment the lesions through failure of epithelial repair. Baggenstoss<sup>5</sup> also tentatively compared the histologic structure to fibrocystic disease of the pancreas.

In a review of 120 surgically treated and 60 necropsy cases of ulcerative colitis,  $\frac{3}{4}$  of the latter group manifested the change.<sup>6</sup> Others, when studying the pancreatic structure associated with chronic ulcerative colitis, described the ectasia as being in approximately the same stage of development in all areas and also unrelated to other pancreatic lesions.<sup>7</sup> Still other observers, in studying 256 necropsies, found an incidence of only 13.7 per cent but also believed the mechanism of the disease to be the same as that of cystic fibrosis.<sup>8</sup> Stein and Powers<sup>9</sup> found the incidence to be 21 per cent and showed the lesion to progress to parenchymal scarring after the accumulation and inspissation of secretion had led to pressure atrophy of acinar cells. They called the condition "pancreatic acinar ectasia" and believed it to be a "morphologic expression of a common metabolic disturbance in water balance and/or nutrition secondary to many types of primary illnesses."<sup>9</sup>

The frequent observation of this ectatic syndrome in routine necropsy preparations of the pancreas coupled with the uncertainty as to its pathogenesis inspired a prospective clinico-pathologic survey of it.

#### MATERIAL AND METHODS

Blocks of tissue from the head, body and tail of the pancreas were collected from 200 almost consecutive necropsies performed at the Royal Perth Hospital, Western Australia, in the latter half of 1962 and early 1963. After fixation in 10 per cent buffered formol-saline and Heidenhain's SUSA fixative the tissues were embedded in paraffin and sections cut at a thickness of 5  $\mu$ . These were stained by the following techniques: Harris' hematoxylin, celestin blue and eosin; picro-Mallory; Masson; periodic acid Schiff (PAS) stains.

#### RESULTS

In the present series ectasia was observed in 64 instances, having an incidence of 32 per cent, and with the same clinical associations as have been outlined by other authors (Table I). The most important ac-

companiments were uremia, dehydration and inanition from any cause, especially carcinoma. Hepato-biliary diseases were also commonly present, and one half of 20 patients receiving steroids of the cortisone type manifested the alteration. Most of the cases listed in the cardiovascular group were associated with loss of consciousness, deficient nutrition, dehydration or uremia.

When a search was made for other histologic lesions accompanying ectasia, it was found that proliferation of centro-acinar and intercalary ductular cells was constantly found in the 64 cases (Figs. 1 and 2). Detailed study of the lesions enabled the pathogenesis to be elucidated from its inception to its full manifestation.

TABLE I

DISEASE PROCESSES AND ASSOCIATED FACTORS ACCOMPANYING PANCREATIC ECTASIA

| Disorder   | No. of cases |
|--|--------------|
| Hepatic diseases   | 13           |
| Alcoholism   | 3            |
| Anorexia and malnutrition                                | 19           |
| Cholecystic diseases                                     | 17           |
| Cardiovascular diseases                                  | 38           |
| Hypertension   | 13           |
| Cerebrovascular disease                                  | 13           |
| Ischemic myocardial necrosis                             | 6            |
| Degenerative vascular disease                            | 6            |
| Administration of steroids                               | 10           |
| Administration of histotoxic drugs, e.g., Mustine, etc.  | 3            |
| Carcinoma and sarcoma                                    | 22           |
| Dehydration (including septicemia and diabetes mellitus) | 18           |
| Elevation of blood urea concentration                    | 39           |

## PATHOGENESIS

The initial change was that of proliferation or hyperplasia of the centro-acinar and intercalary ductular cells. These appeared as polygons with indefinite borders, pale cytoplasm, and with an oval, vesicular nucleus possessing a speckled arrangement of its chromatin complement. When hyperplastic they filled the centers of the acini so that these became hypercellular and swollen (Fig. 3). Mitotic figures were not frequently observed. When stained with the PAS stain the centro-acinar cells differed from the zymogen-containing acinocytes by the pallor of their cytoplasm which occasionally contained flecks of PAS-reacting material.

The next phase consisted of eosinophilic swelling of the hyperplastic cells which were often arranged in the form of ductules (Fig. 4). Correspondingly the zymogen-containing acinar cells underwent atrophy, probably the result of pressure (Fig. 5). As this proceeded, the centro-

acinar cells and ductules frequently became necrotic and coagulated eosinophilic cytoplasm burst from the cells (Figs. 6 and 7). Nuclear pyknosis and lysis were often seen. As a consequence of this phase of degeneration and necrosis of the centro-acinar and ductular cells, an eosinophilic detritus, occasionally containing segmented leukocytes, was produced. This debris in turn led to occlusion of other intercalary ductules and imposed a secondary pattern of obstruction on the initial lesion. Ectasia of ductules then followed.

As the process proceeded further, complete degeneration of acinocytes occurred, leaving dilated ductules containing PAS-reacting debris derived from necrotic centro-acinar ductular cells. The appearance was now reminiscent of fibrocystic disease of the pancreas in miniature (Fig. 8). This florid stage was the one usually witnessed at necropsy, but if prolonged probably resulted in adipose and fibrous replacement of the exocrine pancreas, the most usual termination of pancreatic ductal occlusion.

#### DISCUSSION

The name pancreatic acinar ectasia is a misnomer, as the ectasia involves mainly the ductular rather than acinar components and the emphasis placed on acinar dilatation belittles the importance of the contribution of the centro-acinar and intercalary ductular cell as the basis of the lesion. Should this lesion indeed be related to cystic fibrosis, further confirmatory evidence of the role of ductular epithelium in this condition is provided in the statements of Baar,<sup>9</sup> who commented that the secretion in the cysts formed in this hereditary malady contain large amounts of acid mucopolysaccharides which in the pancreas are secreted only by ductal cells; an increase in the number of spaces containing this secretion is indicative of ductal proliferation.<sup>9</sup>

A realization of the importance of the centro-acinar cell in the pathogenesis of the lesion immediately leads to a reorientation of the focus of attention from mechanistic obstructive hypotheses to a pathophysiologic approach based on what is known of the function of this cell. It has long been held that the epithelium of the intercalated ducts is involved in water and electrolyte, especially bicarbonate, secretion.<sup>10</sup> More recently it has been shown that carbonic anhydrase is concentrated in ductal epithelium, whereas acini virtually contain none.<sup>11</sup> The fact that acinocytic necrosis provoked by ethionine does not affect the volume or concentration of bicarbonate of the pancreatic secretion<sup>12</sup> emphasizes the importance of the ductular cell in such a role. Finally, alloxan, which leads to histologically demonstrable abnormalities of ductular cells<sup>13</sup> raises the threshold for secretin stimulation.<sup>14</sup>

Administration of mecholyl over long periods induces enlargement of the epithelium in the walls of small pancreatic ducts and an increase in nuclear volume, thereby indicating increased cellular activity due to hydrochylia; the ability of organophosphates like parathion to produce pancreatitis has also been acknowledged.<sup>12</sup> These compounds, because of their profound anticholinesterase activity in intoxicated individuals,<sup>15</sup> have a pharmacologic potential equivalent to continuous and pronounced vagal excitation. It will be recalled that nervous stimulation mediated through the vagus was one of the factors advanced in the mechanism of production of "acinar ectasia."<sup>5</sup>

It is clear that the pathogenesis of the lesion is concerned with fluid and electrolyte imbalance, its association with dehydration, uremia and vomiting all pointing in this direction. It would also be expected that the effects of such insults would be borne initially by those cells concerned with fluid and electrocyte equilibrium. Malnutrition, by causing ductular-cell necrosis and failure of repair, might well augment the lesions. Atrophy of ferment-producing cells and necrosis of ductules leads to the latter becoming filled with cellular detritus, and inspissation of this, through failure of water secretion by the ductular cells, leads secondarily to occlusive phenomena.

In postulating that the lesion is initiated by vagal stimulation, one must stress that such excitation can occur in a broad spectrum of clinicopathologic situations so that although a direct result of this neural mechanism is a "specific" hyperplasia of the centro-acinar and small ductular cells (with its necrotic and ectatic sequelae), it presents to the morbid anatomist as a "nonspecific" pancreatic lesion.

#### SUMMARY

Dilatation or ectasia of pancreatic ductules is a common nonspecific lesion which occurred in 32 per cent of a series of 200 consecutive adult necropsies. The lesion is probably initiated through vagal excitation, causing hyperplasia of centro-acinar and intercalary ductular cells, many of which subsequently become necrotic and produce the eosinophilic debris characteristic of this condition as well as hereditary cystic fibrosis. Inspissation of the detritus because of failure of hydration of the material by ductular cells causes progressive obstruction and may eventually lead to pancreatic exocrine lipo-atrophy.

#### REFERENCES

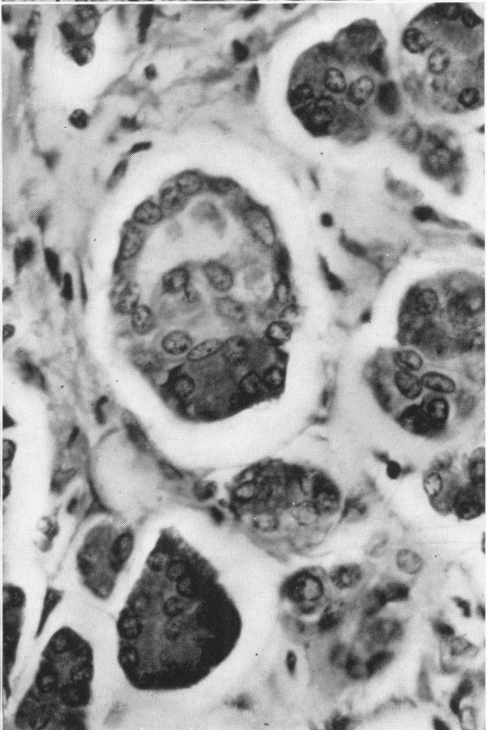
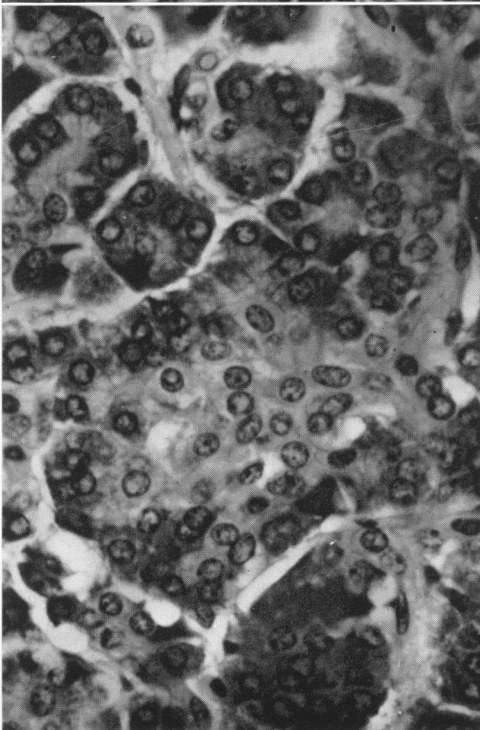
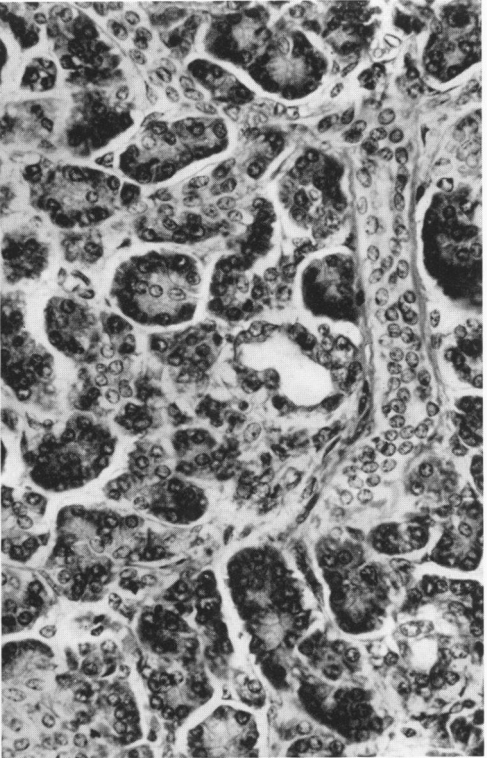
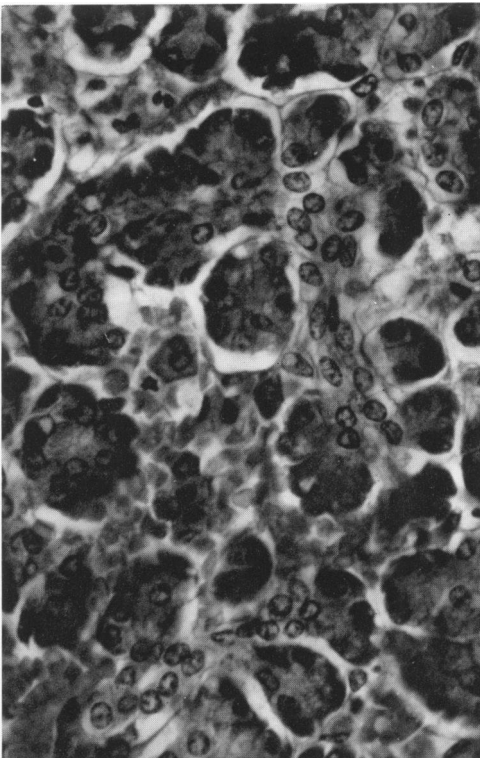
1. BALO, J., and BALLON, H. C. Effects of retention of pancreatic secretion. *Surg. Gynec. & Obst.*, 1929, 48, 1-13.
2. WALLACE, S. A., and ASHWORTH, C. T. Early degenerative lesions of the pancreas. *Texas State J. Med.*, 1942, 37, 584-587.

3. BAGGENSTOSS, A. H. The pancreas in uremia. (Abstract) *Am. J. Path.*, 1947, 23, 908-909.
4. GILLMAN, T. In discussion following Baggenstoss.<sup>3</sup>
5. BAGGENSTOSS, A. H. Dilatation of the acini of the pancreas. Incidence in various pathologic states. *Arch. Path.*, 1948, 45, 463-473.
6. WARREN, S., and SOMMERS, S. C. Pathogenesis of ulcerative colitis. *Am. J. Path.*, 1949, 25, 657-680.
7. BALL, W. P.; BAGGENSTOSS, A. H., and BARGEN, J. A. Pancreatic lesions associated with chronic ulcerative colitis. *Arch. Path.*, 1950, 50, 347-358.
8. MENTEN, M. L., and KINSEY, W. C. Asymptomatic retention of pancreatic secretion. *Arch. Path.*, 1949, 47, 90-96.
9. STEIN, A. A., and POWERS, S. R., JR. Pancreatic acinar ectasia. *Arch. Path.*, 1956, 62, 494-496.
10. BARR, H. S. Fibrocystic disease of the pancreas. *Lancet*, 1953, 2, 80-83.
11. DREILING, D. A., and JANOWITZ, H. D. The secretion of electrolytes by the human pancreas. The effect of diamox, ACTH, and disease. *Am. J. Digest. Dis.*, 1959, 4, 127-144.
12. BECKER, V. Histochemistry of the Exocrine Pancreas. In: The Exocrine Pancreas. Ciba Foundation Symposium. DERUICK, A. V. S., and CAMERON, M. P. (eds.). J. & A. Churchill, Ltd., London, 1961, pp. 56-66.
13. KALSER, M. H., and GROSSMAN, M. I. Pancreatic secretion in dogs with ethionine-induced pancreatitis. *Gastroenterology*, 1954, 26, 189-197.
14. GOLDNER, M. G., and GOMORI, G. Alloxan diabetes in the dog. *Endocrinology*, 1943, 33, 297-308.
15. GROSSMAN, M. I., and IVY, A. C. Effect of alloxan upon external secretion of the pancreas. *Proc. Soc. Exper. Biol. & Med.*, 1946, 63, 62-63.
16. WALTERS, M. N-I. Malathion intoxication. *M.J. Australia*, 1957, 1, 876-877.

The photomicrographs were prepared by H. Upenieks, A.R.P.S., and Jos. Schramp of the Department of Medical Illustration.

#### LEGENDS FOR FIGURES

- Photomicrographs were prepared from sections stained with hematoxylin and eosin.
- FIG. 1. Centro-acinar cells and an intercalary ductule of the exocrine pancreas. × 550.
- FIG. 2. There is proliferation of ductular cells. × 350.
- FIG. 3. Hyperplasia of centro-acinar cells is accompanied by ductular dilatation. × 570.
- FIG. 4. The centro-acinar ductule is dilated. × 600.



1

2

3

4

- FIG. 5. Necrosis of dilated eosinophilic ductules is associated with atrophy of acinocytes.  $\times 400$ .
- FIG. 6. There is cytoplasmic disruption of ductular cells producing "secretion."  $\times 1,500$ .
- FIG. 7. Centro-acinar necrosis results in intra-acinar "mucoïd" debris.  $\times 1,500$ .
- FIG. 8. Pancreatic ductular ectasia. Nuclear remnants are present in the detritus.  $\times 370$ .



