

## DIFFUSE ARTERITIS OF SYPHILITIC ORIGIN \*

CLIFFORD L. DERICK, M.D., AND GEORGE M. HASS, M.D.

(From the Medical Service and the Department of Pathology of the Peter Bent Brigham Hospital, Boston, Mass.)

That the *Treponema pallidum* may cause arteritis has long been recognized. The aorta and cerebral vessels are involved most frequently, although lesions in small vessels elsewhere, such as those of the extremities, have been found occasionally. This subject was reviewed recently by Connor<sup>1</sup> in his Billing's lecture entitled "Development of Knowledge Concerning Role of Syphilis in Cardiovascular Disease." In this lecture Connor noted how infrequently organisms have been found in the lesion.

Since we have had an opportunity to study both clinically and at autopsy a case with widespread involvement of the smaller arteries, and since the *Treponema pallidum* has been identified in one of these vascular lesions, it seemed wise to report our findings in some detail.

### REPORT OF CASE

*Clinical History:* The patient, a 26 year old male, was admitted for the first time to the hospital in January, 1933. At that time he complained of a painful sore on the penis of 7 days duration and of a urethral discharge. His past history was irrelevant, except that he had had gonorrhoea 6 years previously. He stated that he usually went on an alcoholic debauch monthly for 24 hours, at which time he was exposed sexually. The last occasion was 6 weeks previously.

Examination revealed a normal male, except for a chancre 1.7 by 1 cm. on the penis just back of the corona, and the presence of a moderately profuse urethral discharge. The discharge contained numerous organisms typical of the gonococcus. Scrapings from the ulcer, when examined by the dark field method, contained numerous treponemata. The patient remained in the hospital for 14 days, during which time he received five intravenous injections of arsphenamine. The dosage ranged from 0.1 gm. to 0.4 gm.

Following the last injection the patient had an erythematous dermatitis, due presumably to the arsphenamine medication. From this time until Aug. 18, 1933, the patient received three series each of arsphenamine and mercury succinimide in our Out-Patient Department. Hinton and Wassermann tests were repeatedly negative after April 4, 1933. He was treated for urethritis in the Genito-Urinary Department. On August 21, 1933, he was found to have a bilateral epididymitis. The patient was not seen again until Oct. 30, 1933, when

\* Received for publication August 14, 1934.

he returned complaining of pain in the left calf and foot. This pain was shooting in nature and aggravated by walking. Examination at this time revealed no objective evidence of disease, such as swelling, redness or tenderness.

He was seen again on Nov. 15, 1933, with the complaint that the pain in his foot had persisted. He stated also that he had lost weight, had a poor appetite and was constipated. In January the patient weighed 188 pounds; his weight now was 153 pounds. Examination again revealed nothing abnormal, except for evidence of loss of weight and a chronic urethritis. His blood pressure was not recorded at this time. A roentgenogram of the left foot revealed slight atrophy of bones but nothing otherwise abnormal.

He was readmitted to the hospital as an emergency case on Dec. 4, 1933. Because of his confused, irrational state the interval history had to be obtained from his sister. The latter stated that the patient had had severe headaches for 1 week for which he had taken numerous "anacin" tablets and that he had taken twenty-eight tablets the day previously. Each "anacin" tablet contained three grains of acetophenetidin. Headache had persisted in spite of medication, and he had become very irritable and nervous. The morning of admission his vision became involved so that he could distinguish light from dark only.

Physical examination was unsatisfactory on account of the irritability and uncoöperative attitude of the patient. His blood pressure was 230 mm. mercury systolic and 100 mm. diastolic, whereas in January, 1933, it was 110/75 mm. of mercury. The heart seemed normal in all respects, and the walls of the peripheral vessels were not thickened. He was able to count fingers correctly at four feet. Although ophthalmoscopic examination was not satisfactory, no abnormality could be found other than a questionable blurring of the disc margins. All neurological reflexes were normal. The temperature was 100° F. and white blood cell count 12,000 per cmm.

Lumbar puncture at this time revealed a clear, colorless fluid under increased pressure. The fluid contained thirty lymphocytes and nine polymorphonuclear leukocytes per cmm. and an increased amount of globulin. Wassermann reactions on both blood and spinal fluid were negative.

Forty-eight hours after admission the patient seemed normal except for a slight persistent headache. Another lumbar puncture revealed only slight increase of pressure. The fluid at this time contained four lymphocytes per cmm. and a normal amount of globulin. The blood pressure had fallen gradually to 145 mm. mercury systolic and 98 mm. diastolic.

The patient's condition seemed to improve until Dec. 11, 1933, when he complained of cramp-like pain across the upper abdomen. This was accompanied by hiccough and periodic vomiting. Although tender to pressure there was no rigidity of the abdominal wall. At this time the white blood count showed 39,500 leukocytes per cmm. He was seen by Dr. Cutler, who could find no indication for surgical intervention. A stool, which had been free of blood previously, now contained blood in visible amount. The explanation for this was uncertain as the patient had internal hemorrhoids as a possible source. The red blood cell count and hemoglobin were normal and blood urea nitrogen was 21 mg. per cent. Another lumbar puncture was performed, which showed a considerable increase in pressure but nothing otherwise abnormal. With the persistence of nausea, vomiting and hiccough his condition grew worse gradually so that by Dec. 18, 1933, he was in a semicomatose state. At this time there was definite edema of the optic nerve heads, numerous areas of

hemorrhage in the right fundus oculi and incontinence of urine and feces. In view of the possibility of an intracranial tumor he was transferred to the surgical service where ventriculography and encephalography were performed with inconclusive results. His condition failed to improve and he died on Dec. 21, 1933. During the final 10 days of his illness seven white blood cell counts were done. The values of these ranged from 20,000 to 39,500 cells per cmm. His temperature at no time was above 100° F.

In view of the protean manifestations, a hypertension of rapid onset, hemorrhages into the retina, a probable mesenteric thrombosis, pains of unexplained etiology in an extremity, and a marked leukocytosis with little or no febrile response, the clinical diagnosis of vascular disease with multiple thromboses was made.

#### AUTOPSY REPORT

Autopsy was performed 2 hours after death with the following findings.

*Body:* The body was that of a moderately well developed and well nourished white male, 172 cm. in length. Pitting edema of the lower extremities was present. There was a bilateral external strabismus. A small atrophic scar of the penis was found at the site where the primary chancre had been.

*Peritoneal Cavity:* The important findings will be considered in a discussion of the alimentary tract.

*Pleural Cavities and Mediastinum:* These regions were normal except for fibrous adhesions between the apex of the right lung and the parietal pleura.

*Heart:* The pericardial cavity was normal. The heart weighed 300 gm. There was a patent foramen ovale, which was 5 mm. in diameter. The four valves, myocardium and arteries were normal.

*Lungs:* The right lung weighed 700 gm. and the left 630 gm. In the lower lobe of each lung there were scattered and confluent, gray, nodular areas of pneumonic consolidation. Sanguinopurulent exudate could be expressed from these regions. The mucosa of the primary and secondary bronchi showed irregular areas of superficial necrosis covered by a grayish yellow fibrinopurulent exudate. There were no infarcts. The arteries and veins were normal.

*Celiac Axis and Branches:* The splenic, hepatic and left gastric arteries and their major branches appeared to have normal walls and lumens. The small branches of these major trunks will be described in connection with the organs which they supplied.

*Spleen:* The spleen weighed 300 gm. A few fibrous adhesions

were attached to the capsule. The pulp, trabecular structure and vessels were normal.

*Pancreas:* The pancreas weighed 110 gm. There were small indistinct areas of lobular fibrosis. Small arteries were prominent because of their thick, firm walls and very narrow lumens, several of which appeared to be occluded.

*Liver and Gall-Bladder:* The liver weighed 1800 gm. In the left lobe along the anterior border a subcapsular, well demarcated, yellowish white, friable area was found. This was roughly pyramidal in shape and 25 mm. in diameter. In this area the liver markings were not distinct but there was no evidence of liquefaction or caseation necrosis. Further incisions disclosed two small similar areas in the substance of the liver. The small intrahepatic arteries often had narrow lumens and thick walls. The veins were normal. No thrombi were found in the branches or tributaries of the portal vein.

The gall-bladder and extrahepatic biliary ducts were normal.

*Alimentary Tract:* The esophagus was normal. Along the lesser curvature of the stomach, midway between the cardiac and pyloric orifices, there was a punched-out, sharply circumscribed, circular ulcer measuring 8 mm. in diameter. The flat firm base and indurated margins of the ulcer were covered by dark red, necrotic material. In the first portion of the duodenum, just distal to the pyloric sphincter and on the posterior wall, a large irregular ulcer which measured 20 by 10 mm. was found. This appeared to be of more recent formation than the gastric ulcer. The remainder of the duodenum and the proximal 10 cm. of the jejunum were normal. The distal portion of the jejunum had numerous, punctate, subserosal and submucosal hemorrhages. There was slight mucosal edema but no ulceration.

In the ileum three principal areas of hemorrhagic infarction with mucosal ulceration were disclosed. Other similar though less severe lesions were present. The first large infarct was in the first portion of the ileum. The second lesion was 25 cm. distal to the first (Fig. 2). The third major lesion was 35 cm. proximal to the ileocecal valve. They were from 2 to 5 cm. in length and involved the entire circumference of the ileum as well as the adjacent 5 to 10 mm. of the mesentery. Although the degree of hemorrhagic gangrenous necrosis was different in each instance, the lesions were of similar character. The wall of the intestine varied in thickness in propor-

tion to the extent of edema, hemorrhage and necrosis, but in several areas of each infarct it was thin, friable, and greenish black in color. The second lesion was the most severe. A hemorrhagic, fibrino-purulent exudate had accumulated on the peritoneum and the loop of intestine was bound to the diseased sigmoid colon by fibrous and fibrinous adhesions. The mucosa in each area of infarction was hemorrhagic, edematous, soft and ulcerous. The ulcerations for the most part were adjacent to the attachment of the mesentery. They were shallow, poorly demarcated and often confluent. Their bases were flat and were covered with necrotic, gray, hemorrhagic material. The regional mesentery was slightly edematous and congested but had been spared the extensive necrosis that characterized the ileum.

The colon, except for that portion between the middle of the descending colon and the rectosigmoid junction, was normal. The involved part of the colon was contracted. Its wall and mesentery were thick and indurated. The mucosa was hyperemic and extensively ulcerated. The ulcers varied from 8 to 15 mm. in diameter. They were disposed circumferentially and tended to lie between the edematous rugae. They had irregular, well defined margins and gray, firm bases. The thick, edematous and often densely fibrous submucosa formed their bases. The cicatrization of the edematous, pericolonic fat, and the firm, fibrous adhesions which bound the small bowel to the colon indicated that the process was of subacute or chronic character.

The rectum was normal.

The direct cause of the lesions of the ileum and colon was disclosed by a dissection of the superior and inferior mesenteric arteries. The main channels and all branches of greater than 2 mm. in thickness were normal. The arcuate arteries of about 1 to 1.5 mm. in thickness often showed definite thickening of their walls, moderate narrowing of lumens and an unusual degree of adherence of the adventitia to the regional fat of the mesentery. These vessels, however, were much less seriously involved than were their terminal branches which passed directly to the ileum. The degree of involvement was not uniform but varied from place to place along the intestine and from place to place in the same artery. The arteries which supplied the jejunum were relatively free from changes. Those of the upper ileum that were abnormal were few in number. Along the remainder

of the ileum the vascular lesions were rather uniformly distributed, although there was a tendency for groups of arcuate branches to be more seriously diseased than their neighbors. This was especially prominent in the vascular tree which supplied the areas of infarction (Figs. 3 and 4). The branches supplying the colon were only rarely affected. These small arteries, which were usually 1 mm. or less in diameter, were often pale gray and firm, resembling fibrous cords. In other instances this resemblance was restricted to local areas, while a more normal vascular tunic persisted between the lesions. Often the only portion of the vessel that showed prominent thickening was at the point where the artery entered the wall of the ileum. There were no definite aneurysms, although isolated, small, nodular thickenings and spherical, purplish intravascular masses occasionally were found. Cross-sections showed that the appearance of the vessels was due to an increase in the thickness of the adventitia which was often abnormally adherent to the adjacent fat tissue, to a fibrous thickening of the media and intima and to partial or complete closure of the lumens by dense white tissue or firm red thrombi.

The inferior mesenteric, left gastric and pancreaticoduodenal arteries were inspected. The smallest vessels presented lesions that were identical with those of the small arcuate branches of the superior mesenteric artery. These were prominent among the branches that supplied the sigmoid colon and the first part of the duodenum but were rarely found elsewhere.

*Kidneys:* The right kidney weighed 180 gm., and the left 160 gm. They were of similar appearance. The capsules, which were of uniform normal texture, were adherent to the cortex in a few, small, depressed areas. The external surface of each kidney cortex was irregular in contour. There were numerous broad, slightly concave depressions which surrounded and merged imperceptibly with slightly convex, plateau-like elevations. The elevations varied from 1 to 15 mm. in diameter. They were irregular in outline and were usually firm and purplish red in color. Rarely, they were soft and grayish yellow. The intervening areas of cortical substance were firm and grayish pink. Coronal sections of each kidney showed a continuation of these variations in color and texture deeply into the cortex with a gradual diminution in diameter as the medullary regions were approached. The kidney markings were well preserved in the pale gray areas, indistinct in the purplish red zones and ab-

sent in the homogeneous, friable, grayish yellow parts of the cortex. The pyramids, pelves and calices were normal (Fig. 1).

The main renal arteries and their primary branches were normal. The interlobular arteries showed a variable degree of mural thickening with concentric narrowing of their lumens. These changes became greater in the distal parts of these arteries and in the arcuate arteries. Here, the lumens of the vessels occasionally were reduced to minute channels or were replaced by dense fibrous tissue, so that the arteries resembled solid fibrous cords. Thus it seemed that the alterations in the renal cortex represented the effects of partial or complete deprivation of arterial blood.

*Adrenals:* The right adrenal weighed 15 gm., and the left 10 gm. The small extracapsular arteries had thick walls and narrow lumens.

*Pelvic Organs:* Normal in appearance.

*Testes:* Except for a firm indurated hemorrhagic area (3 to 4 mm.) beneath the tunica of one testis, the testes were normal.

*Thyroid and Parathyroids:* The thyroid and parathyroids were normal.

*Bone Marrow:* The marrow of the ribs was dark red in color and slightly diminished in amount.

*Aorta:* Rare atheromatous patches in the intima of the abdominal portion of the aorta were seen.

*Eye:* The vessels were engorged. Moderate edema of the retina was present. Pin-point hemorrhages were few in number.

*Brain:* The brain weighed 1340 gm. There was slight flattening of convolutions and narrowing of the sulci of the cerebral cortex. An indistinct pressure cone was present at the base of the cerebellum. The meningeal and cortical hemorrhages were restricted to the sites of operative trauma. Coronal sections disclosed numerous small, grayish brown areas (1 mm.) in the cerebral cortex and subjacent white matter. The arteries and their branches showed no lesions.

#### MICROSCOPIC STUDY

The sections were stained with eosin-methylene blue. The stains of Giemsa, Gram-Weigert and Levaditi were used in an attempt to demonstrate microorganisms.

*Heart:* The coronary arteries are normal. In the dense connective tissue adjacent to the adventitia of a small artery there is a

small area of infiltration with polymorphonuclear leukocytes and monocytes.

*Lungs:* All arteries are normal. An acute bronchitis and a confluent bronchopneumonia are present. Gram-positive diplococci are found in phagocytic cells. A few polymorphonuclear leukocytes are scattered throughout the walls of several veins.

*Spleen:* Except for a mild thickening and hyalinization of walls of arterioles, the arteries are normal. The sinusoids contain an increased number of polymorphonuclear leukocytes. A large amount of hemosiderin is found in mononuclear phagocytes. A hyaline, eosinophilic deposit is present in many follicles.

*Stomach:* There are lesions of the walls of submucosal arteries and ulcerations of the regional mucosa and submucosa. The lumens of the arteries are reduced to very narrow channels by proliferation of intimal cells and fibril formation. The newly formed intimal tissue is loose-textured and often infiltrated with polymorphonuclear leukocytes, plasma cells and lymphocytes. Occasionally, the intima is partially destroyed and thrombi fill the vascular lumens. In other arteries the process is less acute. In these instances cicatrization of the adventitia and media with lymphocytes scattered about in the dense connective tissue is found. The ulceration of the mucosa is acute. Edema, cellular infiltration and degeneration of tissues of the submucosa are noted in the base of the ulcer.

*Duodenum:* The ulcer is acute. There is extensive necrosis of the mucosa and submucosa. Thrombi of recent formation occlude many veins and arteries in the base and at the margins of the ulcer. The arteries of the submucosa, muscularis and serosa show pathological changes similar to those in the gastric arteries. The small arteries chiefly are affected by the disease. In the larger arteries intimal proliferation is predominant, and the vessel walls usually are free from inflammatory cell infiltration and fibrosis. The smaller arteries show less prominent intimal proliferation, old and recent thrombi, infiltration with lymphocytes and plasma cells and a variable degree of fibrosis of the media and adventitia.

*Small Intestine and Mesentery:* Numerous sections through the small intestine and its mesentery, both in the regions of the infarcts and of the grossly normal bowel, were studied. The significant findings are those in the walls of arteries and those of infarction of the ileum. The arterial lesions, which are common in the mesentery



and rare in the wall of the ileum, are inflammatory and chronic in character. The small arteries of less than 1 mm. in diameter principally are diseased. The smallest arteries, arterioles, and veins are normal or only secondarily affected. The greatest number of arterial lesions are healed. Several apparently are of chronic progressive character. None is acute. So far as could be determined, the earliest lesion seems to be characterized by an infiltration of polymorphonuclear leukocytes, plasma cells, lymphocytes and eosinophiles in the adventitia and outer portions of the media. Subsequent to, or coincident with, this reaction there is a proliferation of cells of the intima with deposition of delicate collagenous fibrils between the newly formed cells. This concentric proliferation is often so great that the narrowing of lumens is carried almost to the point of obliteration. In other instances degeneration of the inner layers of the intima and thrombosis has occurred. The various stages from acute thrombi to those which are dense, fibrous and canalized can be traced (Fig. 5). As the organization of thrombi progresses, there seems to be in the media a coincident atrophy and fibrosis accompanied by the appearance of small vascular channels. Cicatrization of the adventitia gradually becomes prominent. Numerous, small, endothelial-lined spaces are formed in the thick adventitia. These communicate through the newly formed capillaries in the media with the canaliculi in the thrombi. In several older lesions the cellular infiltration has disappeared, leaving the cicatrized remnants of the original arterial wall. There are several variations from this reconstructed sequence of pathological changes. The commonest variation is intimal proliferation which seems to be unassociated with inflammatory cell infiltration. The veins and large lymphatics show no primary lesions and only rarely are they seriously affected by the inflammation in the adventitia of the arteries which they accompany.

The wall of the ileum shows not only slight variations from normal histology but also extensive necrosis. In sections of normal ileum there is an occasional, small, submucosal artery which has a thickened intima and infiltrating lymphocytes and plasma cells in the adventitia. In the areas of necrosis, which may be considered as infarcts, arteritis is more widespread and severe. Not infrequently, acute and organized thrombi are found. In these regions there is an acute or subacute necrosis and a diffuse inflammation throughout the

entire wall. Usually the mucosa is destroyed. Beneath the ulcerations are many dilated vascular channels, several of which contain fibrinous thrombi. These thin-walled vessels extend through the acutely inflamed, edematous wall, ramify throughout the muscularis and serosa and anastomose with serosal vessels.

*Colon and Mesentery:* Numerous sections depict a process which is similar to that in the mesentery and wall of the ileum. The arteritis is of the same nature. The only appreciable difference between the infarcts is that in the colon there are several chronic, cicatrizing ulcers of the mucosa. In general, the lesions of the ileum are more acute.

*Liver:* In small arteries there are numerous inflammatory and proliferative lesions similar to those in the mesenteries, kidneys and elsewhere. The parenchyma is normal, except in the sections through the large pale area which is found along the anterior border of the liver. At the periphery of this well demarcated lesion small acute necroses are found in the midzonal regions. In the center of the area there is acute necrosis of the inner two-thirds of each lobule. The process is characterized by degeneration of liver cells, diminution in the number of red blood cells in the sinusoids, rare fibrinous thrombi in vascular channels and a large number of polymorphonuclear leukocytes, not only in sinusoidal spaces but also invading the columns of liver cells. This lesion is presumably an acute infarct which is the direct result of the arterial disease. In the periportal connective tissue and in Kupffer cells a moderate amount of hemosiderin is found.

*Pancreas:* There are numerous arterial lesions and old and recent infarcts. The type of arteritis is similar to that which has been described in the other organs (Figs. 6 and 7). Thrombi in all stages of organization are found. Several areas of acute or subacute necrosis and small intralobular cicatrices are present. These are probably secondary to partial or complete occlusion of the trophic arteries.

*Kidneys:* Arterial lesions and cortical infarcts are numerous. The inflammation of the arteries is either healed or of chronic progressive nature. The arteries which chiefly are affected measure less than 2 mm. in diameter. The interlobular and arcuate arteries show the most prominent changes. The smallest arteries, arterioles and glomeruli exhibit no primary lesions, although they are affected secondarily by closure of the vessels from which they arise.

The arterial disease is similar to that which is found especially in the mesenteries of the ileum and colon and in the pancreas. The largest arteries (2 mm.) show great thickening of the intima and a corresponding degree of reduction in the size of their lumens. This loose-textured, intimal hyperplasia is not associated with an inflammatory cell infiltration of the intima, except in those instances in which acute thrombi have formed. In the smaller arteries the fibrils and cells of the hyperplastic intima are in a more compact arrangement. The lumens are very narrow and often are occluded by old or recent thrombi. Recent thrombi are more common in the vessels of the kidney than elsewhere. However, the presence of organized and canalized thrombi, as well as the dense fibrosis of the media and adventitia, indicate that the disease is of long duration. In fact, there are only rare arteries which are infiltrated or surrounded by any significant number of lymphocytes and plasma cells.

The infarcts in the renal cortex are undoubtedly secondary to the arterial disease. As a rule, they are of acute nature and correspond to the elevated areas beneath the capsule of each kidney. Here, the glomeruli and tubules show a homogeneous necrosis without any appreciable disturbance of structural relations. The interstitial tissues are edematous and infiltrated with a few polymorphonuclear leukocytes. Infarcts of less recent date are represented by small radial cicatrices.

*Adrenals:* There are prominent pathological changes which involve the periadrenal tissues, the small arteries, the capsule, the sympathetic nerves and the cortex of each gland. The most significant lesions are those of the small arteries. These lesions consist of a proliferation of intimal cells in concentric fashion, an increase in the amount of collagen between the cells, marked narrowing of the lumens, organized and canalized thrombi, fibrosis of the adventitia and media and newly formed capillaries in the adventitia adjacent to the media. This process is accompanied by very little evidence of active inflammation. Occasional clusters of lymphocytes and plasma cells are found in the perivascular tissues and adventitia. The perivascular cicatrices which radiate from the adventitia involve the sheaths of several, unusually large, sympathetic nerve trunks. The fibrous capsule of each gland in many areas is dense and thick and portions of the glomerular zone are replaced by

cicatricial tissue. In the zona fasciculata there are acute and healed foci of degeneration. The acute lesions resemble the necroses in the liver. They show acidophilic, shrunken, cortical cells flanked by large numbers of polymorphonuclear leukocytes in the sinusoids. In the healed lesions most of the cortical cells have disappeared. Between the columns of residual atrophic cells there is an increased amount of connective tissue. In the medullary regions there are aggregates of sympathetic ganglion cells and large sympathetic nerve trunks.

*Testis:* Beneath the tunica albuginea there are several small arteries with lesions which do not differ from those in several other organs. These arteries contain several recent and a few organized thrombi. Focal areas of cicatrization and acute necrosis involve groups of seminiferous tubules. No significant changes are found in the arteries between the tubules.

*Thyroid:* The arteries and parenchyma are normal.

*Pituitary:* In the capsule of the anterior lobe there is an area of recent hemorrhage with fibroblastic proliferation. The arteries are normal.

*Prostate and Urethra:* At the periphery of the gland several small arteries show intimal thickening, which is due to a concentric deposition of dense lamellae of collagen. In the adventitia and less frequently in the media of these arteries there are groups of lymphocytes and plasma cells. A slight chronic inflammatory reaction is present in the mucosa of the urethra and the stroma of the prostate.

*Aorta:* The wall of the aorta is normal. In the adjacent fat tissue there are several small arteries with thickened intimal layers, narrow lumens and areas of lymphocytic infiltration in the adventitial connective tissue.

*Abdominal Lymph Node:* In the sinusoids numerous mononuclear phagocytes which contain red blood cells and hemosiderin are found. Eosinophiles are scattered through the gland. A small artery at the hilum shows concentric intimal hyperplasia, a narrow lumen and many small endothelial-lined channels in the thick fibrous adventitia.

*Bone Marrow:* The rib marrow contains an increased number of erythroblasts. A large amount of hemosiderin is demonstrable in large mononuclear phagocytes.

*Voluntary Muscle and Skin:* There are no lesions.

*Retina:* Between the outer and inner nuclear layers fibrinous thrombi occlude the lumens of several small capillaries. In two small areas necrosis and edema of the nerve fiber layer with hemorrhage into the retina and partial destruction of all layers internal to the pigment epithelium are found. The choroidal and retinal vessels are engorged, but no inflammatory lesions comparable to those in small arteries of other organs are detected.

*Brain:* Small areas of necrosis are numerous. These usually are characterized by hemorrhage and edema, some of which may be the result of operative trauma. However, several cortical and subcortical lesions show, in addition to hemorrhage and edema, a proliferation of glia cells, an infiltration with lymphocytes and monocytes and a proliferation of fibroblasts in the adventitia of small arteries. Acute thrombi are found in the lumens of occasional small vessels. A few lesions appear to be of several days duration. Other significant findings are occasional lymphocytes around small vessels in the medulla and pons and distinct small areas of myelin degeneration.

*Special Stains:* Numerous sections were stained by Wolbach's modification of the Giemsa stain and by the method of Gram-Weigert. These stains disclose no microorganisms that might be considered as etiological agents.

Sixty blocks of tissue from various organs were stained by Levaditi's method for the impregnation of spirochetes. In addition several blocks of cerebral tissue were treated by Jahnke's modification of the Levaditi and Manouélian method for the demonstration of *Treponema pallidum* in the brain and meninges. Only one section showed definite spirochetes although questionable forms appear in several sections. The spirochetes (Fig. 8) are located in the areas of necrosis and inflammation in the submucosa of the duodenum. They are morphologically consistent with *Treponema pallidum* and it seems justifiable to consider them as such.

*Anatomical Diagnoses:* Generalized syphilitic arteritis; multiple healed and acute arterial thrombi; acute and subacute infarcts of stomach, duodenum, ileum, colon, pancreas, liver, kidneys, adrenals, testes and brain; healed infarcts of pancreas, kidneys, adrenals and testes; localized acute and chronic peritonitis; bronchopneumonia; acute splenitis; chronic urethritis and prostatitis; fibrous perisplenitis and pleuritis; patent foramen ovale.

## DISCUSSION

Instances of widespread inflammatory lesions of small arteries and arterioles have been observed and reported from time to time. Dickson<sup>2</sup> in 1908 reviewed the literature and added a case which he had studied. He discussed the lesions under two headings — Periarteritis Nodosa and Polyarteritis Acuta Nodosa. Opinion as to etiology has differed, but Dickson, along with others, believed that the former group was due to syphilitic infection and the latter group to some unknown infection or toxemia other than syphilis. Longcope<sup>3</sup> the same year presented a case of periarteritis nodosa with an excellent clinical and pathological review of the disease. He pointed out the much greater frequency among males than females. Mott, who wrote the section "Arterial Degenerations and Diseases" in Allbutt and Rolleston's *System of Medicine*,<sup>4</sup> agreed on the whole with Dickson as regards etiology and pathology. He discussed syphilitic disease of the small arteries and arterioles under the heading of Periarteritis Nodosa. This author emphasized the widespread distribution of the lesions, the frequent involvement of the coronary arteries and the early onset during the syphilitic infection. Allbutt<sup>5</sup> is quite in agreement with Mott.

Warthin<sup>6</sup> stated that syphilis involves the small arteries quite frequently. There is a large literature dealing with the effects of the syphilitic virus on the blood vessels, but practically all discussions are confined to observations on the cerebral and coronary vessels or the aorta and its larger branches.

When one consults modern text-books on pathology, such as those by Boyd<sup>7</sup> and MacCallum<sup>8</sup> little is to be found concerning the effects of syphilis on the small arteries and arterioles. Boyd does not believe that syphilis is the etiological agent in periarteritis nodosa. He uses as an argument the facts that periarteritis nodosa is chiefly a disease of the muscular type of arteries, while syphilis primarily attacks the elastic type.

Most authors agree that in syphilitic arteritis and in so-called periarteritis nodosa all coats of an artery may be involved. Opinions, however, differ as to the place of attack of the virus. The generally accepted explanation is that the lesion primarily occurs in the larger arteries about the vasa vasorum and in the smaller arteries in relation to the perivascular lymph channels.

The case presented here is of much interest from several points of view. The multiplicity, character and distribution of the symptoms, together with a hypertension of recent development, indicated that the patient had some disease of the vascular system. Longcope<sup>3</sup> pointed out that these findings, together with a leukocytosis and fever, would suggest the diagnosis of periarteritis nodosa, even in the absence of superficial vascular nodules. The fact that the patient had been quite well until he contracted his syphilitic infection, which was of recent occurrence, made it seem probable that his illness was due to this infection. Mott<sup>4</sup> and again Allbutt<sup>5</sup> noted that the widespread involvement of the small arteries by the syphilitic virus occurred early in the course of the infection; usually during the secondary stage, although not infrequently during the late primary stage, and that the whole course of the illness was usually from a few weeks to months in duration. These observations were borne out in our case.

The gross examination of the organs of this patient yielded no clue which would allow diagnoses other than those of disseminated arteritis and multiple infarcts. The assumption at the time of the postmortem was that idiopathic periarteritis nodosa was the malady which would explain all findings in the most satisfactory manner. It was only after microscopic study that the diagnosis of syphilitic arteritis was made. The histological study disclosed inflammatory changes in the walls of small arteries and in the periarterial tissues. There were a few vessels which were affected by a relatively acute inflammation. Most of the lesions were chronic or healed. It was impossible to determine what part of the vascular wall was the original site of the infection. It seemed that the outer portion of the media and the adjacent adventitia were affected primarily. Fibrosis of the vessel walls was prominent. The partial or complete occlusion of the lumens of the arteries by concentric thickening of the intima and thrombosis resulted in the formation of numerous infarcts.

Inasmuch as periarteritis nodosa has not been established as an entity and because the term has come to be used as an opportune "label" for most instances of arteritis of unknown etiology, it seemed that certain features of the present case favored a diagnosis of syphilitic arteritis rather than periarteritis nodosa. In the first place, the patient had contracted syphilis a few months before the

onset of his fatal illness. Secondly, the appearance of severe signs and symptoms occurred during the period in which generalized syphilitic arteritis is most likely to occur. Thirdly, although the patient was treated promptly with arsphenamine and mercury, the therapy was interrupted for several weeks before the onset of serious symptoms. This lapse of therapy would allow for an intense exacerbation of the disease such as, according to Moore,<sup>9</sup> not infrequently occurs in the central nervous system in instances of primary or early secondary syphilis under similar circumstances. Fourthly, the histology was more compatible with syphilis than any other disease. Fifthly, spirochetes, which were indistinguishable from the *Treponema pallidum*, were found in an area of necrosis in the submucosa of the duodenum.

Generalized syphilitic involvement of the small arteries must be uncommon. This is the first case of this type recognized in this hospital. It is impossible to state why the vascular system should have been so vulnerable to the virus. Stokes<sup>10</sup> states that both arsphenamine and mercury are toxic to the walls of blood vessels. In this case treatment was instituted early and was intensive over a period of several months. It may be that this is an example of the "therapeutic paradox" following the use of arsphenamine. Stokes<sup>10</sup> believes that this is due to the too rapid healing of the lesions. He states that "closure of a partially obliterated coronary vessel or branch by edema at some spot of active gummatous arteritis, as in the Herxheimer flare-up, or rapid strangulation by too quick scar formation and healing, may produce death before any compensatory mechanism can come into play." It is conceivable that some such occurrence took place in the present case. Another explanation which has been offered, especially in instances of neurorecurrences of which this is an example, is that early intensive treatment may have prevented the natural development of adequate bodily defences against the virus and that the lapse of treatment permitted a severe exacerbation of the disease.

#### SUMMARY AND CONCLUSIONS

A case of widespread progressive chronic arteritis in a young adult with syphilis has been described. The small arteries were involved almost exclusively. All three coats of the vessels were in-



cluded frequently in the lesion. In most instances the vessels were occluded partially or completely, either by the marked thickening of their walls, by the formation of thrombi, or by a combination of the two processes. Infarcts of various organs often were present in regions where the most severe vascular lesions were found. The etiology of the arteritis has not been proved conclusively, but for several reasons cited in the discussion we believe it to be the virus of syphilis.

## REFERENCES

1. Connor, L. A. Development of knowledge concerning rôle of syphilis in cardiovascular disease. *J. A. M. A.*, 1934, **102**, 575-581.
2. Dickson, W. E. Polyarteritis acuta nodosa and periarteritis nodosa. *J. Path. & Bact.*, 1907-08, **12**, 31-56.
3. Longcope, W. T. Periarteritis nodosa, with report of a case with autopsy. *Bull. Ayer Clin. Lab., Pennsylvania Hosp.*, 1908, No. 5, 1-31.
4. Mott, F. W. Arterial degeneration and diseases. *System of Medicine*, Allbutt, C., and Rolleston, H. D. The Macmillan Company, London, 1909, **6**, 566.
5. Allbutt, T. C. Diseases of the Arteries, Including Angina Pectoris. The Macmillan Company, 1915, **2**, 200.
6. Warthin, A. S. Syphilis of the medium and smaller arteries. *New York M. J.*, 1922, **115**, 69-73.
7. Boyd, W. Pathology of Internal Diseases. Lea & Febiger, Philadelphia, 1931.
8. MacCallum, W. G. A Text-book of Pathology. W. B. Saunders Company, Philadelphia, 1932.
9. Moore, J. E. The relation of neurorecurrences to late syphilis. *Arch. Neurol. & Psychiat.*, 1929, **21**, 117-136.
10. Stokes, J. H. Modern Clinical Syphilology. W. B. Saunders Company, Philadelphia, 1926.

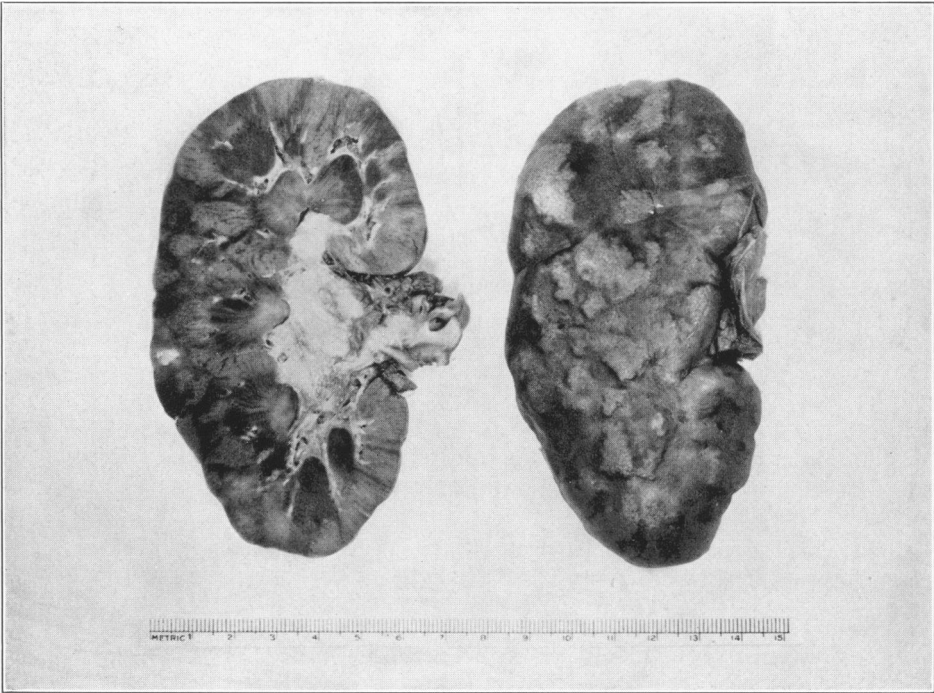
## DESCRIPTION OF PLATES

---

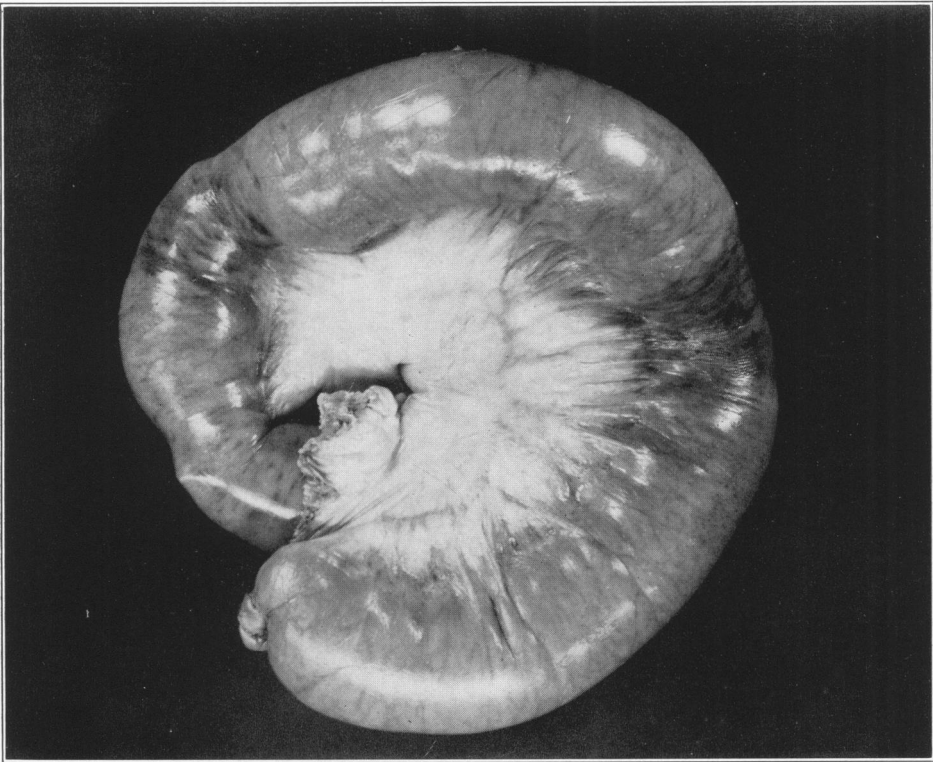
### PLATE 44

**FIG. 1.** Photograph of a coronal section of the kidney and of the external surface from which the capsule has been removed.

**FIG. 2.** Photograph of a distended segment of the ileum. Note the two areas of infarction.



I



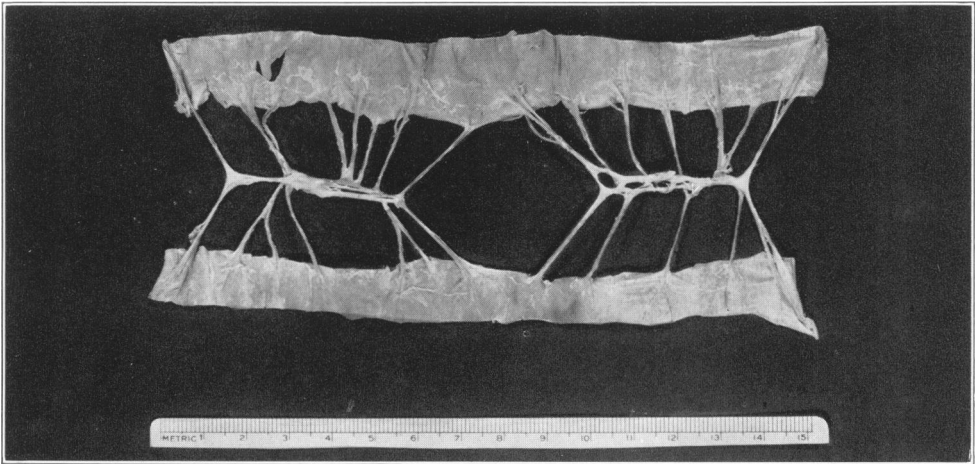
2

Derick and Hass

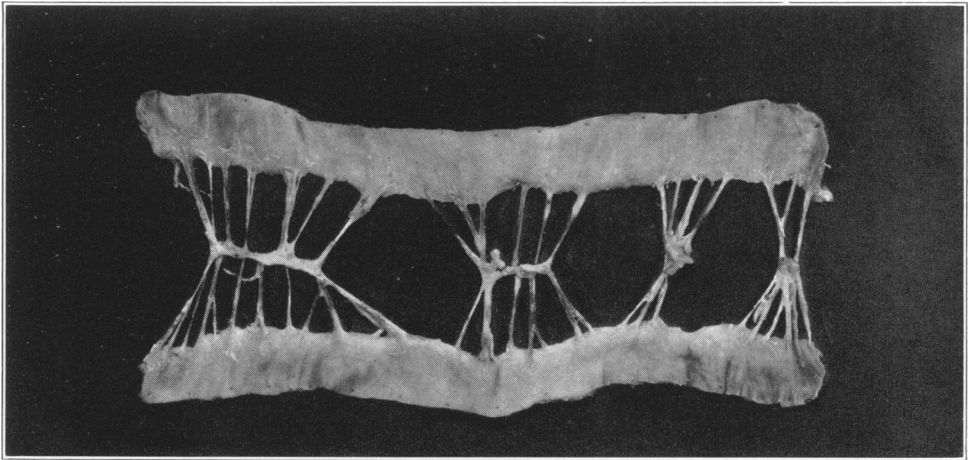
Diffuse Arteritis of Syphilitic Origin

PLATE 45

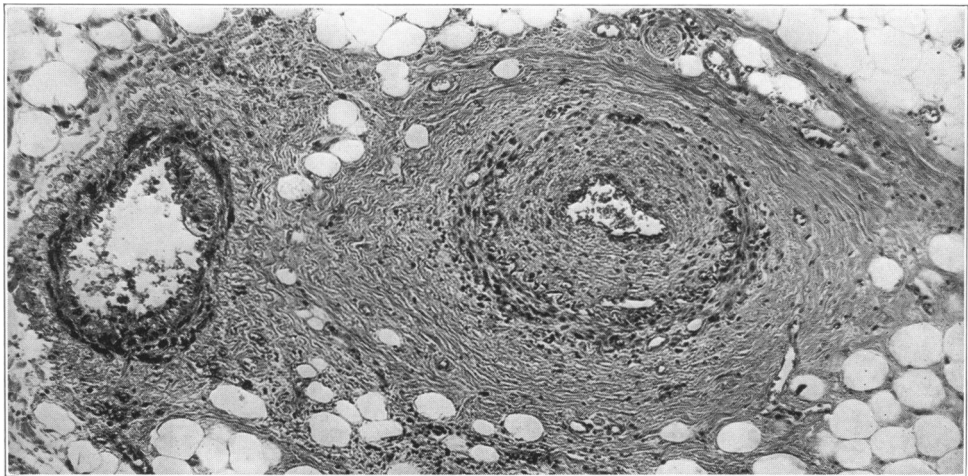
- FIG. 3. The specimen for this photograph was prepared in the following manner. A segment of a normal ileum was selected. A dissection of the terminal arcuate branches of the superior mesenteric artery was made. The ileum was then bisected in the plane of the mesentery and the divided halves of the wall spread out so as to show the paired arcuate branches in one plane.
- FIG. 4. The specimen for this photograph was selected from a portion of the ileum between the areas of infarction in the present case. It was prepared in the same manner as the normal ileum in Fig. 3. Note the increased opacity and thickness of parts of the arcuate arteries. This illustrates the scattered distribution of prominent lesions without true modosities or aneurysmal dilatations. The vessels from which these arteries arose were normal.
- FIG. 5. Photomicrograph of a thickened terminal arcuate artery (such as those in Fig. 4) and an accompanying vein. Note the fibrosis, vascularization and cellular infiltration in the media and adventitia. This also exemplifies the typical intimal proliferation with consequent narrowing of the vascular channel.  $\times 100$ .



3



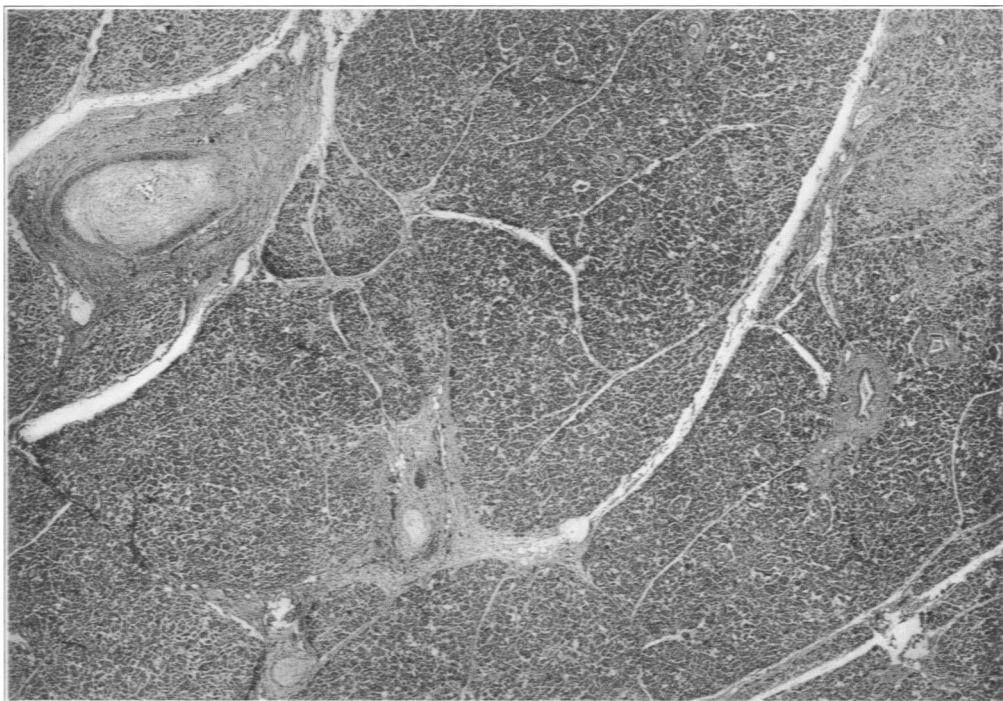
4



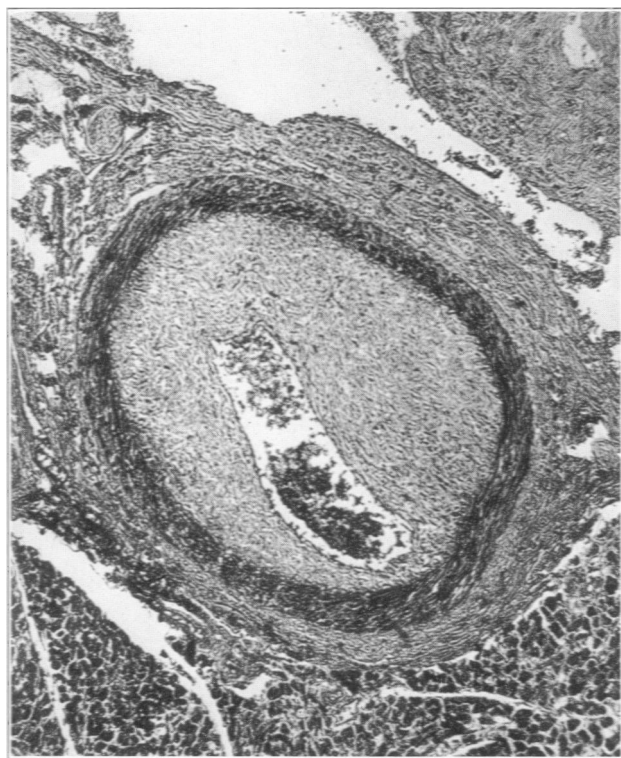5

PLATE 46

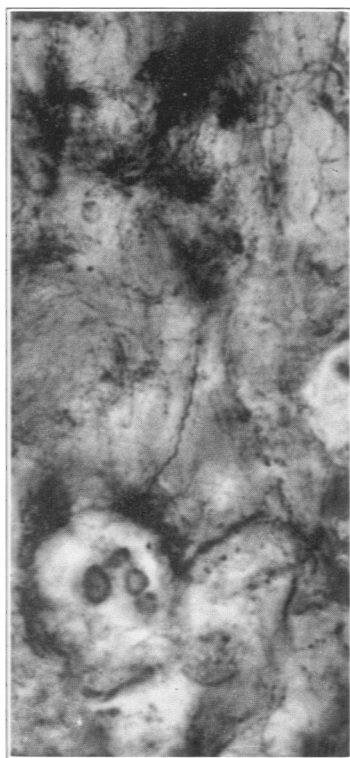
- FIG. 6. Photomicrograph of the pancreas. Note the extraordinary intimal proliferation in the large artery. The two small arteries are similar histologically to the arcuate artery in Fig. 5. A small area of parenchymal fibrosis is also included in the picture.  $\times 25$ .
- FIG. 7. Photomicrograph showing the type of lesion found in the large artery in Fig. 6. It illustrates the typical pathology of the largest vessels which were involved by the disease.  $\times 100$ .
- FIG. 8. Photomicrograph of one of the *Treponema pallidum* in the wall of the duodenum.  $\times 2000$ .



6



7



8