

## THE REGENERATION OF AUTOPLASTIC SPLENIC TRANSPLANTS \*

DAVID PERLA, M.D.

(From the Laboratory Division of Montefiore Hospital, New York City)

The first successful autotransplantation of splenic tissue in animals was made by Marine and Manley.<sup>1</sup> They found that subcutaneous or intramuscular splenic transplants in the rabbit were successful in almost 100 per cent of instances, and that immaturity of the animal was a powerful stimulus to the growth of the transplants. In immature rabbits with one-eighth of the spleen removed there was a slight growth of the transplant which increased rapidly following subsequent total splenectomy. They believed that this stimulus to growth was chemical in nature, because the grafts were removed from their normal neurovascular supply. The histology of the transplants was identical in all characteristics with normal spleen tissue. Spleen grafts, if made in immature rabbits accompanied by complete splenectomy, were permanent throughout the life of the animal. They further observed that although spleen transplants in rabbits were successful, in the absence of a physiological deficiency of spleen tissue they soon atrophied. When there was a definite splenic deficiency due to total splenectomy, autotransplants were not only successful but they grew and increased in size. In mature rabbits, whether splenectomized or not, the transplants regenerated but were slowly resorbed. From their observations they concluded that in the rabbit the spleen is most important in early life. After sexual maturity it is either unimportant or its function may readily be assumed by other hematopoietic tissues.

Subsequently Perla and Marmorston-Gottesman observed the regeneration of autoplasmic splenic transplants in the rat.<sup>2,3</sup> They found that such transplants in the adult rat regenerated and grew in over 90 per cent of instances, even in the presence of the spleen. In many instances it was further observed that the regenerated transplants may function in place of the normal spleen. As evidence of this it was found that in a strain of rats that developed *Bartonella muris* anemia after splenectomy, autoplasmic splenic transplants, performed 7 weeks prior to splenectomy, afforded protection against

\* Received for publication February 10, 1936.

this disease in more than 50 per cent of instances. A conspicuous difference was noted in the histology of the transplants that protected and those that did not protect the animal. In the protected rats the red pulp appeared normal and showed a large amount of phagocytosis of iron-containing pigment by the reticular cells and macrophages. In the transplants of the animals that died of *Bartonella muris* anemia only a few lymphoid cells were found in the red pulp. Many of the nuclei of the reticular cells showed evidence of necrosis. Only minute amounts of iron-containing pigment were found in the macrophages. The sinuses of the red pulp were engorged with blood. The follicles were sharply defined and showed no pathological change.

In the present communication the detailed histogenesis of autoplasmic splenic transplants is reported.

#### METHODS \*

In this work 24 mature albino rats free from *Bartonella muris* infection (Wistar stock), about 3 months of age, were used. The spleen was exposed through a small incision in the abdominal wall and one pole was gently pulled up into the opening. A piece was cut off for transplantation. Pieces of spleen about 6 mm. in diameter were immediately placed in small prepared pockets in the abdominal wall. Great care was exercised to avoid hemorrhage into these pockets, and if hemorrhage occurred a new pocket was made. The sites of the transplants were indicated by closing the mouth of the pocket with a black silk suture. The method of transplantation was essentially the same as that employed in the transplantation of thymus and lymph node tissue reported in previous communications by Marmorston-Gottesman and Jaffe.<sup>4,5</sup> Four transplants were usually inserted in each animal. Two rats each were killed at intervals of 2, 18, 24 and 36 hours, and 3, 4, 5, 6, 7, 12, 21 days and 7 weeks after operation. The transplants were carefully removed, fixed in Bouin's fluid, and embedded in paraffin. Sections were stained with hematoxylin-eosin, Verhoeff's elastic tissue stain, Pacini's stain, and by Bielschowsky's silver impregnation method.

\* I am indebted to Dr. Jessie Marmorston for surgical assistance in the transplantations.

## PRESENTATION OF DATA

This study is based on an examination of 96 splenic transplants. A description of the successive stages of degeneration, regeneration and growth of the transplants follows.

*2 Hours:* Only at the cut edge of the splenic transplant is there evidence of necrosis in the splenic tissue. In the remaining tissue the cells are intact, the architecture clear. In the muscle surrounding the transplant there is little cellular reaction to its presence. The cytoplasm of the surrounding muscle fibers is swollen and shows granular degeneration.

*15 Hours:* There is evidence of necrosis throughout the entire transplant except for a thin outer zone of viable tissue. This zone shows well formed lymphocytes and reticular cells. The rest of the transplant architecture is poorly defined. The nuclear elements show various stages of karyorrhexis. In some sections extensive hemorrhage is present in and about the transplant. The surrounding tissue contains many polymorphonuclear leukocytes, very few mononuclear phagocytes but a considerable amount of edematous fluid.

*24 Hours:* The transplant is infiltrated with blood. There is an extensive necrosis of the entire splenic tissue except for a narrow zone where a layer of well defined cells is present, at the outer margin of the transplant. Fragments of nuclear elements are present throughout. The surrounding tissue is edematous and is infiltrated with many polymorphonuclear leukocytes and a few mononuclear phagocytes.

*36 Hours:* In some areas a portion of the splenic capsule is still preserved, and just beneath the capsule within the transplant reticular cells, lymphocytes and well formed sinuses are seen. There are small areas of hemorrhage and erythrophagocytosis by macrophages is seen. There is a zone of apparently viable reticular cells at the periphery which merges with the necrotic tissue that occupies the rest of the transplant. In many areas the entire architecture of the splenic tissue is destroyed. Nuclear fragments, cellular debris and many red blood cells and polymorphonuclear leukocytes are present within the transplant. In these areas lymphocytes and reticular and endothelial cells in all stages of degeneration are visible. The

blood vessels are included in the massive necrosis which is seen in the transplant.

The reticulum and collagen fibrils within the area of necrosis are not distinguishable. A few elastic fibers are still present in the connective tissue septa of the transplant. The remnant of capsule around it contains some elastic tissue. That of the small arterioles throughout the transplant is destroyed.

Around the periphery of the transplant the tissue is edematous, and phagocytic macrophages, many of which have engulfed debris and red blood cells, are present in large numbers. Occasional polymorphonuclear leukocytes are seen and a zone of young fibroblasts surrounds the transplant.

*48 Hours:* In the central portions of the transplant the splenic tissue is destroyed. The site of the malpighian corpuscles is discernible but the cells show all stages of degeneration. Throughout most of this area the reticular and endothelial cells are necrotic. In many places they are swollen and show evidence of erythrophagocytosis.

At the periphery of the transplant and beneath the remnant of the capsule numerous reticular-like elements are present. These appear to be growing into the transplant (see Fig. 1). The cytoplasm of these cells forms an irregular syncytium. Red cells are present in ill defined vascular spaces in this zone, but few lymphocytes are seen. The reticulum of the capsule of the transplant is sharply defined and in the tissue surrounding the latter the capillaries are congested, areas of hemorrhage are seen, and many polymorphonuclear leukocytes and phagocytic macrophages containing ingested red blood cells are present.

*3 Days:* In larger transplants the outer half is completely replaced by a mesh of syncytial reticular cells which surrounds and invades the central area of necrotic tissue with finger-like projections.

In one small transplant the reticular cells have regenerated and have almost completely overgrown the transplant. It is completely replaced by what appear to be reticular cells (see Fig. 2). There are few lymphocytes present. The fibrillar and cellular reticulum has formed a mesh of sinuses which gives it a honeycomb appearance. These sinuses are lined with flattened endothelium and

in places it is apparently proliferating and large cells lie free in the sinuses. In other areas several of these cells have fused to form irregular multinuclear giant cells. In reticular and endothelial cells the cytoplasm is scanty and vacuolated. The nuclei are large, pale and vesiculated, and contain finely scattered chromatin material. The cytoplasmic processes anastomose with those of surrounding cells. The fibrillar reticulum can be traced about the sinuses, weaving an interlacing mesh throughout the transplant.

In larger transplants the formation of sinuses has not as yet occurred, although capillaries containing blood cells are present.

*4 Days:* A wide outer zone of the transplant shows large numbers of reticular cells, some of which contain mitotic figures. Their cytoplasm forms a loose syncytial mass penetrating the inner portions of the transplant. Some of these cells contain iron pigment. There are no lymphocytes in this outer zone but there are many red blood cells which lie in irregular, poorly defined sinusoidal spaces. Elliptical endothelial cells, apparently arising from the reticular cells, line the irregular blood spaces in some places. The formation of new fibrillar reticulum forming primitive sinuses within the outer zone can be distinguished. In one area a large mass of reticular cells is arranged in a concentrically lamellated whorl about a capillary space and a few elements resembling small lymphocytes are found in the interstices of this tissue. The reticular fibrils penetrate the outer portion of what appears to be a primitive follicle (see Fig. 3).

In the center of the transplant there is a small area of necrosis, surrounded by a broad zone of mononuclear phagocytes, containing nuclear debris, red blood cells and hemosiderin. Numerous fibroblasts are seen about the transplant and in some areas they seem to invade it. This does not occur in the zones covered by transplanted splenic capsule. The connective tissue of the capsule and the reticulum in the outer zone of the plant is clearly defined. Extending from the capsule are connective tissue septa in the process of formation.

*5 Days:* There is still a central area of necrosis with a zone of hemorrhage. The outer half of the transplant shows complete regeneration. A partly developed follicle close to an arteriole can be seen. All stages of lymphoid cell formation are visible. The reticular cells

vary considerably in size and shape, and transition forms between large, oval reticular cells and fully developed lymphocytes may be distinguished.

The reticular fibrils in the regenerated part of the transplant form a fine pattern of sinuses. In one area a prominent and well formed arteriole lies in the center of a follicle. The elastica of the wall is fully developed.

The connective tissue of the capsule is clearly defined. The connective tissue septa are present, extending into the transplant. Scattered outside of its capsule are reticular cells, lymphocytes, occasional polymorphonuclear leukocytes and mononuclear macrophages containing blood pigment.

*6 Days:* The transplant presents a remarkable picture. There is a small central area of necrosis. Within this area are ghosts of large cells containing blood pigment but showing evidence of degeneration. The necrotic zone merges imperceptibly with a zone of loosely arranged, large mononuclear cells containing large amounts of blood pigment. These large reticular-like elements gradually become more compact as the outer portion of the transplant is approached. An occasional well formed arteriole is seen in this area. The outer two thirds of the transplant show fully regenerated splenic tissue. Sinuses containing red blood cells are present. Reticular and endothelial cells are rich in blood pigment. Lymphocytes, although scattered through the pulp, accumulate more prominently in some areas where follicle formation is apparently occurring. Cells suggesting transition forms between large oval reticular cells and fully developed lymphocytes may be distinguished.

Within a primitive follicle a small arteriole seems to be in the process of formation. The outer portion is composed of whorls of flattened reticular-like cells with elliptical nuclei. The inner portion of the structure consists of a syncytium of large, pale, reticular elements with pale staining cytoplasm. The lumen is not definitely seen. A well defined zone of fibrillar reticulum is discernible in the outer portion of the wall. Another arteriole shows a later stage with more definite lumen formation. The connective tissue of the media is more deeply stained and condensed. The lumen contains red blood cells and is lined with a syncytium of large, vesiculated endothelial cells. The transplant has a well defined capsule which sharply separates it from the surrounding tissue. Surrounding the

transplant, outside of the capsule, is a fibrillar connective tissue structure containing macrophages rich in blood pigment. In one area in direct contiguity with the capsule, but outside of it, there is a large cluster of reticular cells arranged in a concentric whorl showing evidence of follicle formation and containing various transition forms between reticular cells and lymphocytes.

*7 Days:* There is no area of central necrosis. The entire inner two-thirds of the transplant is completely replaced by a loose syncytium of reticular cells. Many of these cells in this zone and in the outer zone contain a large quantity of blood pigment. In the outer third of the transplant, in addition to the syncytial mass of reticular elements, there are several well defined follicles with lymphocyte formation. Cells suggesting all stages of lymphoid cell formation from large reticular cells to lymphocytes are present. An occasional normoblast may be seen. A large arteriole in the process of formation is evident in one area. The lumen is lined by flattened endothelial cells and about this is a loosely arranged whorl of reticular cells.

The sinuses in the outer zone are not so clearly defined as in some of the other transplants, but where they occur they are markedly distended with blood. The capsule is composed of dense collagen fibrils and well defined trabeculae extend from the capsule into the transplant.

*12 Days:* The transplant is replaced by large numbers of reticular cells. Sinuses containing blood elements are distinguishable. In the outer third are scattered lymphocytes. Veins and arterioles are present. In one area close to a newly formed arteriole there is a clump of modified reticular cells which are round and vesiculated, but their nuclei contain more condensed chromatin masses than are found in reticular cells. They appear to be lymphoblastic cells. Cellular elements suggesting gradations from these to adult lymphocytes may be distinguished. Many pigment-laden mononuclear macrophages are present in the transplant. It is demarcated by a definite capsule containing collagen fibers. The surrounding tissue contains a few polymorphonuclear leukocytes and large macrophages laden with iron pigment.

*21 Days:* The transplant shows evidence of complete regeneration with the formation of a capsule and trabeculae. Foci of lymphocytes surround the arterioles and suggest follicle formation. Well formed

sinuses are present and these are congested. There is evidence of erythrophagocytosis by macrophages. Occasional megakaryocytes are seen in the red pulp.

*7 Weeks:* The transplant is a small spleen about 1.5 cm. in diameter. The elements are completely differentiated. The splenic follicles and the blood sinuses, with the normal red pulp elements, including megakaryocytes, are present. Blood pigment is present within the macrophages and reticular and endothelial cells (see Fig. 4).

#### DISCUSSION

The phylogenetic and ontogenetic development of the spleen may be simulated in the adult rat in the regeneration of autoplasmic transplants of fragments of splenic tissue within a few days. The observations reported in this communication suggest that the reticular cells of the adult spleen retain their potentiality for differentiation and that they may be the precursor of the structural cellular elements of the spleen. These studies further suggest that the lymphoblastic tissue may arise from the reticular cell.

Phylogenetically it appears that the entire pulp of the spleen (red and white) develops from a common ancestral mesenchymal reticulum. In certain lower vertebrates, as in fish and amphibia, there is no distinction between the malpighian corpuscles and the red pulp. In the selachians, reptiles and birds, the lymphatic follicles become prominent and stand out against the vascular pulp, but masses of lymphocytes are scattered throughout the red pulp (Klemperer<sup>6</sup>). In the human, the spleen arises embryologically in the dorsal mesogastrium from a group of round cells which appear cytologically identical with those of the surrounding mesenchyme but are more compact. During the early phase of its development the undifferentiated mesenchyme increases in amount and forms a rich vascular network. Later the pulp reticulum, venous sinuses, arterial sheaths and lymphatic tissue develop. At 8 weeks the mesenchymal cells are surrounded by delicate fibers (Ono<sup>7</sup>). In the 3rd month a capsule and trabeculae develop. During the 5th month a vascular bed develops by separation, loosening and rearrangement of the reticular cells. The venous sinuses consist of delicate endothelial-lined tubes apparently continuous with the primary embryonal plexus of veins. At this time hematopoiesis is observed in the growing spleen.



Hemocytoblasts separate from the fixed mesenchymal cells. These differentiate into erythroblasts. After the 5th month this process decreases and is practically absent in the 6th month (Ono).

According to Ono, the development of the lymphatic tissue is associated with the formation of the arterial system. When the branches of the splenic artery acquire a muscular wall during the 4th month, they become surrounded by a mantle of reticular tissue. Early in the 5th month within these areas accumulations of lymphoid cells appear which separate themselves from the surrounding reticular cells. The follicles develop during the 5th and 6th month within the angles of the arterial tree. The vascular network of the follicles is fully developed at the end of fetal life.

From the study reported in the present communication it is evident that the histogenesis of the splenic elements in the regeneration of the autoplasmic transplants repeats the ontogenetic development of the spleen and suggests that the major elements of this organ have a common origin in the mesenchymal reticulum.

It is striking that the developmental potentiality of the reticular cell is retained in adult life in the rat and that regeneration of splenic autotransplants readily occurs even in the presence of most of the spleen.

A comparison of the regeneration of thymus autoplasmic transplants<sup>4</sup> and of lymph node transplants<sup>5</sup> with that of splenic tissue reveals the fact that the reticular cell in each case is the common ancestral cell of the structural elements subsequently found in the fully regenerated tissue. Morphologically the reticular cells of the lymph node, thymus and spleen transplants which survive in the extreme outer zone are apparently identical, and are closely related in their capacity to form lymphoid tissue and in the property of phagocytosis. But in each instance they must possess some specific growth trend different from the reticular elements of other organs.

#### SUMMARY AND CONCLUSION

The histogenetic development of the regeneration of autoplasmic splenic transplants was studied in a series of adult albino rats. It was found that the transplanted splenic tissue undergoes rapid degeneration within the first 24 hours. A thin zone of viable reticular cells survives. There is little inflammatory reaction about the

transplant. By the 3rd day there is marked proliferation of the reticular cells at the outer zone and streamers of cells are seen penetrating the necrotic center of the transplant. In some instances the entire transplant is replaced by reticular cells which have formed the pattern of a sinus organ. By the 3rd or 4th day lymphocytes appear irregularly in clusters and apparently all stages of lymphoid cell formation are observed.

By the 6th day the outer two-thirds of the transplant are replaced by reticular elements arranged in an intricate mesh as in the adult spleen, with sinus formation, and ill defined clusters of lymphocytes are present. Complete regeneration of large transplants occurs from the 12th to the 21st day and the morphological structure of adult spleen tissue is apparent, with well developed capsule and trabeculae.

These studies suggest that the reticular cell of the adult spleen retains its potentiality for differentiation and may be the precursor of the structural elements of the spleen.

ADDENDUM: Some months after this work had been completed a report on the behavior of transplanted spleen by Silberberg appeared (*Arch. Path.*, 1935, 20, 216). In autotransplantation of splenic tissue he also observed complete regeneration in 16 to 21 days. He finds the reticular cells the most resistant to necrosis but does not commit himself with reference to the transformation of these cells to lymphoblastic tissue.

#### REFERENCES

1. Marine, David, and Manley, O. T. Homeotransplantation and autotransplantation of the spleen in rabbits. III. Further data on growth, permanence, effect of age, and partial or complete removal of the spleen. *J. Exper. Med.*, 1920, 32, 113-133.
2. Perla, David, and Marmorston-Gottesman, J. Further studies on *T. Lewisi* infection in albino rats. I. The effect of splenectomy on *T. Lewisi* infection in albino rats and the protective action of splenic autotransplants. II. The effect of thymectomy and bilateral gonadectomy on *T. Lewisi* infection in albino rats. *J. Exper. Med.*, 1930, 52, 601-616.
3. Perla, David, and Marmorston-Gottesman, J. Studies on *Bartonella muris* anemia of albino rats. III. The protective effect of autoplasmic splenic transplants on the *Bartonella muris* anemia of splenectomized rats. *J. Exper. Med.*, 1930, 52, 131-143.
4. Gottesman, Jessie M., and Jaffe, Henry L. Studies on the histogenesis of autoplasmic thymus transplantations. *J. Exper. Med.*, 1926, 43, 403-413.

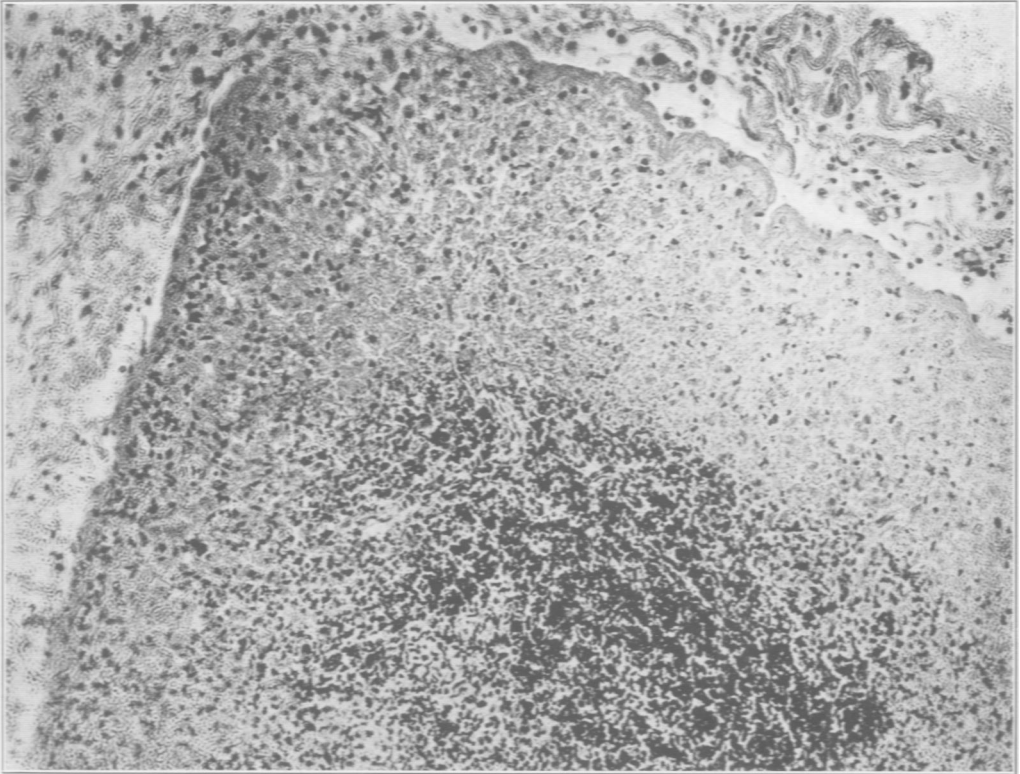
5. Marmorston-Gottesman, J., and Gottesman, J. Autoplastic lymph node and thymus transplants. Comparative studies. *Arch. Path.*, 1928, **6**, 406-417.
6. Klemperer, P. The spleen. Handbook of Hematology, Downey, H. Paul Hoeber, New York. (In press.)
7. Ono, Kosaku. Untersuchungen über die Entwicklung der menschlichen Milz. *Ztschr. f. Zellforsch. u. mikr. Anat.*, 1930, **10**, 573-603.
8. Thiel, Geo. A., and Downey, Hal. The development of the mammalian spleen, with special reference to its hematopoietic activity. *Am. J. Anat.*, 1921, **28**, 279-333.

## DESCRIPTION OF PLATES

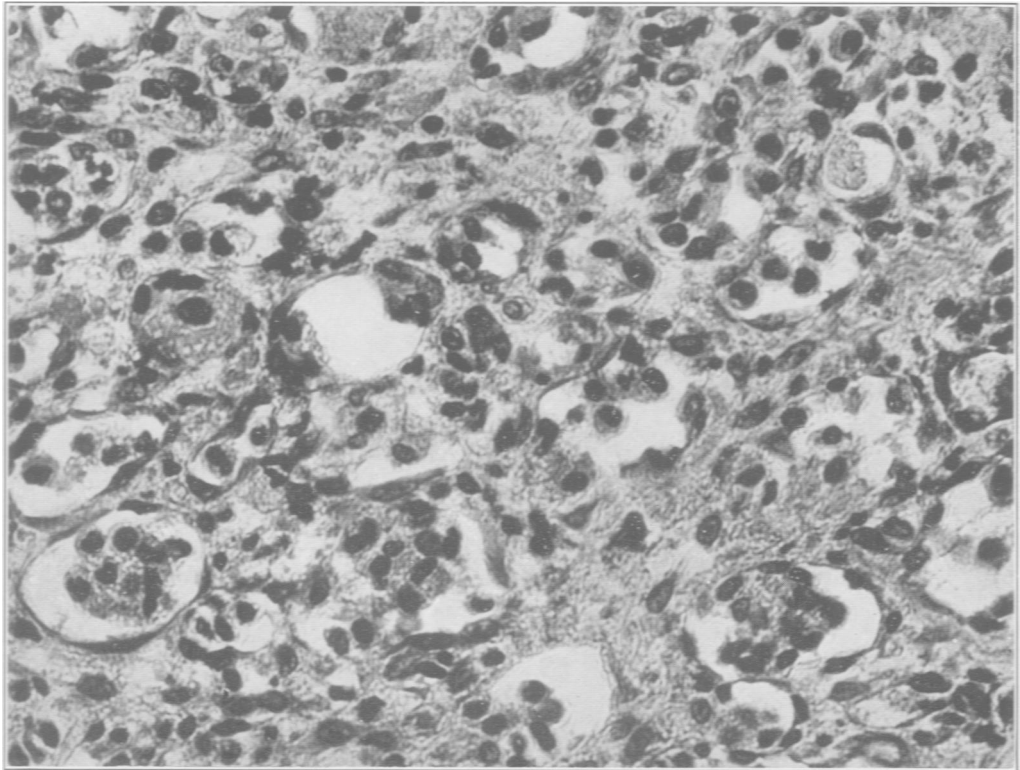
---

### PLATE 121

- FIG. 1. Autoplastic splenic transplant, 48 hours. Necrosis of inner portion of the transplant. Outer zone contains numerous reticular cells growing into the transplant and a few scattered lymphocytes. Hematoxylin and eosin stain.  $\times 100$ .
- FIG. 2. Autoplastic splenic transplants, 3 days. Small transplant showing complete replacement by reticular cells and sinuses. Few lymphocytes present. Numerous sinusoidal structures lined with flattened endothelium. In some sinuses endothelial cells are present in the lumens. The reticular cells fill the intersinusoid spaces. Hematoxylin and eosin stain.  $\times 440$ .



1



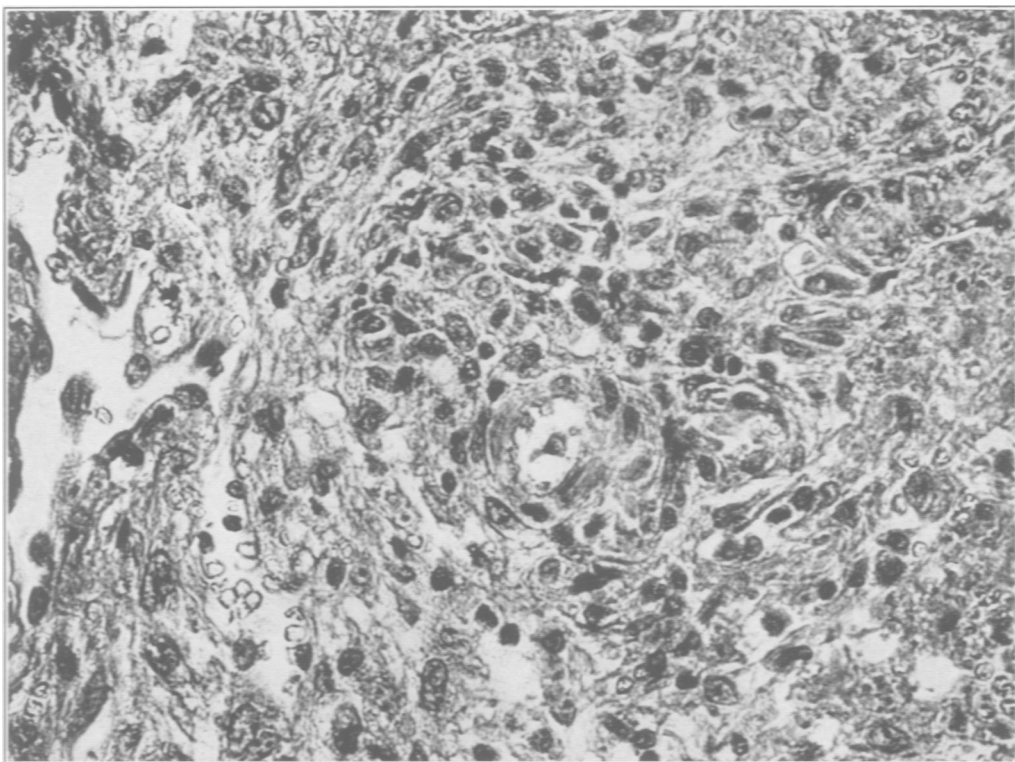
2

Perla

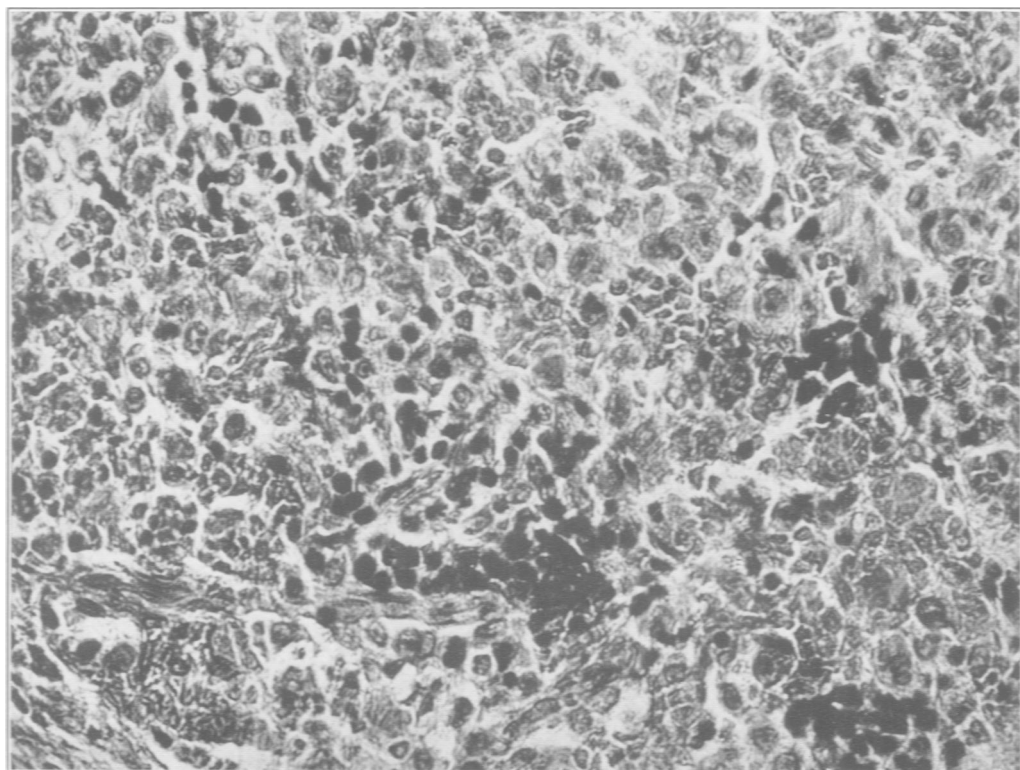
Regeneration of Autoplastic Splenic Transplants

PLATE 122

- FIG. 3. Autoplastic splenic transplant, 4 days. Area showing early follicle formation. The reticular cells are arranged in a concentrically lamellated whorl about a capillary. A few lymphocytes are present within this primitive lymph follicle. Hematoxylin and eosin stain.  $\times 440$ .
- FIG. 4. Autoplastic splenic transplant, 7 weeks. Completely regenerated transplant showing adult splenic structure. Note presence of megakaryocytes in the pulp. Hematoxylin and eosin stain.  $\times 240$ .



3



4

Perla

Regeneration of Autoplastic Splenic Transplants