

## BLASTOMYCOSIS OF THE HEART \*

### REPORT OF TWO CASES

ROGER D. BAKER, M.D., AND EARL W. BRIAN, M.D.

*(From the Department of Pathology, Duke University School of Medicine, and the Duke Hospital, Durham, N. C.)*

Publications regarding generalized blastomycosis are sufficiently numerous to make the broad features of the disease well known. From the anatomical approach it remains to define the reaction in various organs and to study the spread of the process in the body, as has been done for example in tuberculosis. Moreover, a comparison between tuberculosis and blastomycosis regarding cardiac involvement is of interest because of the similarity of the two diseases.

Two authors have dealt specifically with blastomycosis of the heart. LeCount<sup>1</sup> described a case of generalized blastomycosis showing miliary nodules in the epicardium. He believed that dissemination to the epicardium had occurred by retrograde extension along the lymph channels from the blastomycotic lymph nodes at the base of the heart. Hurley's<sup>2</sup> case, also with generalized involvement, had a sinus extending from the pericardial cavity to the body surface. One lesion extended 1.5 cm. into the wall of the greatly hypertrophied left ventricle. Two other large lesions extended through the right atrium and presented minute endocardial nodules and sinuses, which had evidently been discharging into the blood stream. The lungs contained extremely numerous, minute lesions "seeded" by the blood stream. During the patient's illness "there was evidence of cardiac disturbance, but this was a minor feature."

Several other authors have referred to cardiac blastomycosis in case reports and reviews of generalized blastomycosis. Cleary<sup>3</sup> found minute blastomycotic tubercles "in the myocardium and spleen in the histological examination of these organs," and one of the myocardial tubercles was shown in the illustrations of his paper. Case 1 of Coupal's series<sup>4</sup> showed a smooth and glistening epicardium, beneath which there was an abscess 2 by 1 cm. in the left ventricle. A few, isolated yellowish abscesses, 1 to 2 mm. in diame-

\* Presented at the meeting of the American Association of Pathologists and Bacteriologists, Boston, Mass., April 9, 1936.

Received for publication July 24, 1936.

ter, occurred on the left auricular wall. Sections showed enormous numbers of organisms. Medlar<sup>5</sup> wrote regarding a case: "The heart shows a small tubercle composed entirely of mononuclear leukocytes with three yeast-like bodies present." Blastomycotic infections of the pericardial cavity, apparently without involvement of the myocardium and endocardium, were reported by Churchill and Stober,<sup>6</sup> and by Howes and Morse.<sup>7</sup>

The 2 following cases of cardiac blastomycosis in generalized forms of the infection have several features in common. Pericardial blastomycosis with involvement of the right atrial musculature and endocardium, miliary pulmonary blastomycosis, and evidences of cardiac insufficiency occurred in both. Only the data bearing on the cardiac lesions, the spread of the infection to and from the heart, and the impairment of cardiac function are included in the reports.

#### CASE REPORTS

CASE 1. *Clinical History:* S. D., a male negro 17 years of age, developed a painless swelling below the left nipple 2 years before death. Incision yielded pus and the wound resulted in sinus formation. Later several more sinuses appeared. One year before death he developed a cough productive of yellow, blood-streaked sputum. Loss of weight occurred. Dullness and râles were present over the left lower chest. The heart was normal on physical examination. On culture *Blastomyces dermatitidis* was obtained from the pus and the sputum. Throughout the patient's course of 9 months in the hospital his temperature averaged about 38° C. Tachycardia (110 to 120 beats per minute) and tachypnea were present. An electrocardiogram made 5 weeks before death showed tachycardia, but no other abnormality. X-ray films demonstrated miliary nodules throughout both lungs, but no cardiac abnormality. During the last 2 months of life edema of the dependent parts of the body, cyanosis and increasing dyspnea were present. Two days before death the hemoglobin was 13 gm. per 100 cc. of blood (82 per cent Sahli), red blood cells 5,590,000, and leukocytes 13,500 per cmm. of blood. Clinical studies of the blood proteins were not made.

#### *Postmortem Examination*

At autopsy several ulcers with underlying abscesses were noted in the left lower chest wall. These lesions communicated with subcutaneous sinuses and with several ribs. The peritoneal cavity contained 600 cc. of cloudy fluid, and the right pleural cavity 450 cc. The left pleural cavity was obliterated by fibrous adhesions.

The pericardial sac was densely adherent to the left pleura and lung. The pericardial cavity was obliterated except for a pocket which contained pus and partially encircled the base of the heart. The enlarged mediastinal lymph nodes contained an occasional tiny nodule.

The heart could not be weighed because of the adherent pericardium and diaphragm. It appeared to be slightly enlarged, owing to dilatation of the ventricles. The left ventricle measured 1 cm. in thickness and the right ventricle 0.7 cm. Multiple sections through the myocardium showed no lesions, except in the right atrium.

A firm nodule, 2.5 cm. in diameter, projected into the atrium, reducing the diameter of the latter and compressing the auricular appendage. The surface of the nodule presented smaller elevations, also ulcers, the largest of which was 0.5 cm. in diameter and had rounded margins. The cut surface of the lesion presented yellow and gray areas. The nodule was continuous with similar tissue lining the pericardial pocket.

The cardiac valves appeared normal.

The lower lobe of the left lung (Fig. 1) contained nodules 0.5 cm. in diameter. Throughout both lungs there were miliary tubercles 1 mm. or less in diameter, with a uniform distribution similar to that seen in hematogenous miliary tuberculosis of the lungs.

The liver weighed 1400 gm. and presented the accentuated lobular pattern of chronic passive congestion. The spleen weighed 150 gm.

#### *Microscopic Examination*

Immediately beneath the inner surface of the nodule in the wall of the right atrium lie caseous areas containing blastomycetes. A crater has formed and is lined by tissue rich in these yeasts. Here the incoming blood apparently flowed over the ulcer. The nodule (Fig. 2) shows caseous areas interspersed with connective tissue and granulation tissue. Polymorphonuclear leukocytes are practically absent. Blastomycetes are numerous inside and outside giant cells of the granulation tissue.

Elastic tissue stains allow one to trace the elastic tissue of the adjacent normal endocardium into the caseous nodule. The presence of blastomycotic granulation tissue superficial to the strands of elastic tissue extending into the nodule indicates that the lesion lies in part on the original endocardial surface. At some points the endocardial elastic tissue has been destroyed. In addition to the definite ulcer already mentioned there are irregularities in the surface and projecting flaps of tissue, indicating surface erosion. Some of this may be artifact, but the presence of hyaline material lining the defects suggests that the irregularities existed during life. Some of the

crevices between trabeculae in the endocardium adjacent to the lesion contain organizing thrombi. No bacteria, including acid-fast organisms, could be stained in the lesion or thrombus.

The ramifying pericardial pocket is lined by tissue similar to that composing the nodule. The myocardium contains no blastomycotic tubercles.

The lower lobe of the left lung shows extensive fibrosis continuous with that of the pleura. Throughout both lungs tubercles are scattered which do not occur in relation to bronchi or bronchioles. Blastomycosis of the latter air passages is not noted. The hilum lymph nodes are hyperplastic. One contains an old fibrous blastomycotic nodule. Miliary tubercles in organs other than the lungs are not found. Chronic passive congestion and central necrosis of the liver are present.

*Summary:* Multiple draining blastomycotic sinuses in left thoracic wall; blastomycotic osteomyelitis of left ribs; obliteration of left pleural cavity by fibrous adhesions; fibrosing pulmonary blastomycosis of left lower lobe; scarred blastomycotic tubercles in mediastinal lymph nodes; blastomycotic pericarditis; blastomycotic tubercle in wall of left atrium with extension through endocardium; disseminated blastomycotic tubercles in both lungs; blastomycotic subdiaphragmatic abscess; dilatation of cardiac ventricles; chronic passive congestion of liver; hydrothorax, right (450 cc.); ascites (600 cc.); and hyperplasia of femur marrow.

*CASE 2. Clinical History:* R. H., a male negro 24 years of age, developed a subcutaneous abscess between the shoulder blades 13 months before death. This was incised and yielded bloody pus from which *Blastomyces dermatitidis* was grown. Other similar abscesses formed. The course in the hospital during the last month of the patient's life was characterized by cough productive of a little mucoid material, night sweats, moderate fever, loss of weight and dyspnea. The dyspnea was a distressing symptom terminally. He had persistent tachycardia of 120 to 140 beats per minute. The cardiac impulse seemed to be in normal position. An extra-systole occurred occasionally. A faint systolic blow was heard over the entire precordium. X-ray films showed uniform mottling in both upper lobes of the lungs. Three days before death the hemoglobin was 12 gm., and the red blood cells numbered 4,460,000 per cmm. Clinical studies of blood proteins were not made.

#### *Postmortem Examination*

The abdominal cavity contained 500 cc. of clear fluid, the left pleural cavity 1650 cc., and the right pleural cavity 500 cc. The

pleural surfaces were covered with a fibrinous exudate. The right lung had many adhesions, particularly with the mediastinum and pericardium.

The parietal pericardium was thickened and adherent to the pleurae to a greater extent than normal. No firm adhesion, however, was noted between the pericardium and the sternum. The pericardial cavity was obliterated except for several accumulations of yellow pus and caseous material. The total amount of pus was about 25 cc.

Mediastinal lymph nodes showing abscesses and caseation were adherent to the pericardium, but no point of rupture from them into the pericardial cavity could be demonstrated. However, a probe could be passed from a pericardial pocket into an encapsulated mediastinal pocket.

The heart could not be weighed because of the adhesions. It was estimated to be slightly heavier than normal.

Section through the heart (Fig. 3) showed that the pericardial blastomycosis extended into the myocardium in some places. In the region of the right auricular appendage, for example, a caseous lesion 1.5 cm. in diameter extended through the atrial myocardium and presented on the endocardium with a smooth surface. Small nodules projected beyond the endocardial surface of the lesion. The cavity of the right ventricle was dilated and the wall hypertrophied, measuring 0.8 cm. in thickness. The left ventricular wall measured 1.3 cm. in thickness.

Multiple sections less than 1 cm. apart through the whole heart failed to show myocardial lesions which might have developed there primarily and not from the pericardium. The coronary arteries were surrounded and possibly compressed by the epicardial blastomycosis. The valves appeared normal.

The lungs were compressed by the pleural fluid. The right lower lobe showed old scarring. In both lungs uniformly scattered blastomycotic tubercles 1-2 mm. in diameter were noted. The liver weighed 1700 gm. The lobular markings were accentuated. The spleen weighed 300 gm.

#### *Microscopic Examination*

The lesion in the wall of the right atrium is composed of necrotic, partially liquefied tissue containing numerous blastomycetes and

comparatively few polymorphonuclear neutrophils. The edge of the lesion shows necrosis and granulation tissue. Blastomycetes usually within giant cells are noted. Tubercle formation occurs.

The lesion extending into the endocardium consists of lymphocytic and large mononuclear cell infiltrations and some proliferating fibrous tissue. The endothelium cannot be followed across the surface, and it appears that part of the lesion was in contact with circulating blood. This appearance is not an artifact, caused possibly by the rubbing off of the free surface of the nodule, for a similar appearance is noted in the protected crevices between the muscular trabeculae. Blastomycetes occur in giant cells just beneath the surface. There is an organizing thrombus on the free surface of the lesion, close to a trabecula. No bacteria, including acid-fast organisms, could be stained in the thrombus or the underlying lesion.

Elastic tissue staining impregnates the elastic fibers in the endocardium and demonstrates that the endocardial lesion lies not only in the endocardium but on its free inner surface as well.

Smaller lesions similar to the large one are noted in the epicardium and in the original pericardial cavity. One of these comes close to a coronary vein but does not communicate with it.

Sections from the ventricles fail to show isolated miliary lesions in the myocardium.

All sections of lungs show minute tubercles containing giant cells and blastomycetes. A moderate amount of edema is noted. The left lung is atelectatic owing to the pleural fluid. The pleural exudate contains blastomycetes but no bacteria. Blastomycotic tubercles of miliary size, such as might have come from a recent dissemination of organisms in the extrapulmonic blood stream, are not seen, with the possible exception of one minute hepatic nodule which contains no blastomycetes. The liver and spleen show extreme congestion. The liver also shows central necrosis.

*Summary:* Generalized blastomycosis involving the lungs, pleurae, pericardium, myocardium, endocardium, mediastinal lymph nodes, bones, subcutaneous and paravertebral tissues, prostate, and left seminal vesicle; right-sided cardiac hypertrophy and dilatation; chronic passive congestion of liver and spleen; and accumulations of fluid in the peritoneal and pleural cavities.

## DISCUSSION

Consideration of the 2 cases reported here, together with those in the literature, indicates that blastomycosis may involve the heart by extension from pericardial blastomycosis, by direct miliary involvement of the cardiac musculature, or possibly by retrograde lymphatic extension from mediastinal lymph nodes. In the cases reported here the pericardium seemed to be infected from the adjacent pleurae, although extension from mediastinal nodes cannot be excluded in the 2nd case. Neither can an original colonization in the atrial myocardium be excluded in either case.

The pericardial lesions apparently extended into the myocardium of the right atrium, penetrating the endocardium and growing on the endocardial surface. Ulceration of the endocardial lesion occurred in the 1st case, producing miliary blastomycotic tubercles of the lungs. In the 2nd case it is thought that the mechanism of infection of the lungs was the same. However, organisms may have entered the lungs through the systemic veins, since there were many old blastomycotic lesions in various parts of the body.

The presence of thrombi in connection with the endocardial lesions is related to the injury of the endocardium and possibly also to the cardiac failure. They tend to occur between trabeculae and contain no organisms of any kind. They are thus unlike the thrombi of bacterial endocarditis and more like the bland mural thrombi found at autopsy in the auricle in various conditions.

The 2 cases reported here have additional interest because the blastomycotic lesions of the heart were associated with congestive heart failure. Both showed cardiac dilatation with comparatively little hypertrophy. The possibility that the edema was nutritional in type cannot be excluded, since studies of the blood proteins were unfortunately not done. However, 1 of the cases showed dependent edema, and both showed advanced chronic passive congestion of the liver in addition to accumulations of fluid in the body cavities. The exact mechanism of the production of cardiac insufficiency is not clear. The pockets of pus between the adherent pericardial layers and the pressure of blastomycotic lesions about the base of the heart with compression of veins, as in the 2nd case, may have contributed to the congestive failure.

A comparison between cardiac blastomycosis and cardiac tuberculosis reveals many features in common. In tuberculosis, endocardial masses may develop from a pericardial process, and blood-borne tubercles may form in the myocardium and endocardium. Of interest as a point of difference is the fact that in a series of cases of endocardial tuberculosis no thrombi were associated with the lesions.<sup>8</sup>

Cardiac blastomycosis is comparatively frequent when it is considered that we have been able to collect 9 cases and that the total reported number of cases of generalized blastomycosis with autopsy is much less than a hundred. A similar number of autopsies of cases of tuberculosis would not show such a high proportion unless many of them were instances of generalized miliary tuberculosis, in which case the percentage might be higher. The autopsied cases of blastomycosis have been instances of generalized dissemination, whereas most cases of tuberculosis coming to autopsy show pulmonary involvement and less conspicuous generalized dissemination.

#### SUMMARY AND CONCLUSIONS

Blastomycosis of the heart was encountered at autopsy in 2 cases of generalized infection with *Blastomyces dermatitidis*. Each showed diffuse pericardial blastomycosis, a large blastomycotic tubercle of the right atrial wall, and involvement of the corresponding endocardium. From the latter site organisms apparently entered the blood stream to produce the miliary pulmonary blastomycosis noted in both cases. Evidences of cardiac insufficiency, dependent probably on the cardiac blastomycosis, occurred in both.

Blastomycosis of the heart may also develop as part of generalized miliary blastomycosis, and possibly by retrograde lymphatic extension from the infection in mediastinal nodes.

Blastomycosis is similar to tuberculosis in respect to cardiac involvement.



## REFERENCES

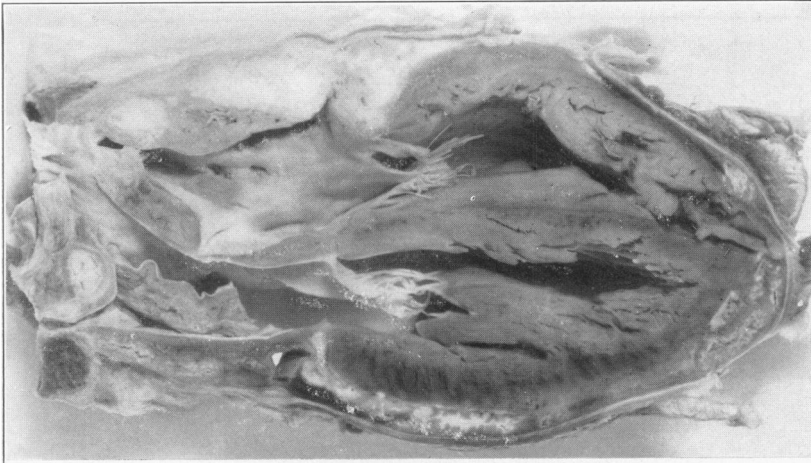1. LeCount, Edwin R. Miliary blastomycotic retrogressive lymphangitis of the epicardium. *Bull. Johns Hopkins Hosp.*, 1915, **26**, 315-316.
2. Hurley, Thomas D. An unique lesion of the heart in systemic blastomycosis. *J. M. Research*, 1915-1916, **33**, 499-502.
3. Cleary, John H. A case of generalized blastomycosis. *Medicine*, 1904, **10**, 818-823.
4. Coupal, James F. Report of six cases of blastomycosis. *Internat. Clin.*, 1924, **4**, 1-14.
5. Medlar, Edgar M. Pulmonary blastomycosis; its similarity to tuberculosis. Report of two cases. *Am. J. Path.*, 1927, **3**, 305-314.
6. Churchill, T., and Stober, Alvin M. A case of systemic blastomycosis. *Arch. Int. Med.*, 1914, **13**, 568-574.
7. Howes, Willard B., and Morse, Plinn F. Report of two cases of blastomycosis. *Boston M. & S. J.*, 1921, **185**, 315-317.
8. Baker, Roger D. Endocardial tuberculosis. *Arch. Path.*, 1935, **19**, 611-635.

## DESCRIPTION OF PLATE

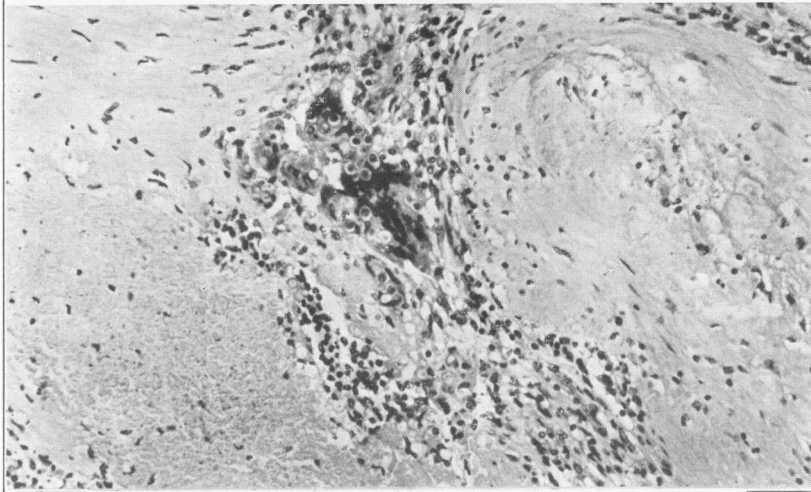
---

### PLATE 19

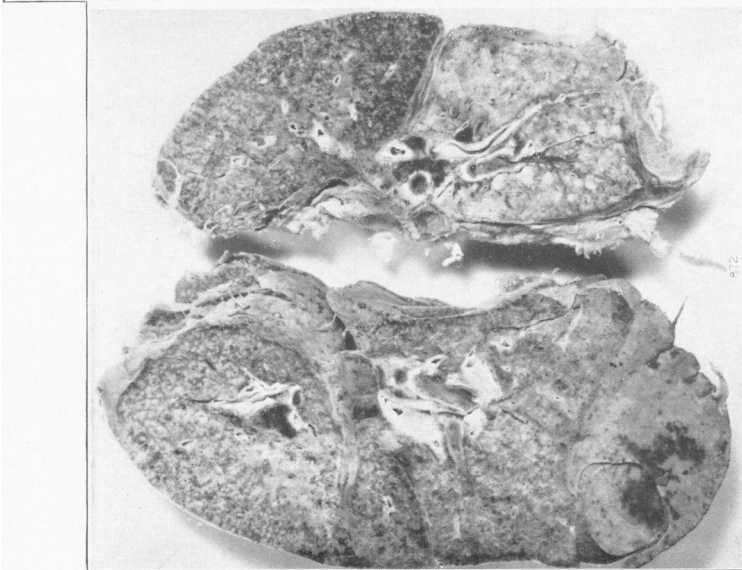- FIG. 1.** Case 1. Miliary pulmonary blastomycosis, probably derived from dissemination of blastomycetes from the ulcerated cardiac lesion. The posterior half of each lung is shown. The process in the left lower lobe is much older than the recent hematogenous spread.
- FIG. 2.** Case 1. Giant cell containing blastomycetes. From center of large atrial nodule. Necrosis above and to left; fibrosis prominent elsewhere.
- FIG. 3.** Case 2. Blastomycosis of the heart. The caseous pericardial process extends into the right atrium above the attachment of the tricuspid valve.



3



2



I