

A NEW METHOD FOR THE RAPID STAINING OF MYELIN SHEATHS *

WILBUR K. SMITH, M.D., AND BRIAN QUIGLEY

*(From the Department of Anatomy, University of Rochester,
School of Medicine and Dentistry, Rochester, N. Y.)*

The various methods that have so far been devised for staining the myelin sheaths of nerve fibers suffer from one of two disadvantages, either an undue complexity of the method or too great a length of time necessary for its execution. Weigert's methods,^{1,2} or any of the several modifications such as those of Pal³ and Kultschitzky,^{4,5} necessitate long periods of mordanting the entire block of tissue before embedding in a solution of either copper or chromium salts, or both. Preparation of the sections by these methods is so time consuming that a period of weeks or months must elapse before they are ready for study. Furthermore, these methods not only do not stain the cells, but the process of mordanting the blocks of tissue so alters the cellular elements that poor results are obtained when an attempt is made to stain the cells by other methods.

The iron hematoxylin method devised by Heidenhain⁶ for staining tissues in general has been adapted to the staining of myelin sheaths by several investigators including Loyez,⁷ Spielmeyer,⁸ Morgan,⁹ Weil,¹⁰ and Clark and Ward.¹¹ While all of these procedures require much less time than Weigert's original method, or its modifications, none of them combines the qualities of reliability, simplicity and rapidity to such a degree as the method described in this report.

The method described herein may be performed in from $\frac{1}{2}$ to 1 hour, depending on the thickness of the sections. It is applicable to normal or pathological material and works well on frozen, paraffin or celloidin sections. It has the further advantage that only the sections to be stained need be mordanted so that sections adjacent to the myelin stained ones may be stained by other methods. In addition, the chromophilic substance may be stained with excellent results in the section that has been stained for myelin sheaths. The myelin is stained a deep blue and the background remains either colorless or

* Received for publication February 3, 1937.

slightly tinted, depending on the degree of differentiation. The nuclei of all the cellular elements are stained in such a manner that the nuclear structure is clearly shown and it is therefore possible to differentiate the various types of glial cells from each other and from the nerve cells. The chromophilic substance may be stained in the same section by the use of neutral red, thionin or a similar stain.

DIRECTIONS

1. Mordant sections for 15 minutes in a 4 per cent aqueous solution of ferric ammonium sulphate ($\text{FeNH}_4(\text{SO}_4)_2$) prepared from violet crystals.
2. Rinse in 70 per cent alcohol to remove excess of mordant.
3. Place sections in a solution of 1 per cent hematoxylin containing 2 to 3 per cent glacial acetic acid by volume. (The 1 per cent hematoxylin solution is made by the addition of distilled water to a 10 per cent stock solution of hematoxylin in absolute alcohol.) The solution containing the sections is kept at or near 55°C . The sections at first stain deeply, then differentiate, and the depth of staining of the myelin sheaths depends on the time the sections are left in the staining-differentiating solution. Usually between 30 and 60 minutes are required but thin sections may require less time.
4. Place in a half saturated solution of lithium carbonate for 5 to 10 minutes.
5. Rinse in tap water.
6. Counterstain or stain for chromophilic substance if desired.
7. Dehydrate in alcohol, clear in xylol and mount in balsam.

COMMENT

This method gives excellent results with paraffin, celloidin or frozen sections after a number of fixatives, including formalin, alcohol-formalin, and Bouin's fluid. Sections of brain stem which had been preserved in formalin for 5 years stained well. Fixatives containing copper or chromium salts, *e.g.* Zenker's fluid, are not applicable to this method since differentiation will not occur after their use.

Frozen sections can be cut directly from the fixative and stored either in 10 per cent formalin or in 70 per cent alcohol, from which they may be taken and placed directly in the mordant. Paraffin

sections can be stained mounted or unmounted, as desired, but it is necessary to remove the paraffin before the method is applied. In the case of celloidin sections the celloidin need not be removed for no stain is left in it at the completion of the process. On the other hand, if it is so desired, the celloidin may be removed without adverse effects, either before or after the staining process is completed.

The 4 per cent ferric ammonium sulphate mordant should be made from violet crystals and the solution can be used repeatedly as long as it remains clear and without a precipitate. Sections may be placed in the mordant directly from 70 per cent or 80 per cent alcohol, in which they have been stored, or from 10 per cent formalin solution or water. A period of 15 minutes in the mordant is ample; a longer time does no harm and, when convenient, a group of sections may be mordanted overnight and the process completed the next day. Sections that have been mordanted for 2 weeks have been successfully stained. After mordanting the sections are rinsed in 70 per cent alcohol in order to remove the excess of the ferric ammonium sulphate solution. Alcohol is used in preference to water because of the tendency of the water to remove too much of the mordant from the tissue.

The staining solution used in this procedure is unique in that the sections not only stain but also differentiate in the same solution. The staining-differentiating solution is prepared from a 10 per cent stock solution of hematoxylin in absolute alcohol. This solution does not require ripening and it may be used immediately after preparation. Ripening, on the other hand, does not affect the quality of the results. In order to avoid overripening about a month's supply is usually made up in advance and kept tightly corked. Just before using, the required amount of the 10 per cent stock solution is diluted to 1 per cent by the addition of distilled water and enough glacial acetic acid is added so that the solution contains 2 to 3 per cent glacial acetic acid by volume. This gives a sufficiently rapid differentiation in nearly all instances, but if a more rapid differentiation is desired the solution may be made up to contain as much as 8 per cent glacial acetic acid without any apparent harm to the sections. In every instance it is important that the sections be observed frequently in order to prevent differentiation from proceeding too far. A convenient way to handle the sections is to place them in the stain in Petri dishes on a slide warming table. Care

should be taken to make certain that the sections are entirely covered by the staining-differentiating solution and do not lie upon one another, otherwise an irregular differentiation occurs. When the section has been differentiated to the desired degree it is placed in a half saturated solution of lithium carbonate for about 5 minutes. In the lithium carbonate solution not only is the differentiation stopped but the hematoxylin that has not been fixed in the tissues diffuses into the solution. The section is then placed in tap water for a few minutes, dehydrated in graded alcohols and mounted in neutral balsam. If it is necessary to keep stained sections a day or two before mounting they should be placed in tap water since storage in alcohol causes the stain to fade slowly.

Occasionally it may be found necessary to interrupt the process of differentiation before it has been completed. Under such circumstances the section may be taken from the staining-differentiating solution, placed for 5 minutes in a half saturated solution of lithium carbonate and then transferred to tap water where it may be kept for as long as several days. When convenient the differentiation may be completed by placing the section in the staining-differentiating solution at 55° C. If for any reason the differentiation has been allowed to proceed too far, the section may again be mordanted and the staining-differentiating process repeated.

The advantage this method offers in making possible the staining of sections for myelin sheaths and the adjacent sections for other structures is further enhanced by the fact that a cell stain may be used on the myelin stained sections. Although the cytoplasm of the nerve cells is tinted and the chromophilic granules are usually faintly discernible in the sections, they are not stained well enough for careful study. If, therefore, it is desired to study the chromophilic substance in the myelin stained sections they can be stained in the usual manner by any of the chromophilic stains such as thionin, toluidine blue or neutral red. We have found that a 1 per cent aqueous solution of neutral red not only stains the chromophilic granules well but also affords a good contrast stain.

In addition to staining the myelin sheaths this procedure affords a nuclear stain of such excellence that details of nuclear structure are clearly shown and differentiation of cell types is possible on this basis. All of the cells show a more or less distinct nuclear membrane. The large nucleus of the nerve cell possesses a conspicuous black

staining nucleolus and an extremely delicate, net-like arrangement of nuclear chromatin. The nucleus of the astrocyte, usually about the size of that seen in the small nerve cells, possesses no such large and conspicuous nucleolus but usually contains a number of small deeply stained granules, two or three of which are decidedly larger than the others. The nuclei of the oligodendroglia appear smaller than either of the preceding and contain several relatively large, deeply staining, irregularly shaped chromatin masses scattered throughout the nucleoplasm. The microglia possess the smallest and most elongated nuclei of all the glial cells and have many deeply stained chromatin granules within the nucleoplasm. Red blood cells stain black, a characteristic that renders areas of vascular congestion or extravasation easily recognizable microscopically. The nuclear structure of endothelium, smooth muscle and connective tissue is clearly shown.

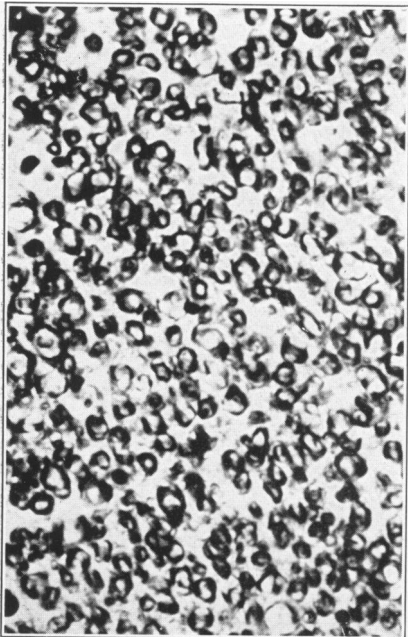
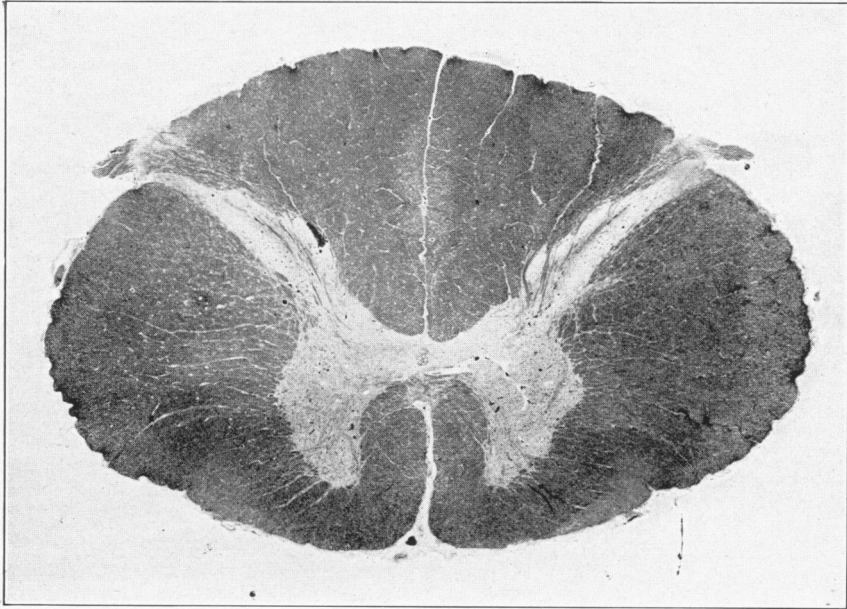
REFERENCES

1. Weigert, C. Eine Verbesserung der Haematoxylin-Blutlaugensalzmethode für das Centralnervensystem. *Fortschr. d. Med.*, 1885, 3, 236-239.
2. Weigert, C. Zur Markscheidenfärbung. *Deutsche med. Wchnschr.*, 1891, 17, 1184-1186.
3. Pal, J. Ein Beitrag zur Nervenfärbetechnik. *Med. Jahrb.*, 1886, 82, 619-631.
4. Kultschitzky, N. Über eine neue Methode der Hämatoxylin-Färbung. *Anat. Anz.*, 1889, 4, 223-224.
5. Kultschitzky, N. Über die Färbung der markhaltigen Nervenfasern in den Schnitten des Centralnervensystems mit Hämatoxylin und mit Karmin. *Anat. Anz.*, 1890, 5, 519-524.
6. Heidenhain, M. Über Kern und Protoplasma. *Festschr. f. A. von Koelliker, W. Engelmann, Leipzig*, 1892, 109-166.
7. Loyez, Marie. Coloration des fibres nerveuses par la méthode à l'hématoxyline au fer après inclusion à la celloïdine. *Compt. rend. Soc. de biol.*, 1910, 69, 511-513.
8. Spielmeyer, Walther. Markscheidenfärbung am Gefrierschnitt. *Neurol. Centralbl.*, 1910, 29, 348-350.
9. Morgan, Lawrence Onis. Iron hematoxylin as a myelin sheath stain and neutral red ripened by colon bacillus as a nerve-cell stain. *Anat. Rec.*, 1926, 32, 283-293.
10. Weil, Arthur. A rapid method for staining myelin sheaths. *Arch. Neurol. & Psychiat.*, 1928, 20, 392-393.
11. Clark, S. L., and Ward, J. W. A variation of the Pal-Weigert method for staining myelin sheaths. *Stain Tech.*, 1934, 9, 53-55.

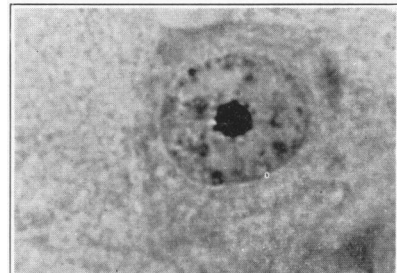
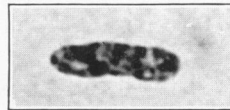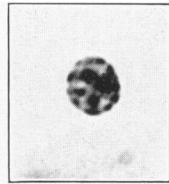
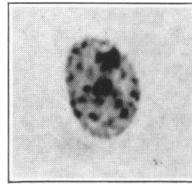
DESCRIPTION OF PLATES

PLATE 83

- FIG. 1.** Human spinal cord stained by the new method showing the sharp demarcation between the white and gray matter and the amyelinic zone of the entering dorsal root. Formalin fixation, celloidin section, 20 μ . \times 10.
- FIG. 2.** A portion of the dorsal columns from Fig. 1 showing the definitive staining of the myelin sheaths. Formalin fixation, celloidin section, 20 μ . \times 500.
- FIGS. 3, 4, 5 and 6.** Nuclei of astrocyte, oligodendroglia, microglia and nerve cell from a myelin stained section of the cerebral cortex of the dog. Formalin fixation, celloidin section, 20 μ . \times 1500.



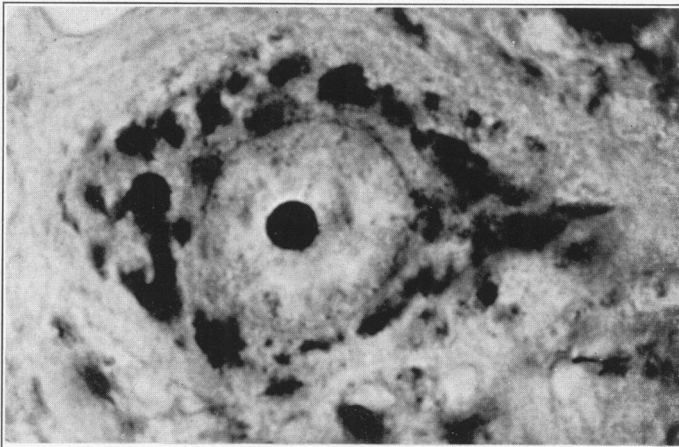
Smith and Quigley



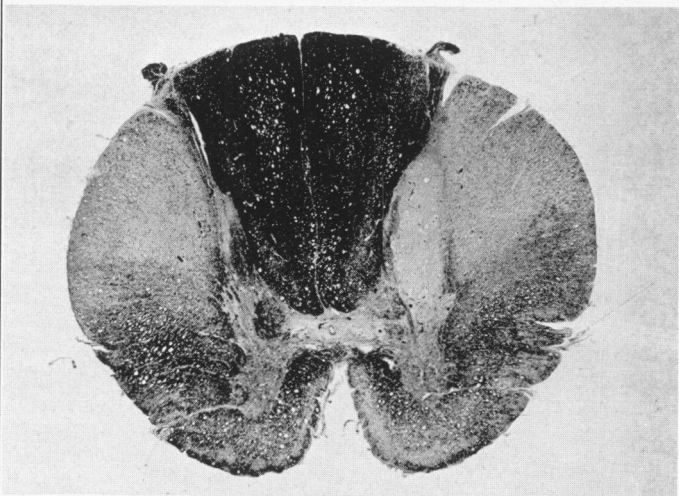
Rapid Staining of Myelin Sheaths

PLATE 84

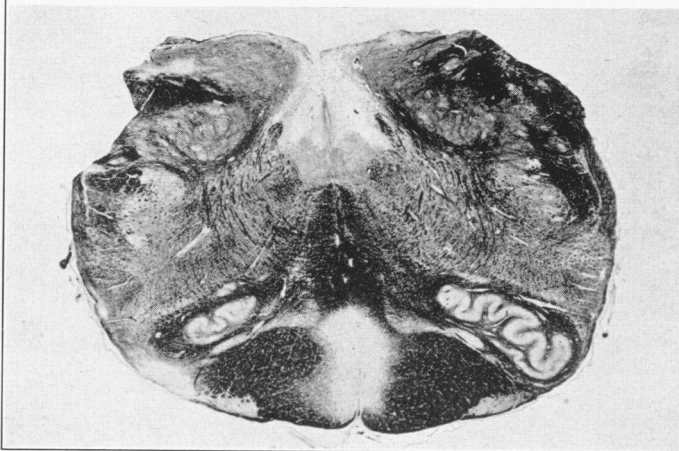
- FIG. 7. Nerve cell from a section of normal spinal cord stained with neutral red after the myelin sheath stain. The chromophilic granules have retained their normal arrangement and ability to stain. Formalin fixation, celloidin section, 20 μ . \times 1500.
- FIG. 8. Spinal cord from a case of myelitis. Myelin sheath stain. Formalin fixation, paraffin section, 20 μ . \times 10.
- FIG. 9. Section through the medulla oblongata from a case of multiple sclerosis. The demyelinated plaques are clearly defined by this staining method. Formalin fixation, celloidin section, 20 μ . \times 5.



7



8



9

Smith and Quigley

Rapid Staining of Myelin Sheaths