

ANIMAL MODEL
OF
HUMAN DISEASE

Subacute Sclerosing Panencephalitis,
Multiple Sclerosis

Animal Model: Distemper-Associated
Demyelinating Encephalomyelitis

Contributed by: A. Koestner, DVM, PhD, Department of Veterinary Pathobiology, The Ohio State University School of Veterinary Medicine, Columbus, OH 43210.

Biologic Features

Canine distemper is a naturally occurring infectious disease of dogs and other members of the canine family caused by a paramyxovirus closely related, both physicochemically and antigenically, to human measles virus.¹ The acute or subacute disease is characterized clinically by pyrexia, leukopenia, nasal and ocular discharge, and signs of respiratory and gastrointestinal infection. Occasionally, hyperkeratosis of the food pads develops. Secondary bacterial infection in untreated animals results in a suppurative pneumonia that is usually fatal.

Some dogs develop a demyelinating encephalomyelitis characterized by a gradual or precipitous onset of severe neurologic signs including tremors, spasms, paresis, paralysis and convulsions. These signs may appear several weeks or months after recovery from the generalized disease. They sometimes develop without any preceeding clinical illness in aged and immunized dogs. This phase of distemper in dogs has been described as postdistemper encephalitis, old-dog encephalitis, acute multiple sclerosis and subacute diffuse sclerosing encephalitis. This selection of names indicates the attributed similarity to subacute sclerosing panencephalitis (SSPE) and multiple sclerosis (MS) in man.

Pathologic Features

The demyelinating stage of canine distemper affects primarily the white matter of cerebellum, brain stem and spinal cord with a rather distinct periventricular predilection. Excellent detailed descriptions of the lesions exist in the literature.²⁻⁴ In general, the lesions are either demyelinating or necrotic. The demyelinating lesions (Figure 1) are characterized by patches of vacuolization representing destruction of myelin. Lipid-laden macrophages (gitter cells) can be demonstrated in

Publication sponsored by the Registry of Comparative Pathology of the Armed Forces Institute of Pathology and supported by Public Health Service Grant RR 00301 from the Division of Research Resources, US Department of Health, Education and Welfare, under auspices of Universities Associated for Research and Education in Pathology, Inc.

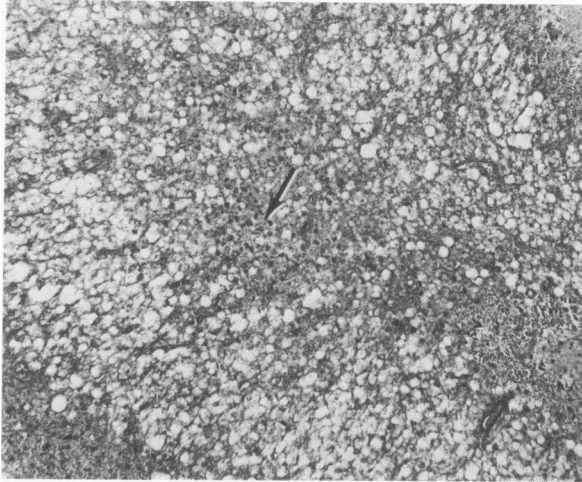


Fig 1 (top)—Cerebellum from a dog with distemper-associated demyelinating encephalitis. Note the status spongiosus in cerebellar folium and severe loss of myelin. Dark spots (*arrow*) are PAS-positive breakdown products. Note absence of perivascular cuffs (Luxol-fast blue-PAS, $\times 150$).

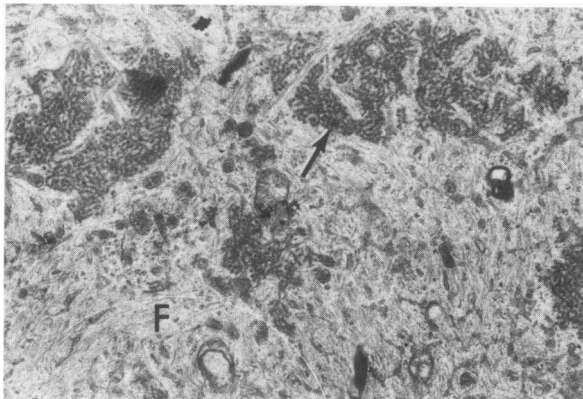


Fig 2 (bottom)—Electron-micrograph illustrating aggregates of tubular nucleocapsids (*arrow*) of canine distemper virus within an astrocyte. Note glial filaments (*F*) (Contrasted with uranyl acetate and lead hydroxide $\times 21,000$).

and around patches of demyelination and sometimes aggregated within the vicinity of blood vessels. Inclusion bodies, mostly intranuclear, are demonstrable in glial cells and are composed ultrastructurally of aggregates of nucleocapsids of distemper virus (Figure 2). While perivascular cuffs of hematogenous cells (lymphocytes, plasma cells and monocytes) usually are associated with demyelinating lesions, plaques can be detected in cases with minimal or absent perivascular infiltration.

Necrotic plaques represent a nonselective degeneration, encompassing axons, which are generally unaffected (naked axons) in demyelinating lesions. The necrotic plaques often resemble a glial scar with fibrous astrocytes forming a network in which macrophages are entrapped.³

Comparison with Human Disease

The disease in dogs may be compared with two human diseases—SSPE and MS. SSPE has been definitely linked to measles virus infection. Measles virus and measles virus antigen⁵ have been demonstrated

in brain sections, and virus has been isolated from brain lesions of children with SSPE.⁶⁻⁹ Similarly, distemper virus antigen has been demonstrated in lesions of the white matter in dogs with distemper-associated demyelinating encephalitis.

Evidence has accumulated in the past few years suggesting that MS may also be a virus-induced demyelinating encephalitis. Most serologic surveys have indicated a higher measles antibody titer in MS patients as compared to control populations.¹⁰ Viral particles of the paramyxovirus type have been demonstrated in acute demyelination of chronic relapsing MS¹¹ and in cells cultured from brains of MS patients.¹²

Lesions in SSPE usually are widely dispersed throughout the gray and white matter of the nervous system; unlike in distemper, they occur without predisposition for any particular region.¹³ In addition to perivascular and leptomenigeal infiltrates of mononuclear cells, areas of gliosis are associated with a patchy demyelination.¹³ There are cases reported in which demyelination is the prominent lesion, hence the synonymous designation of this disease as subacute sclerosing leukoencephalitis.¹⁴ Inclusion bodies are usually demonstrated.¹³

MS, a disseminated sclerosis, is characterized by a patchy demyelination as the primary lesion. The demyelinated plaques with preserved axons are similar to the demyelinating foci of canine distemper. Predilection sites are in the white matter adjacent to the lateral ventricles and the long tracts of the brain stem and spinal cord. Because of the recurrent nature of this disease (remissions and relapses) early demyelinating foci and old sclerotic plaques may be found side by side. Although the pattern of remissions and relapses has not been reported in canine distemper, the possibility of its occurrence can not be excluded.

It may be hypothesized that demyelination in canine distemper and perhaps in SSPE and MS is virus-induced and dependent upon certain mutants of paramyxoviruses. These mutants have the capability to persist in the brain and induce an antimyelin response. The antimyelin response is most likely due to membrane alteration of glial cells and is independent of viral maturation. Myelin-reactive complement-fixing antibodies probably amplify the virus-induced membrane lesion.

Experimental Model

In addition to the spontaneous cases of canine-distemper-virus-induced demyelinating encephalitis available for study, we have recently been successful in reproducing demyelinating encephalitis experimentally in a high percentage of gnotobiotic puppies with a specific canine distemper virus isolate using various routes of inoculation, including

contact exposure.¹⁵ The latent period is 5 to 6 weeks. The course of the disease depends on the route and dose of infection and also on the age of the dogs. Just like dogs with the natural disease, those with demyelinating encephalitis contain serum antibodies against myelin.¹⁵ Preliminary studies indicate that animals in remission, and even those without clinical signs of disease, show evidence of nervous system infection in the form of distemper virus antigen demonstrable by the fluorescence antibody technic. The firm establishment of this model may provide a basis for the clarification of the pathogenesis of virus-induced demyelinating encephalitis.

References

1. Appel MJC, Gillespie JJ: Canine distemper virus. *Virology Monographs* 11:1-96, 1972
2. Innes JRM, Saunders LZ: *Comparative Neuropathology*. New York, Academic Press, Inc, 1962
3. Raine CS: Viral infections of nervous tissue and their relevance to multiple sclerosis. *Multiple Sclerosis*. Edited by F Wolfram, GW Ellison, JG Stevens, JM Andrews. New York, Academic Press, Inc, 1972, pp 91-118
4. Wisniewski HM, Raine CS, Kay WJ: Observations on viral demyelinating encephalomyelitis: canine distemper. *Lab Invest* 26:589-599, 1974
5. Connolly JH, Allen IV, Hurwitz LH, Millar JH: Measles-virus antibody and antigen in subacute sclerosing panencephalitis. *Lancet* 1:542-544, 1967
6. Chen TT, Watanabe I, Zeman W, Mealey Jr J: Subacute sclerosing panencephalitis: propagation of measles virus from brain biopsy in tissue culture. *Science* 163:1193-1194, 1969
7. Horta-Barbosa L, Fuccillo DA, Sever JL, Zeman W: Subacute sclerosing panencephalitis: isolation of measles virus from a brain biopsy. *Nature [Lond]* 221:974, 1969
8. Katz M, Rorke LB, Masland WS, Koprowski H, Tucker SH: Transmission of an encephalitogenic agent from brains of patients with subacute sclerosing panencephalitis to ferrets. *N Engl J Med* 279:793-798, 1968
9. Payne FE, Baublis JV, Itabashi HH: Isolation of measles virus from cell cultures of brain from a patient with subacute sclerosing panencephalitis. *N Engl J Med* 281:585-589, 1969
10. Brody JA: Epidemiologic and serologic data on multiple sclerosis and their possible significance.³ pp 127-141
11. Prineas J: Paramycovirus-like particles associated with acute demyelinating in chronic relapsing multiple sclerosis. *Science* 178:760-763, 1972
12. Iwasaki Y, Koprowski H, Müller D, ter Meulen V, Käckell YM: Morphogenesis and structure of a virus in cells cultured from brain tissue from two cases of multiple sclerosis. *Lab Invest* 28:494-500, 1973
13. Parker Jr JC, Klintworth GK, Graham DG, Griffith JF: Uncommon morphologic features in subacute sclerosing panencephalitis (SSPE). *Am J Pathol* 61:275-291, 1970
14. Tellez-Nagel I, Harter DH: Subacute sclerosing leukoencephalitis. I. Clinicopathological, electron microscope and virological observations. *J Neuropathol Exp Neurol* 25:560-581, 1966
15. Koestner A, McCullough B, Krakowka GS, Long JF, Olsen RG: Canine distemper: a virus-induced demyelinating encephalomyelitis. *Slow Virus Diseases*, Vol 3. Edited by W. Zeman. Baltimore, Williams & Wilkins, 1974